


**MALFORMATIONS  
DU  
MEMBRE SUPERIEUR**

**C.ROMAÑA  
HOPITAL TROUSSEAU  
PARIS**



# MALFORMATIONS DE LA MAIN

- ENORME SPECTRE DE DEFORMATIONS
- CLASSIFICATION TRES

PROBLEMATIQUE

INTERNATIONAL FEDERATION OF  
SOCIETIES FOR SURGERY OF THE  
HAND

# CLASSIFICATION

- 1- TROUBLES FORMATION
- 2- TROUBLES SEPARATION
- 3- DUPLICATION
- 4- SURDEVELOPPEMENT
- 5- SOUSDEVELOPPEMENT
- 6- BRIDES AMNIOTIQUES
- 7- ANOMALIES GENERALISEES

# 1° TROUBLES DE LA FORMATION



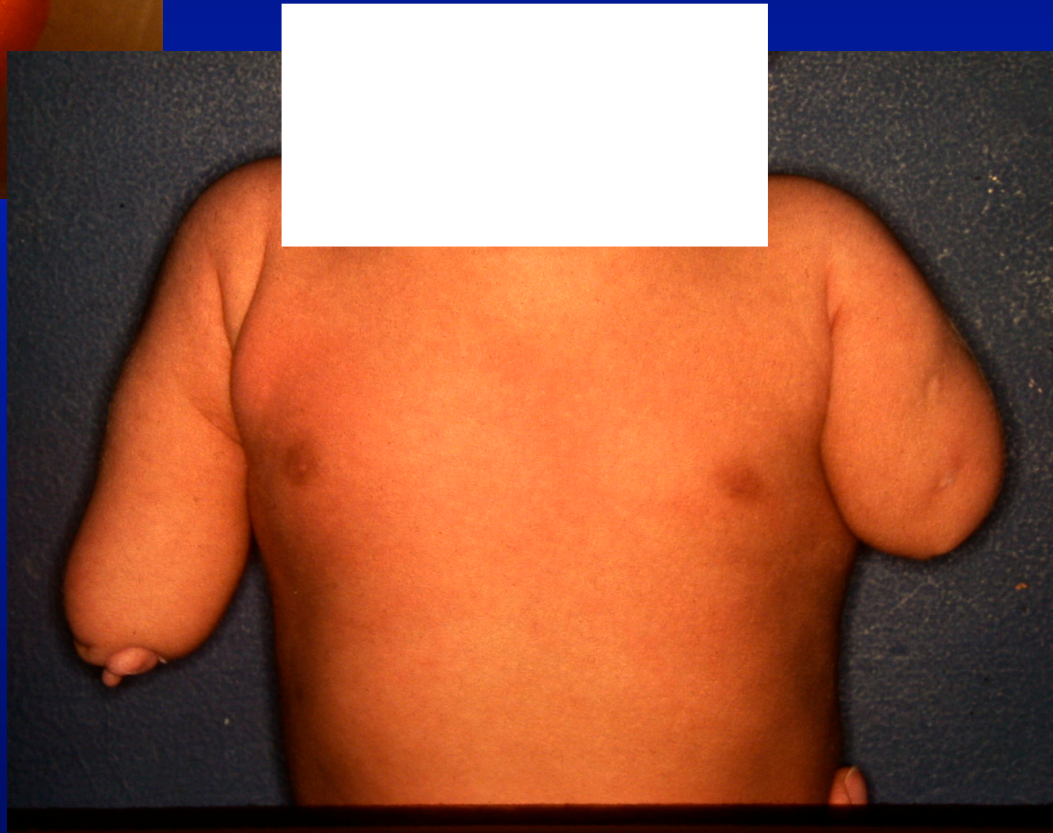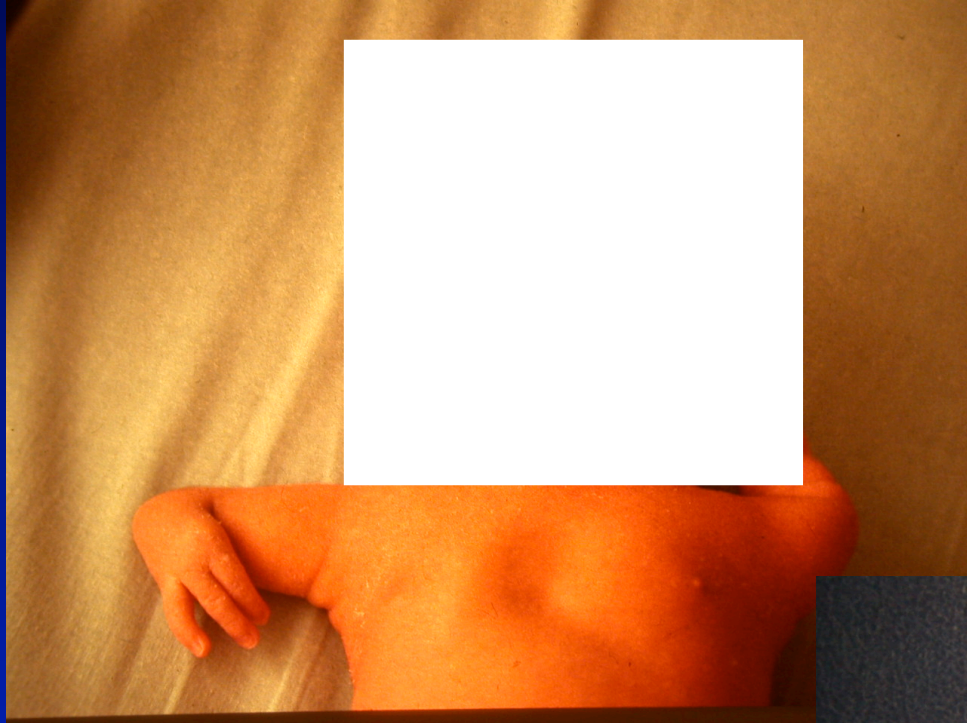**ARRET TRANSVERSAL**

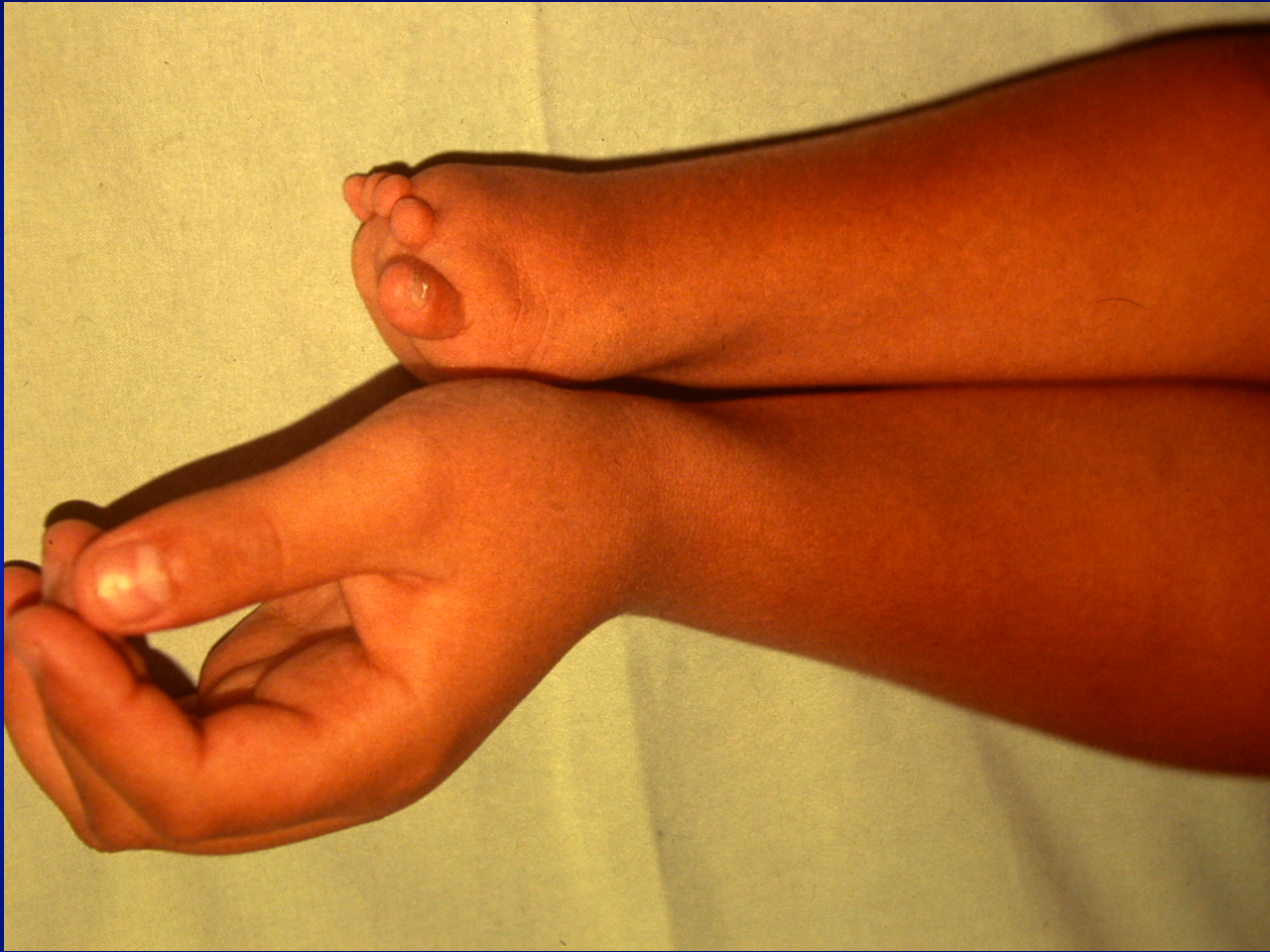**ARRET LONGITUDINAL**

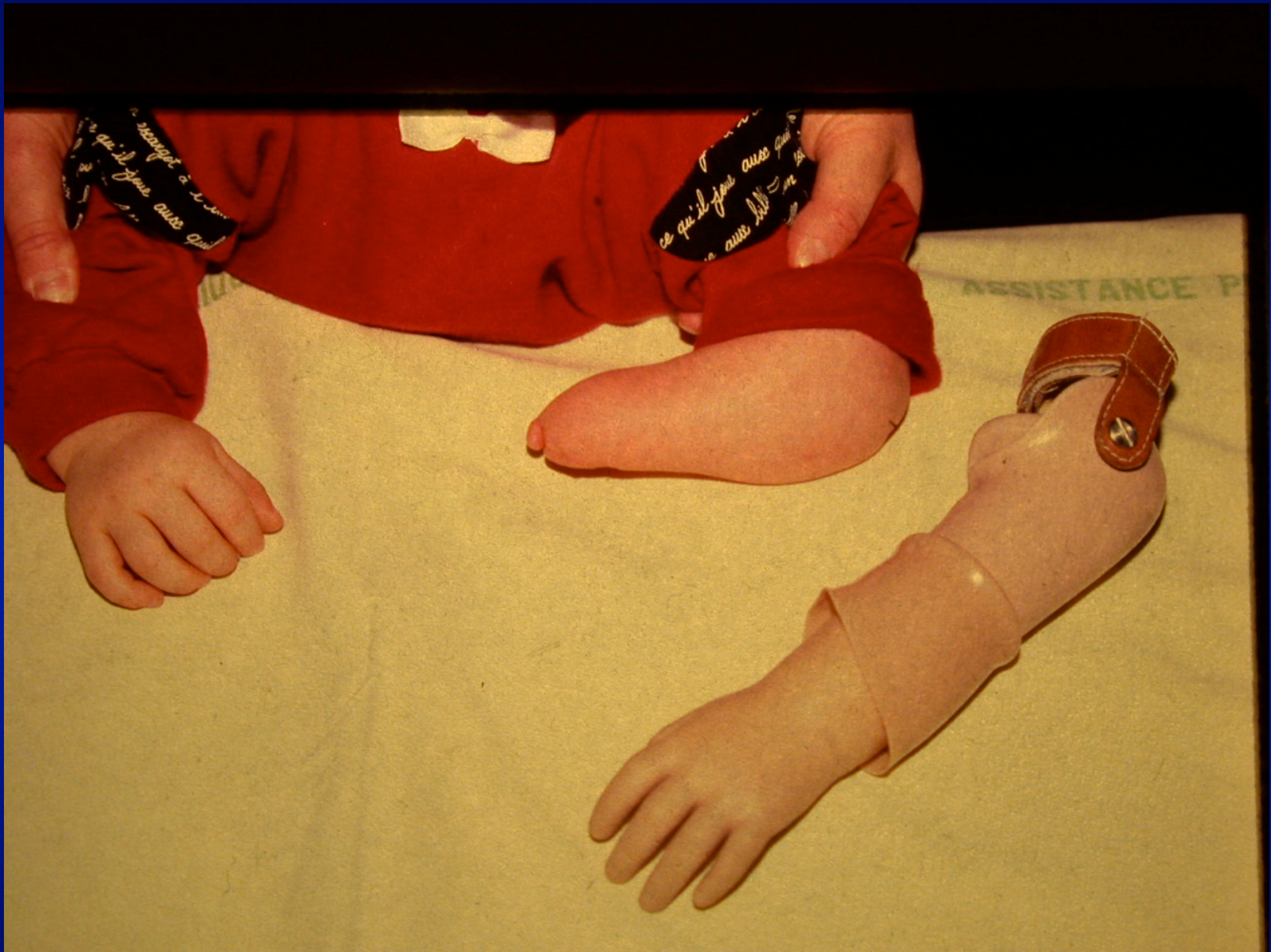**RAYON RADIAL**

**RAYON LONGITUDINAL**

**INTERSEGMENTAIRE**







# 1° TROUBLES DE LA FORMATION

**ARRET TRANSVERSAL**

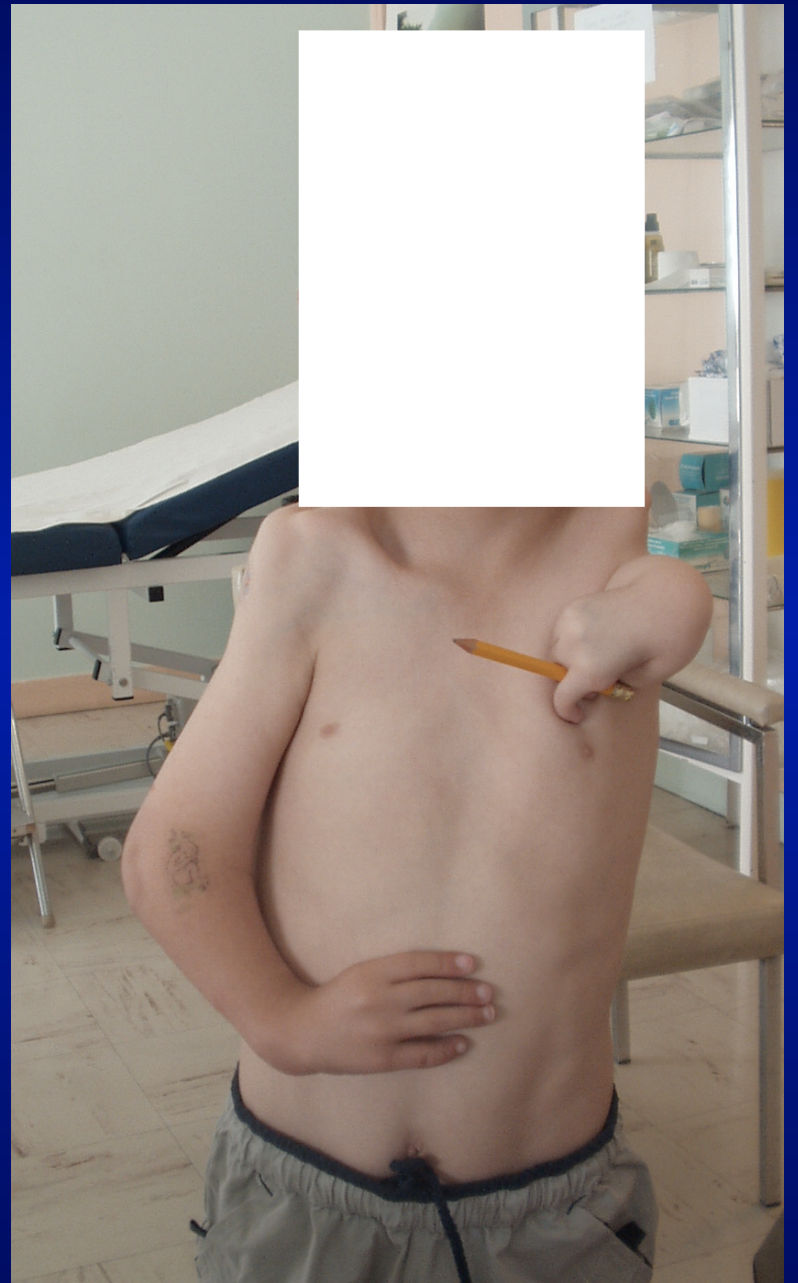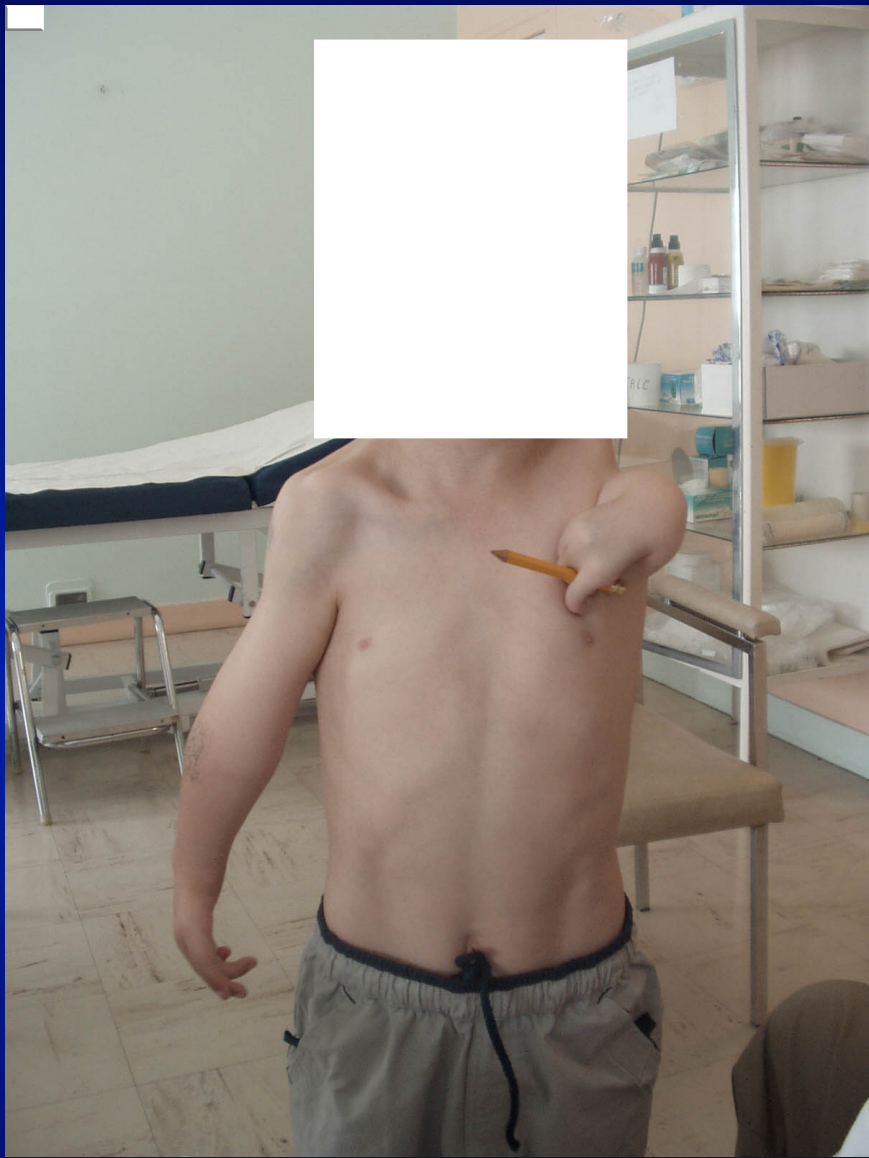✓ **ARRET LONGITUDINAL**

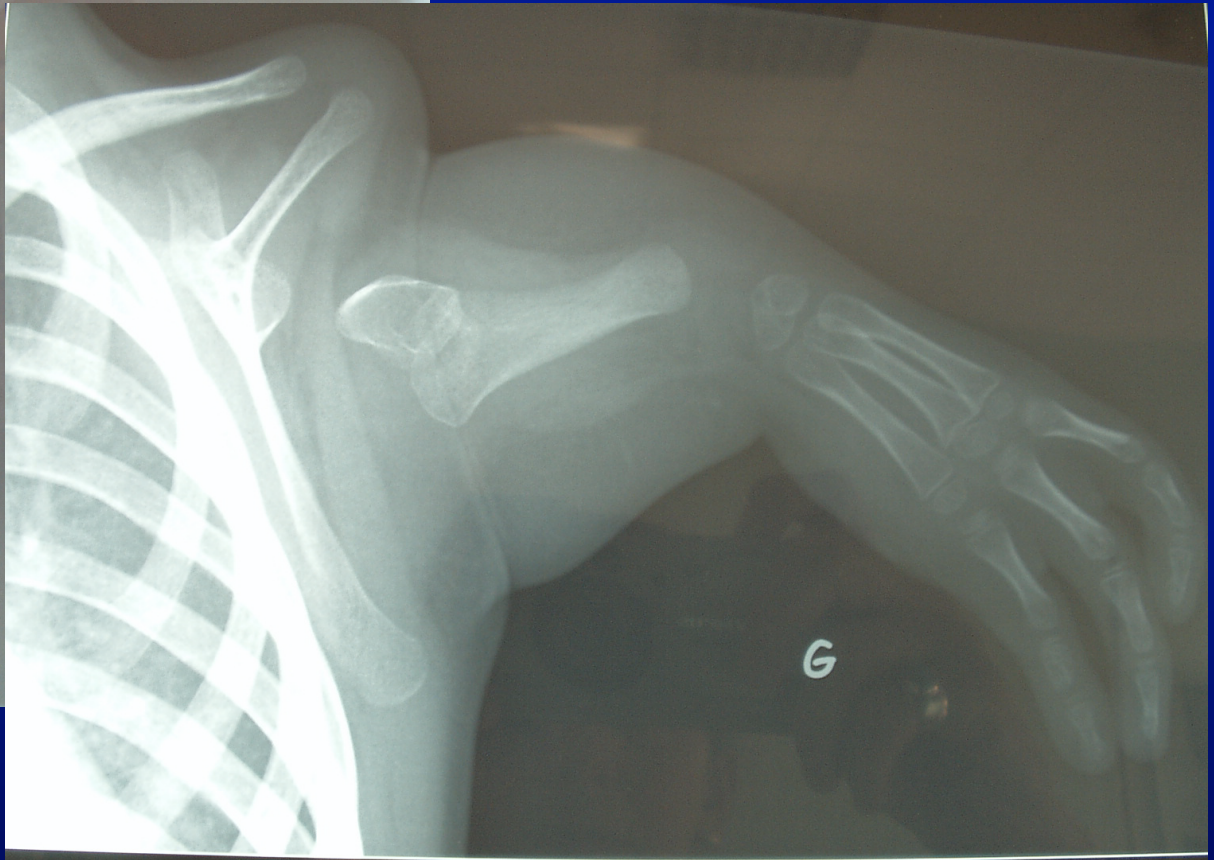
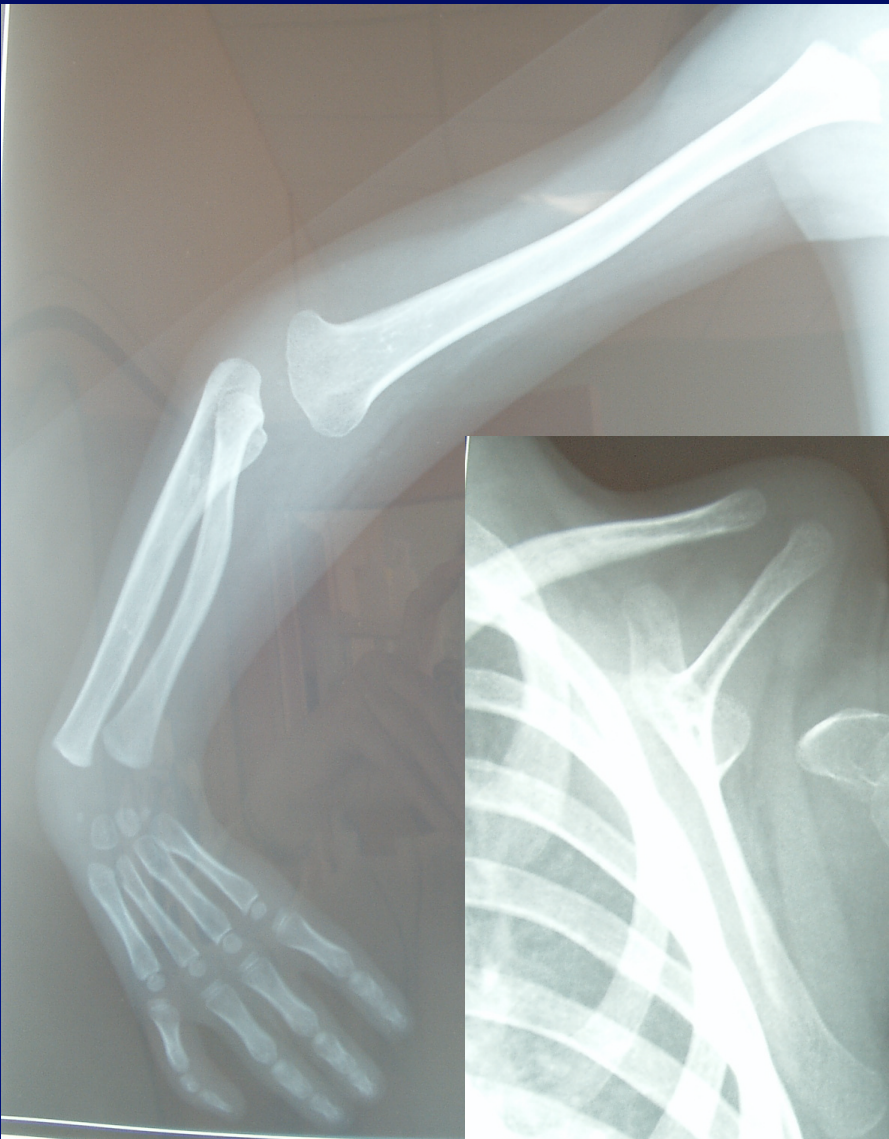
**RAYON RADIAL**

**RAYON LONGITUDINAL**

**INTERSEGMENTAIRE**

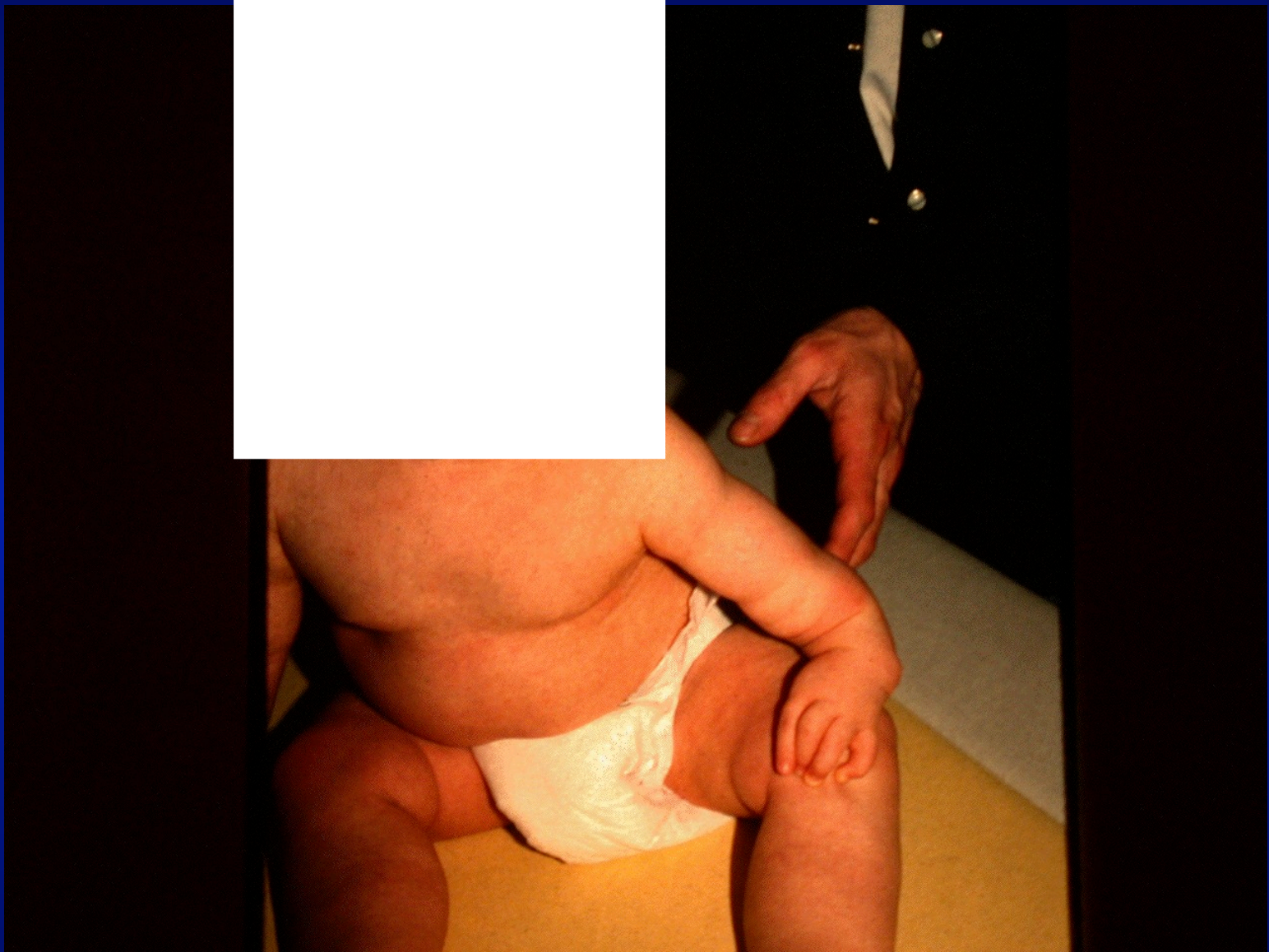

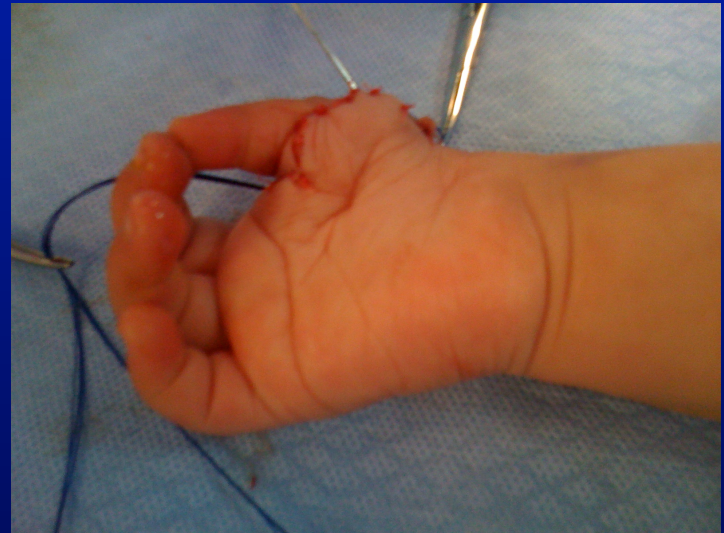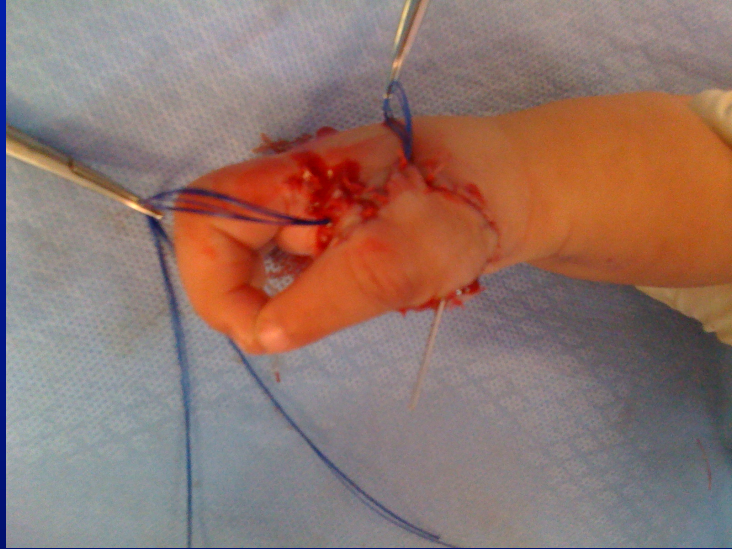
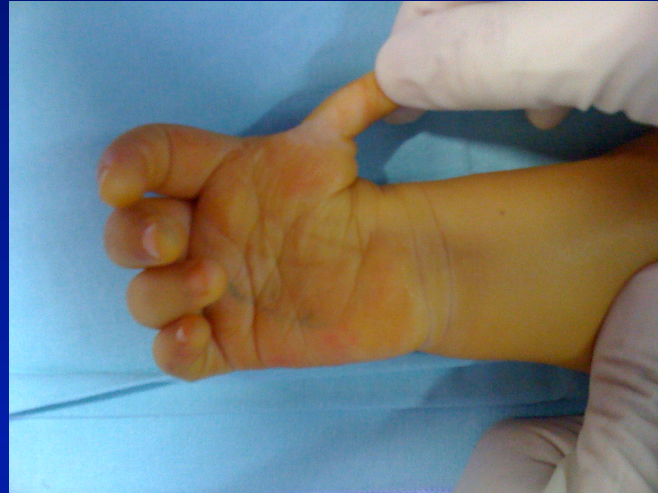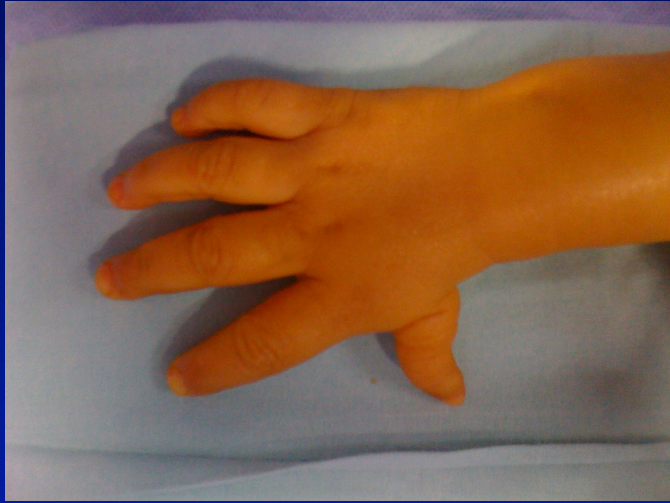




# MALFORMATIONS DE L'AVANT-BRAS

- HEMIMELIE LONGITUDINALE EXTERNE (*MAIN BOTE RADIALE*)
- HEMIMELIE LONGITUDINALE INTERNE (*MAIN BOTE CUBITALE*)
- SYNOSTOSE RADIO-CUBITALE

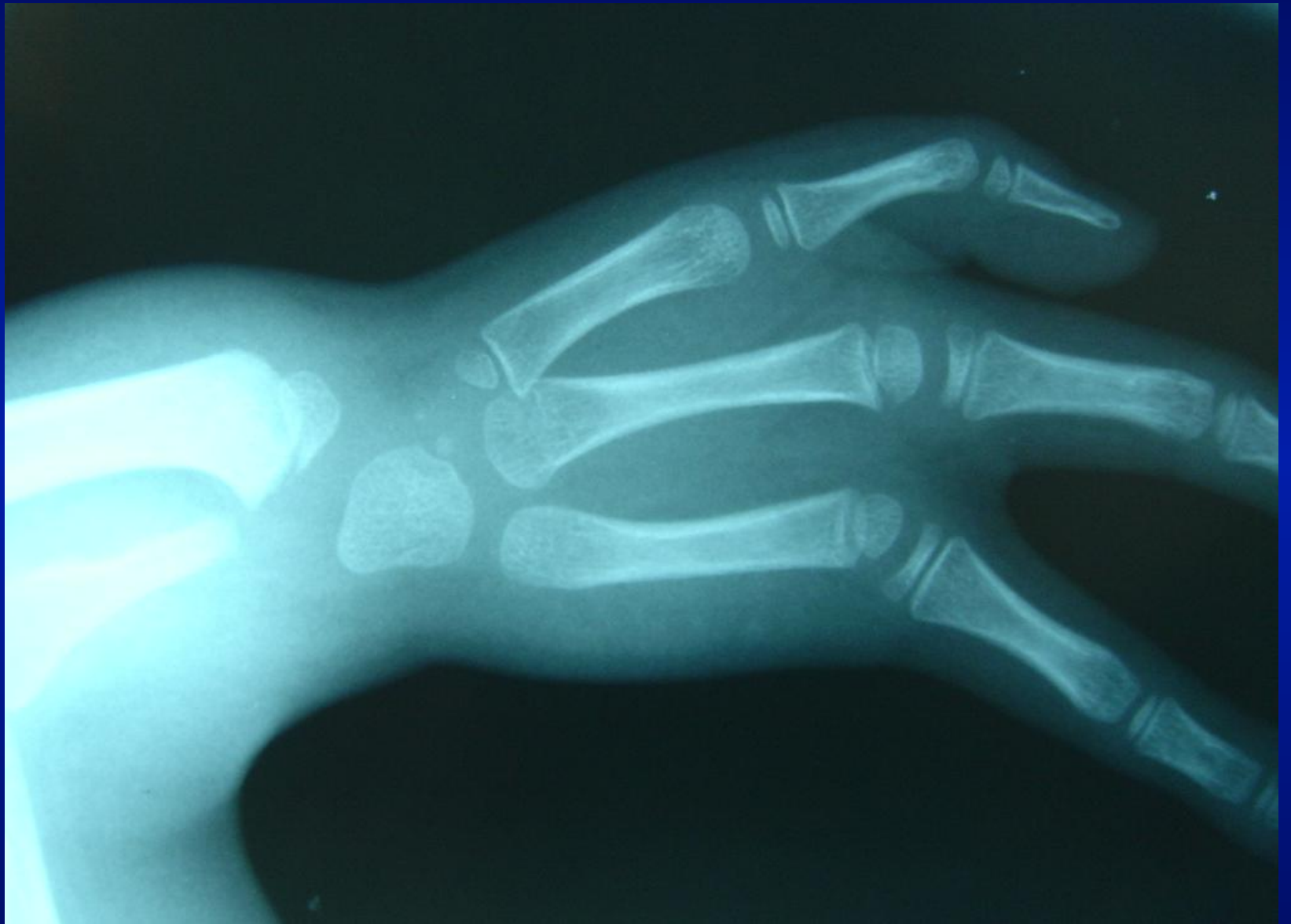



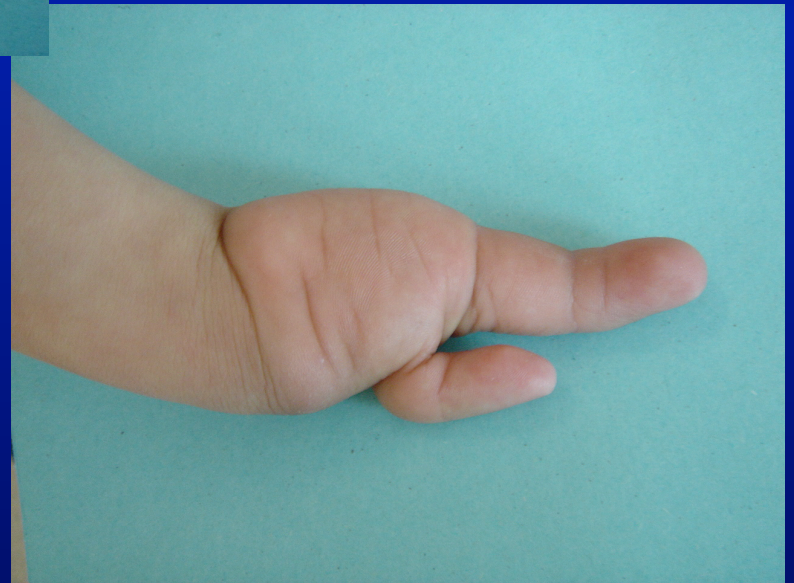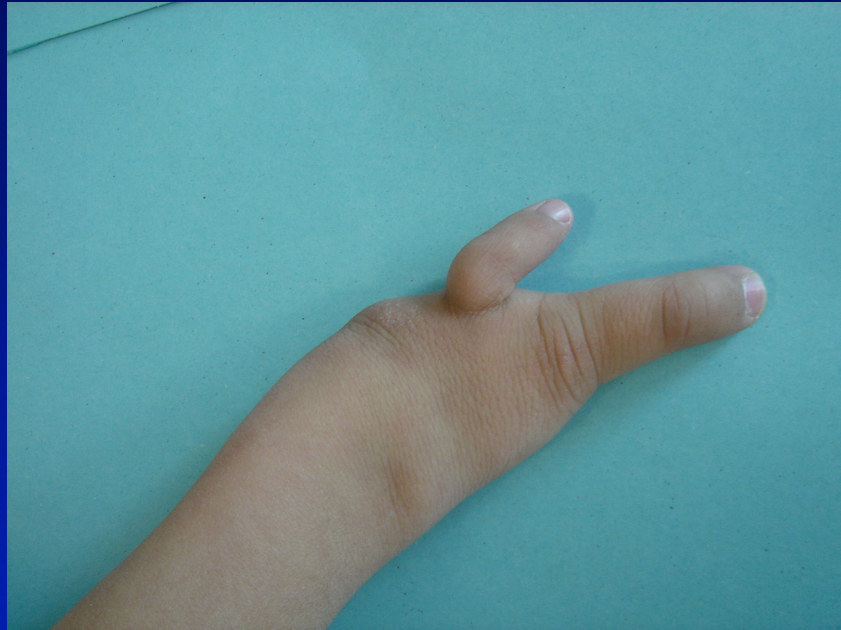# **MAIN BOTE CUBITALE**

- **ECTROMELIE LONGITUDINALE  
INTERNE**
- **ABSENCE TOTALE OU PARTIELLE  
CUBITUS**
- **FREQUENCE : TROIS FOIS MOINS  
MAIN BOTE RADIALE**









# 1° TROUBLES DE LA FORMATION

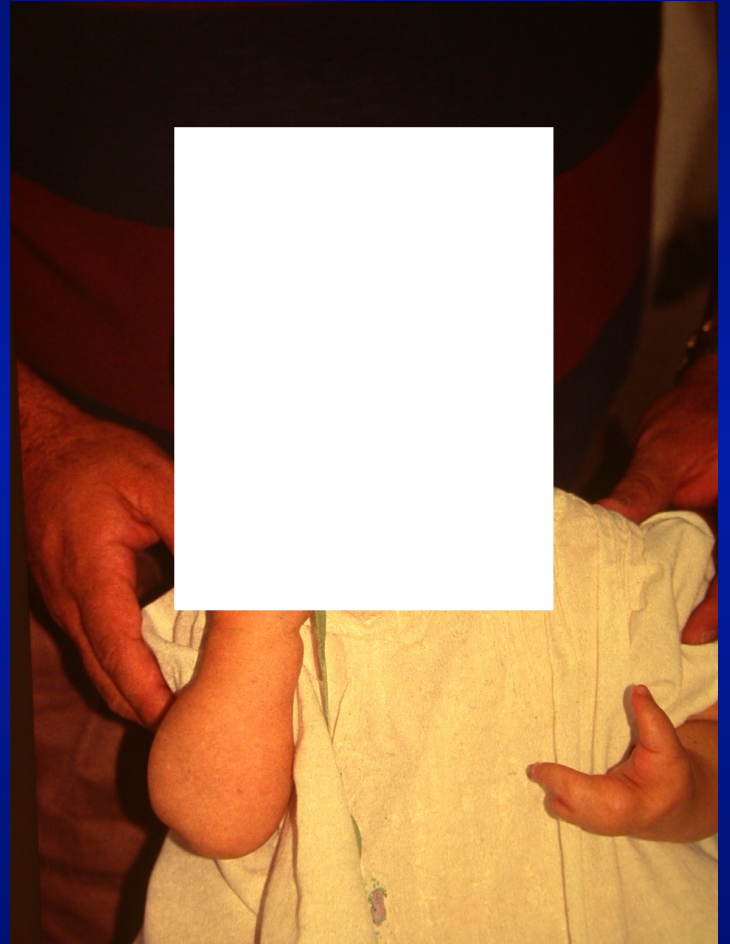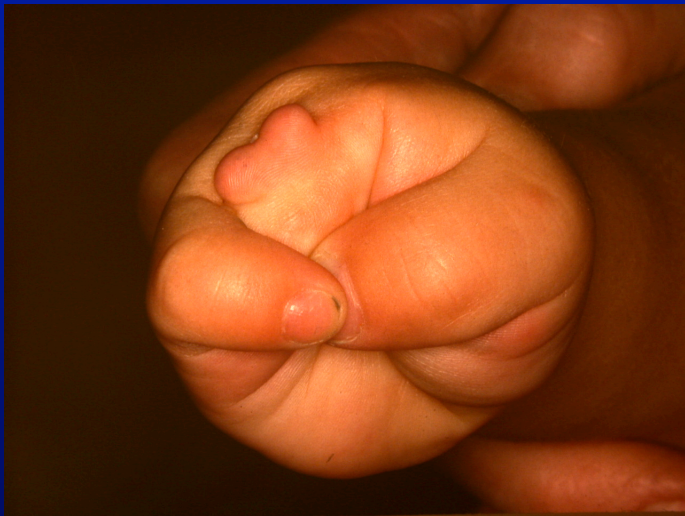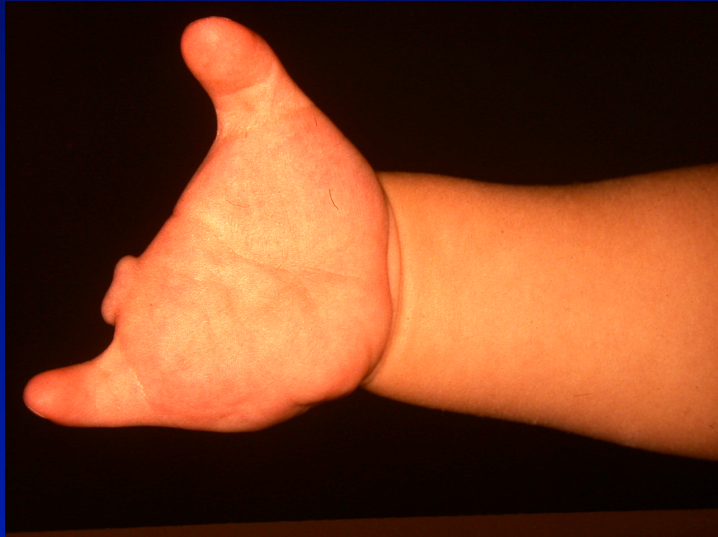**ARRET TRANSVERSAL**

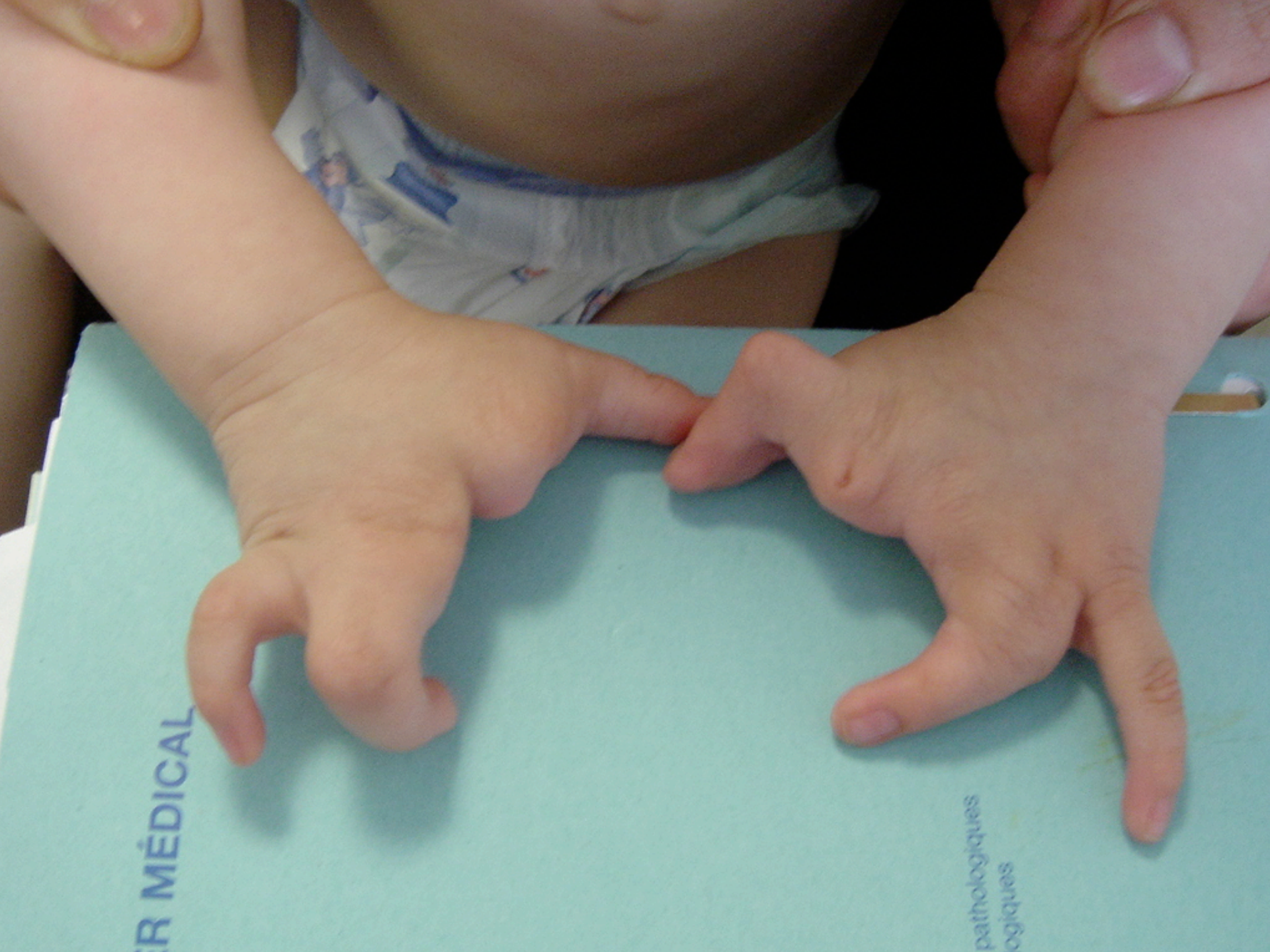**ARRET LONGITUDINAL**

**RAYON RADIAL**

**RAYON LONGITUDINAL**

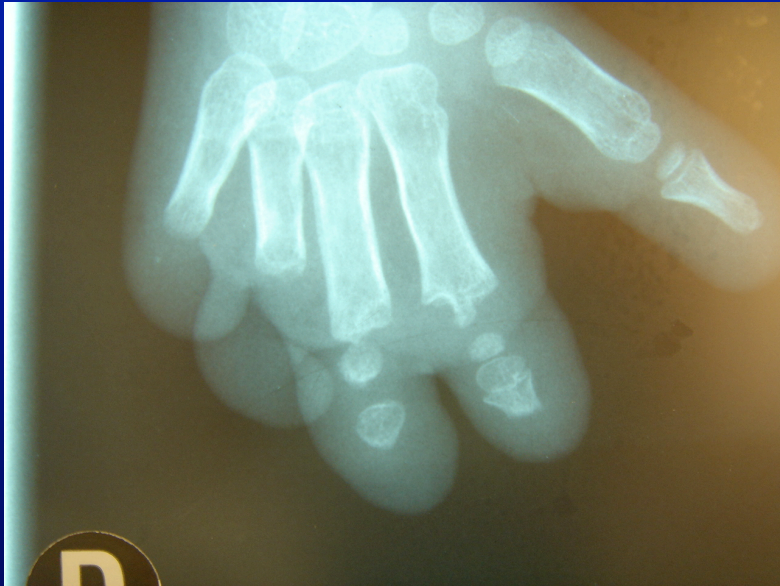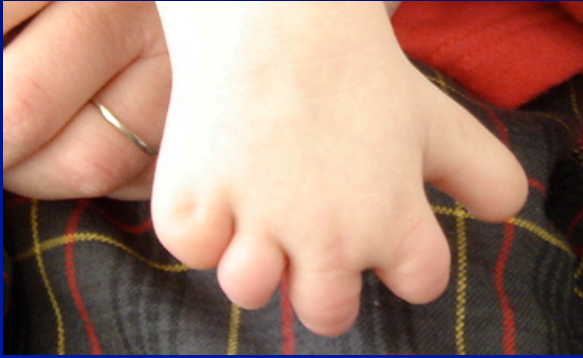**✓ INTERSEGMENTAIRE**





R MÉDICAL

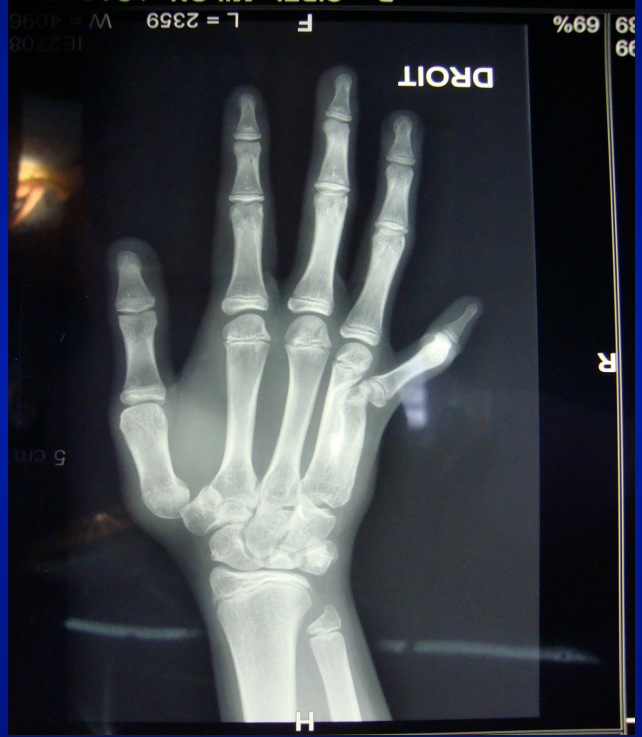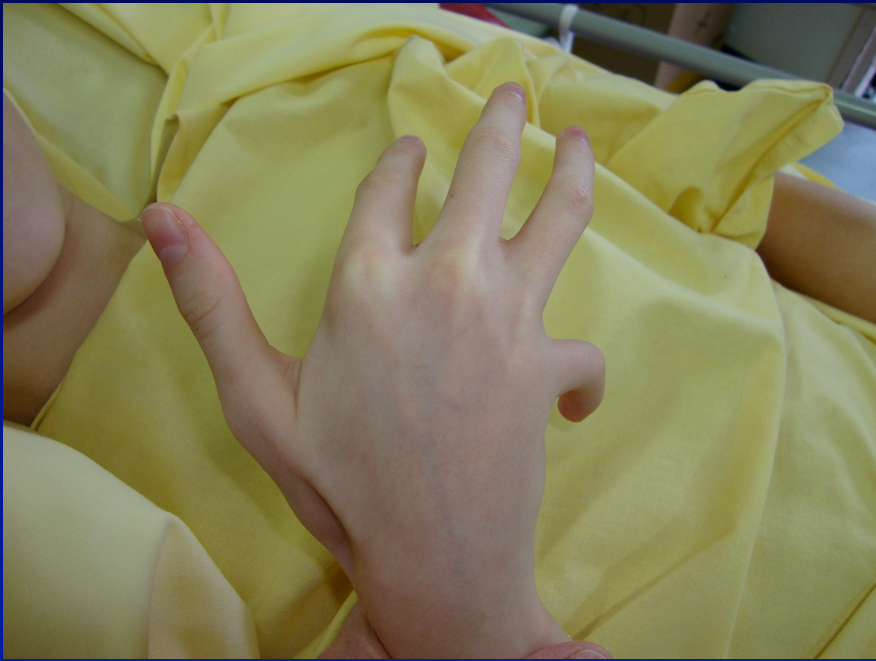pathologiques  
ogiques

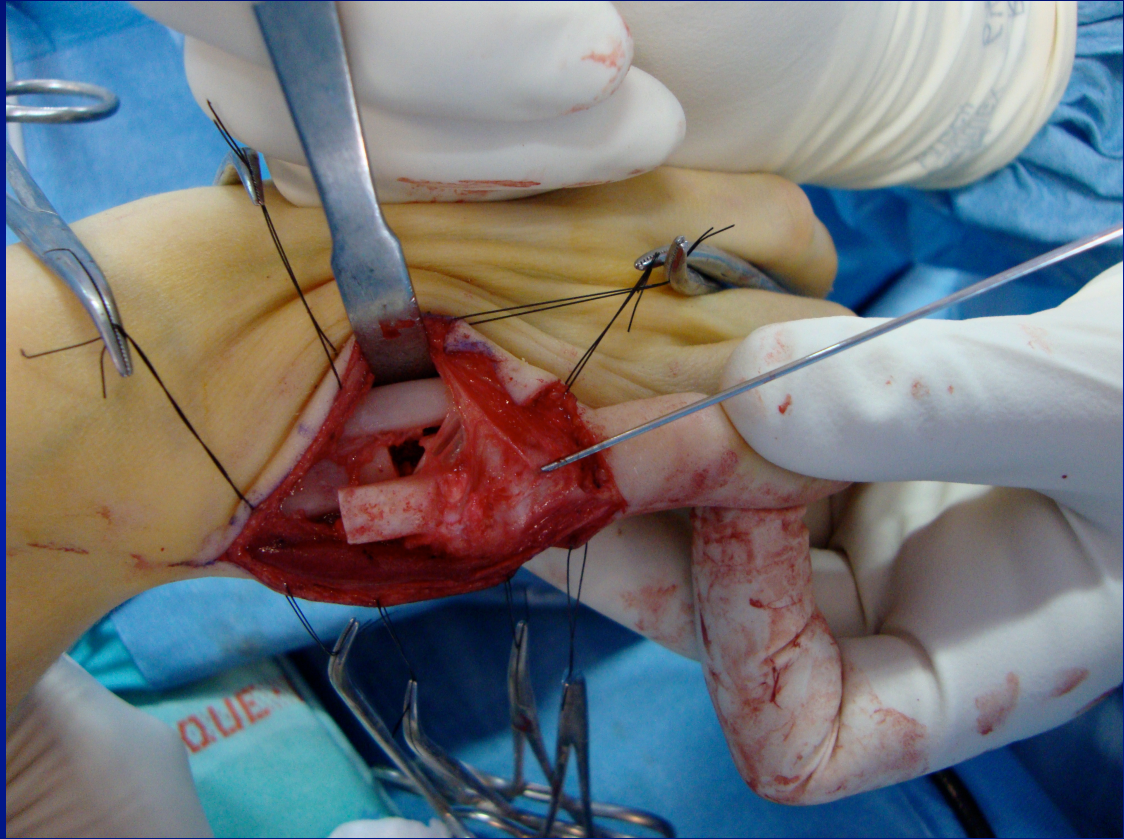


# MALFORMATIONS DE LA MAIN

## 2° - TROUBLES DE LA SEPARATION ET DE LA DIFFERENCIATION

- **SYNOSTOSES**
- LUXATION TETE RADIALE
- SYNDACTYLIE
- ARTHROGRYPOSE...







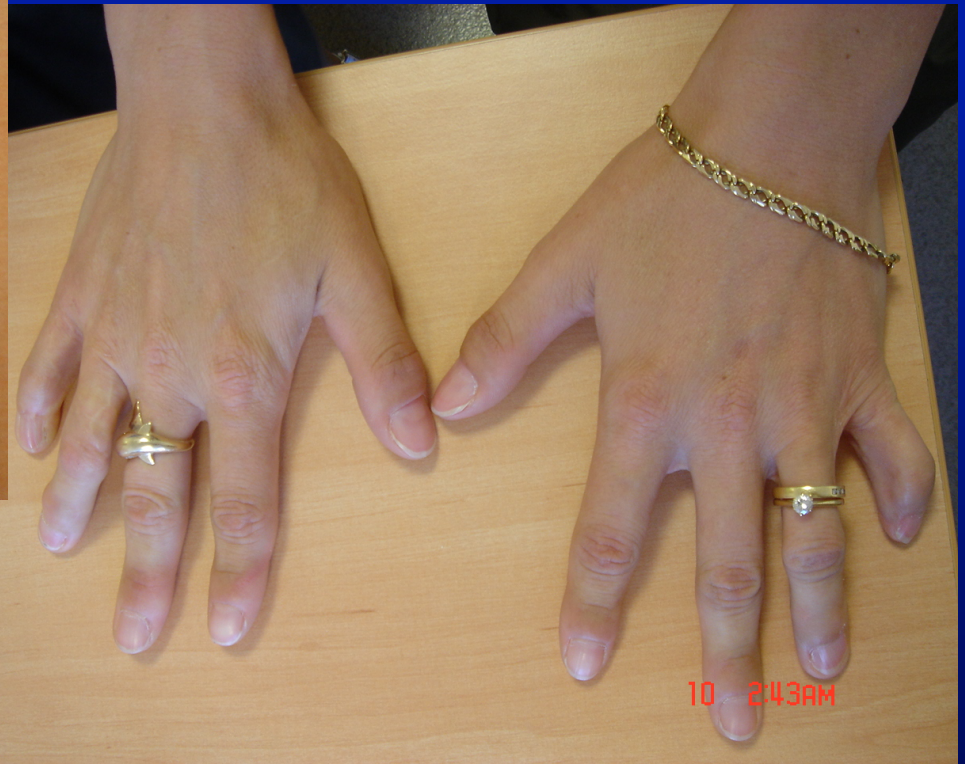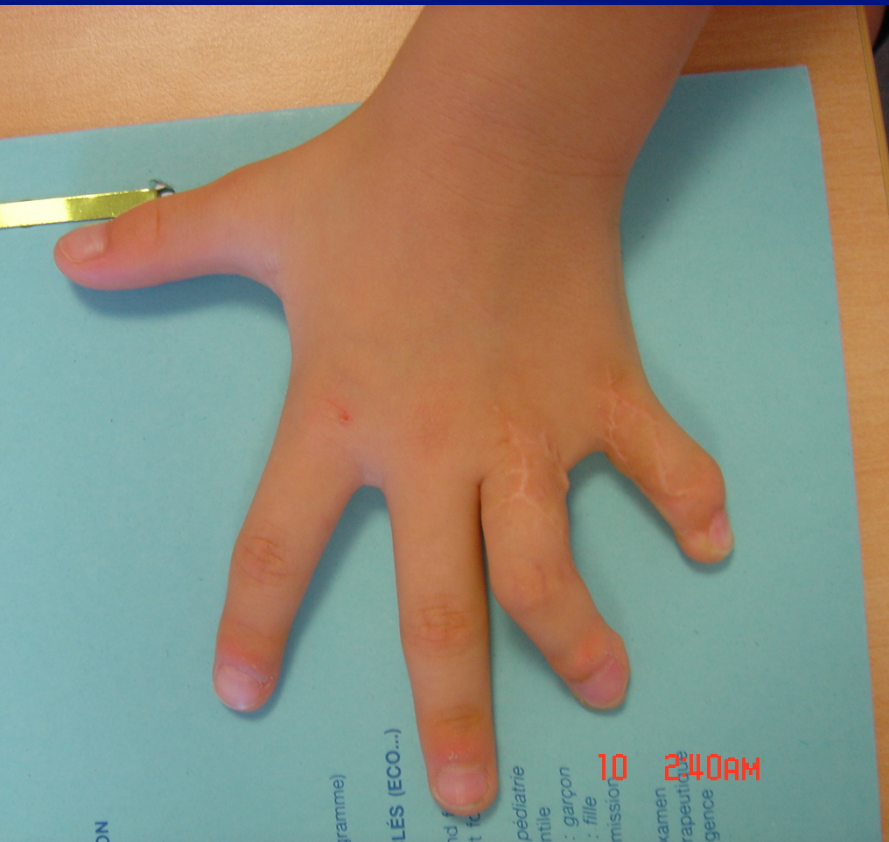
# MALFORMATIONS DE LA MAIN

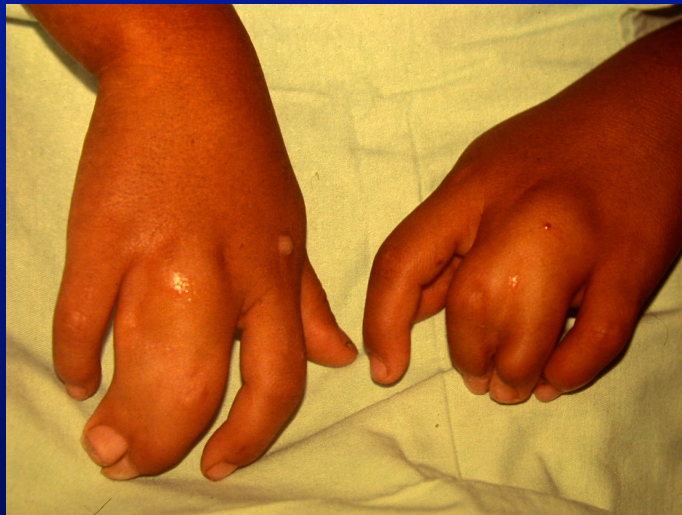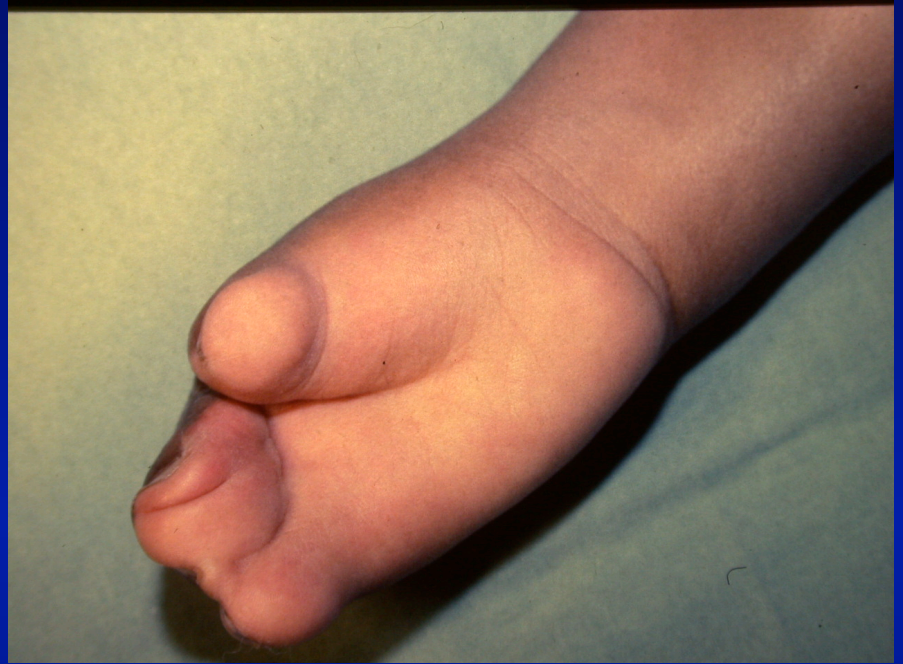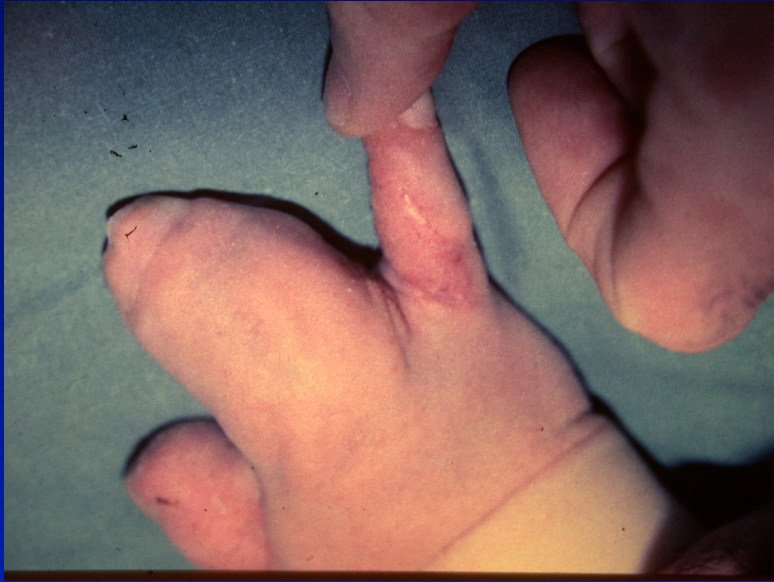## 2° - TROUBLES DE LA SEPARATION ET DE LA DIFFERENCIATION:

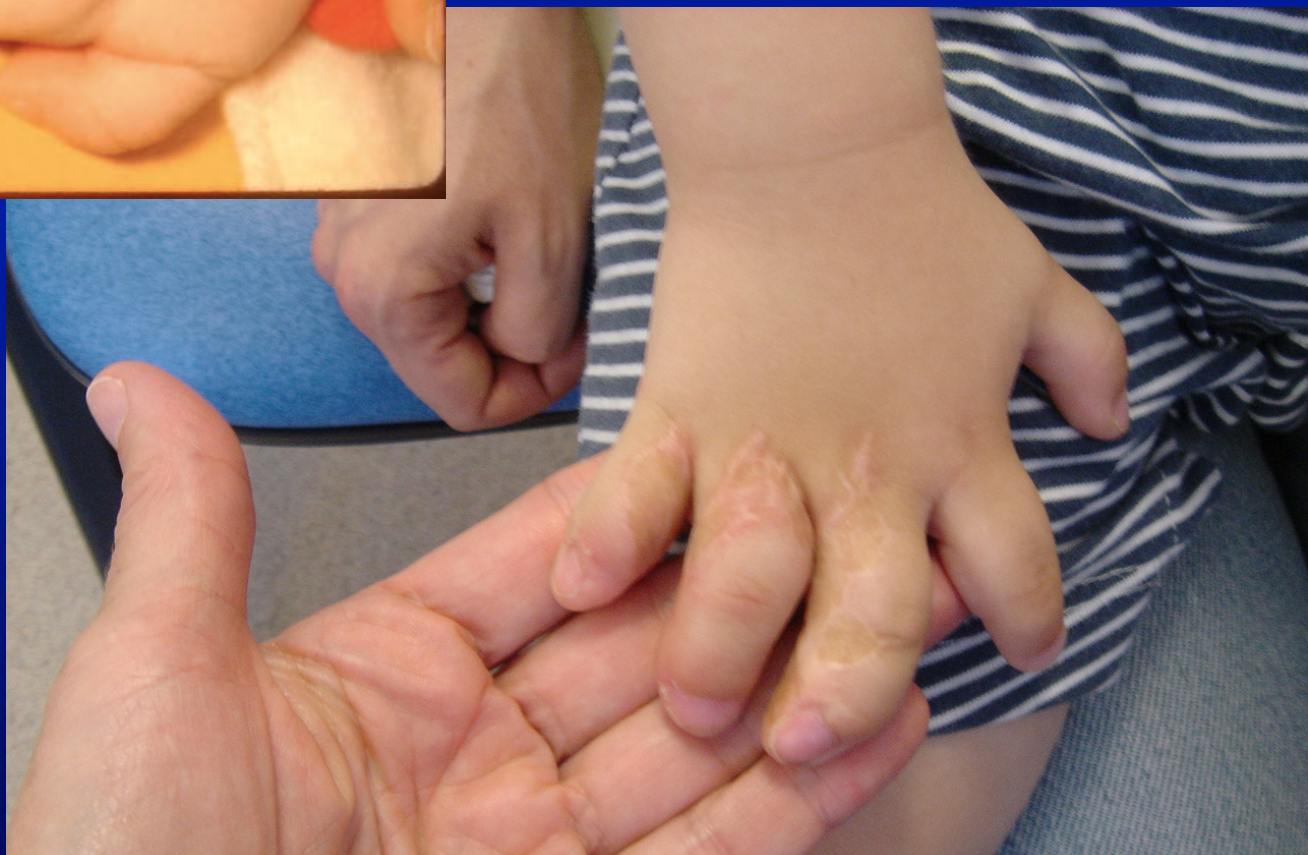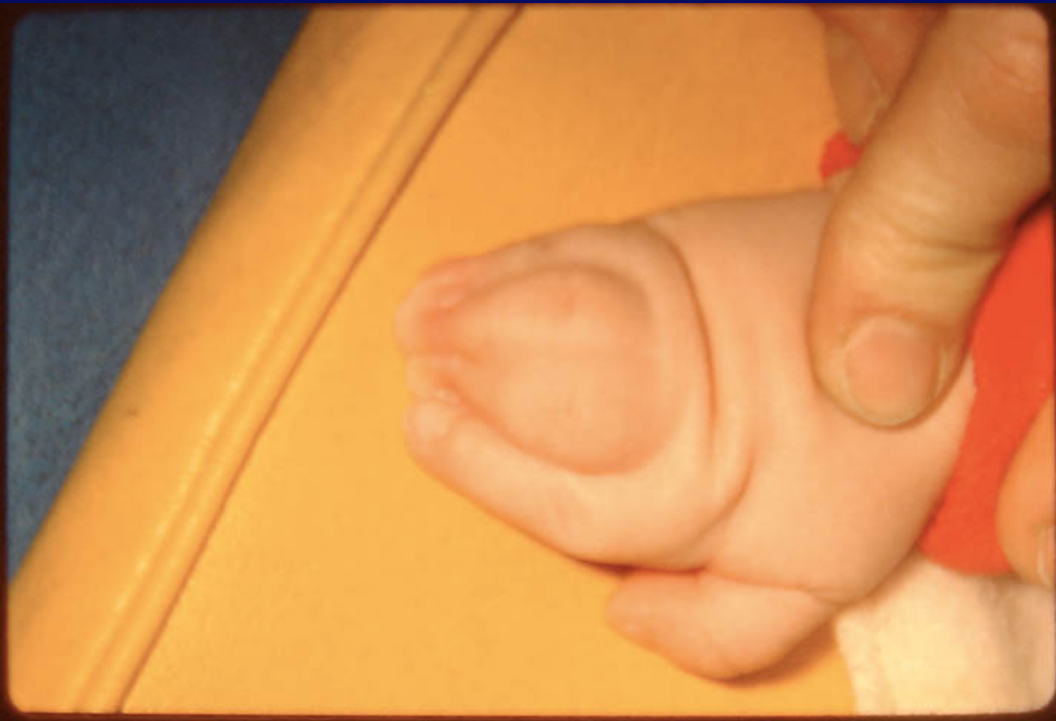- SYNOSTOSES
- LUXATION TETE RADIALE
- SYNDACTYLIE
- ARTHROGRYPOSE...

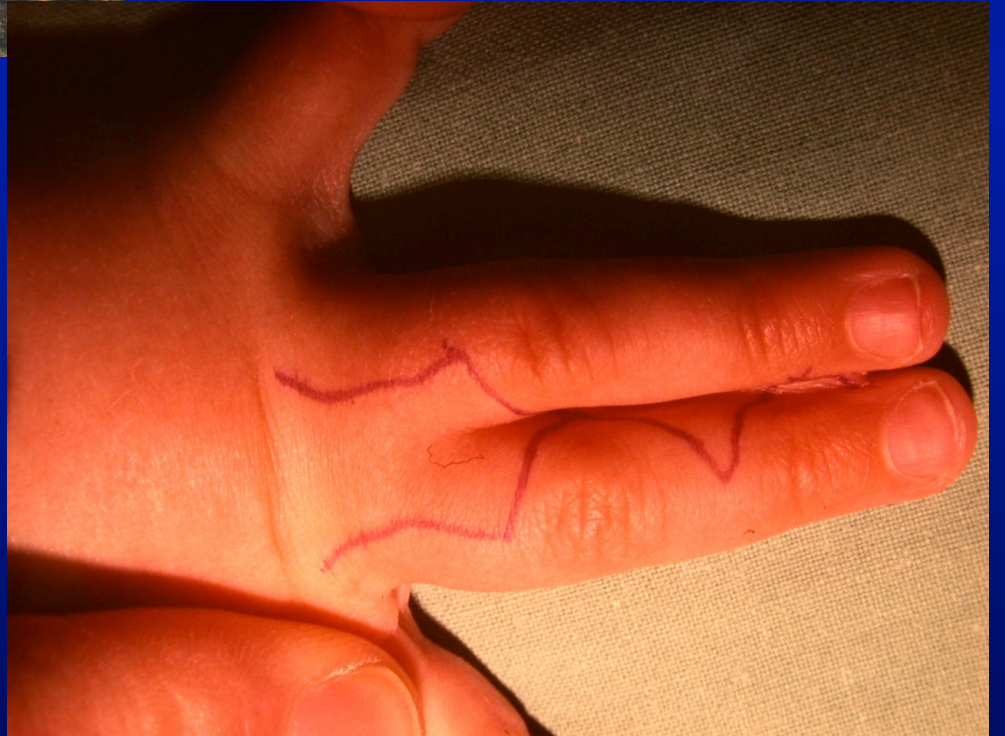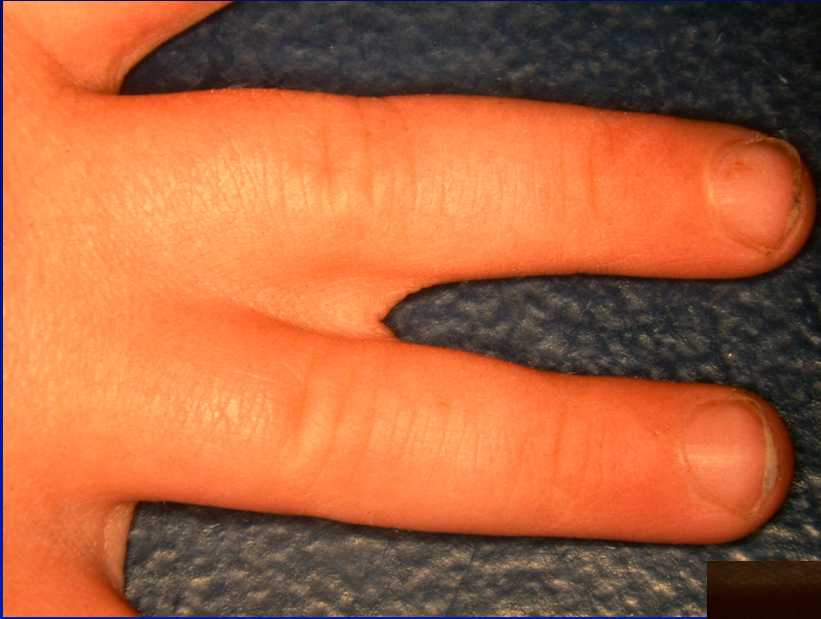# CARACTERE FAMILIAL

SOUVENT ASSOCIE POLYDACTYLIE

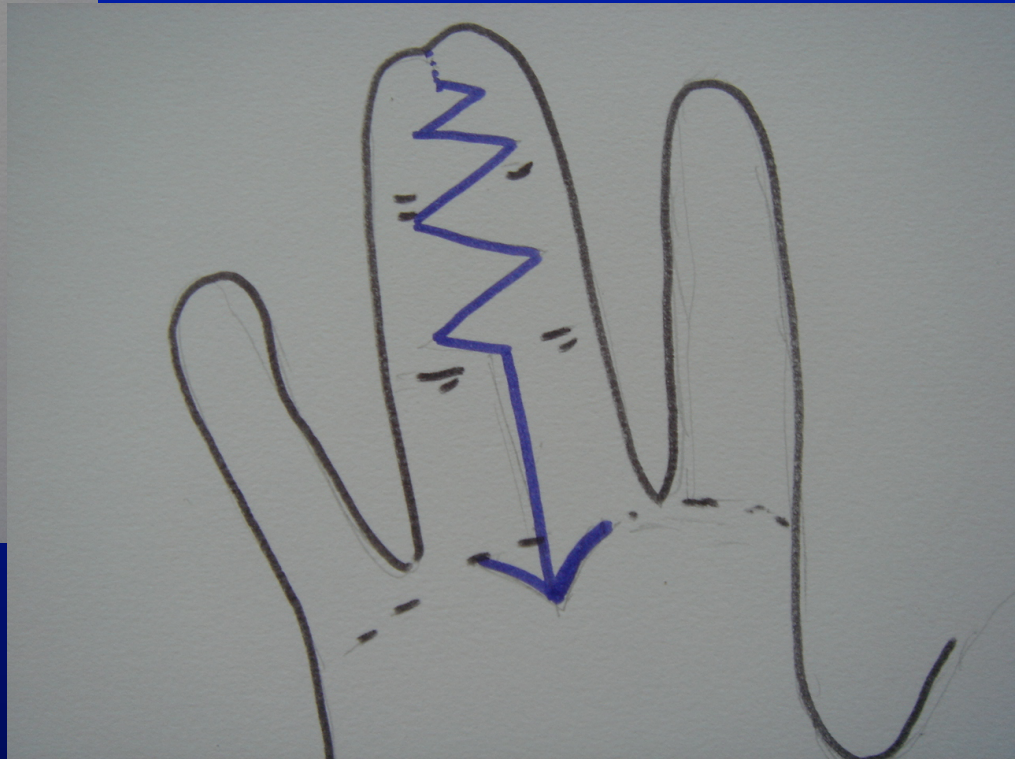
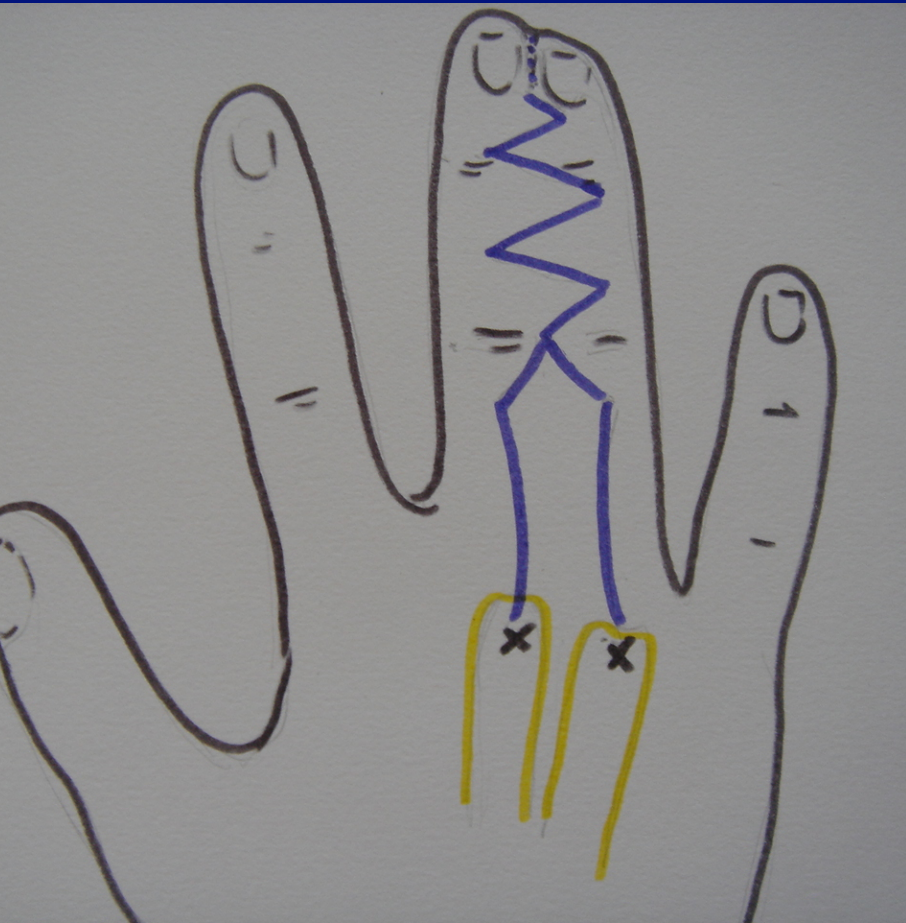


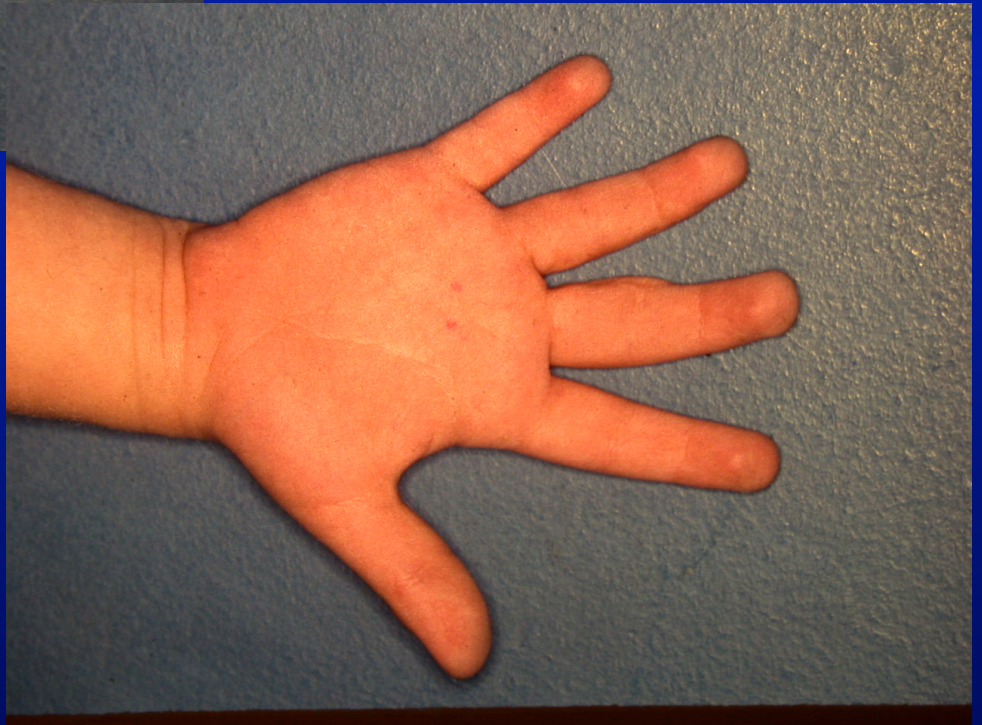
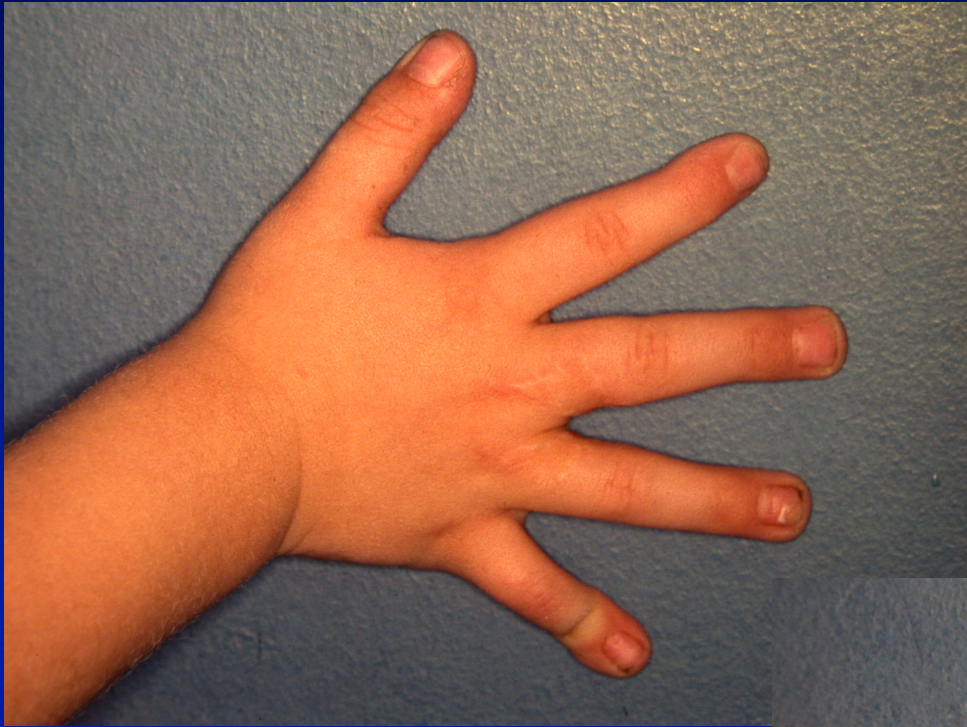



# TEMPS IMPORTANT DESSIN DES INCISIONS





# **MALFORMATIONS DU MEMBRE SUPERIEUR**

**2° - TROUBLES DE LA SEPARATION  
ET DE LA DIFFERENCIATION:**

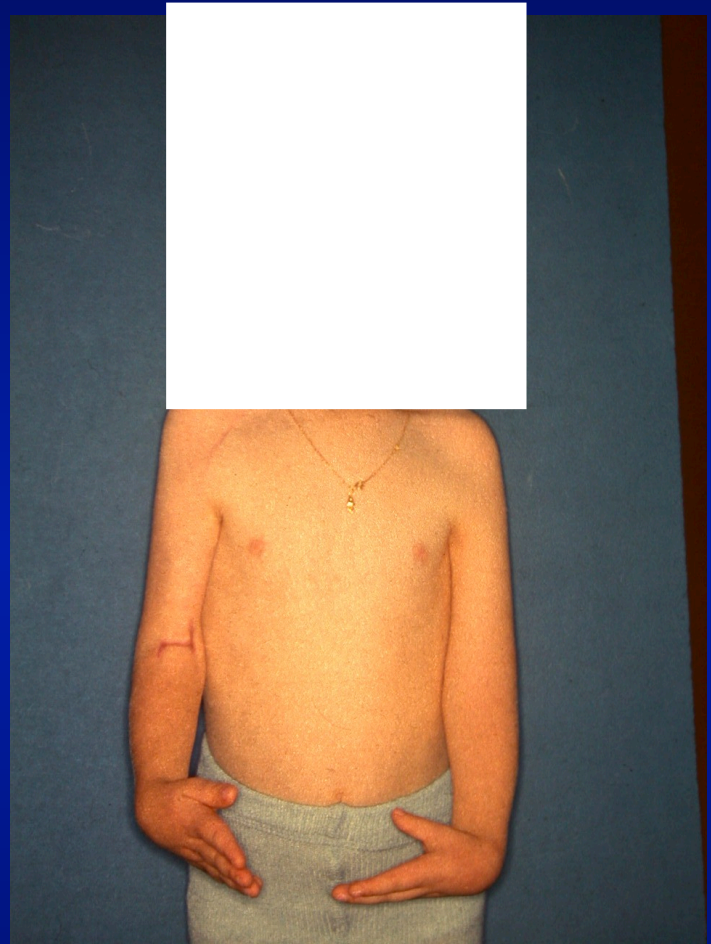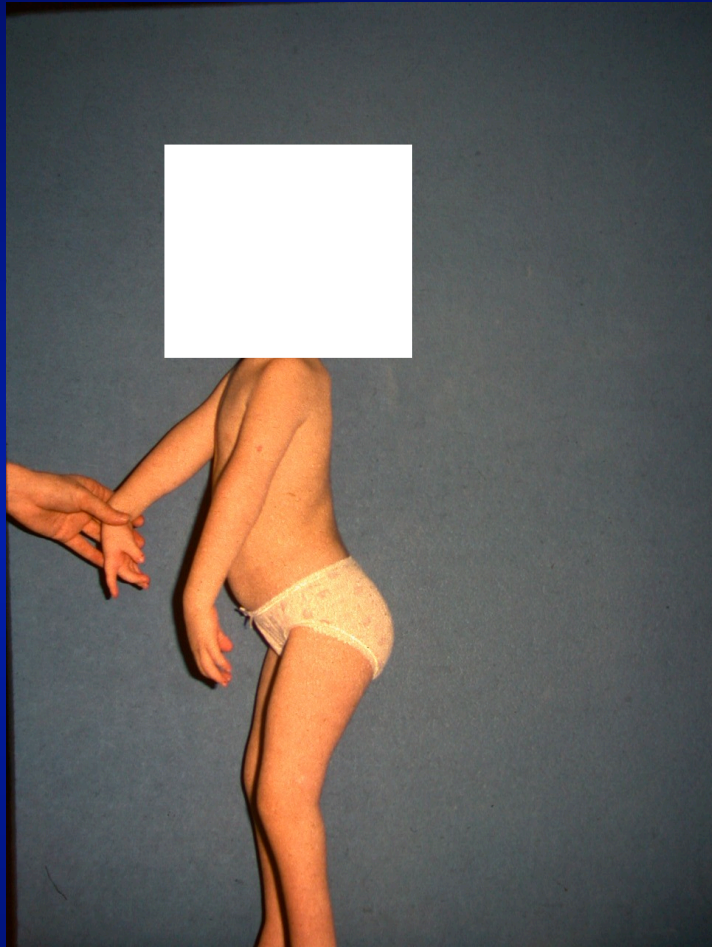**SYNOSTOSES**

**LUXATION TETE RADIALE**

**SYNDACTYLIE**

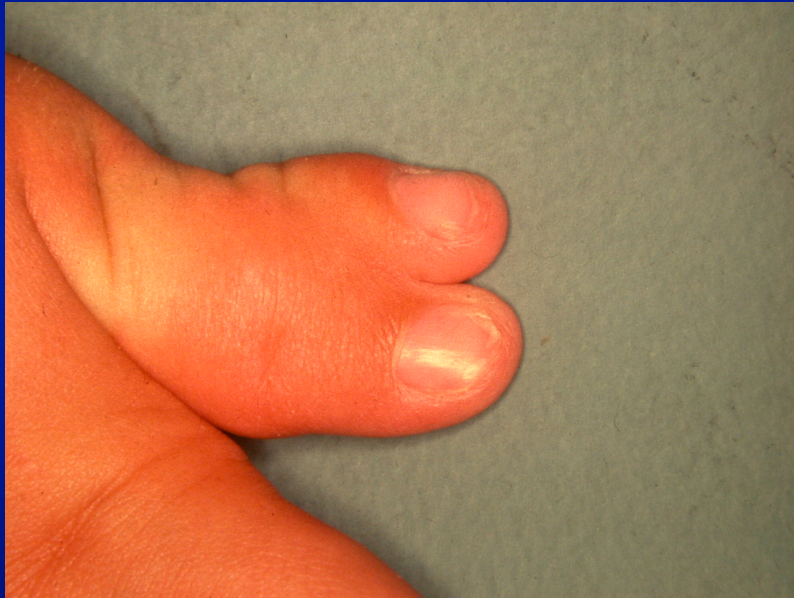**✓ ARTHROGRYPOSE...**



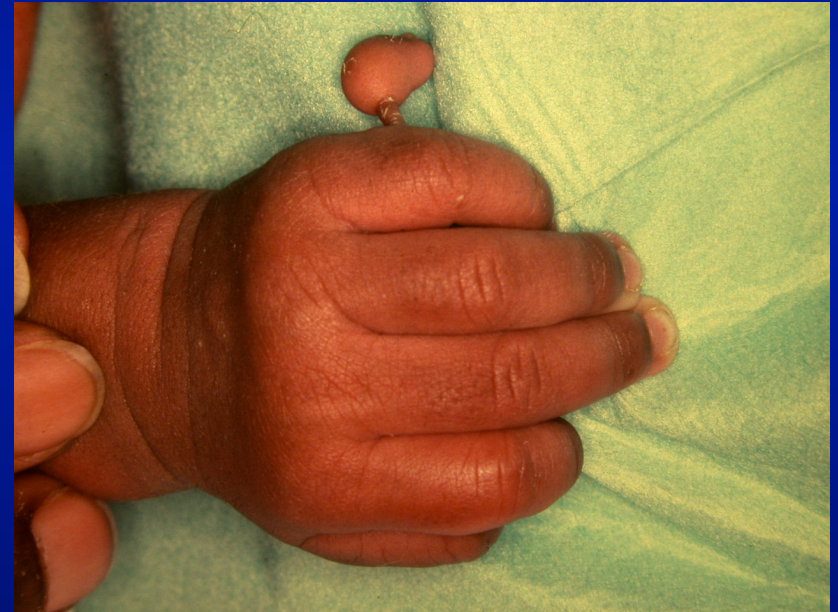

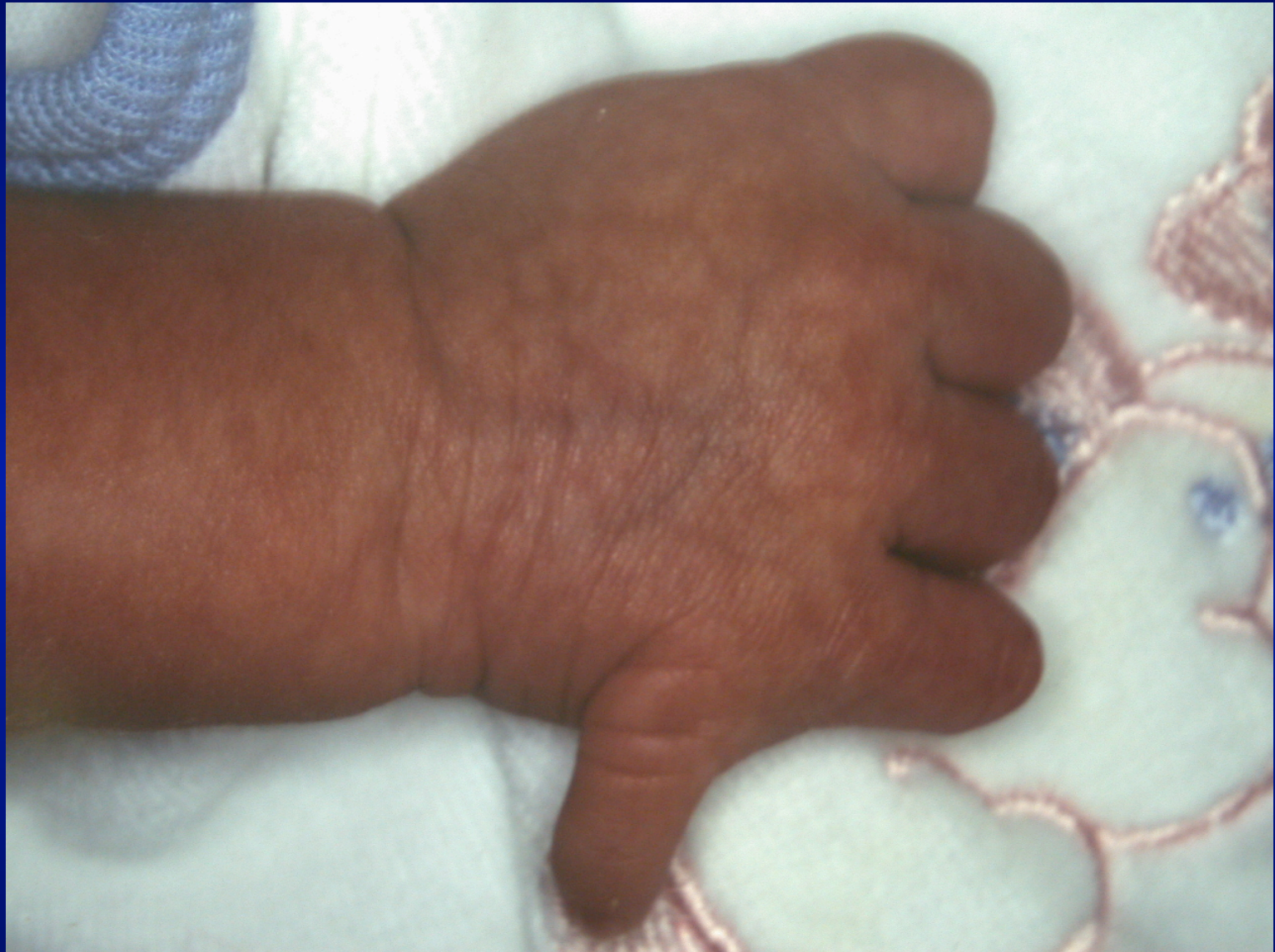# 3° DUPLICATION

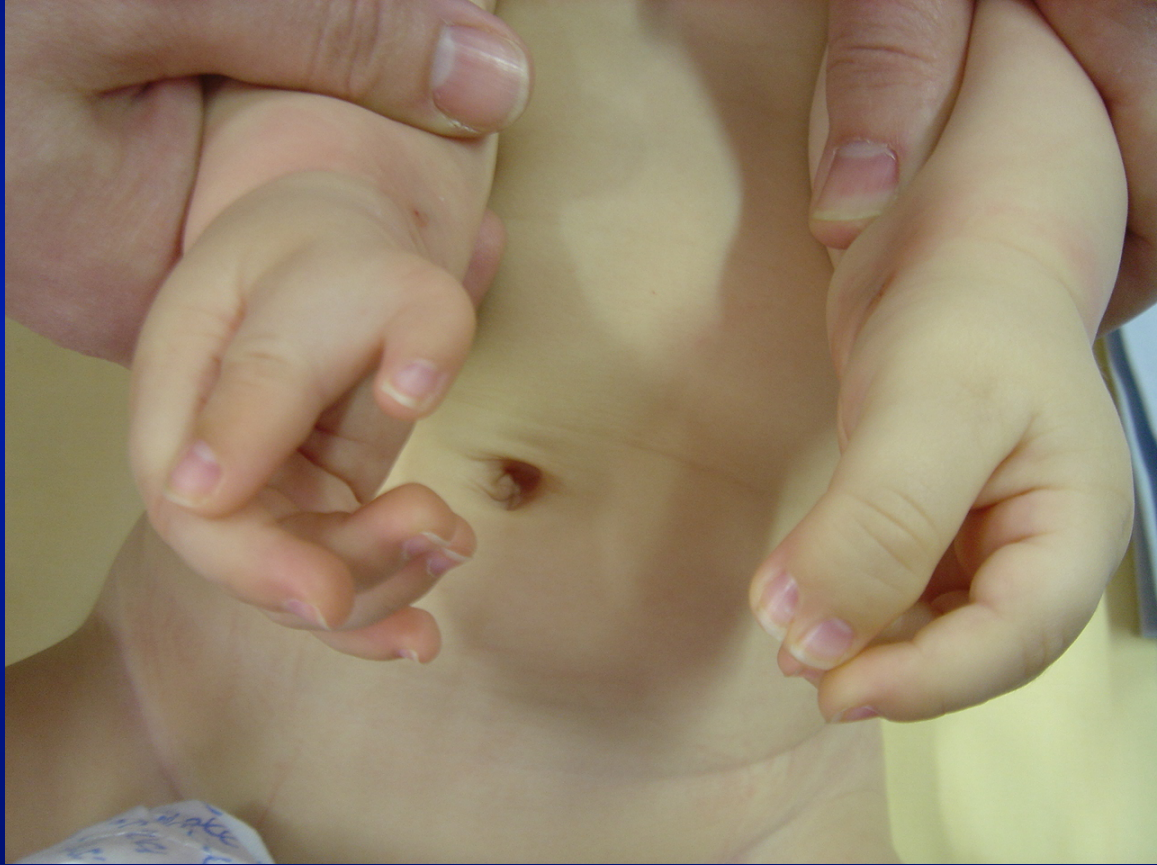**PREAXIALE**



**POSTAXIALE**












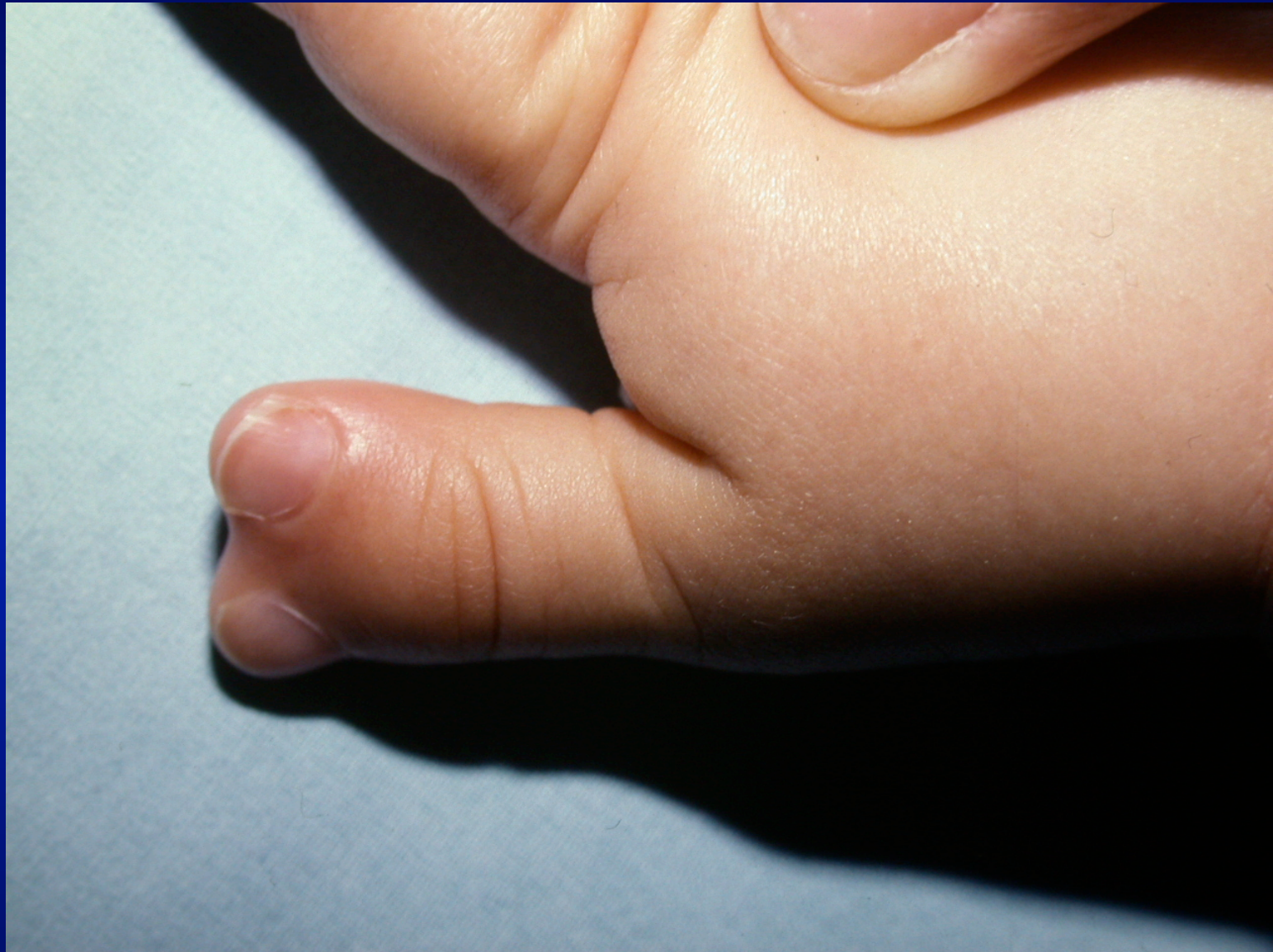

# CLASSIFICATION

DE WASSEL :

IV >> VII > II

Type I	
Type II	
Type III	
Type IV	
Type V	
Type VI	
Type VII	

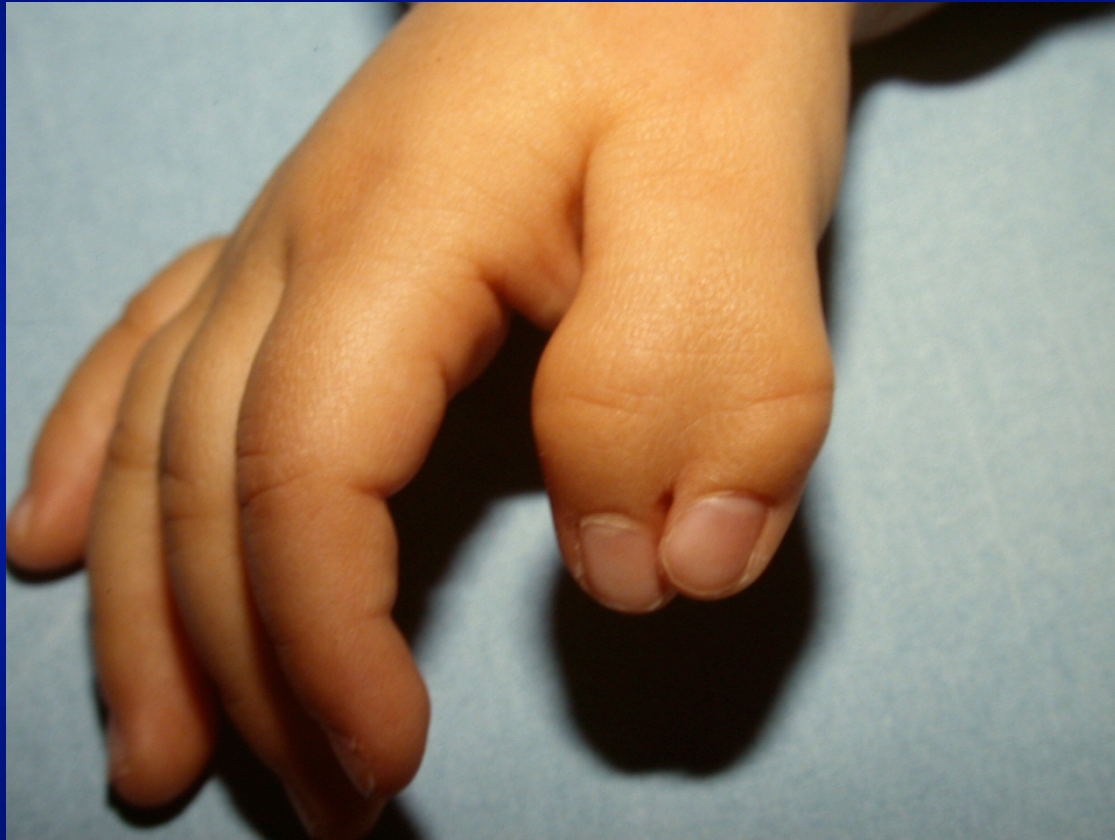



# **TRAITEMENT CHIRURGICAL**

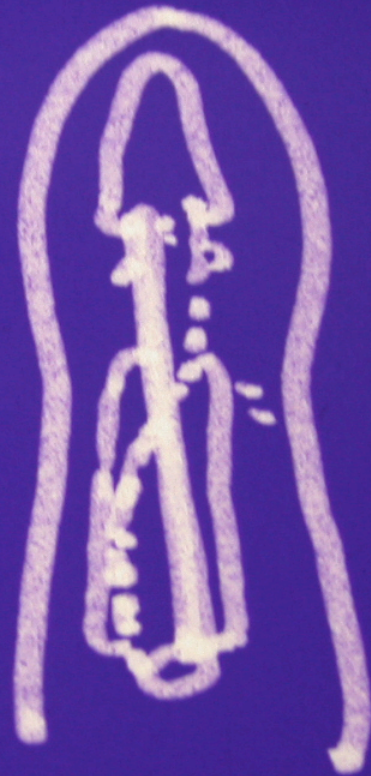
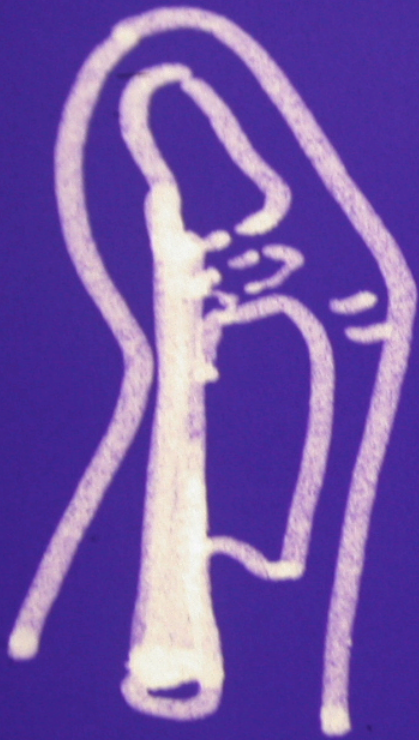
- **FAUSSE FACILITE**
- **VERS 8 - 10 MOIS**





# Anatomie

- **m. extrinsèques :**
  - **En Y à la bifurcation**
  - **Insertion parfois anormale sur P2**




# Anatomie

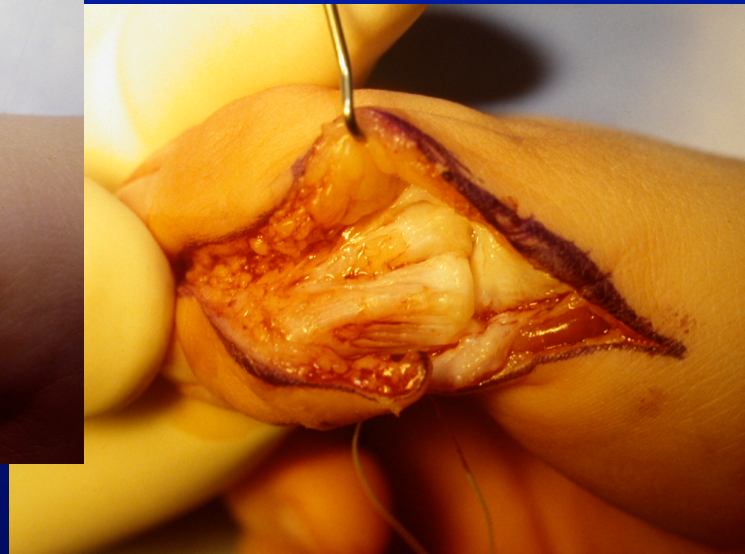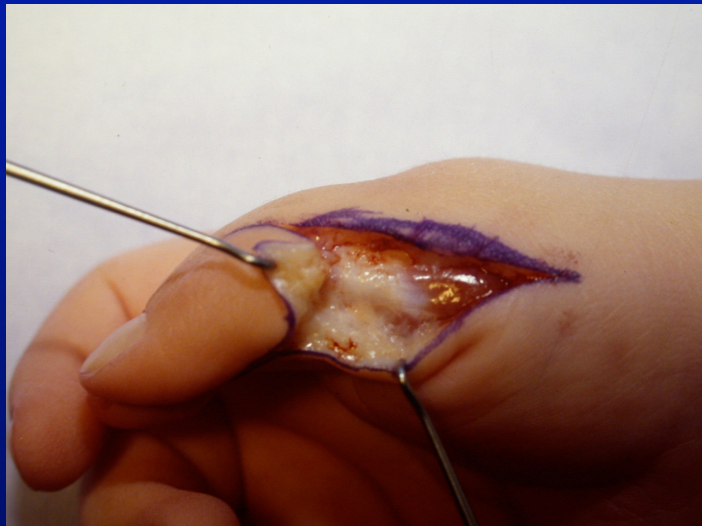
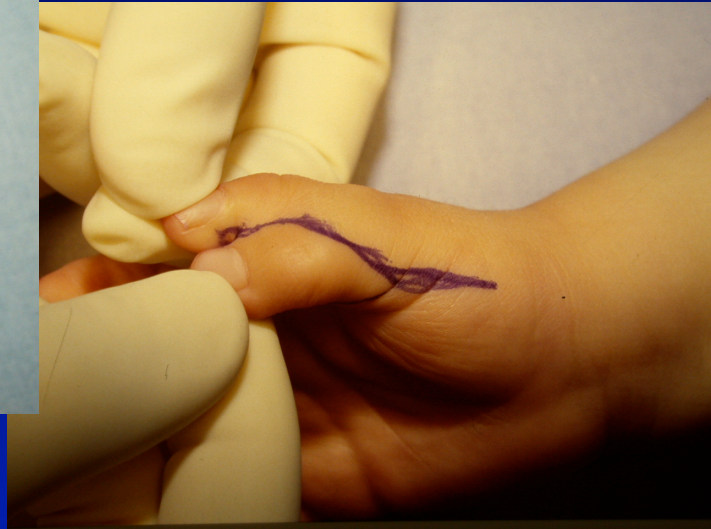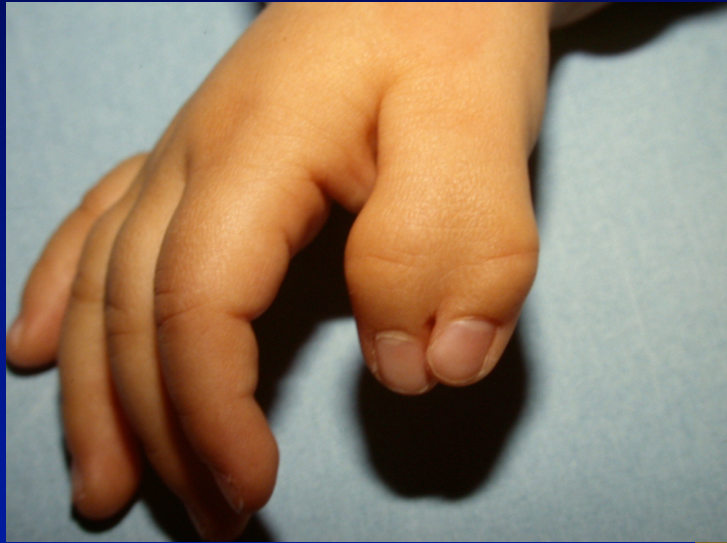- **M. intrinsèques :**
- **M. thénariens externes ---> pouce radial**
- **M. thénariens internes ---> pouce cubital**

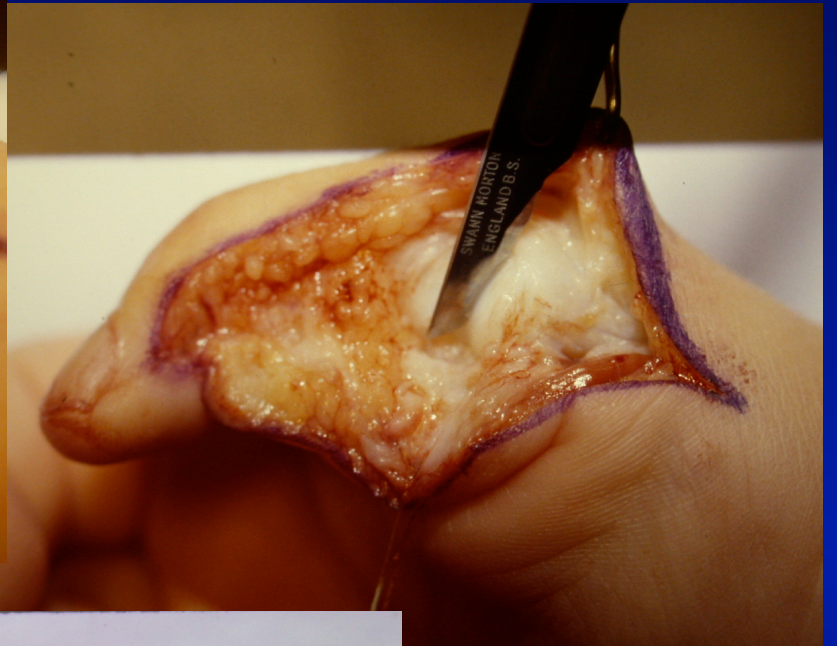
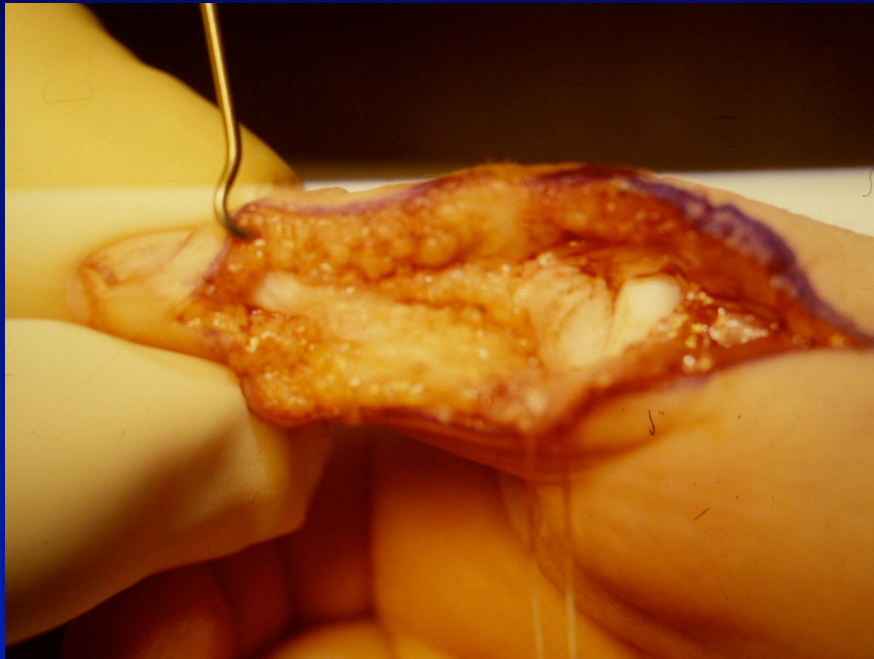
# Traitement chirurgical

## Type IV : le plus difficile

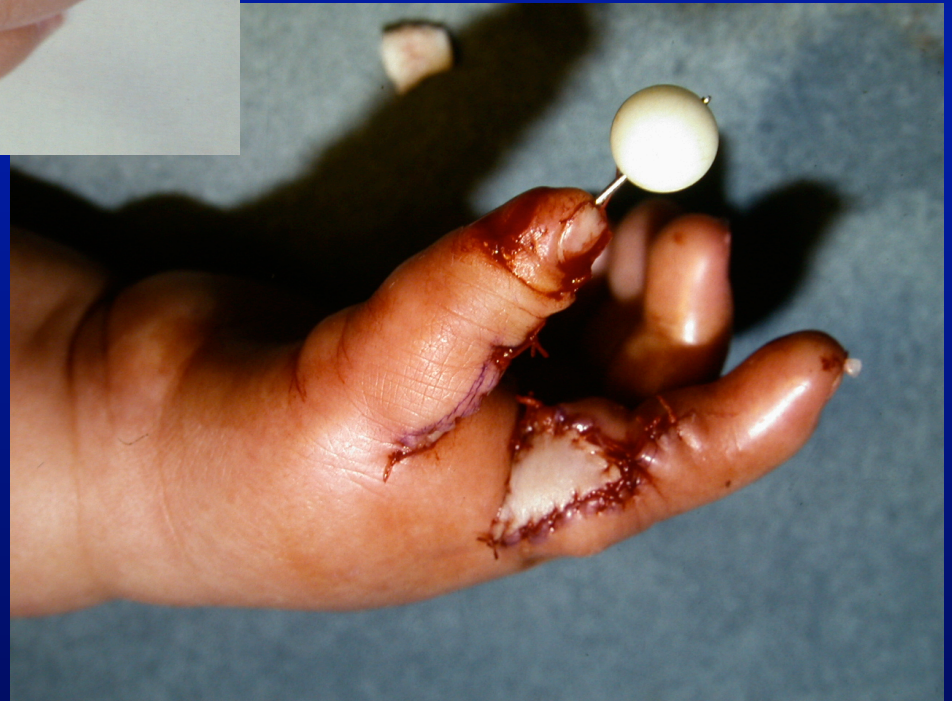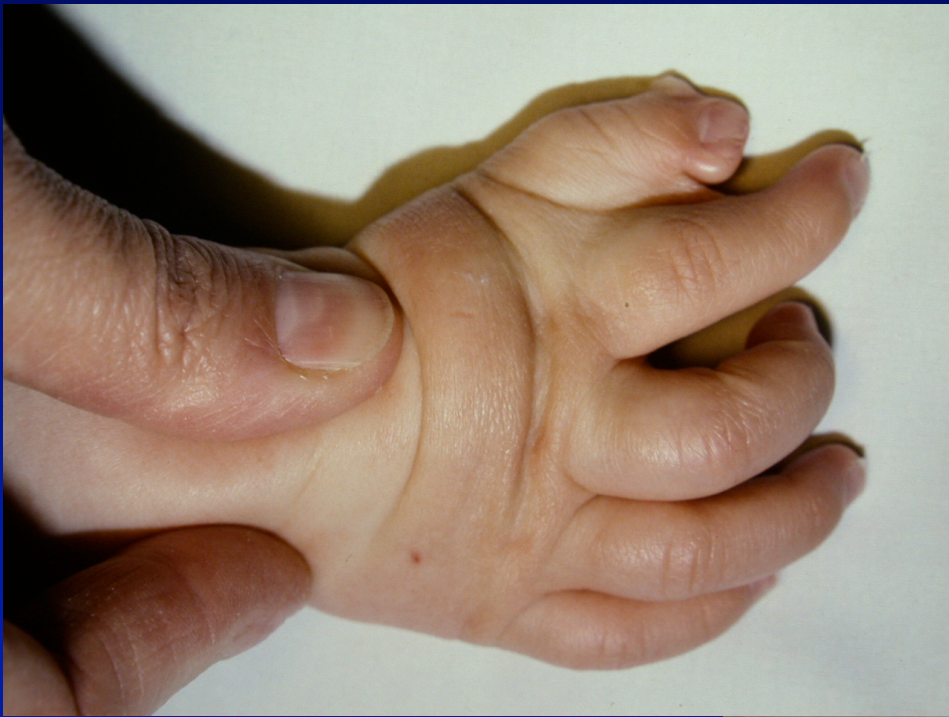- Garder pouce cubital
- Réinsertion soigneuse m. thénariens
- Résection hémi-facette articulaire de M1
- Ostéotomie sous-capitale de M1
- Réinsertion tendon fléchisseur

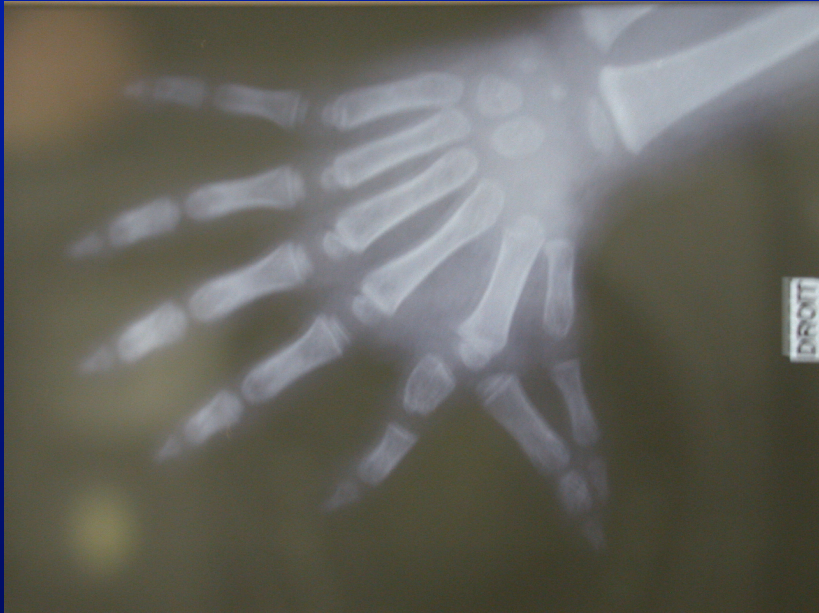
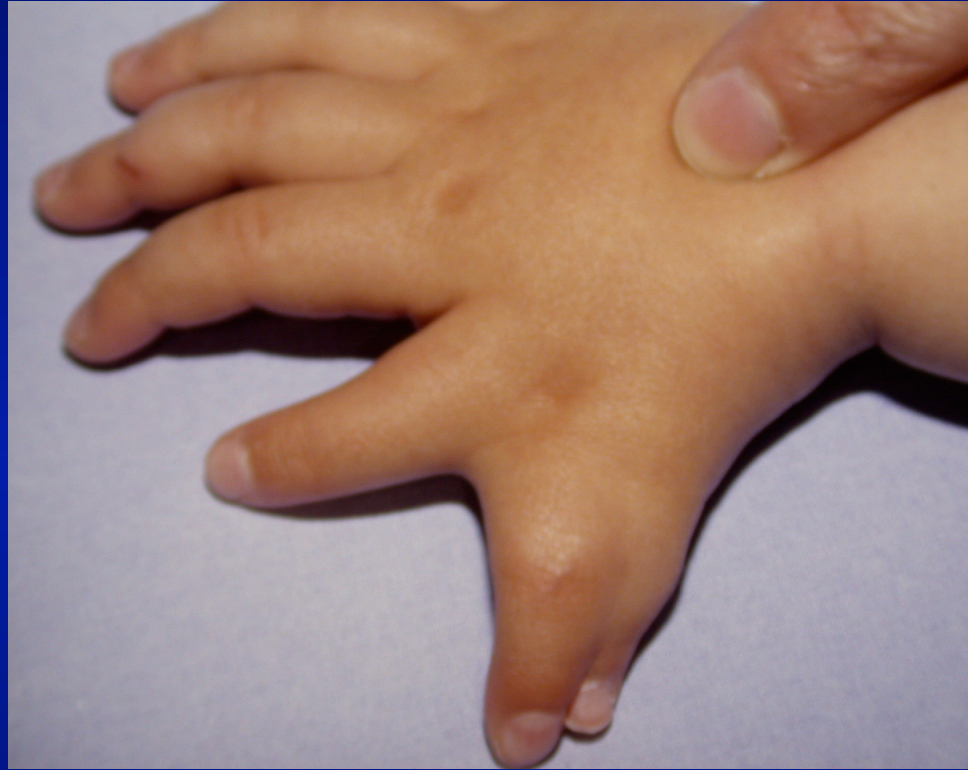
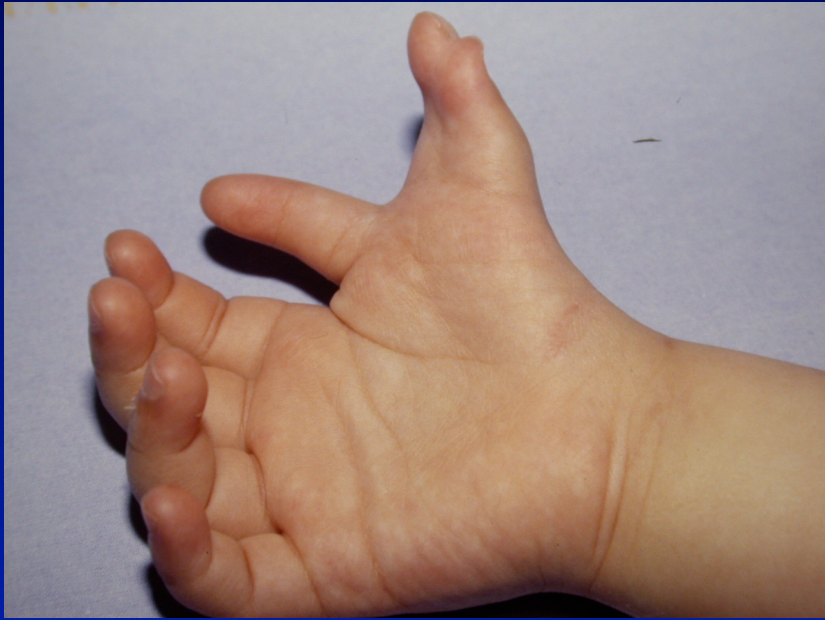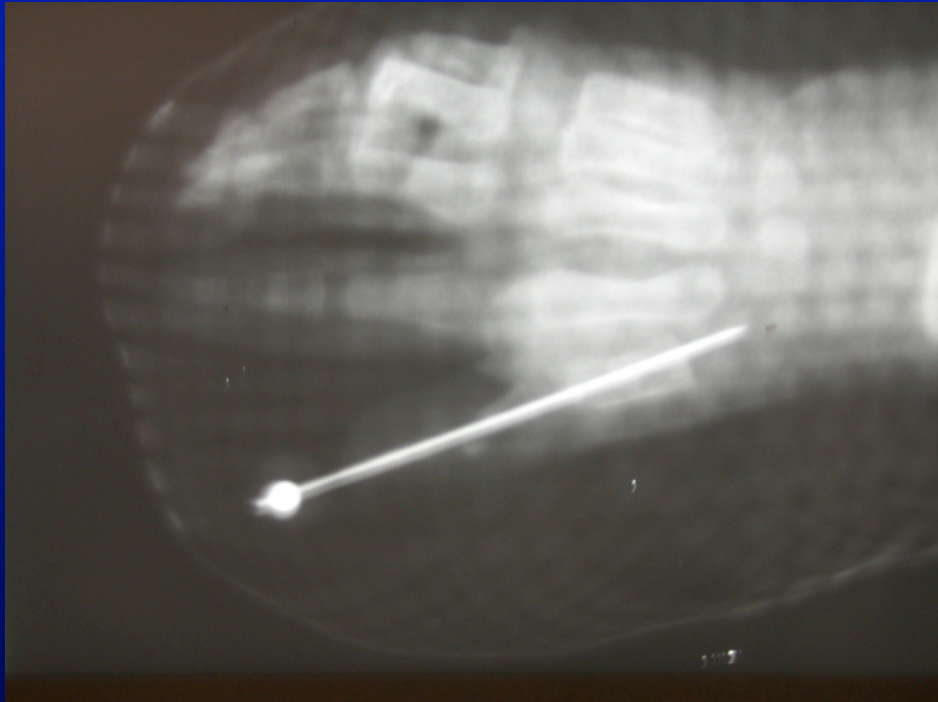


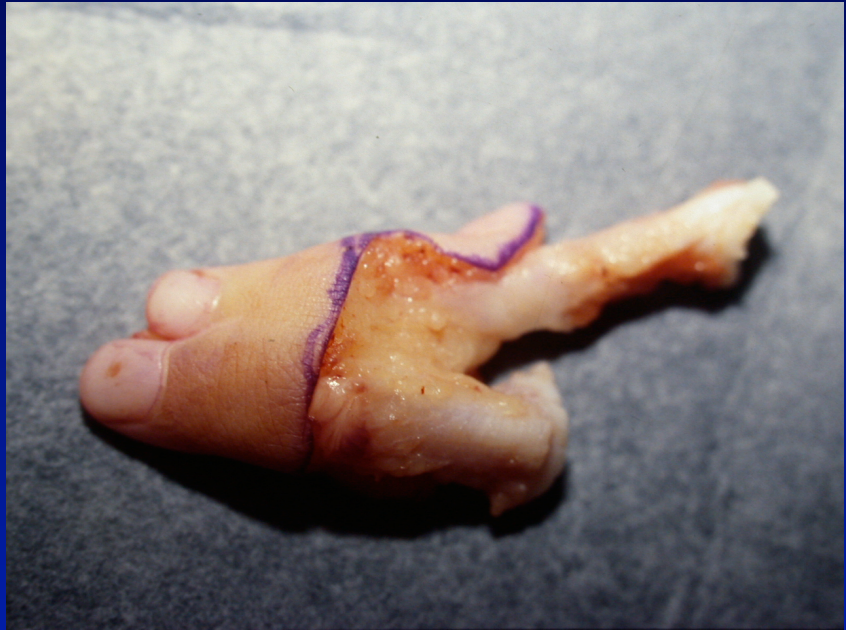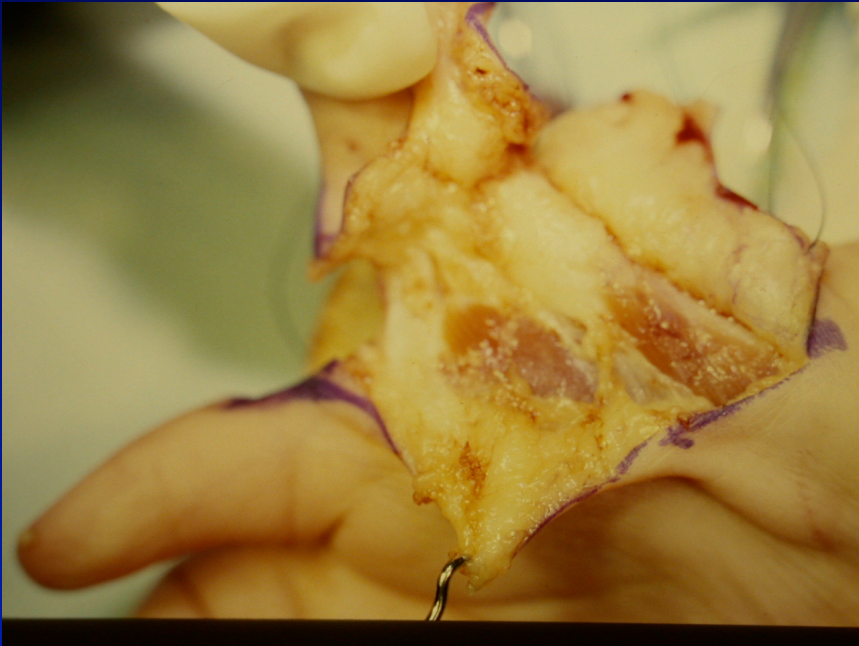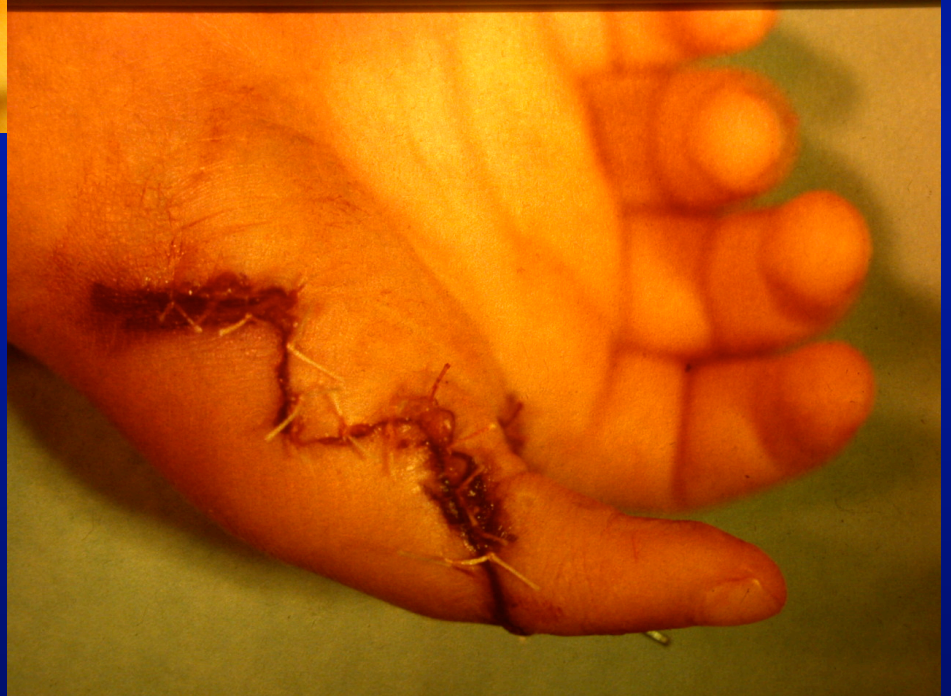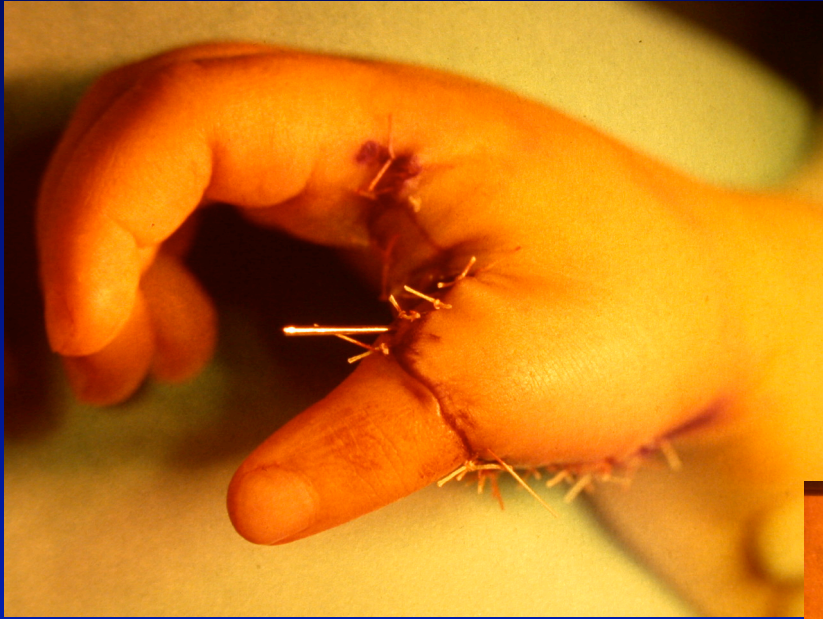


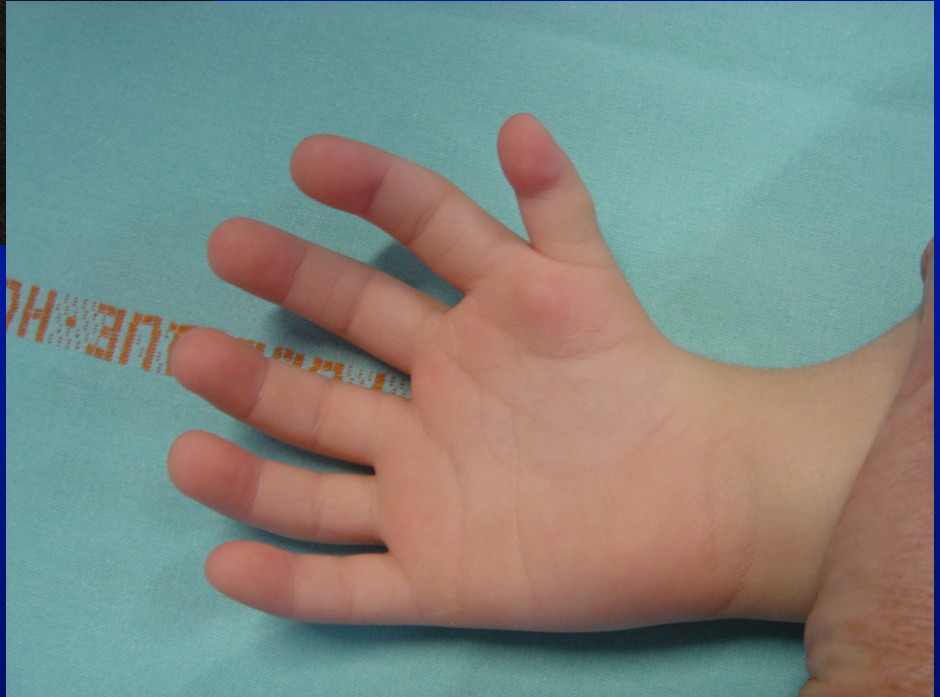




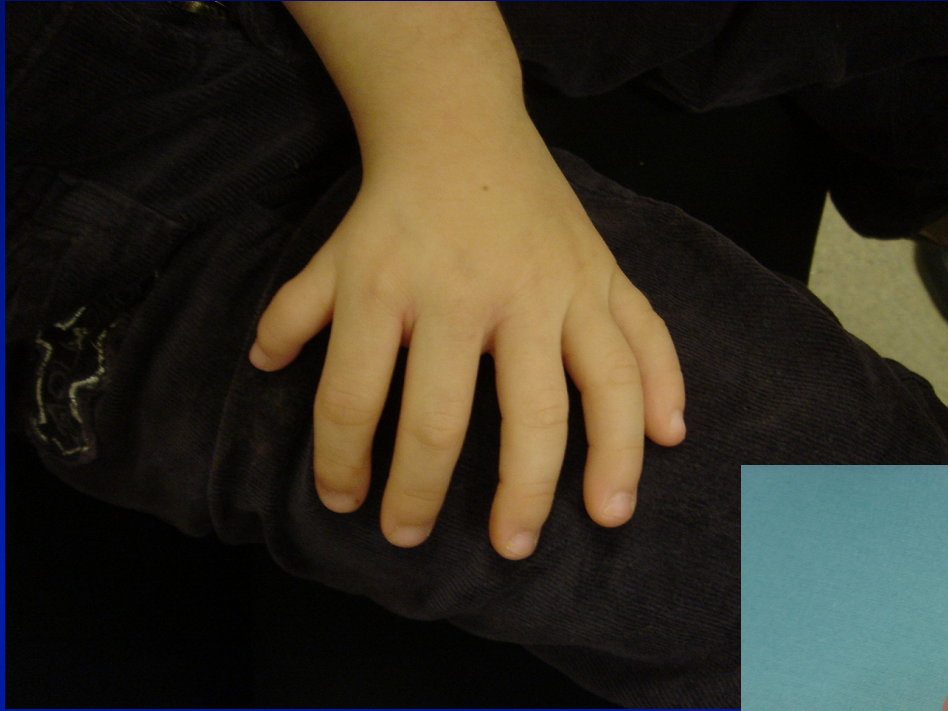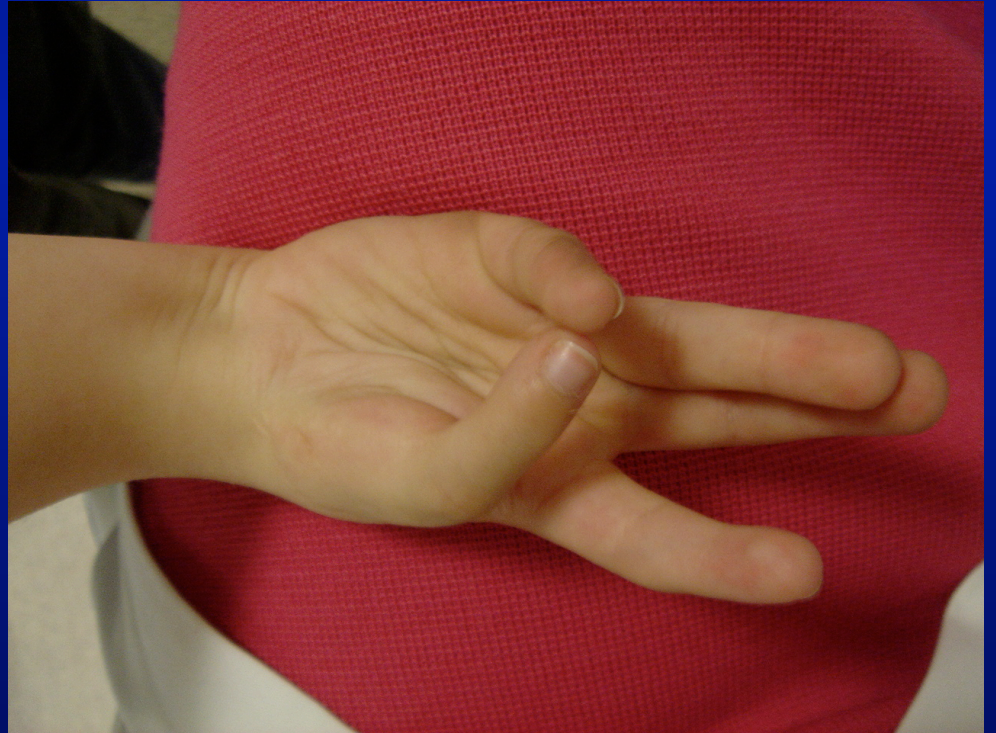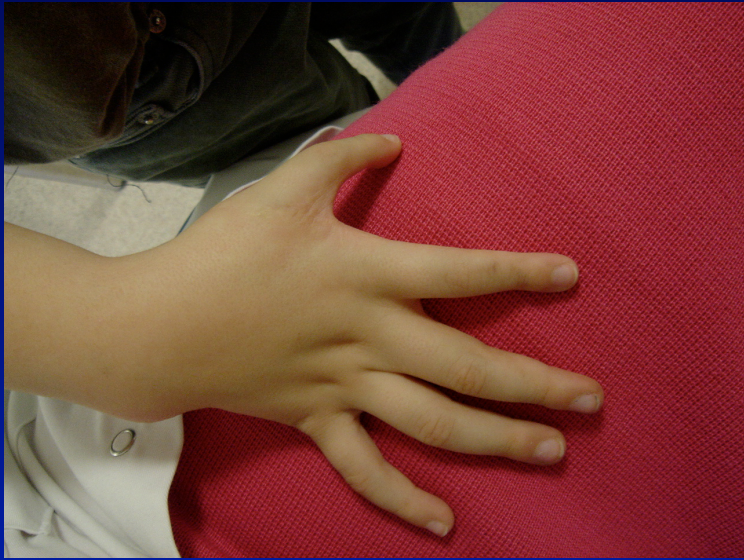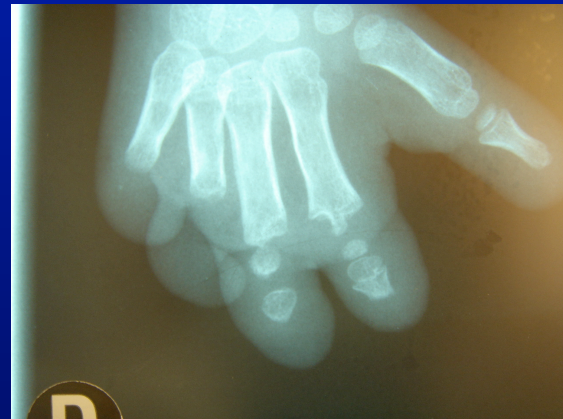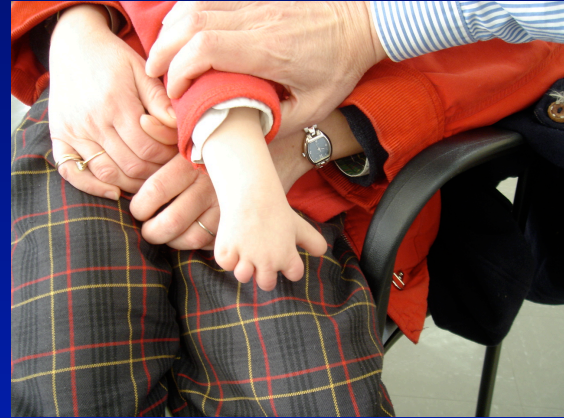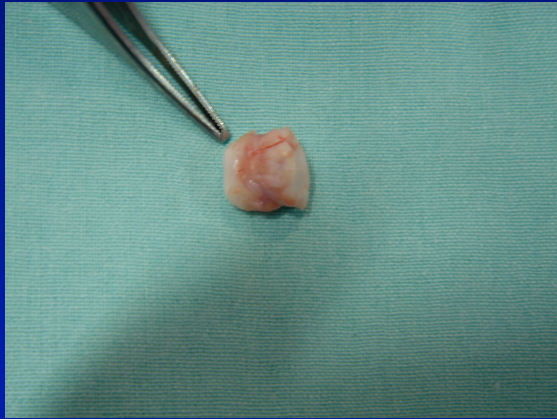








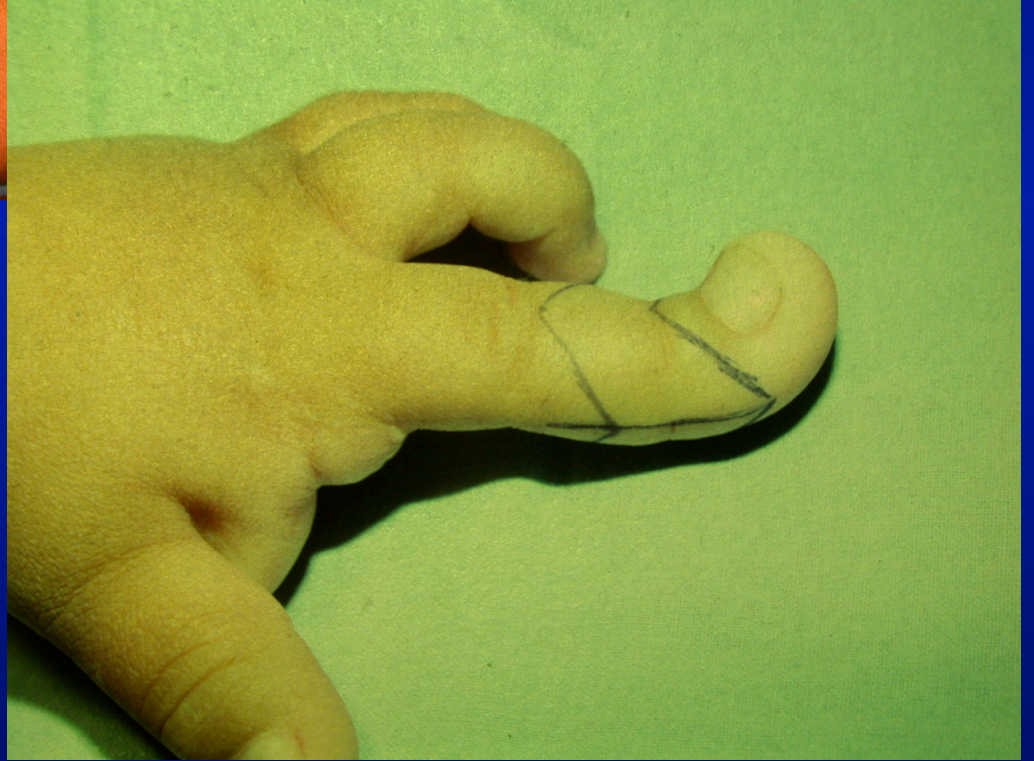




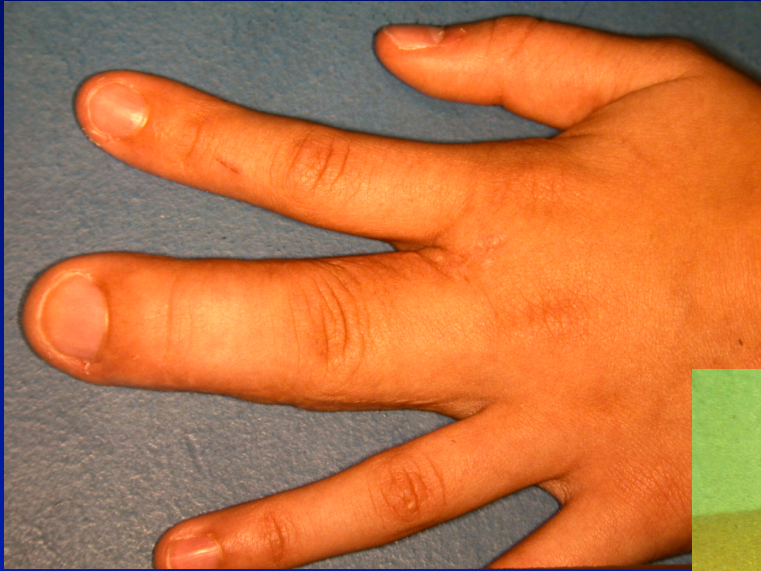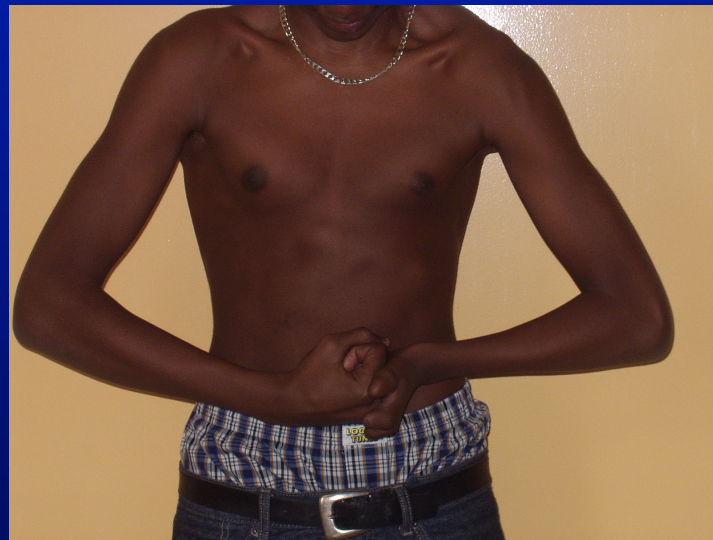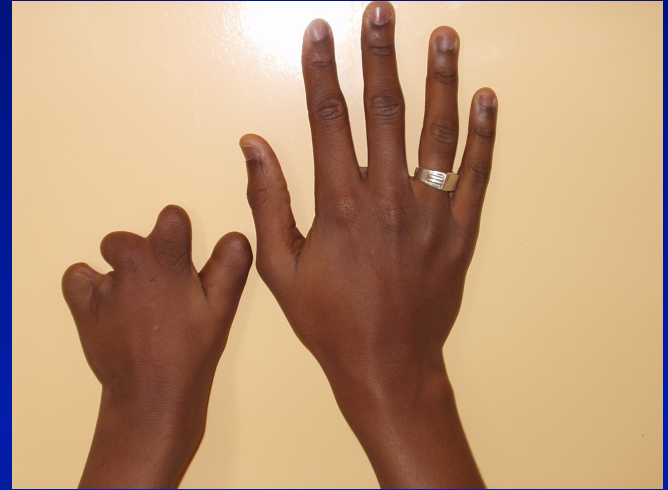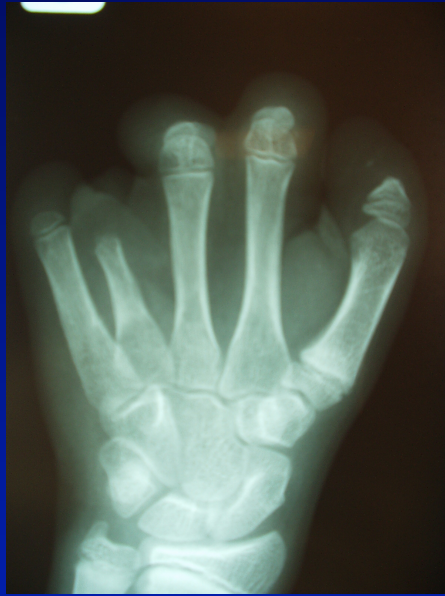**- SUR - DEVELOPPEMENT**

**- SOUS - DEVELOPPEMENT**

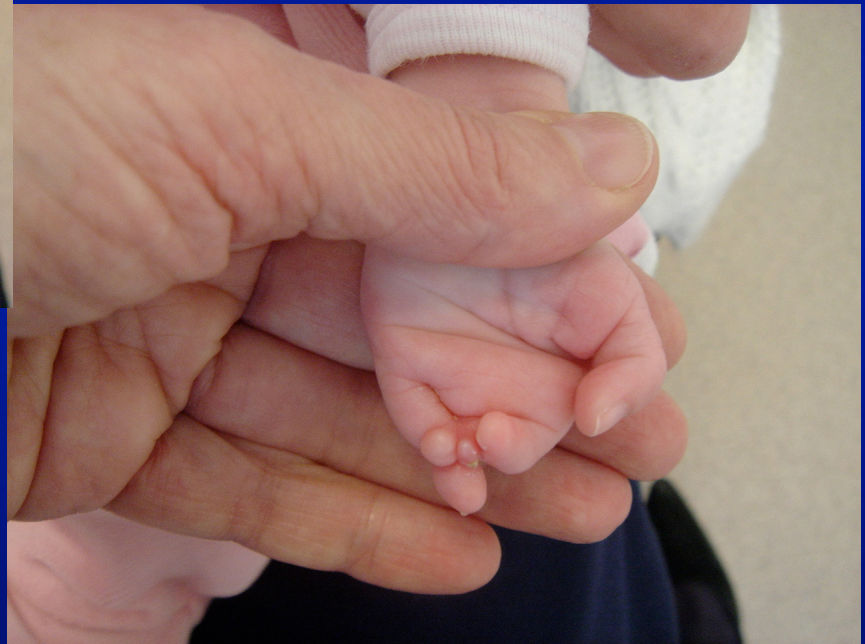
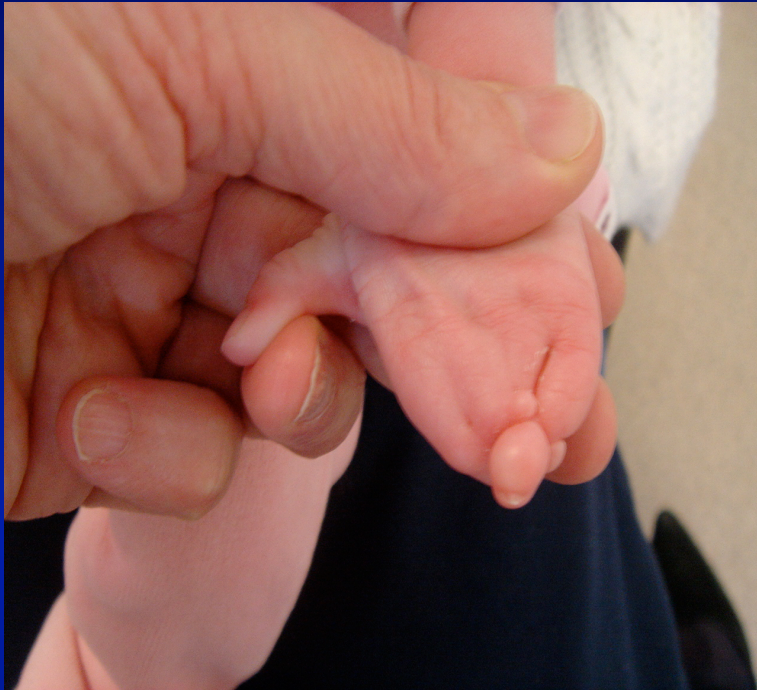


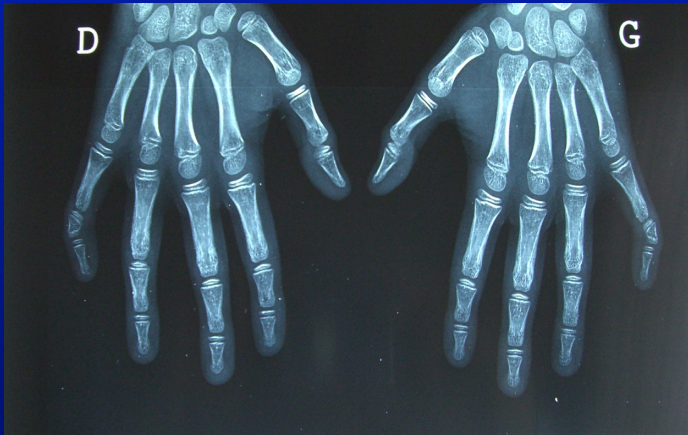
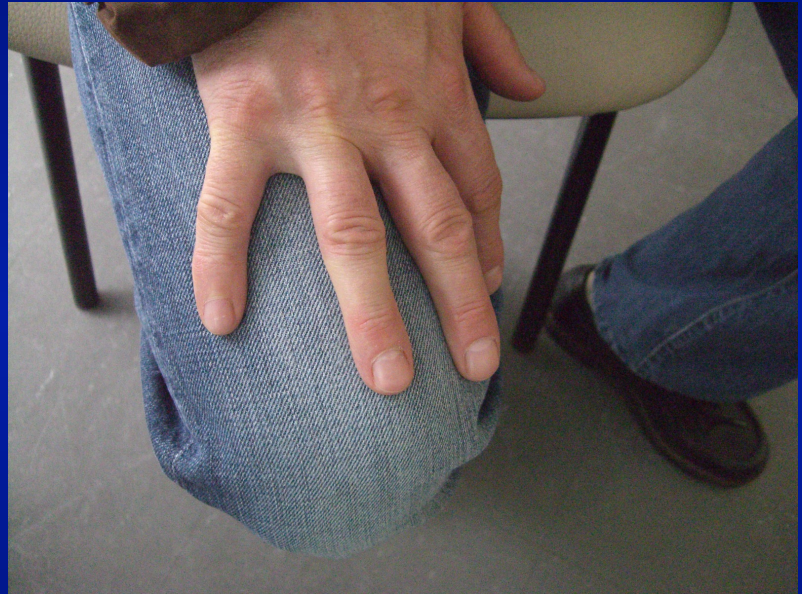
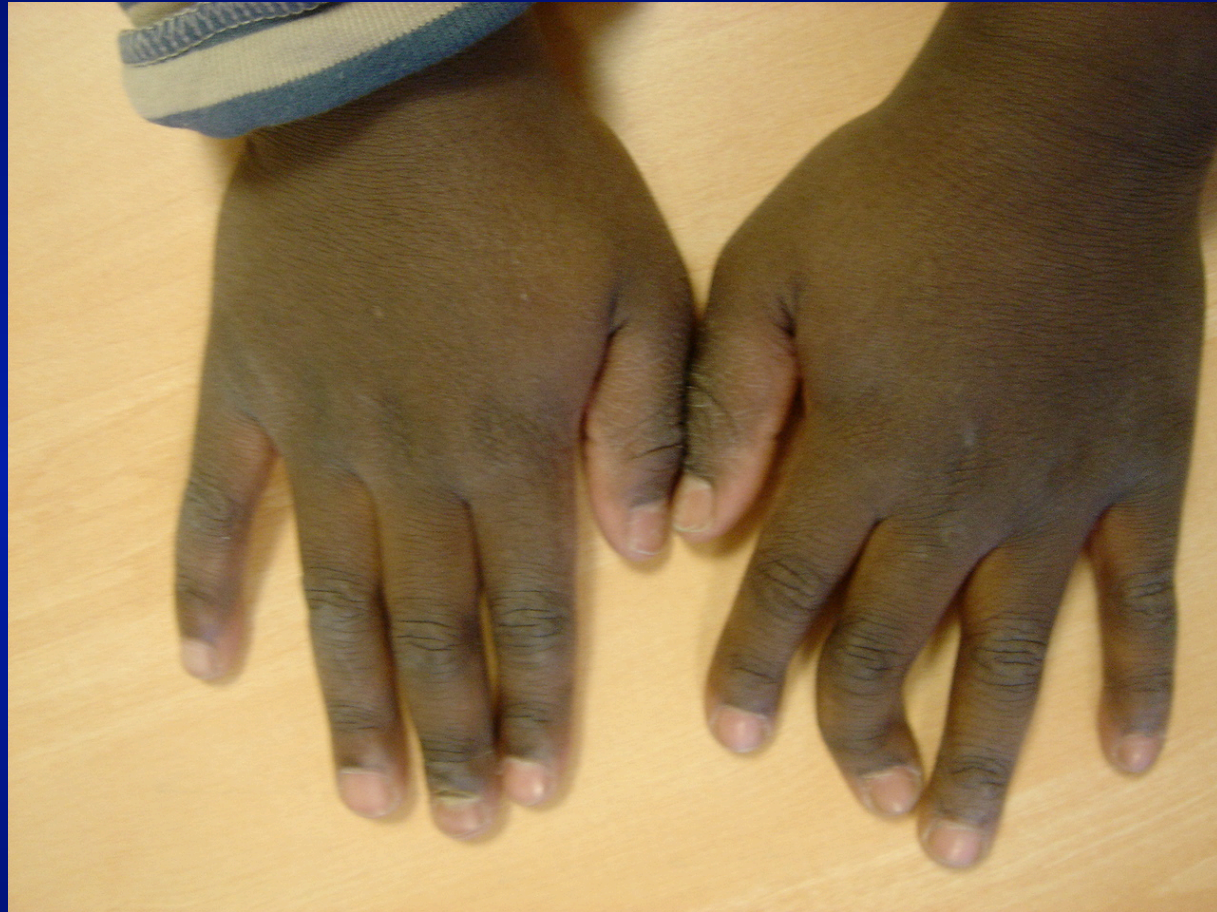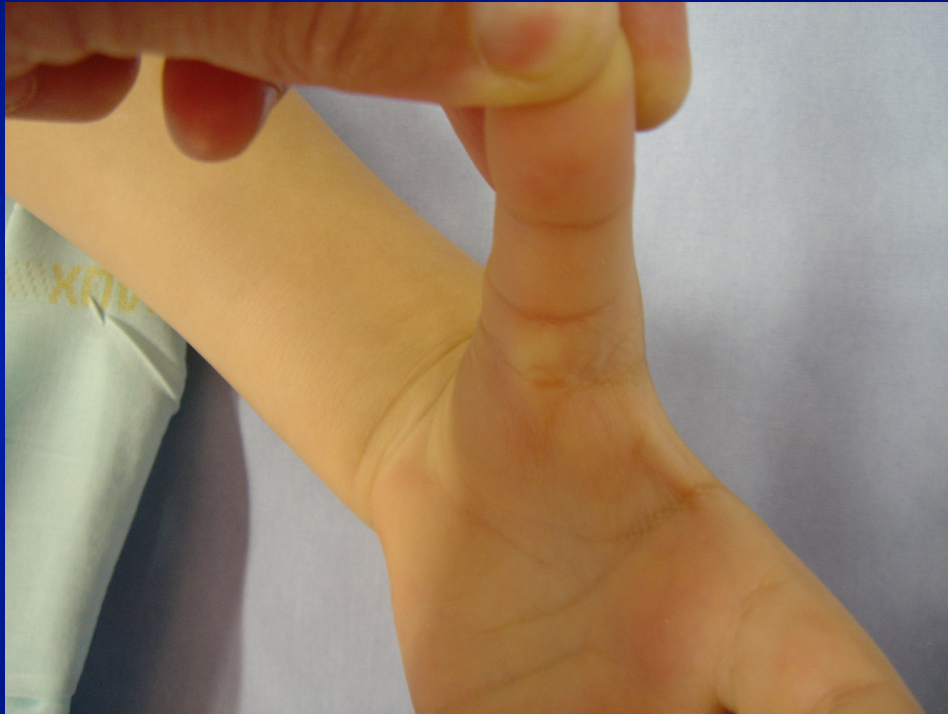# **MALFORMATIONS DU MEMBRE SUPERIEUR**

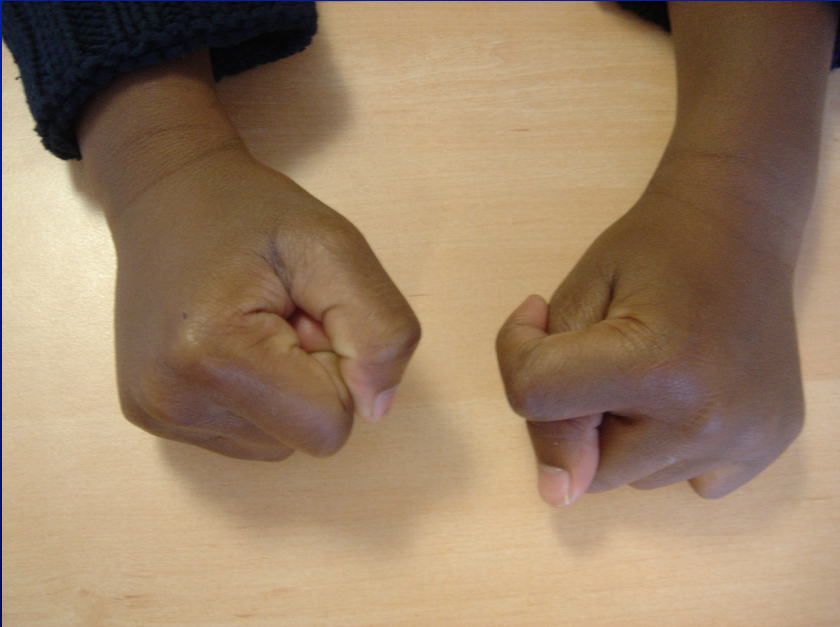
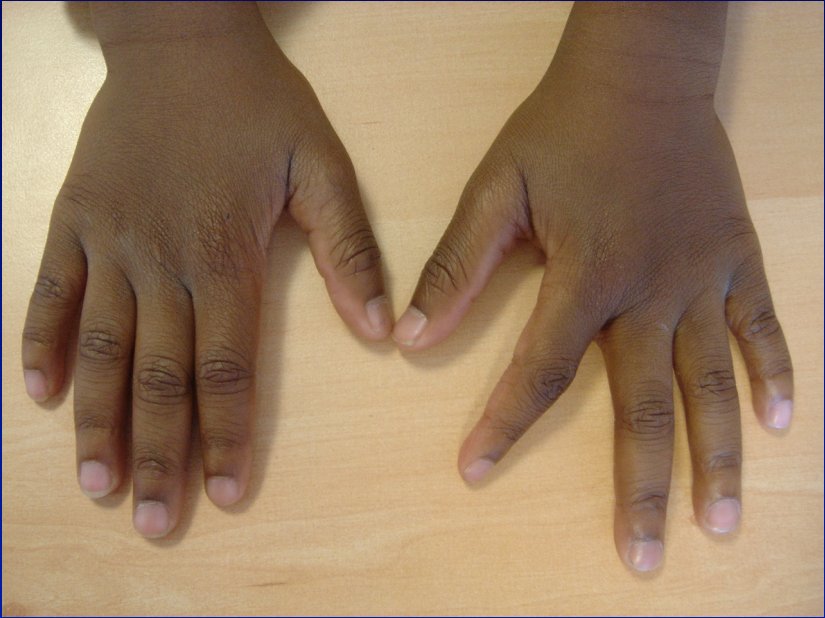- **BRIDES AMNIOTIQUES**
- **ANOMALIES GENERALISEES**













# CONCLUSION

- **DISPARITION DES GRANDES MALFORMATIONS**
- **ASSOCIATION SINDROMES PLURIMALFORMATIFS**