

Pathologie du canal omphalo mésentérique

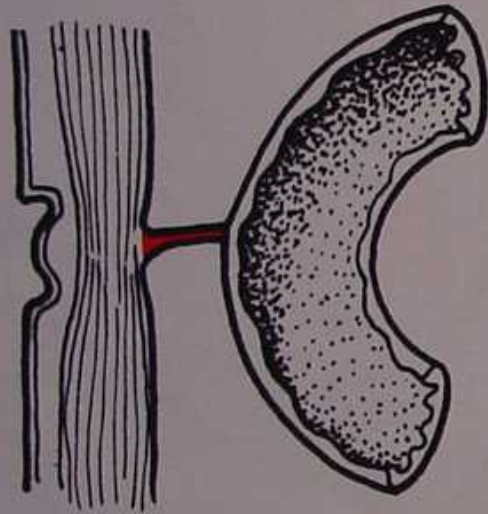
Canal omphalo mésentérique perméable

Diverticule de Meckel

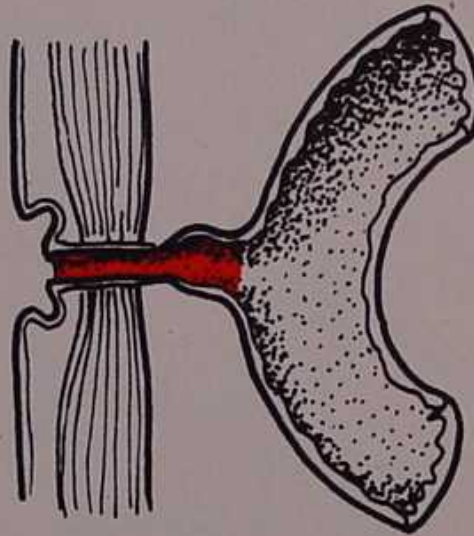
Bride mésentérique

Hétérotopie digestive ombilicale

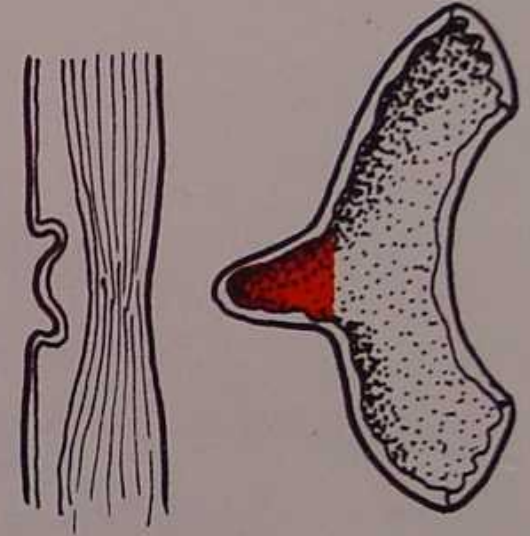
Pathologie du canal omphalo mésentérique



Bride.



Fistule entéro-ombilicale.



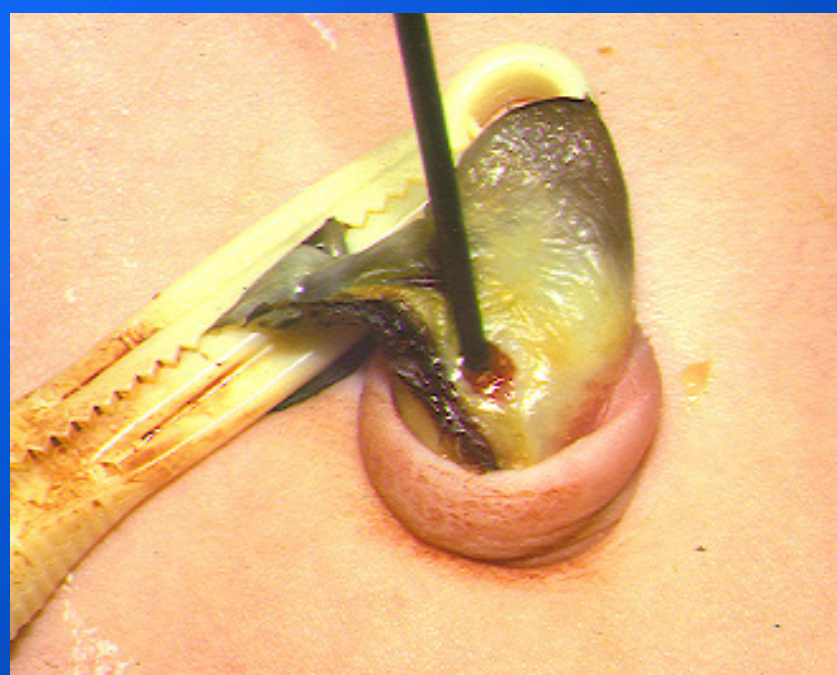
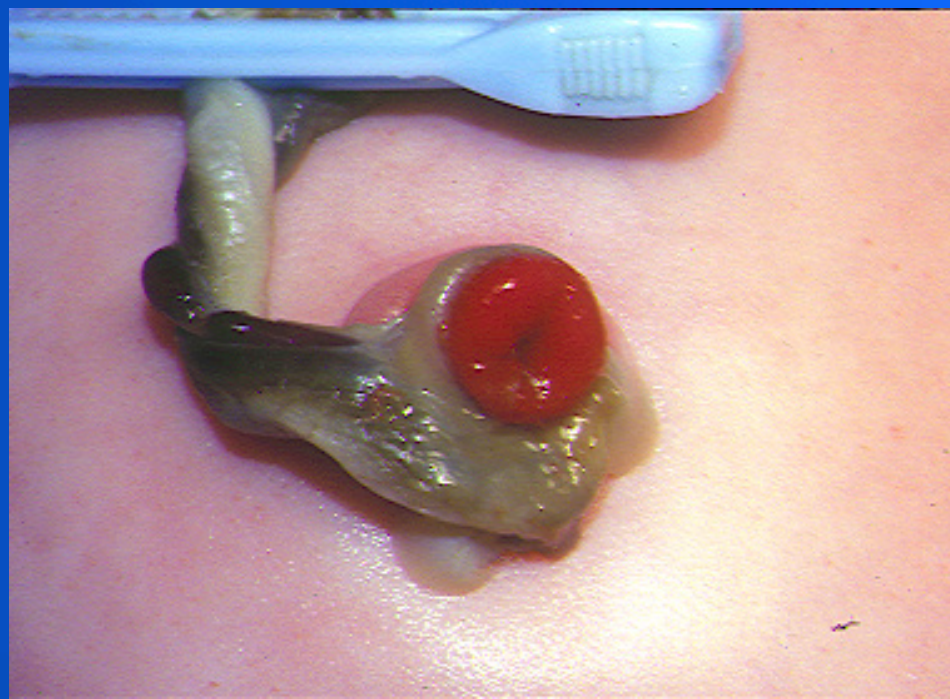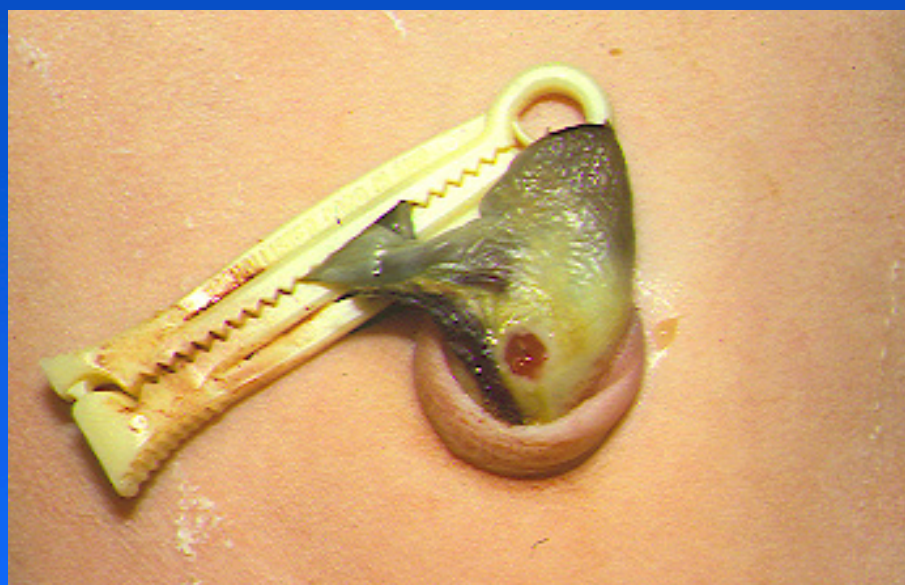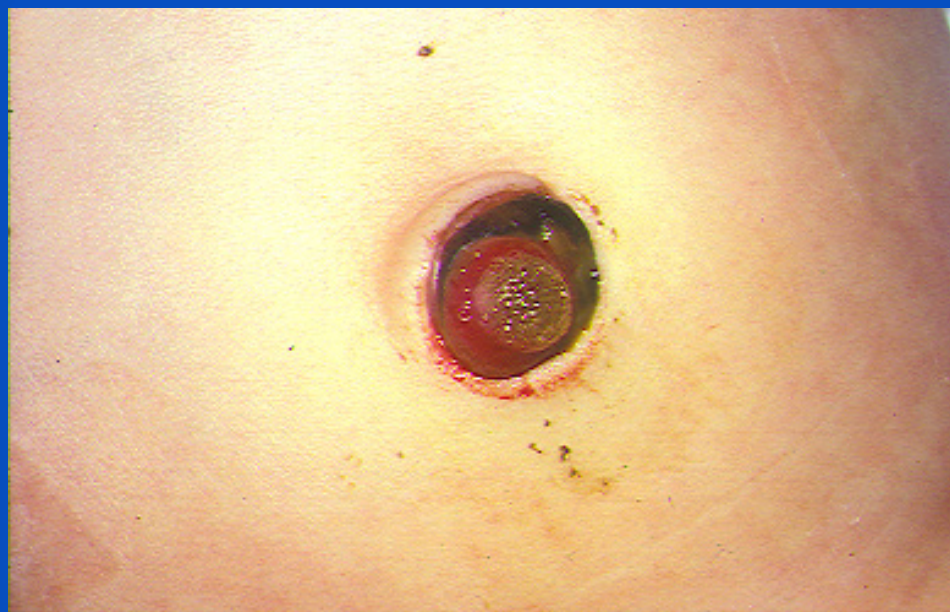Diverticule typique.

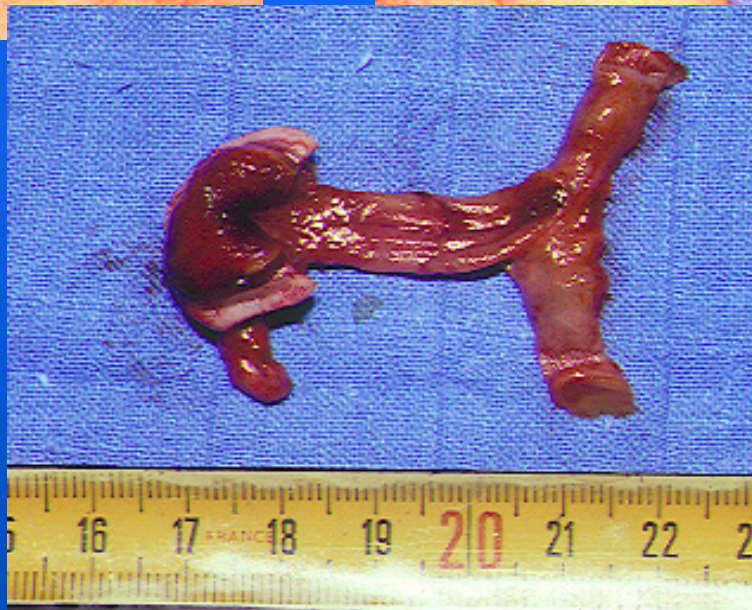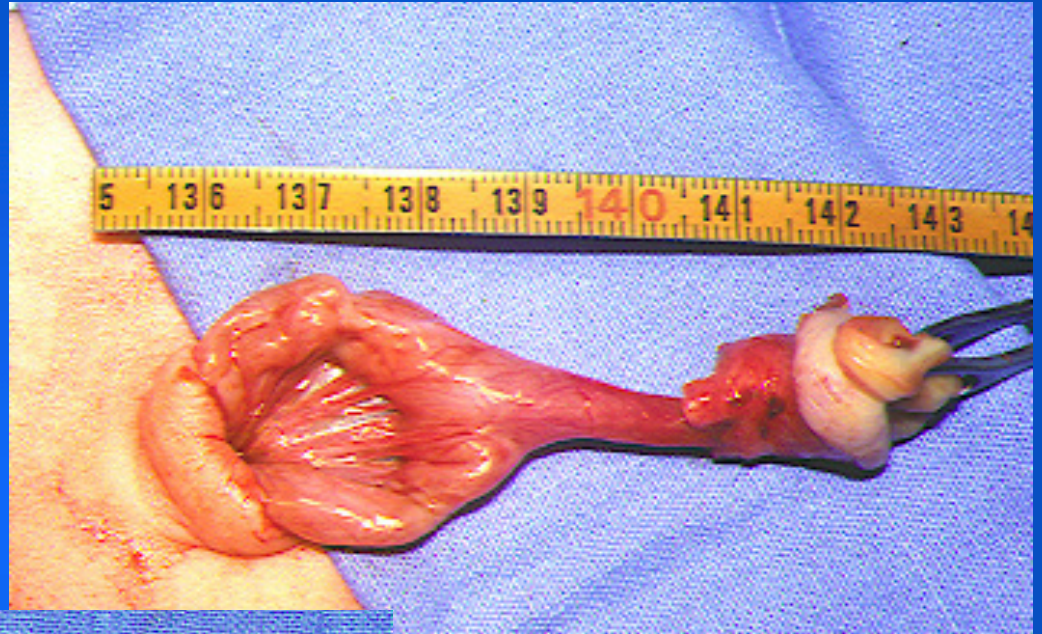
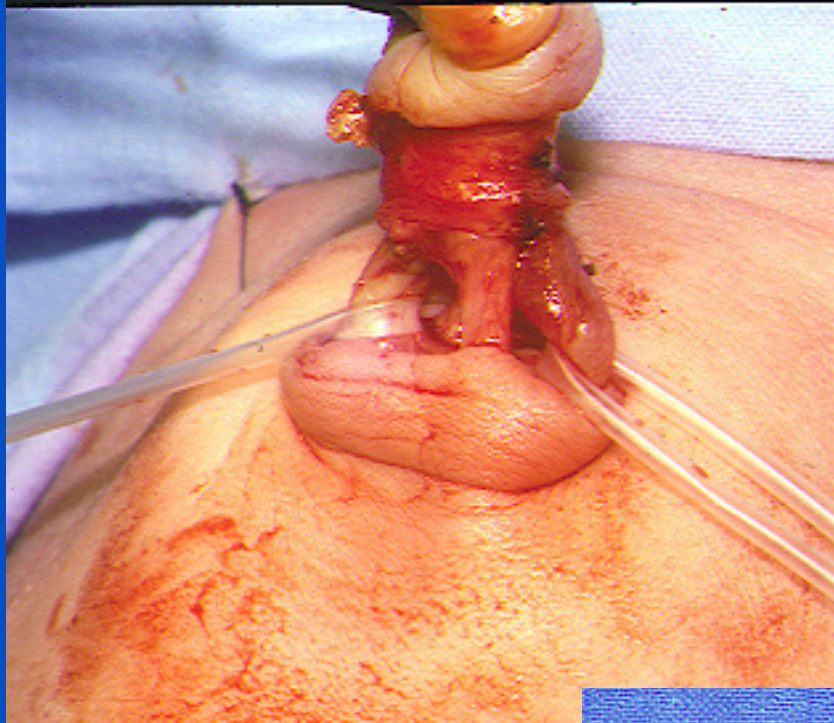
Fistule omphalo méésentérique

Evidente dès la naissance

Fistule digestive ombilicale

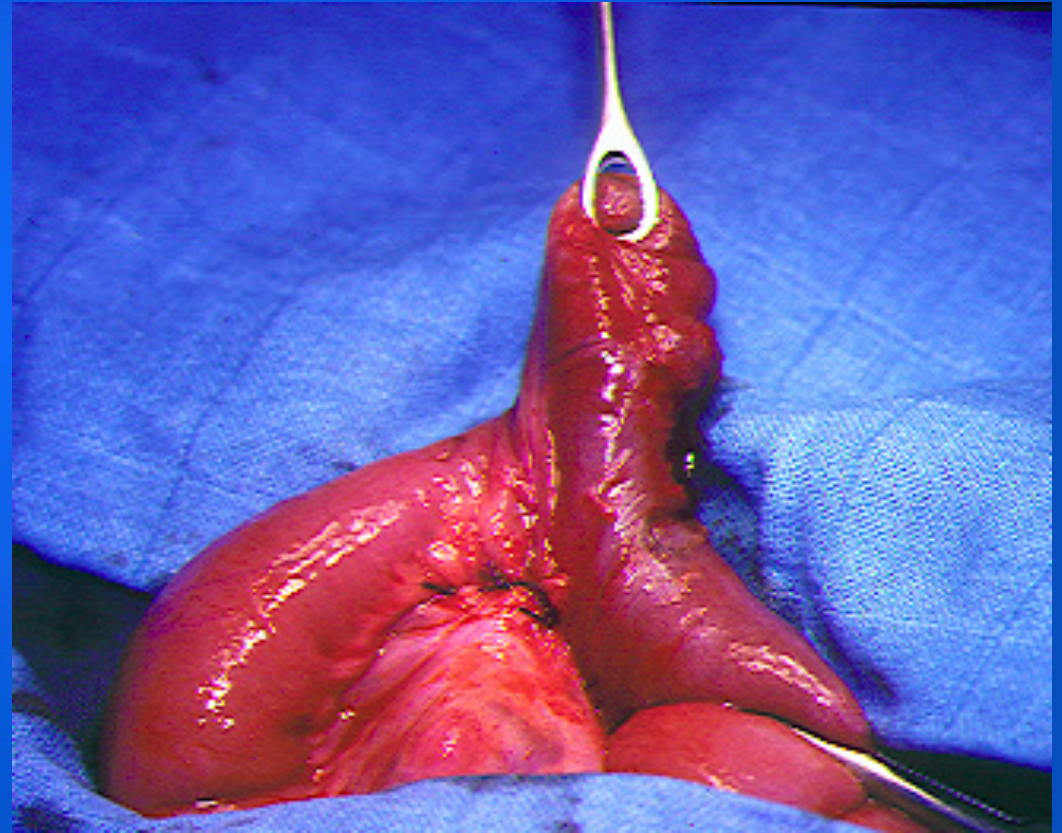
Pas d'occlusion +++



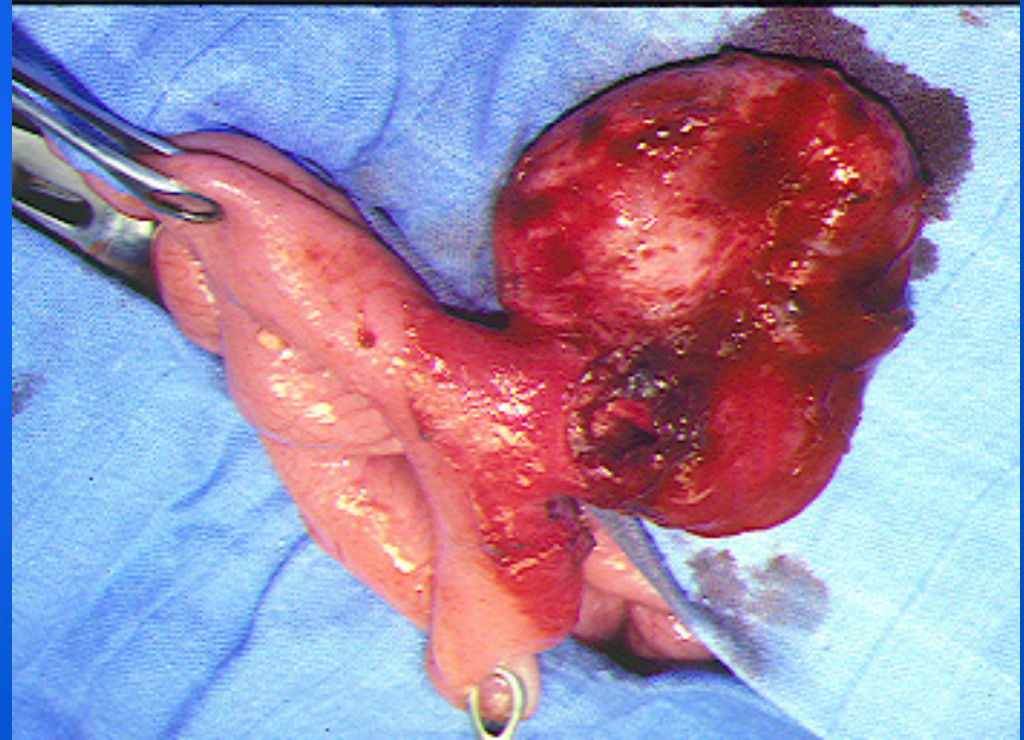
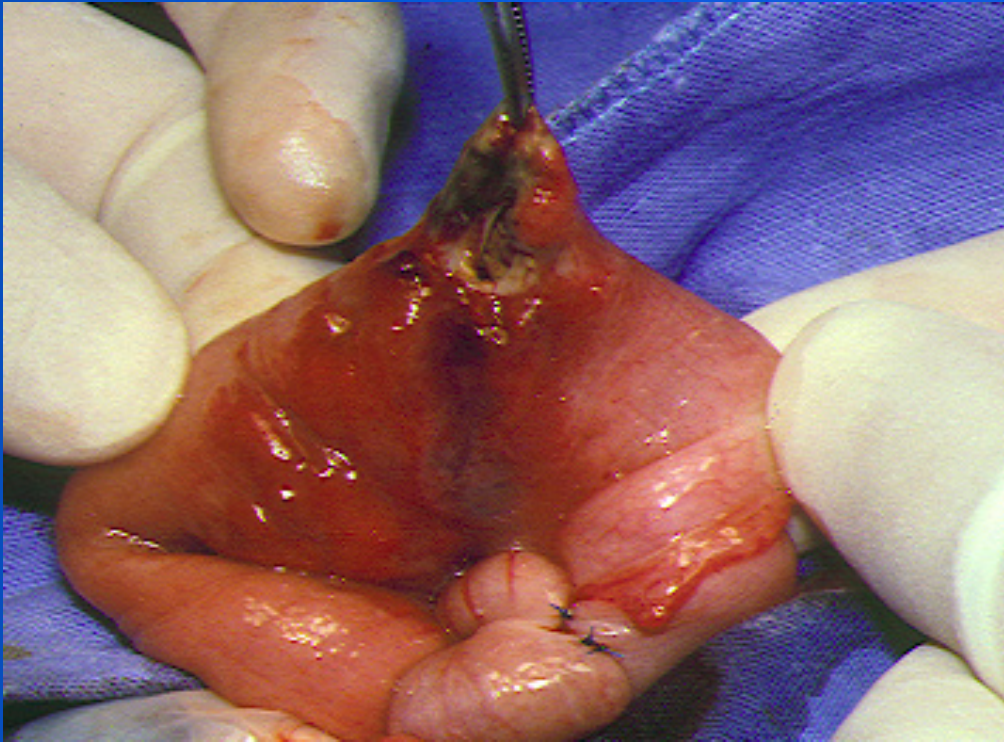


Diverticule de Meckel

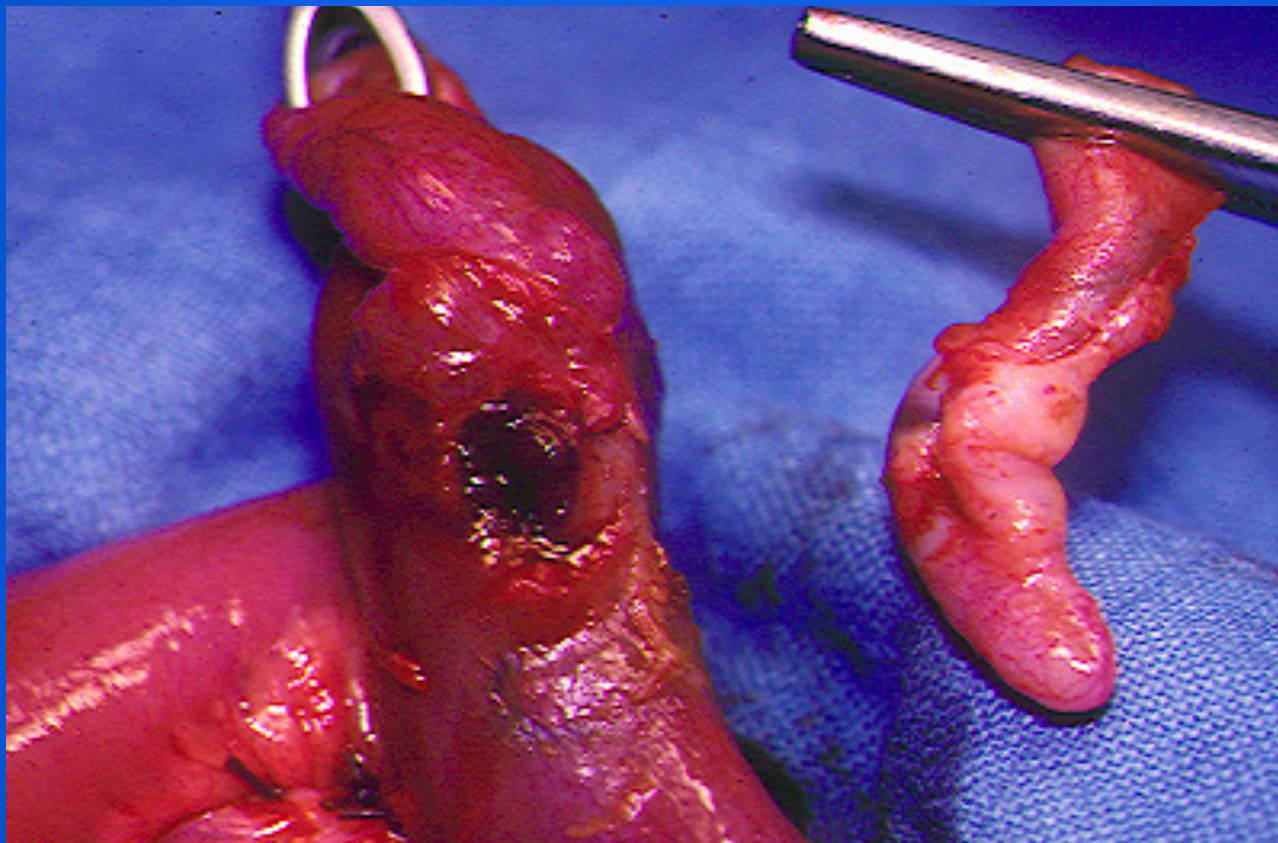
- > douleurs
- > meckelite
- > hémorragie
- > invagination



Meckelite

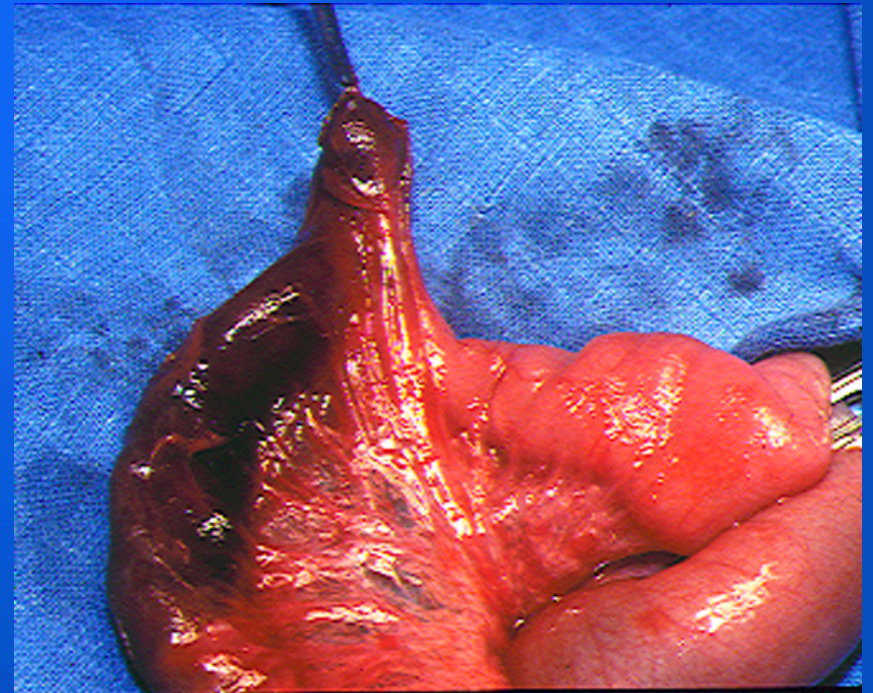
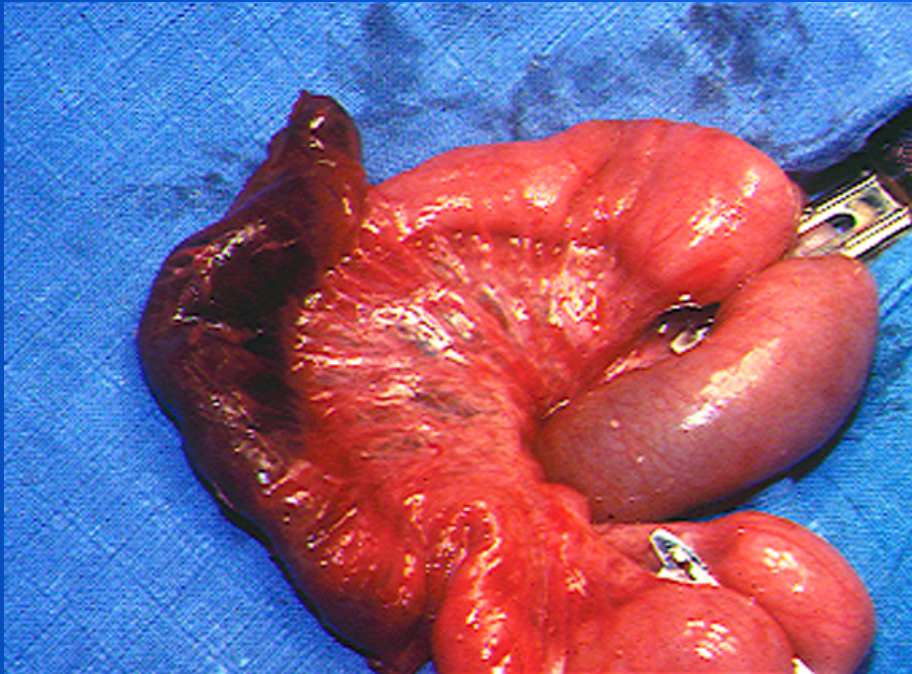


Piège: meckel + appendicite



Invagination

Irréductible au traitement radiologique
Souvent irréductible à ventre ouvert
Réséction du grêle



Hémorragie digestive

Conduite à tenir

Endoscopie haute

Endoscopie basse

**Coeliochirurgie dans la même anesthésie
si endoscopies négatives**

