



Collège Hospitalier et Universitaire
de Chirurgie Pédiatrique

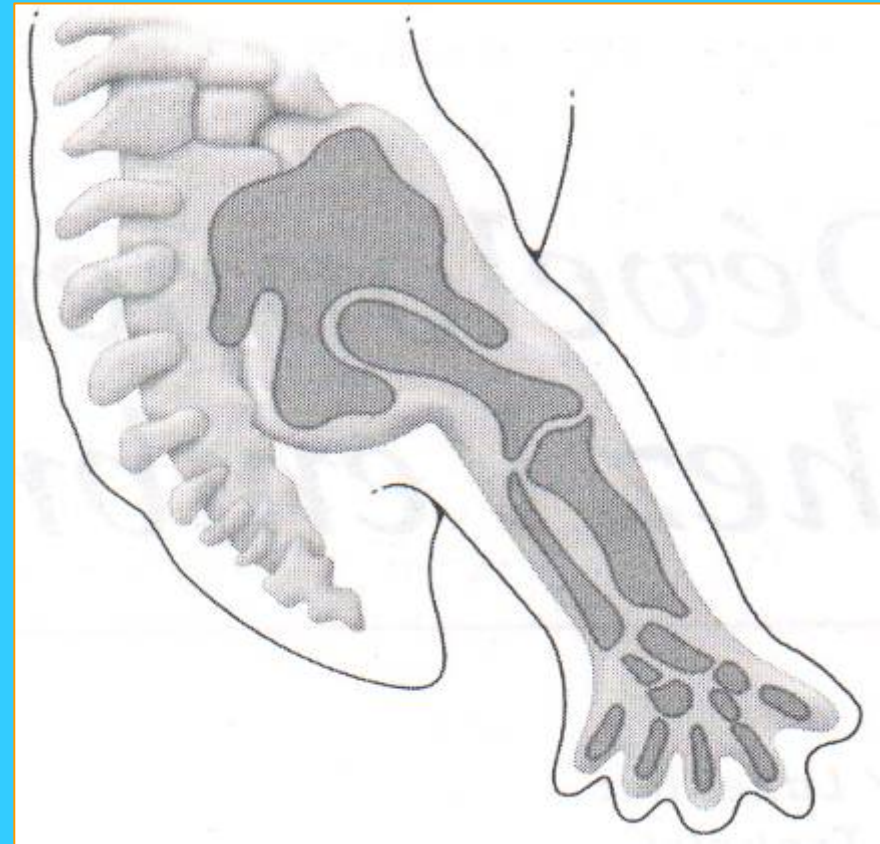
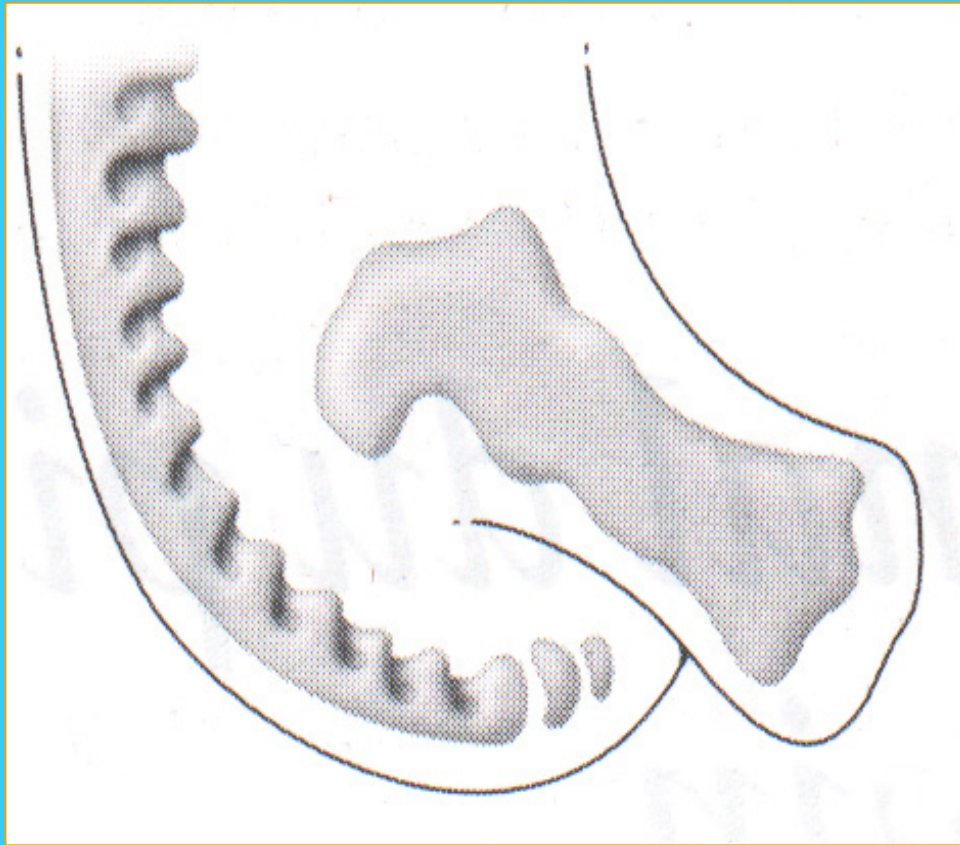
DESC de Chirurgie Pédiatrique

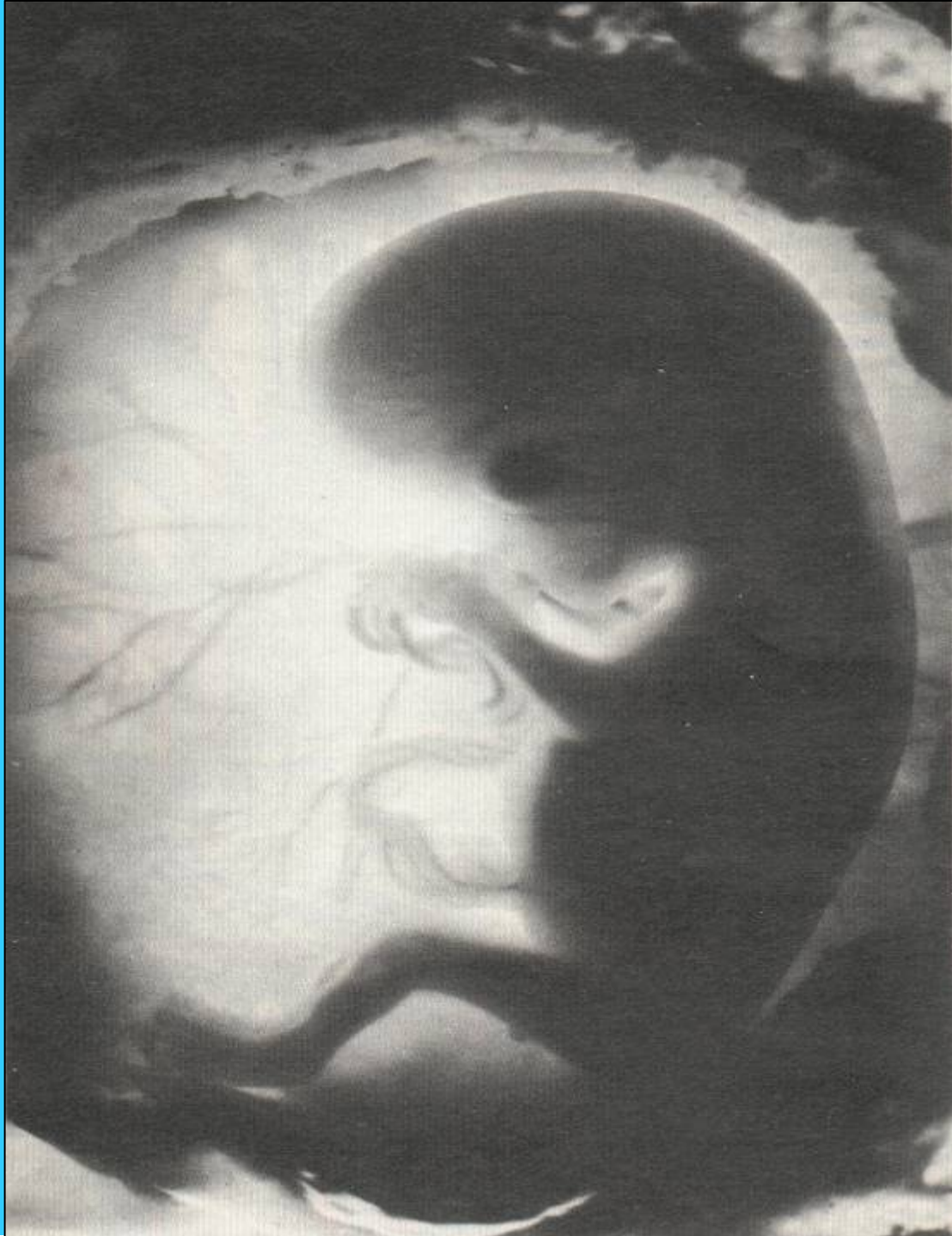
Session de Septembre 2009 - PARIS

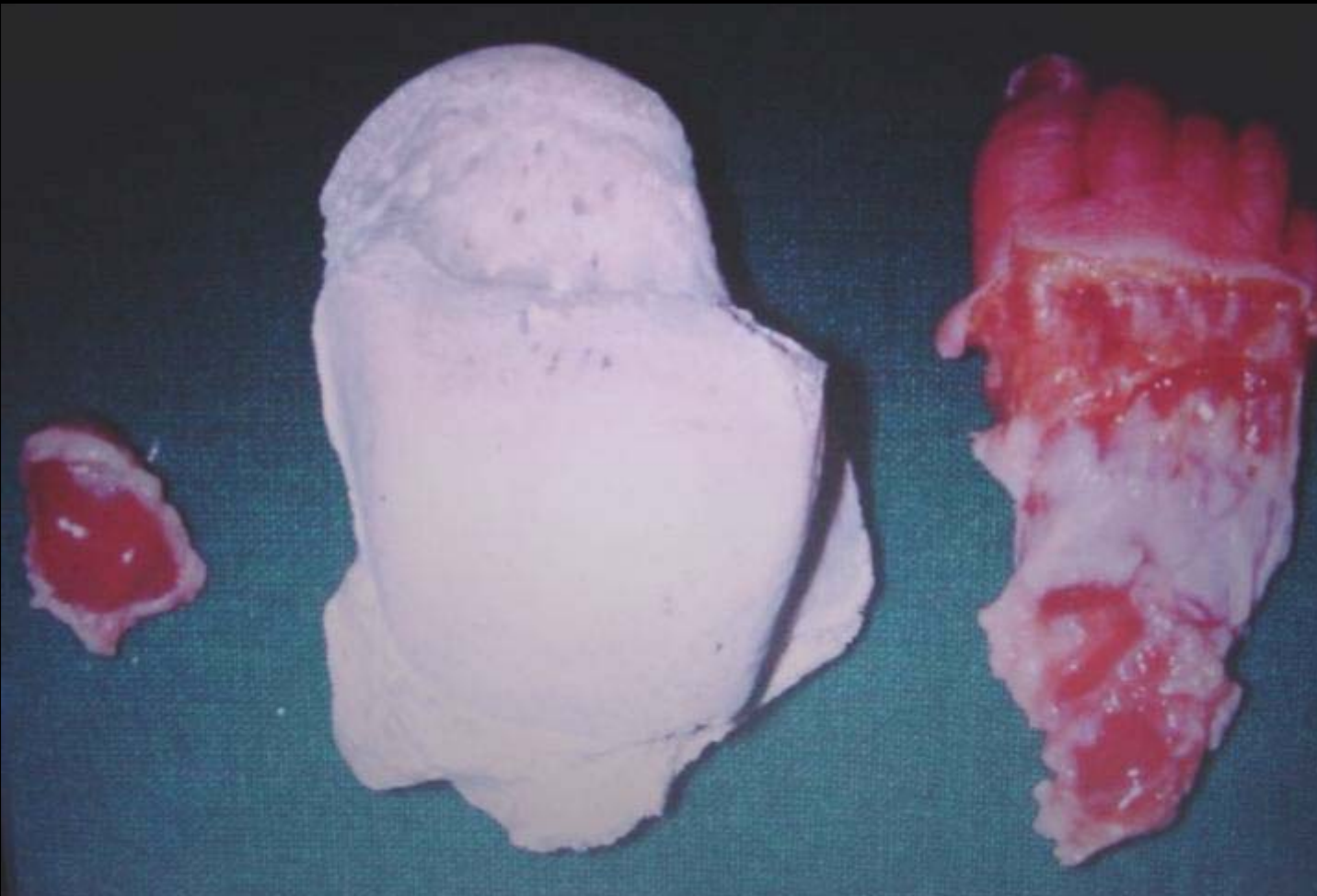Physiologie du pied

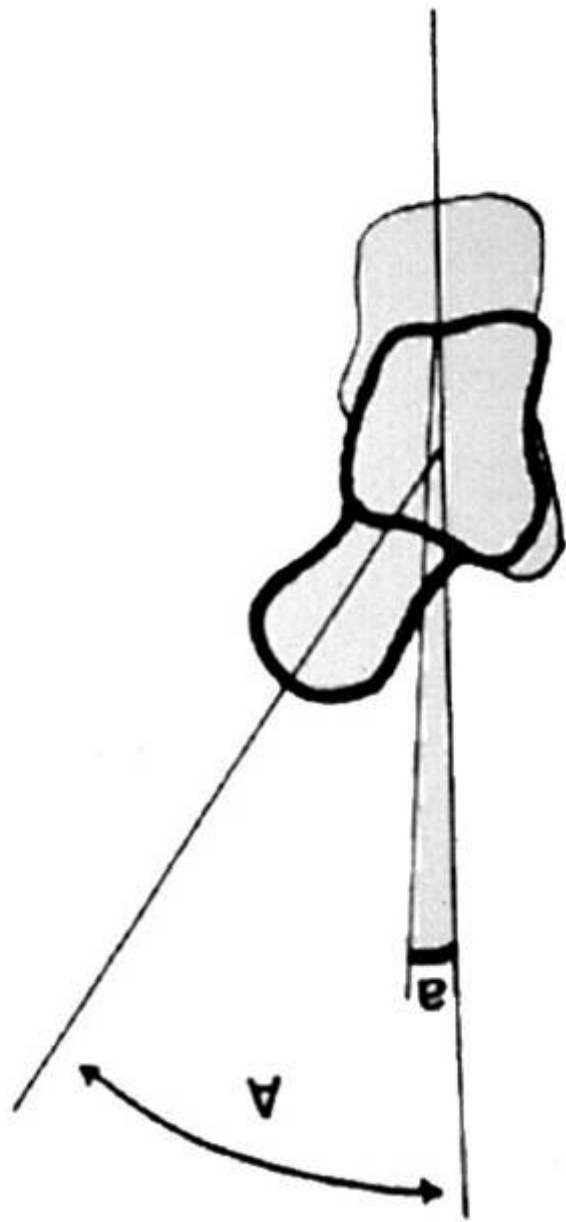
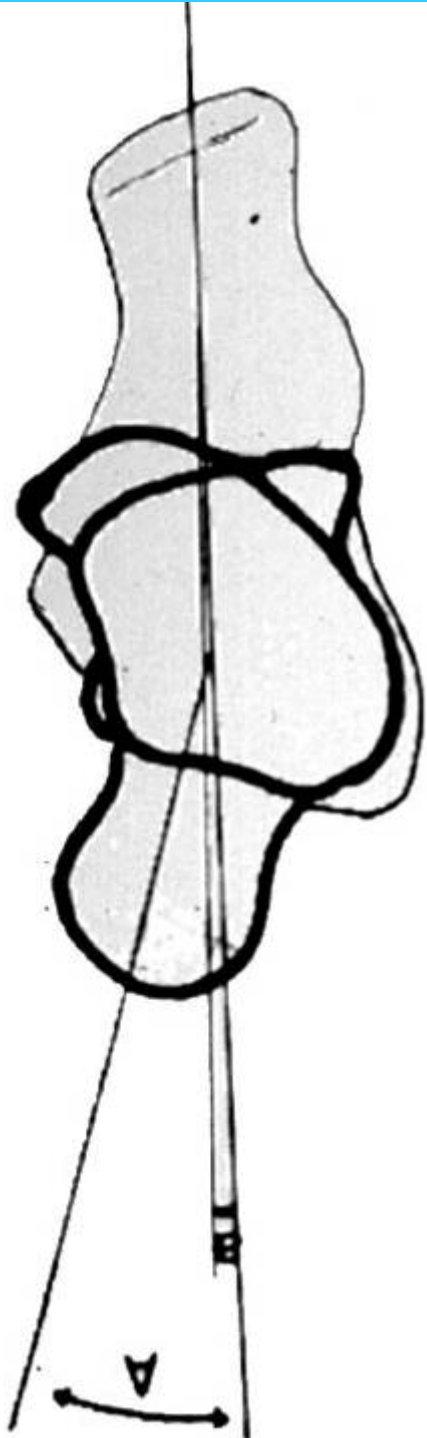
D MOULIES

Embryologie : 6ème semaine

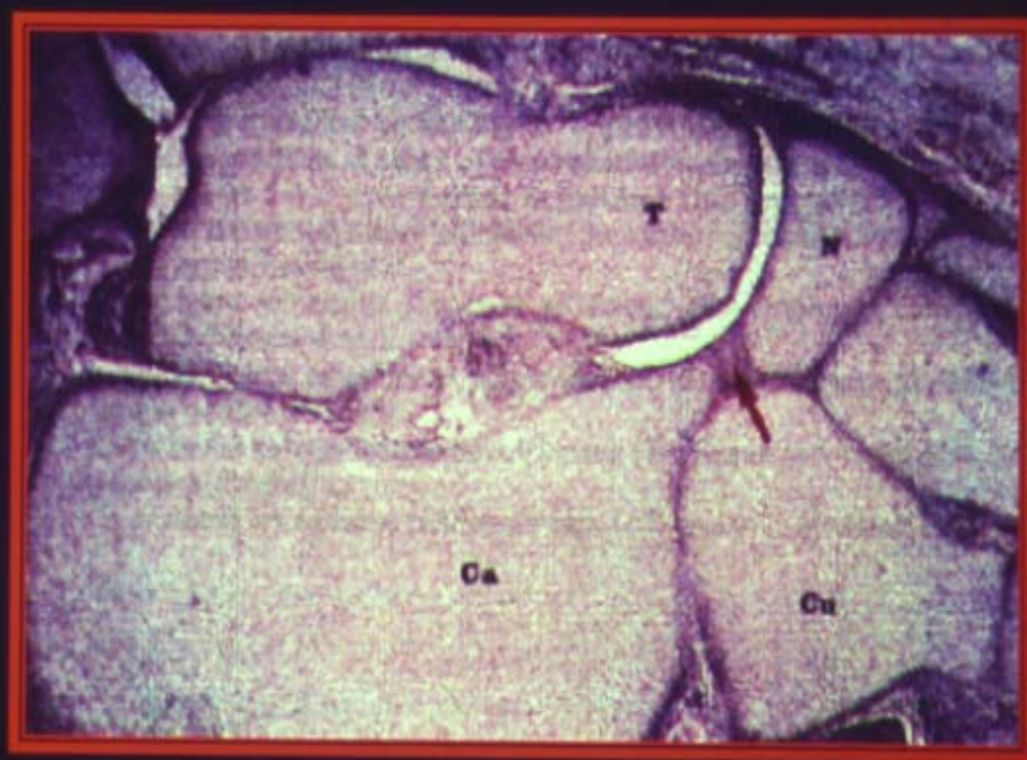
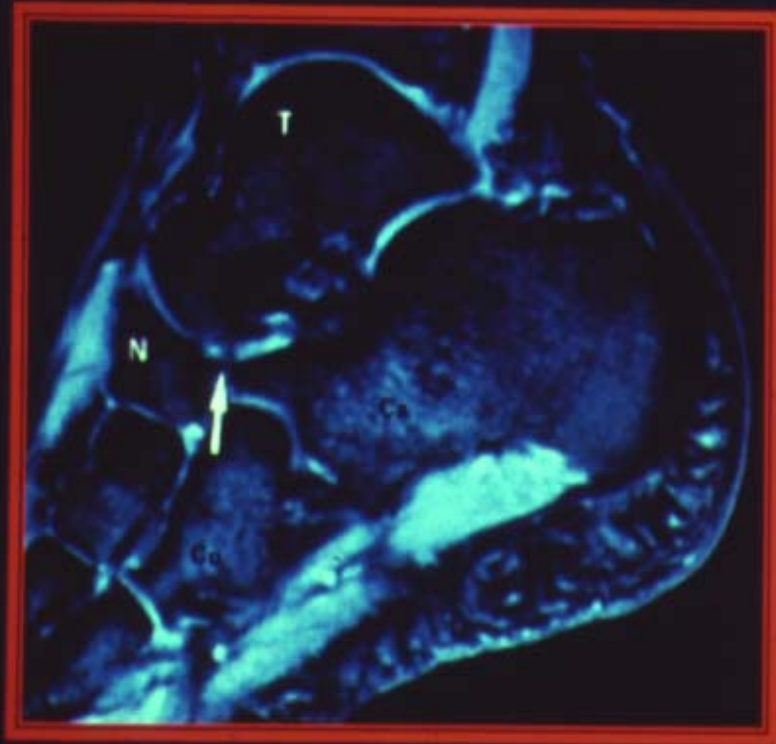




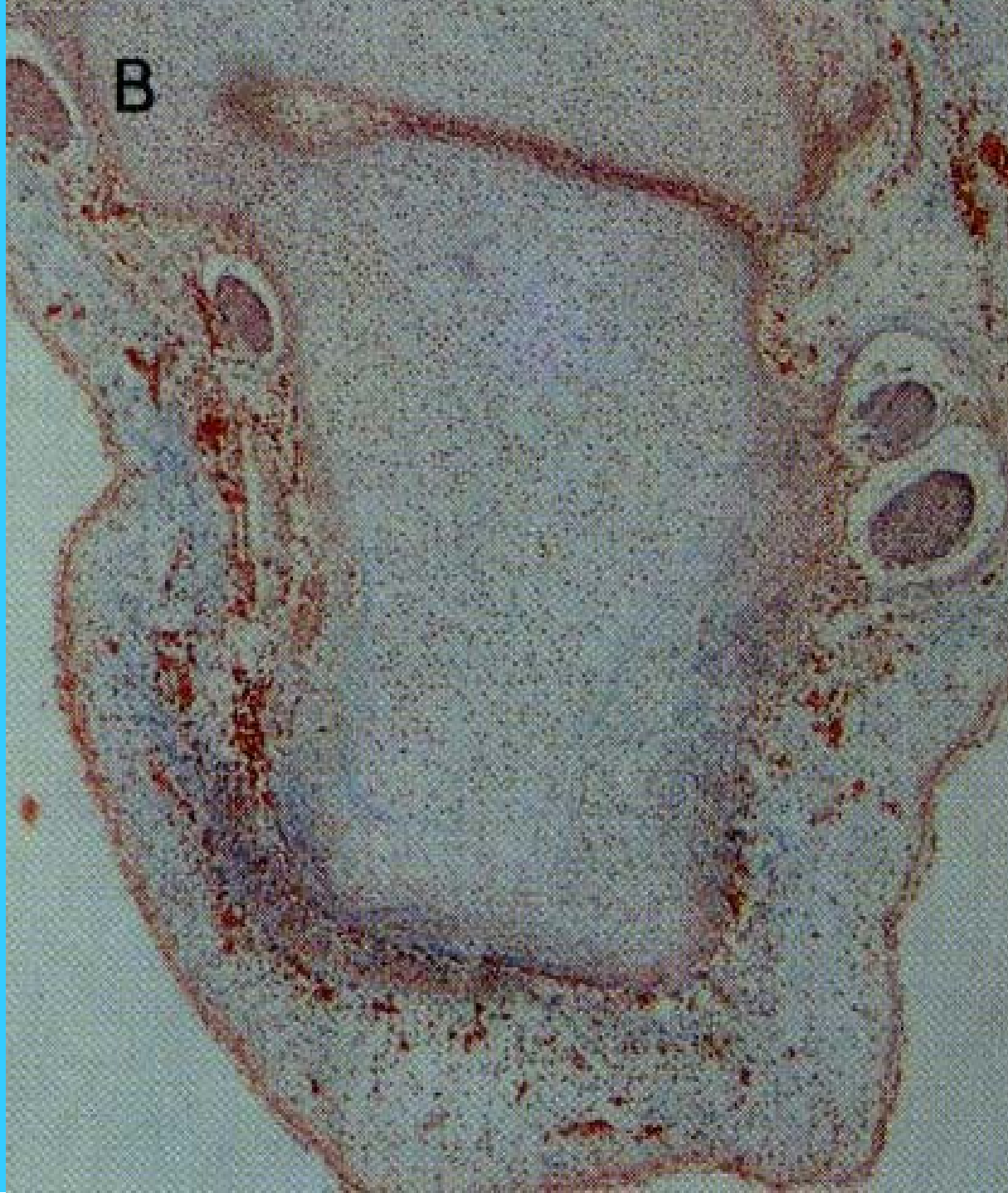

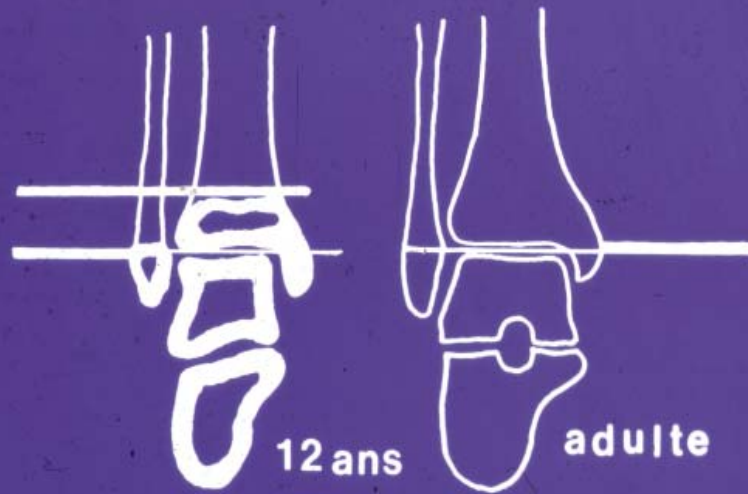


La "coxa pedis"




B



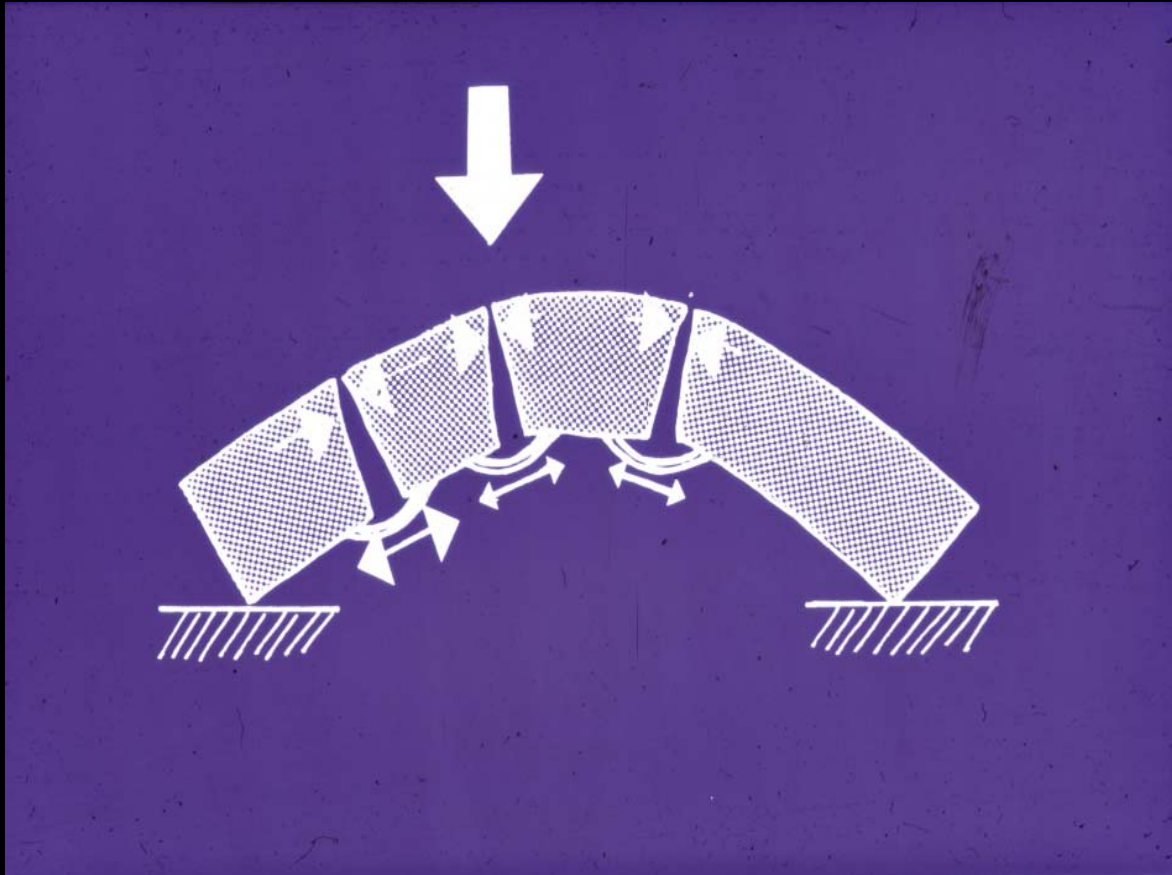


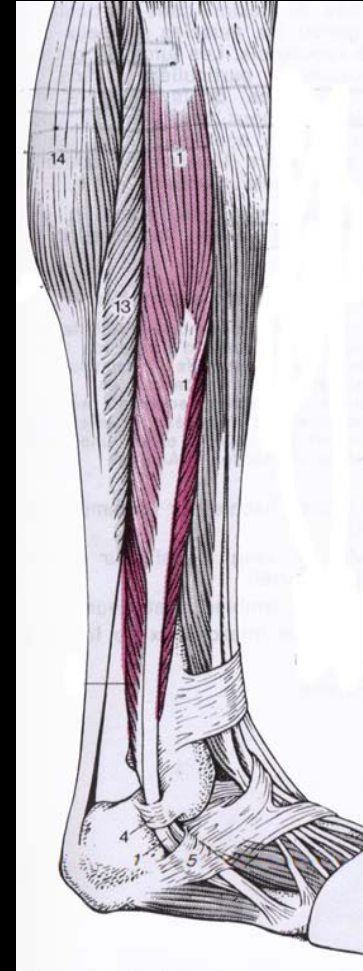
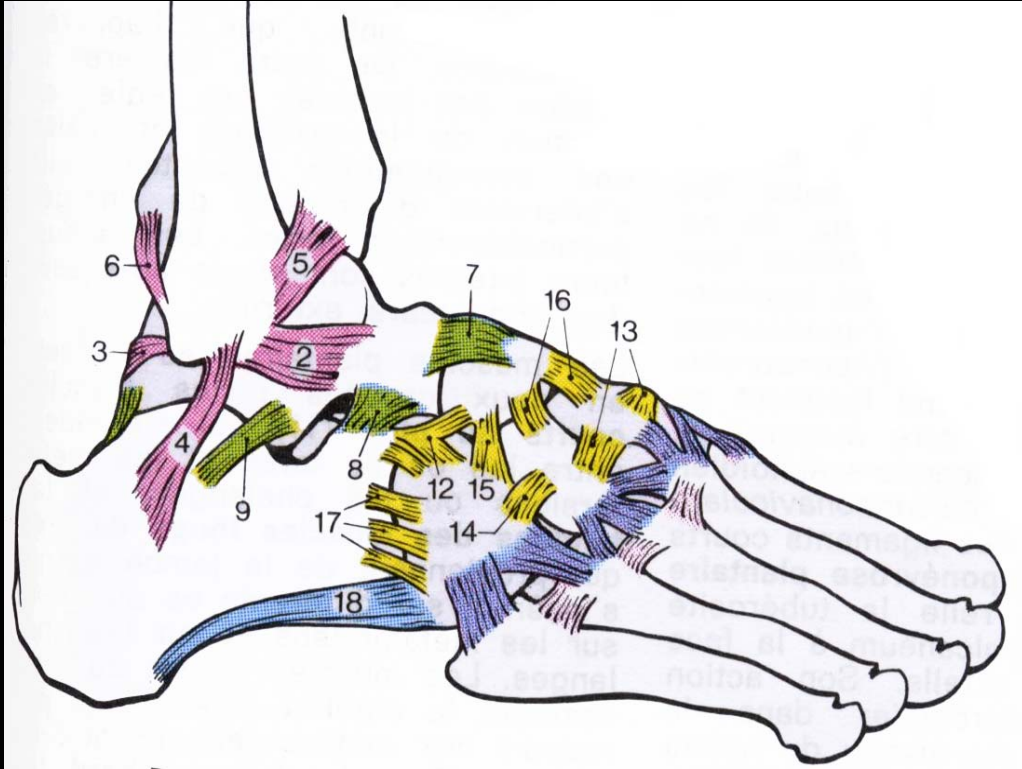
La lamina pedis

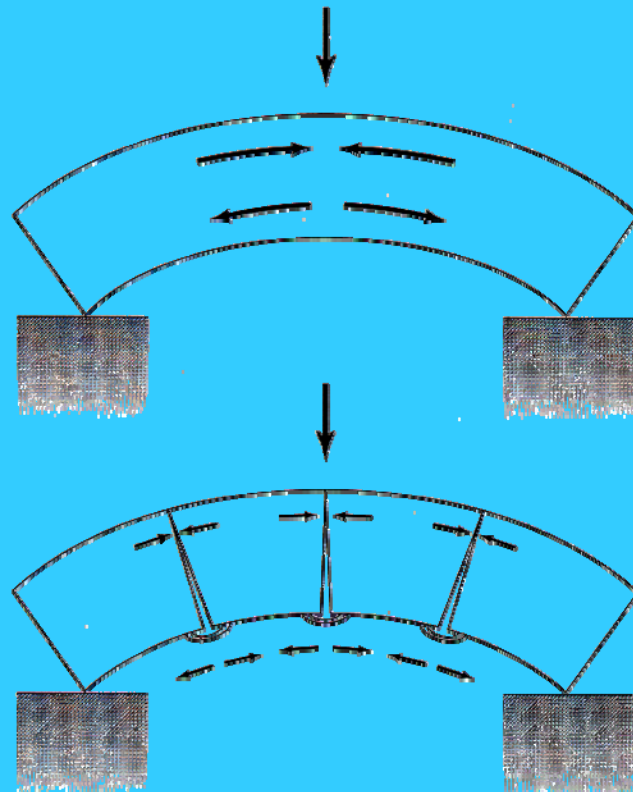
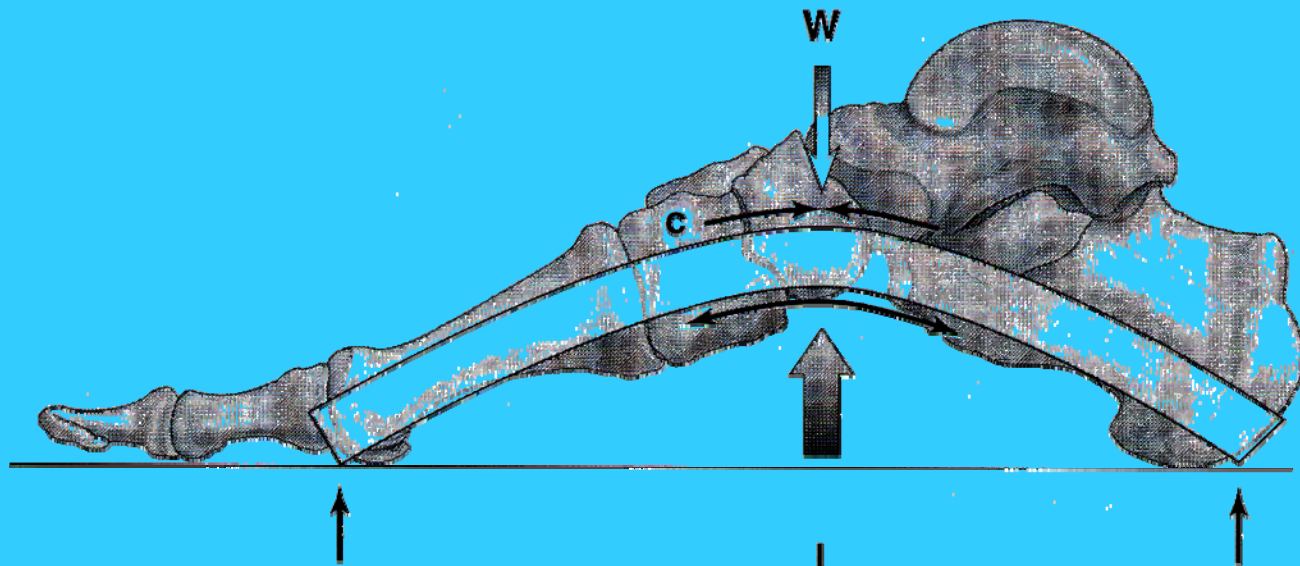


Dessin articulaire

+ ligaments et capsules = morphologie







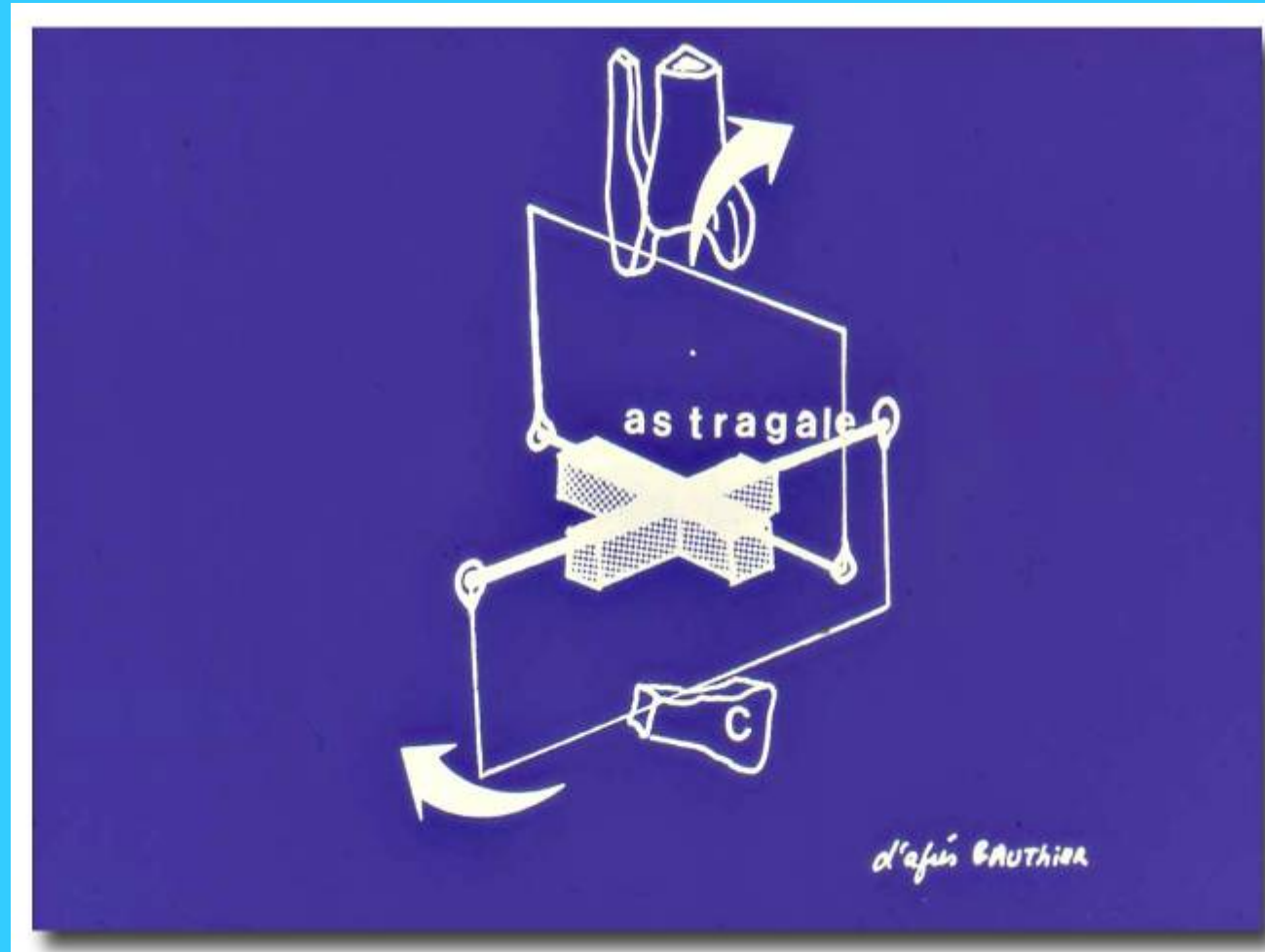EMC

[REDACTED]


[REDACTED]

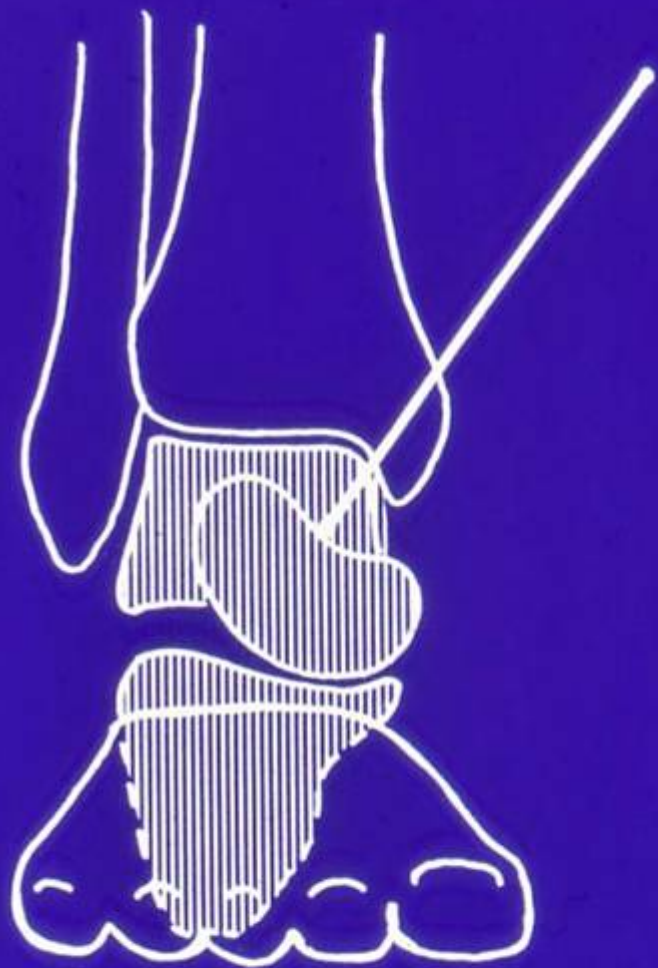[REDACTED]

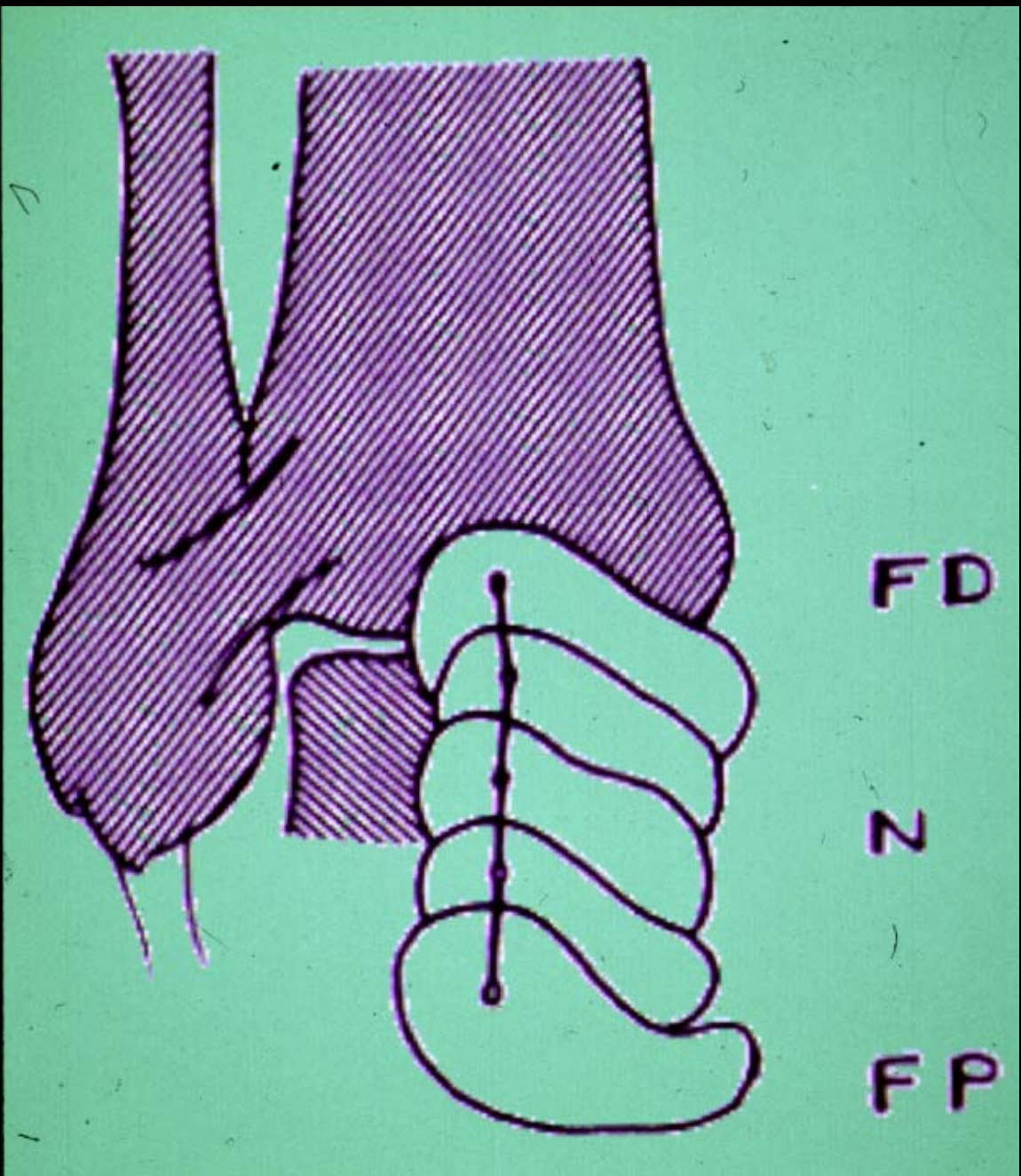
[REDACTED]

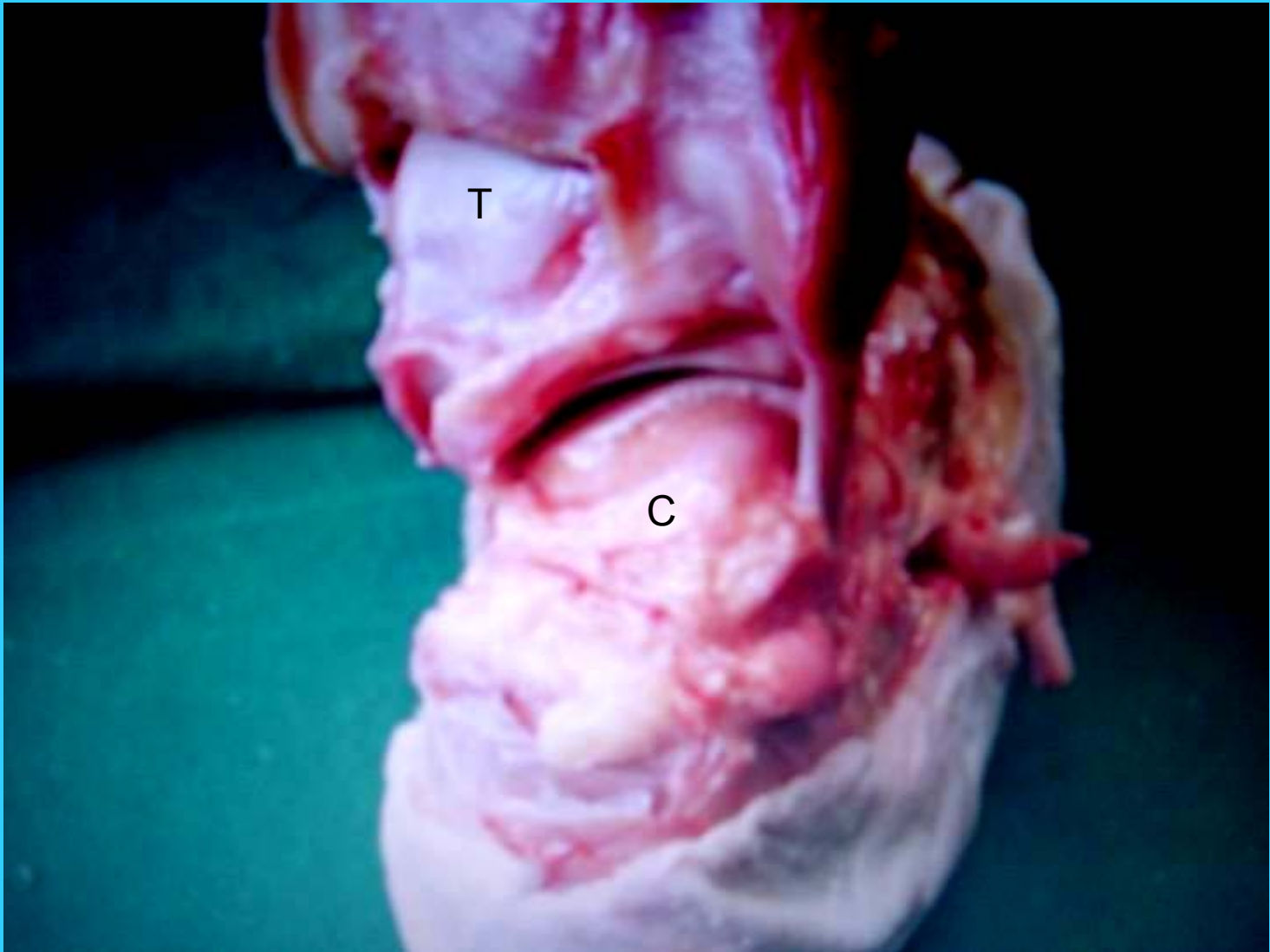


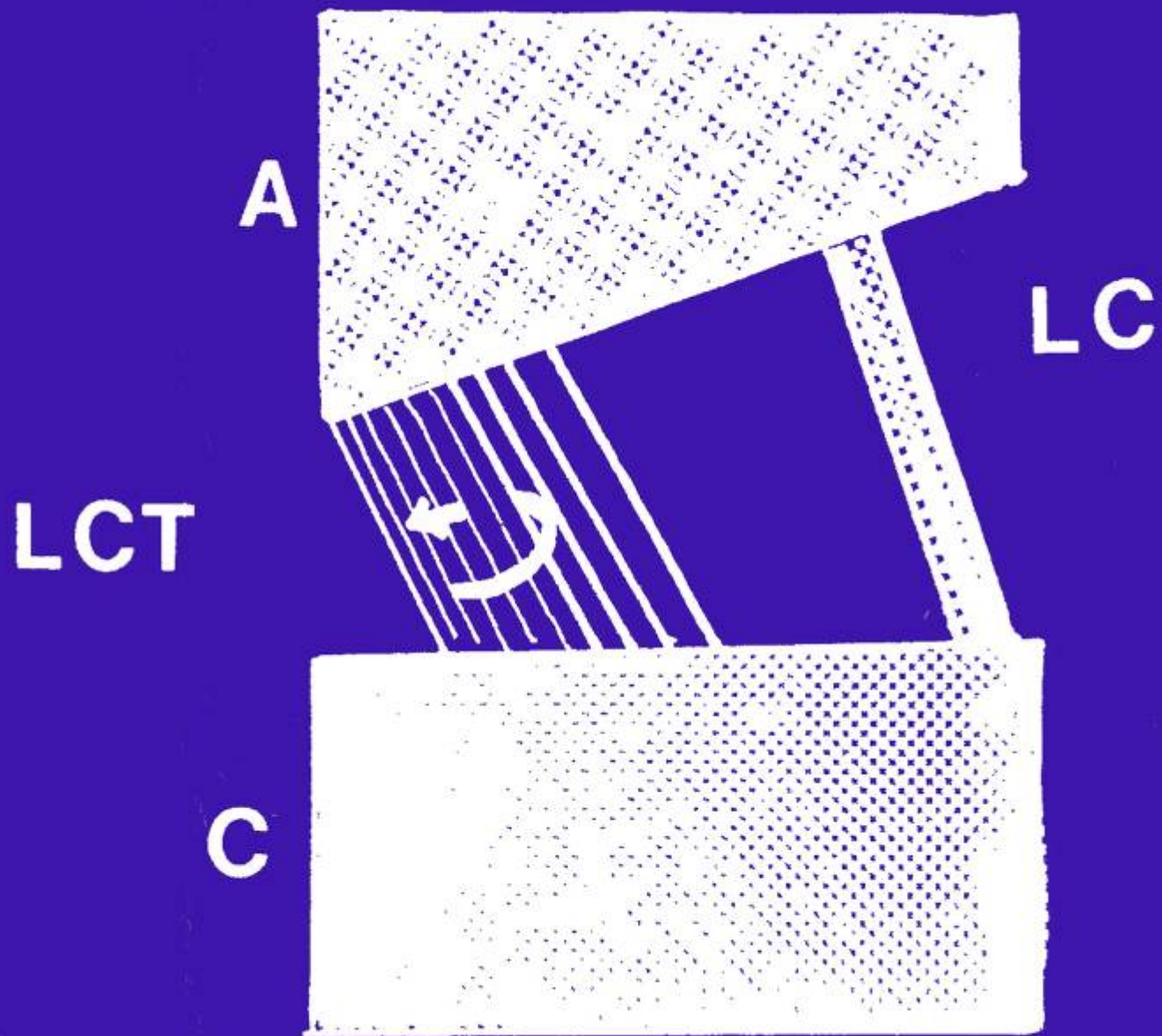
d'après BAUTHIER

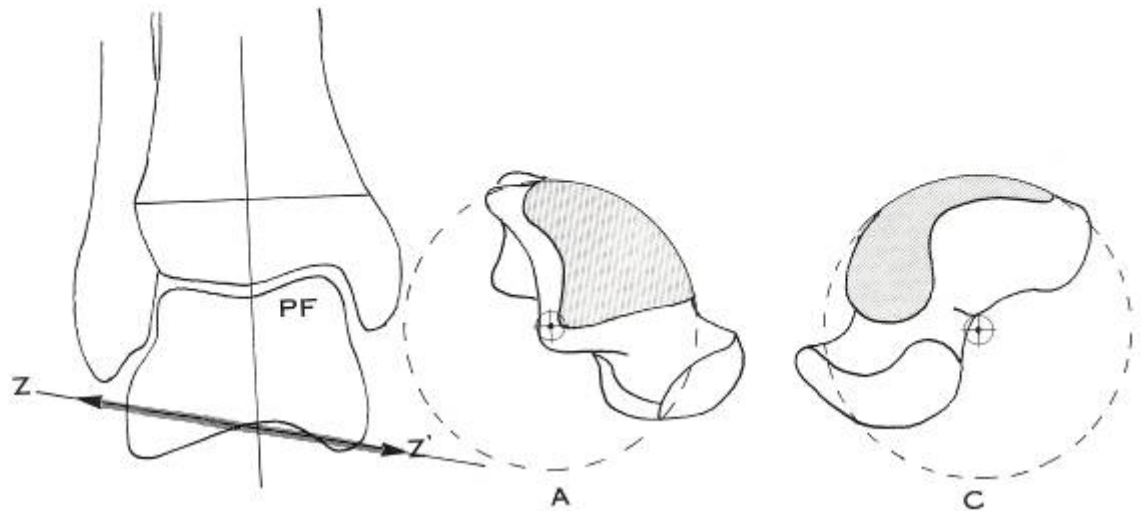
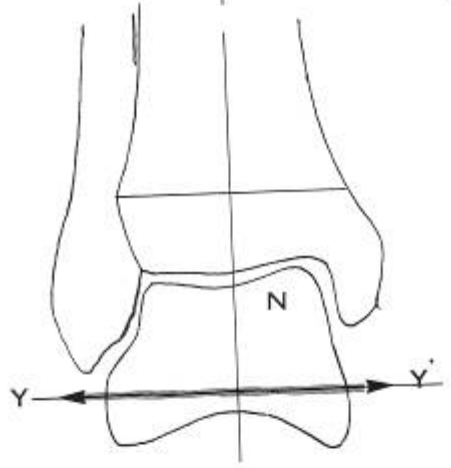
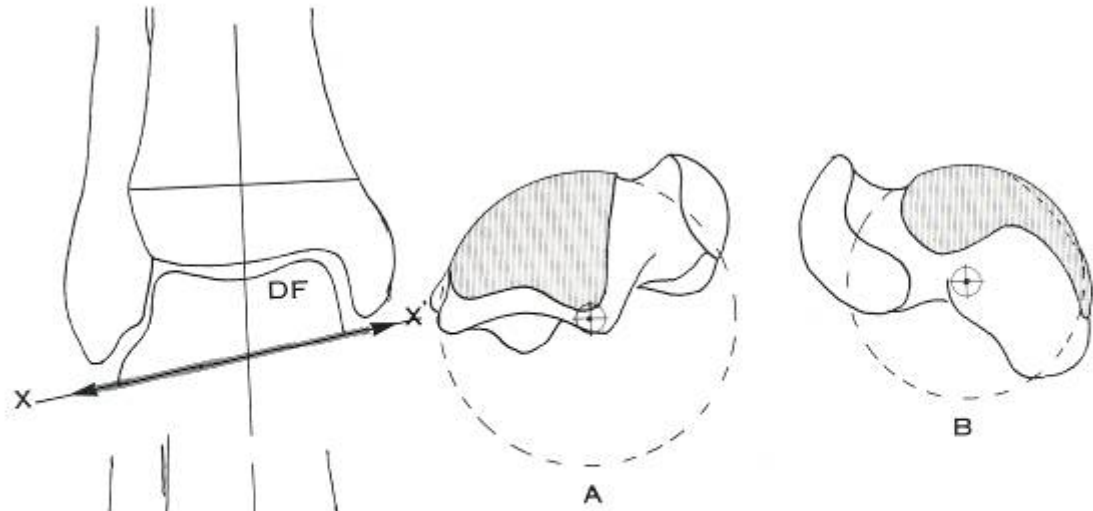


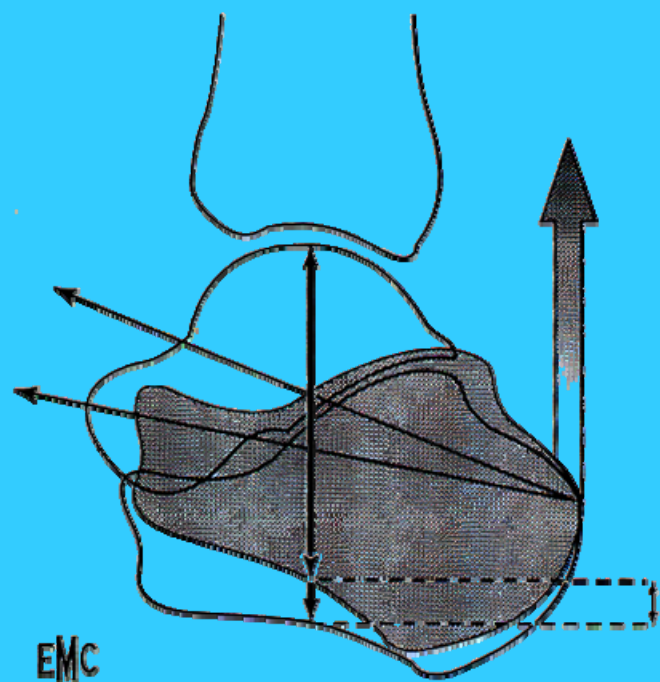




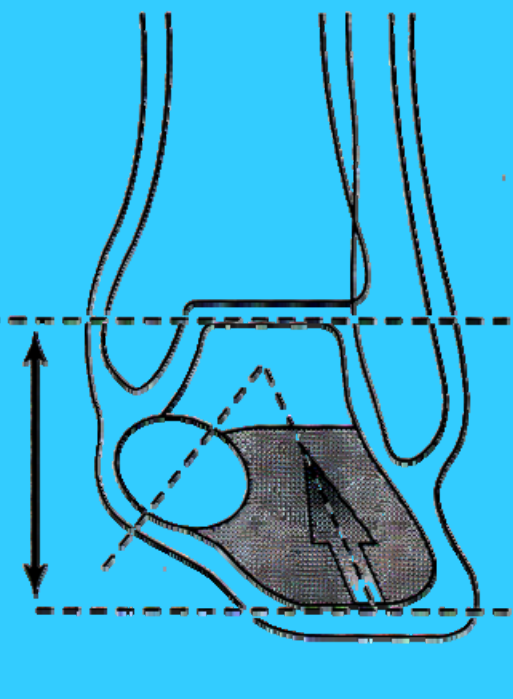
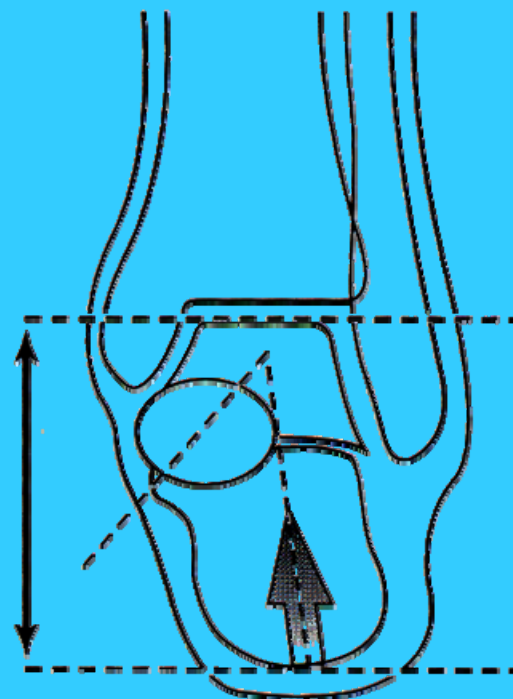


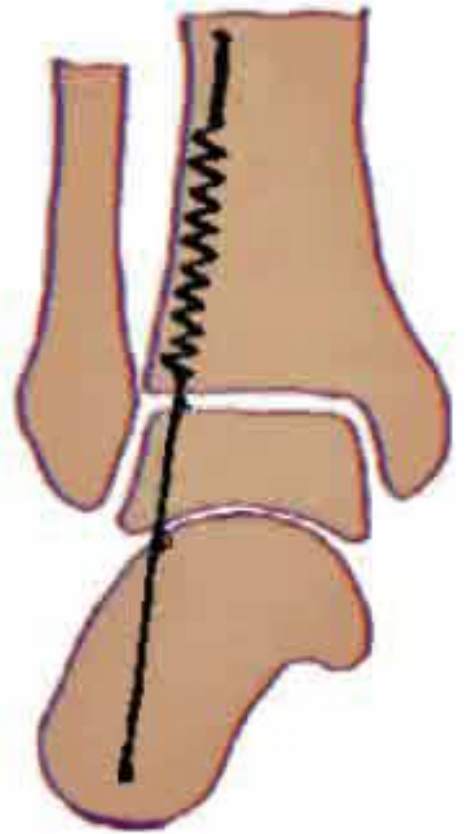
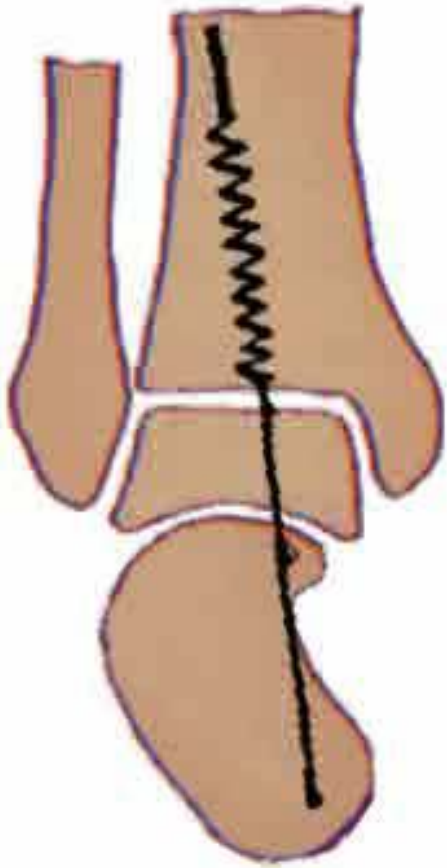


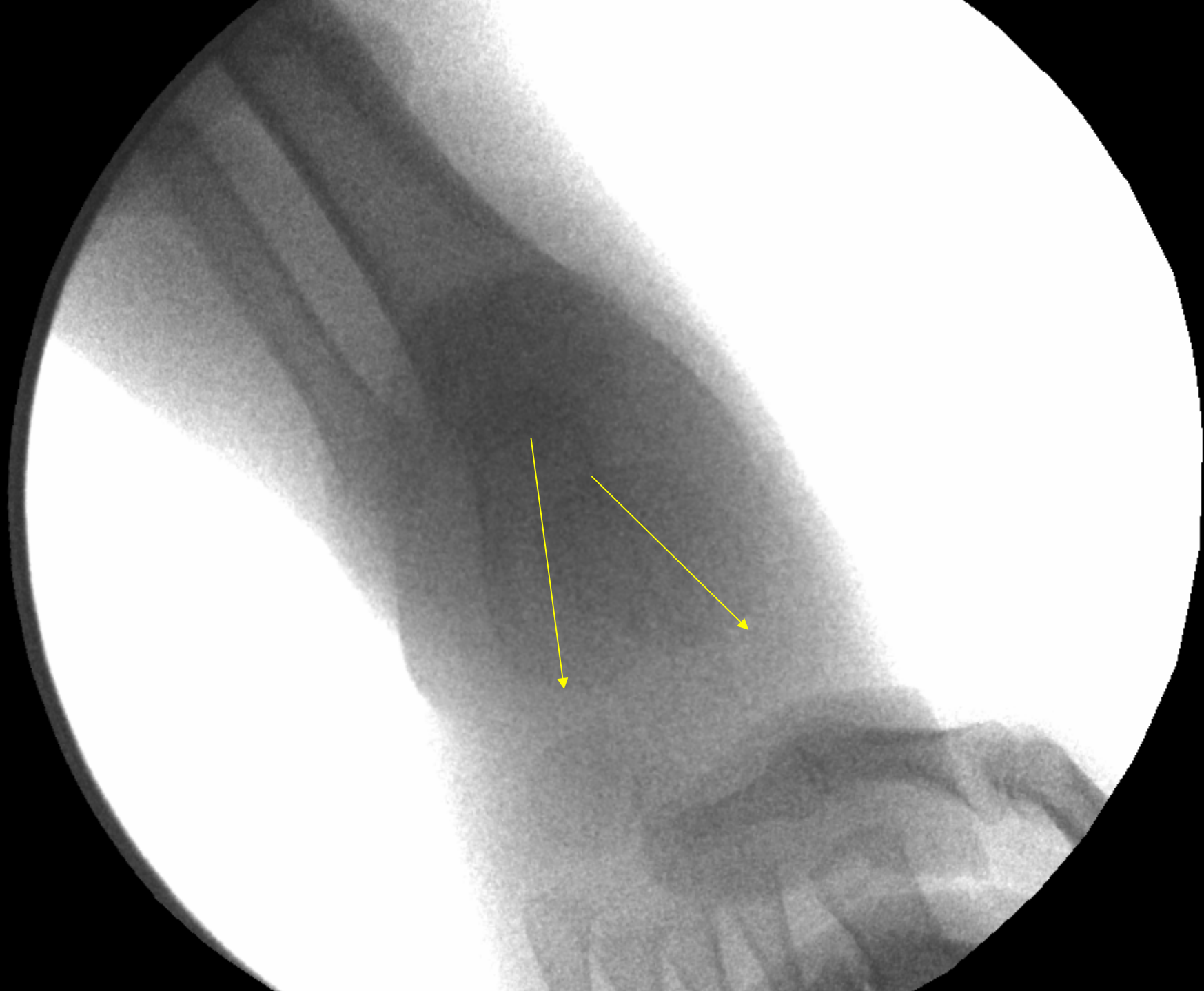


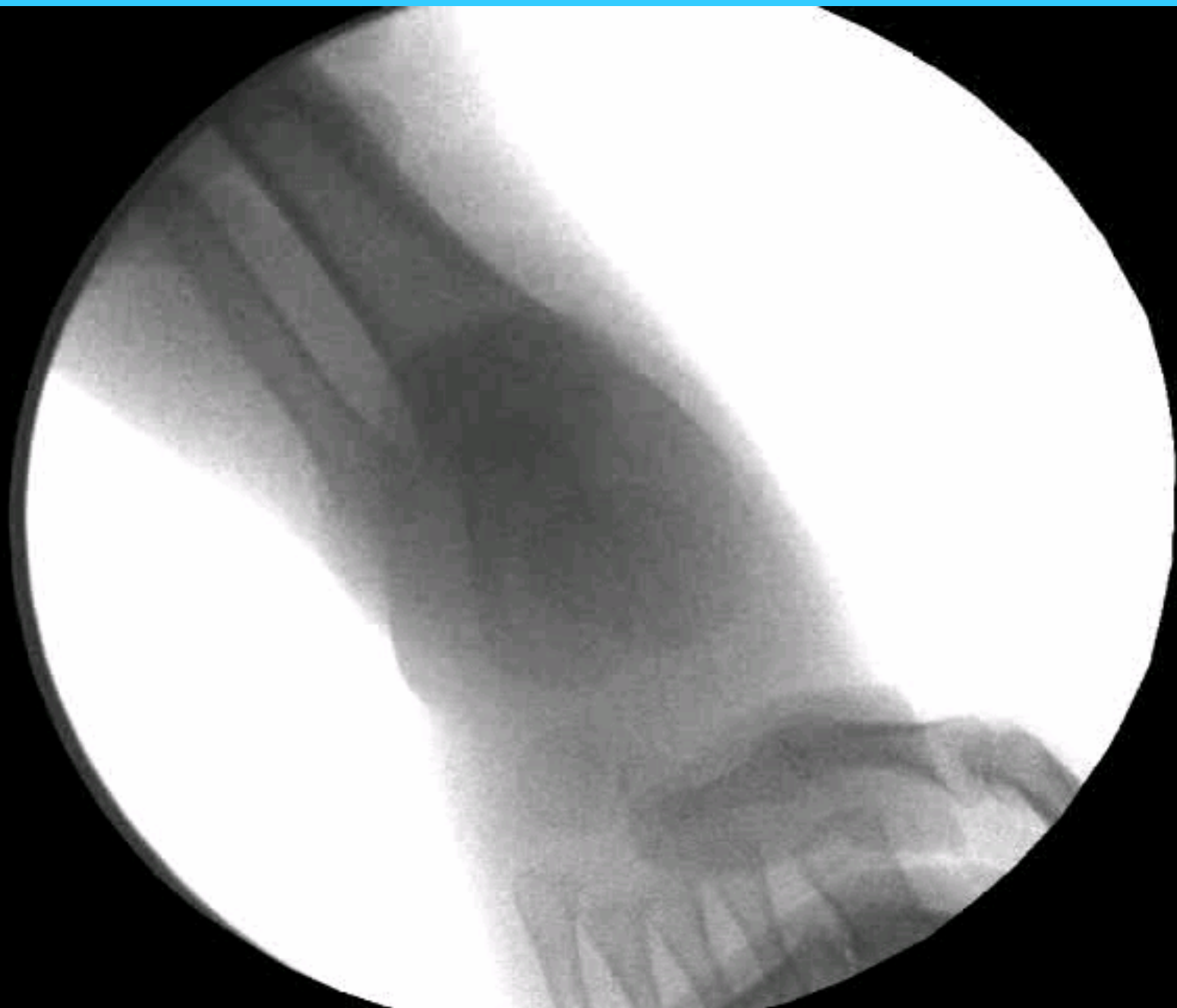
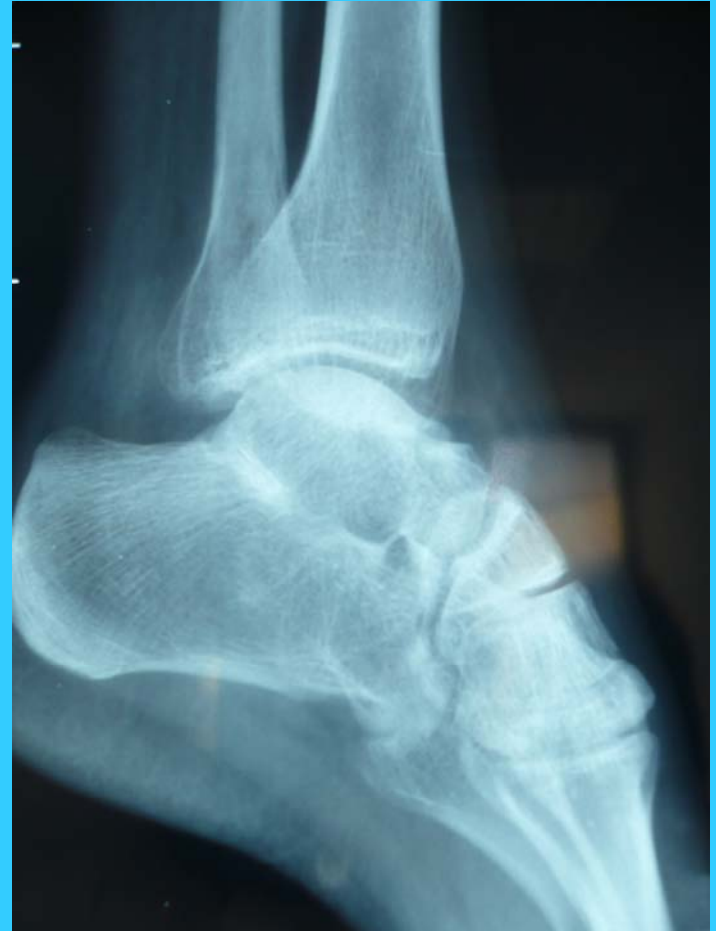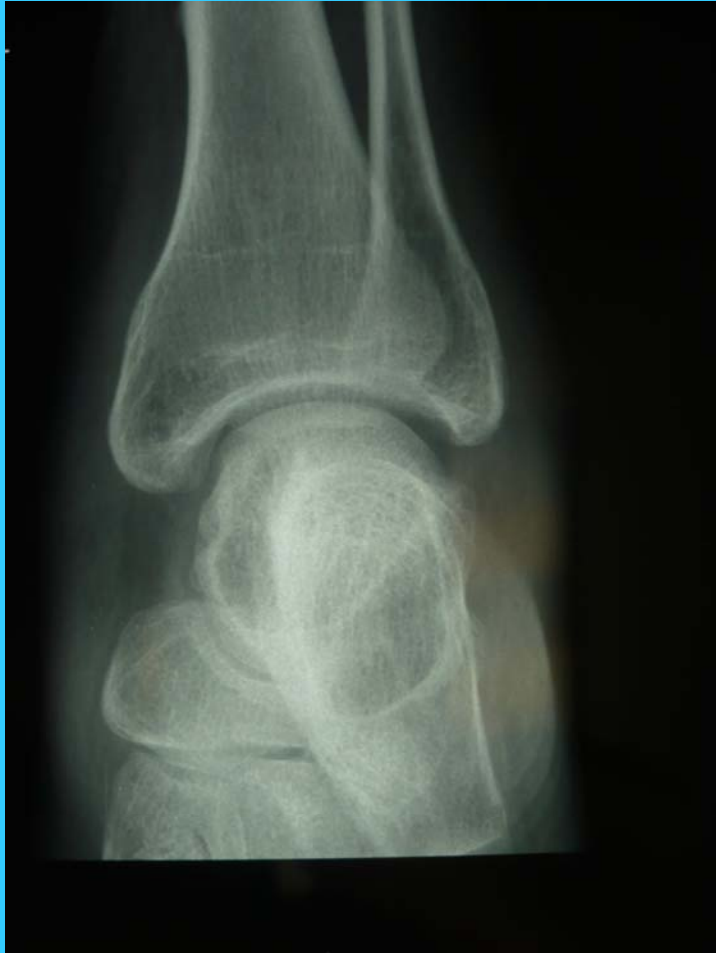A

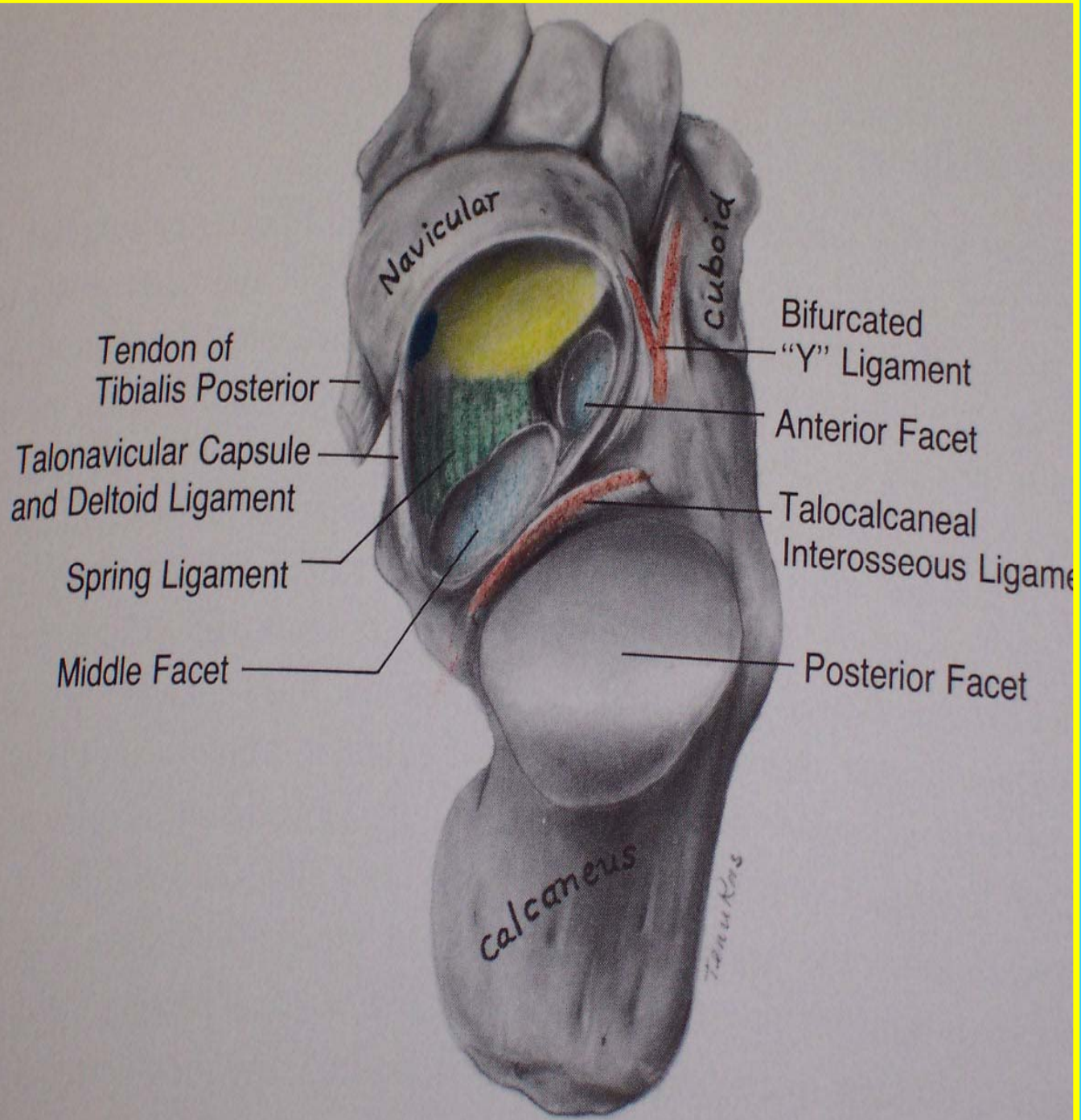


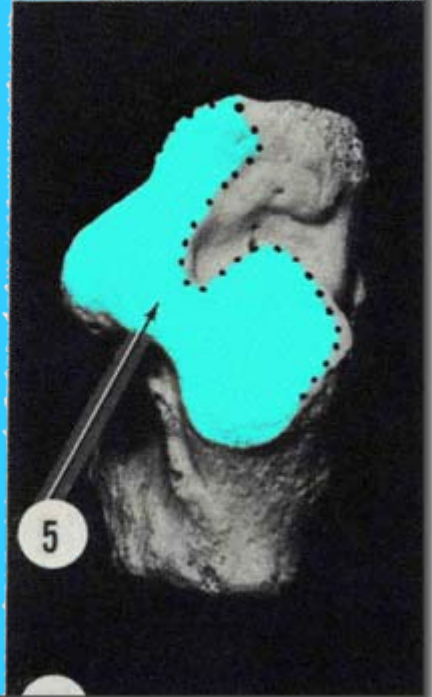
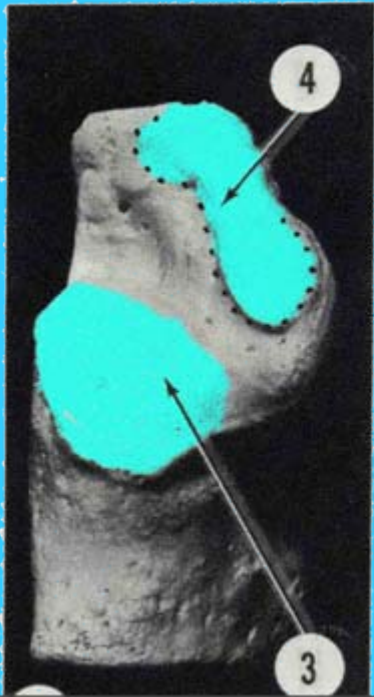
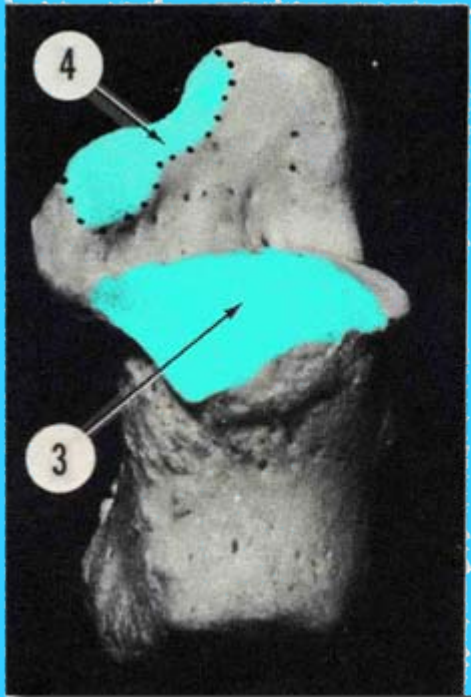
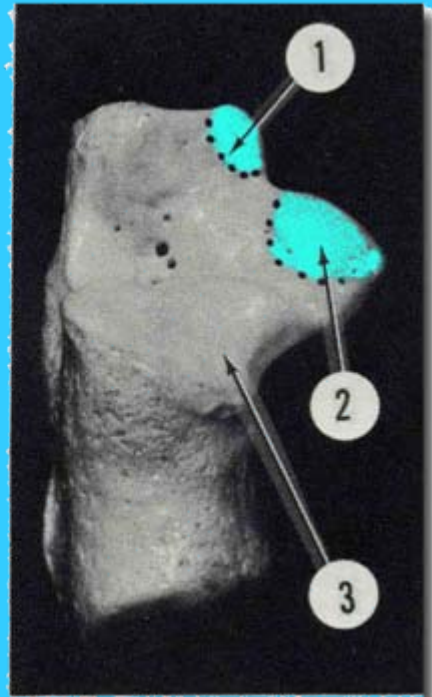
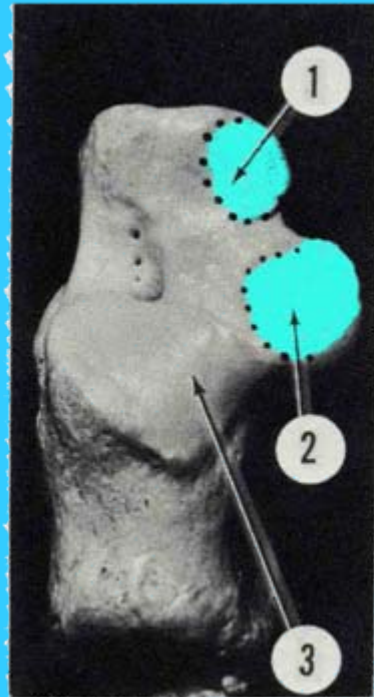
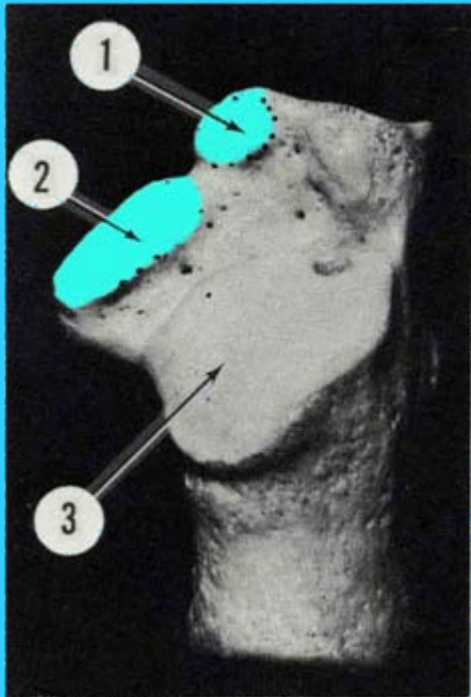


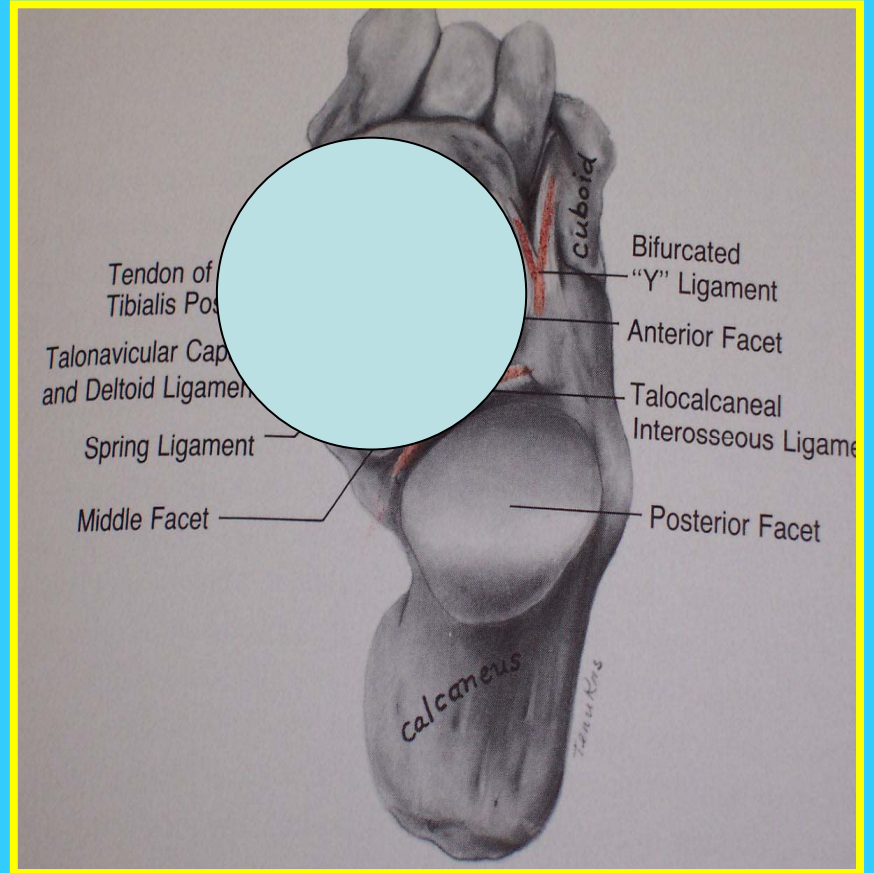


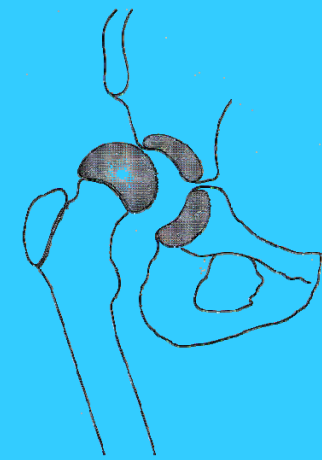




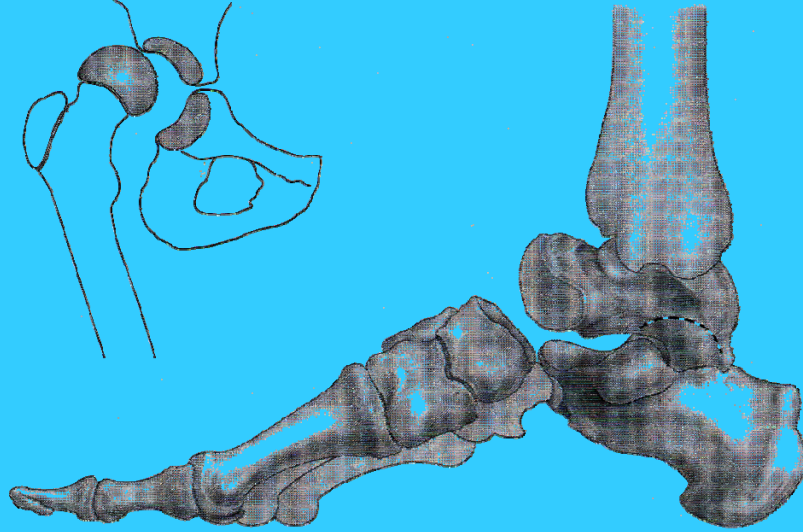




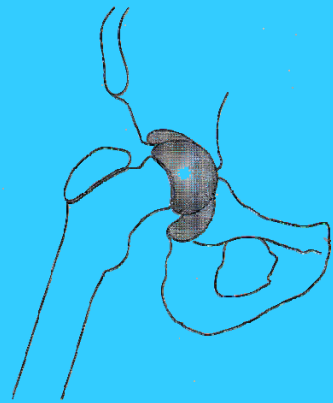




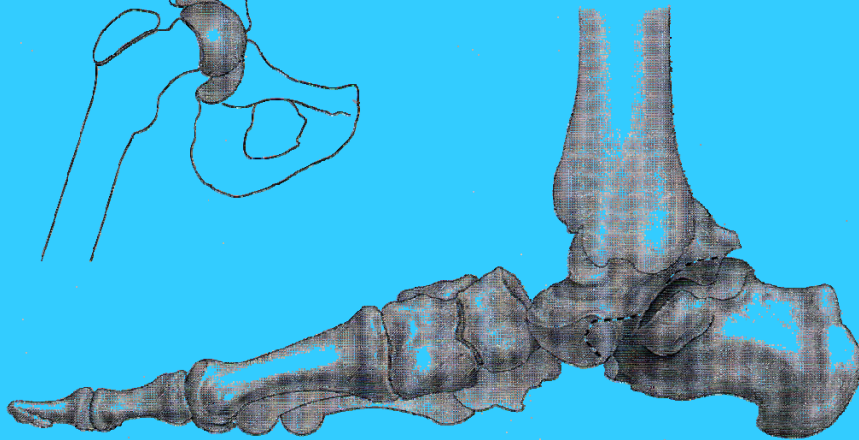
EMC



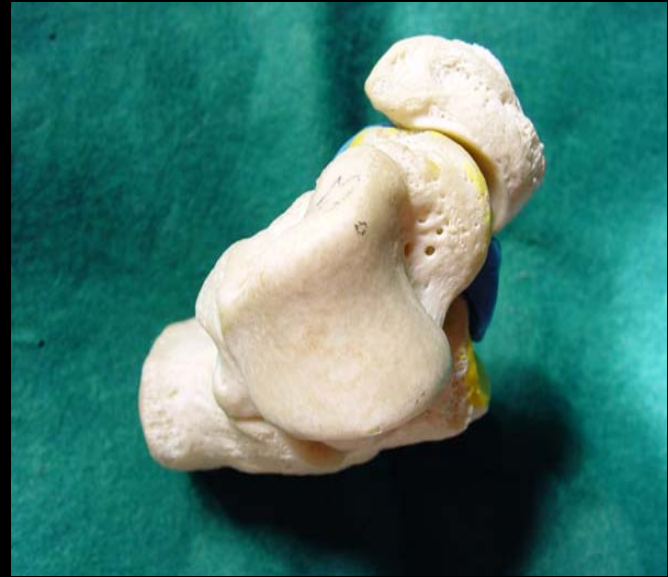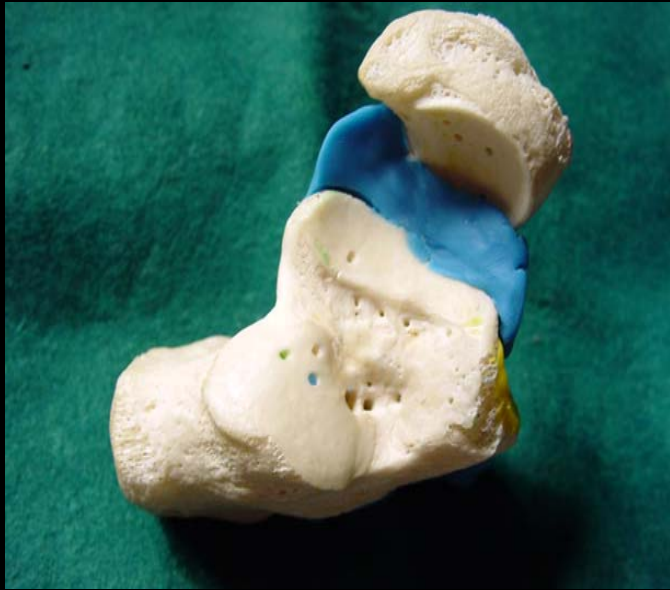MD **A**

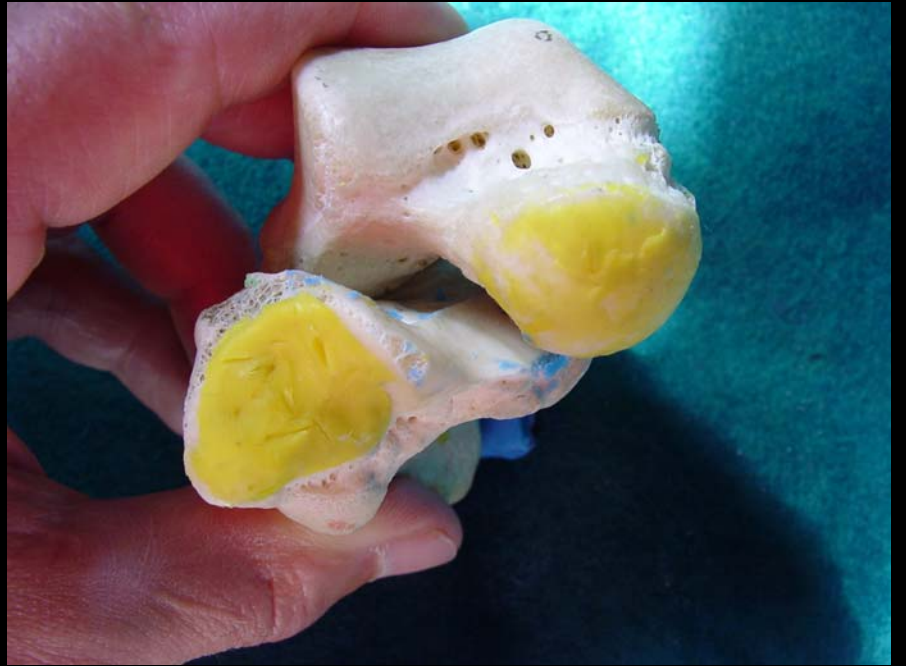
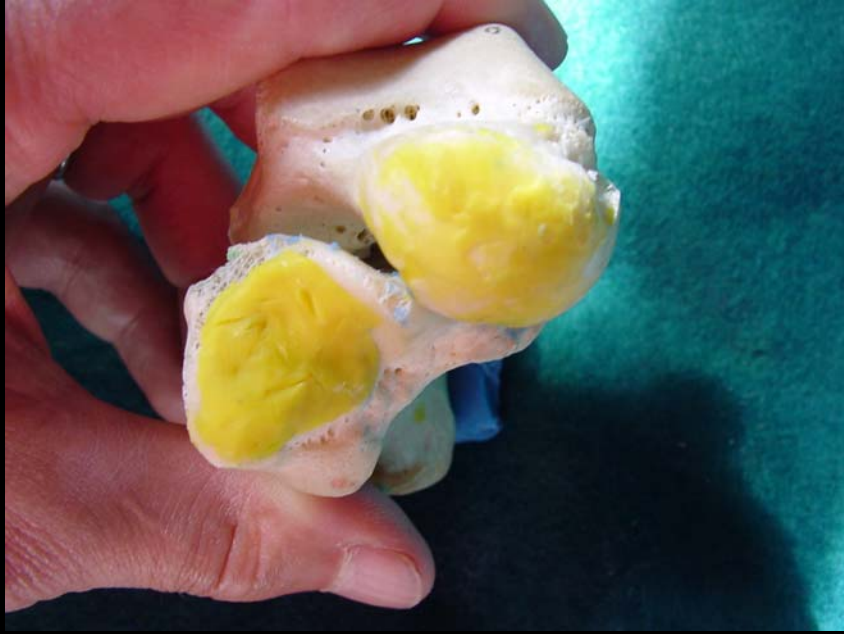
EMC



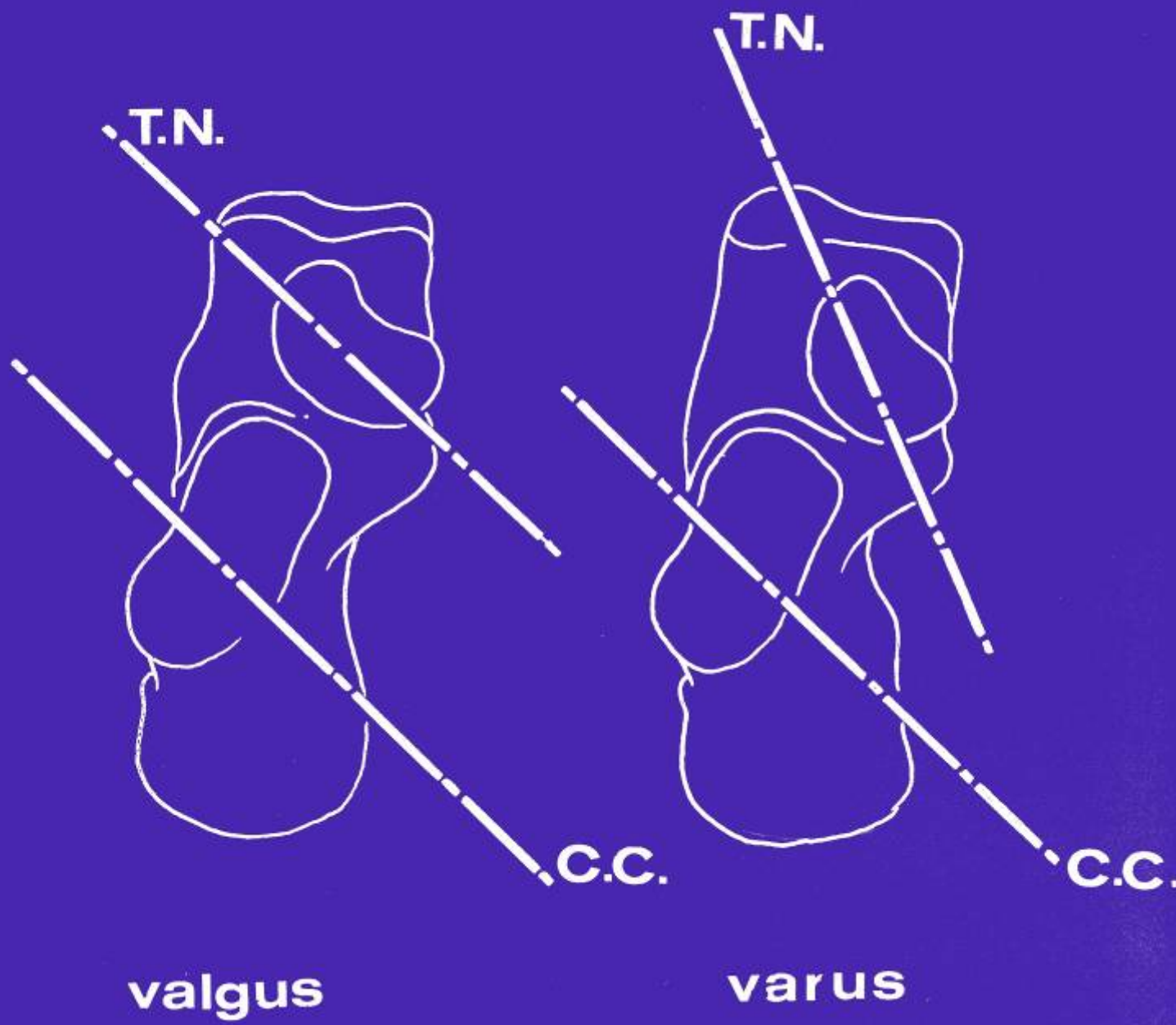
B





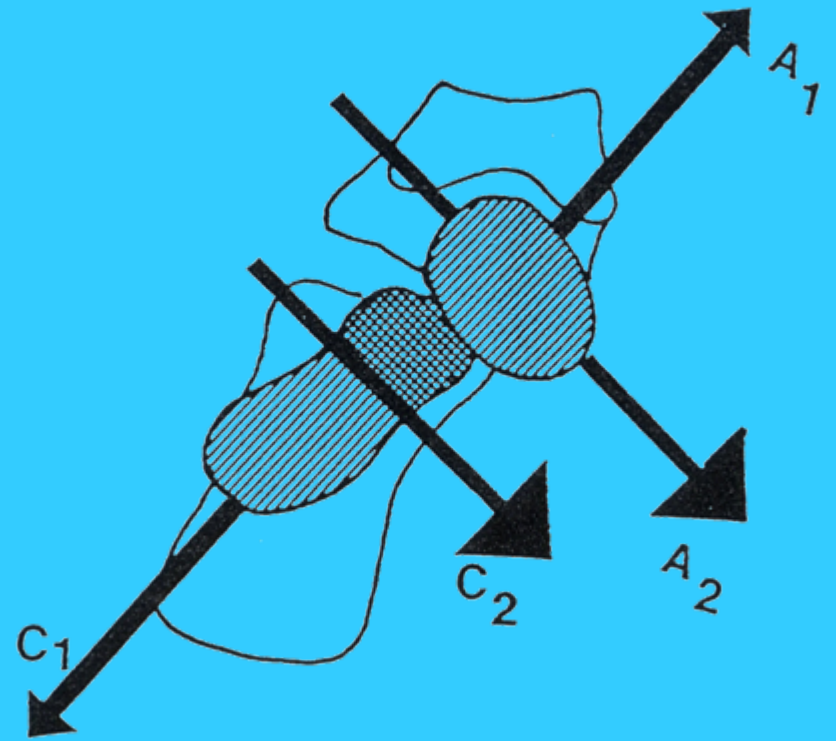
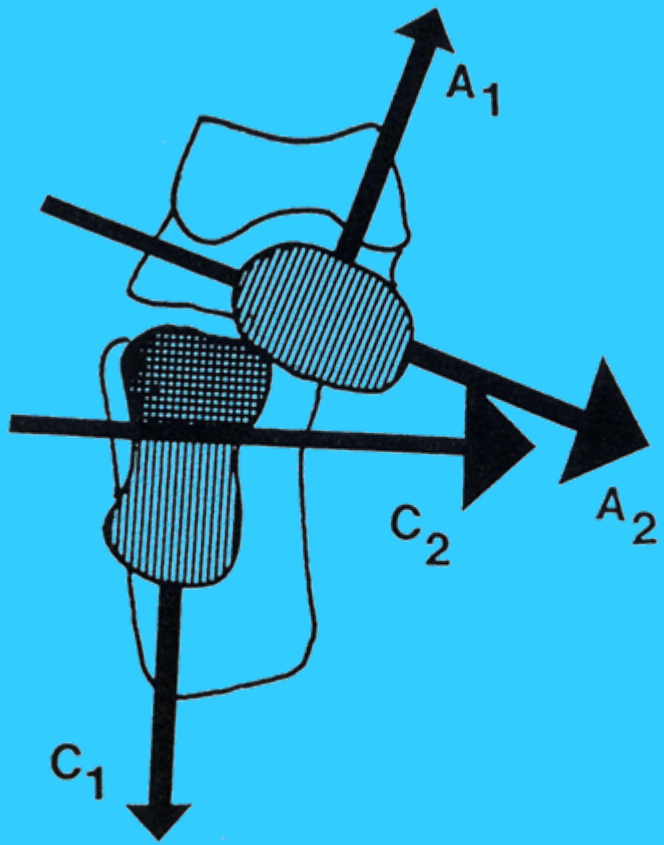


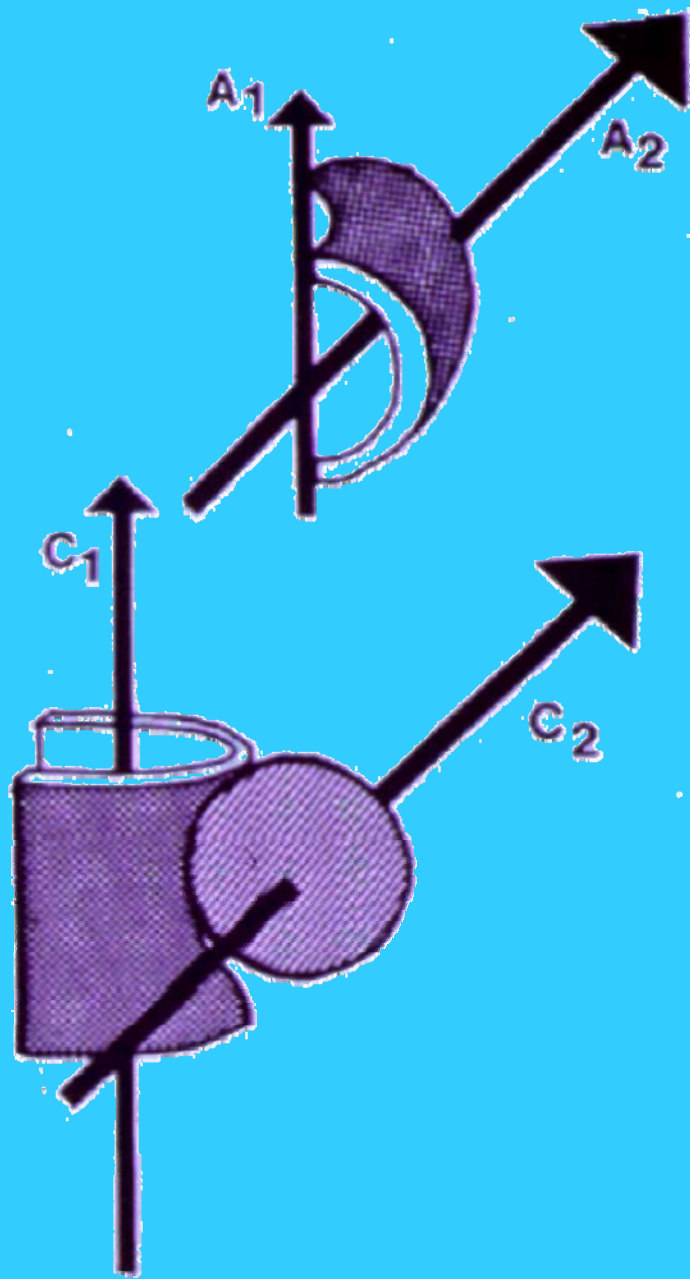
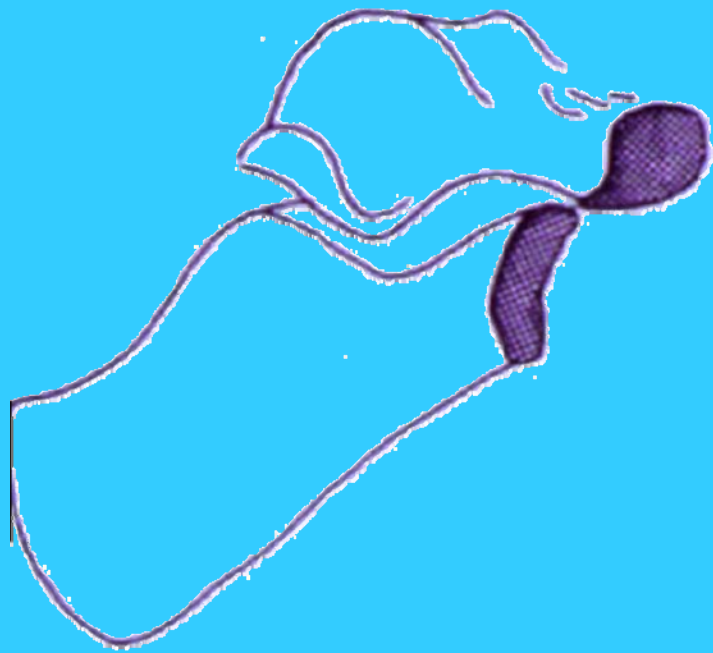
VERROUILLAGE MEDIO TARSE



valgus

varus





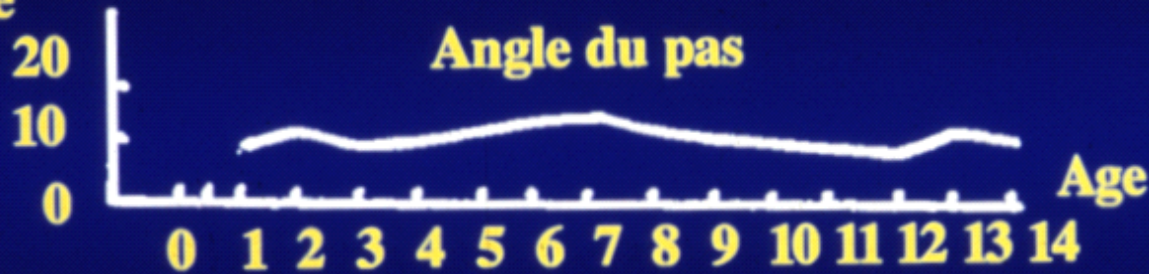
INTERDEPENDANCE

Squelette sus jacent

Rotation globale de hanche



Degré

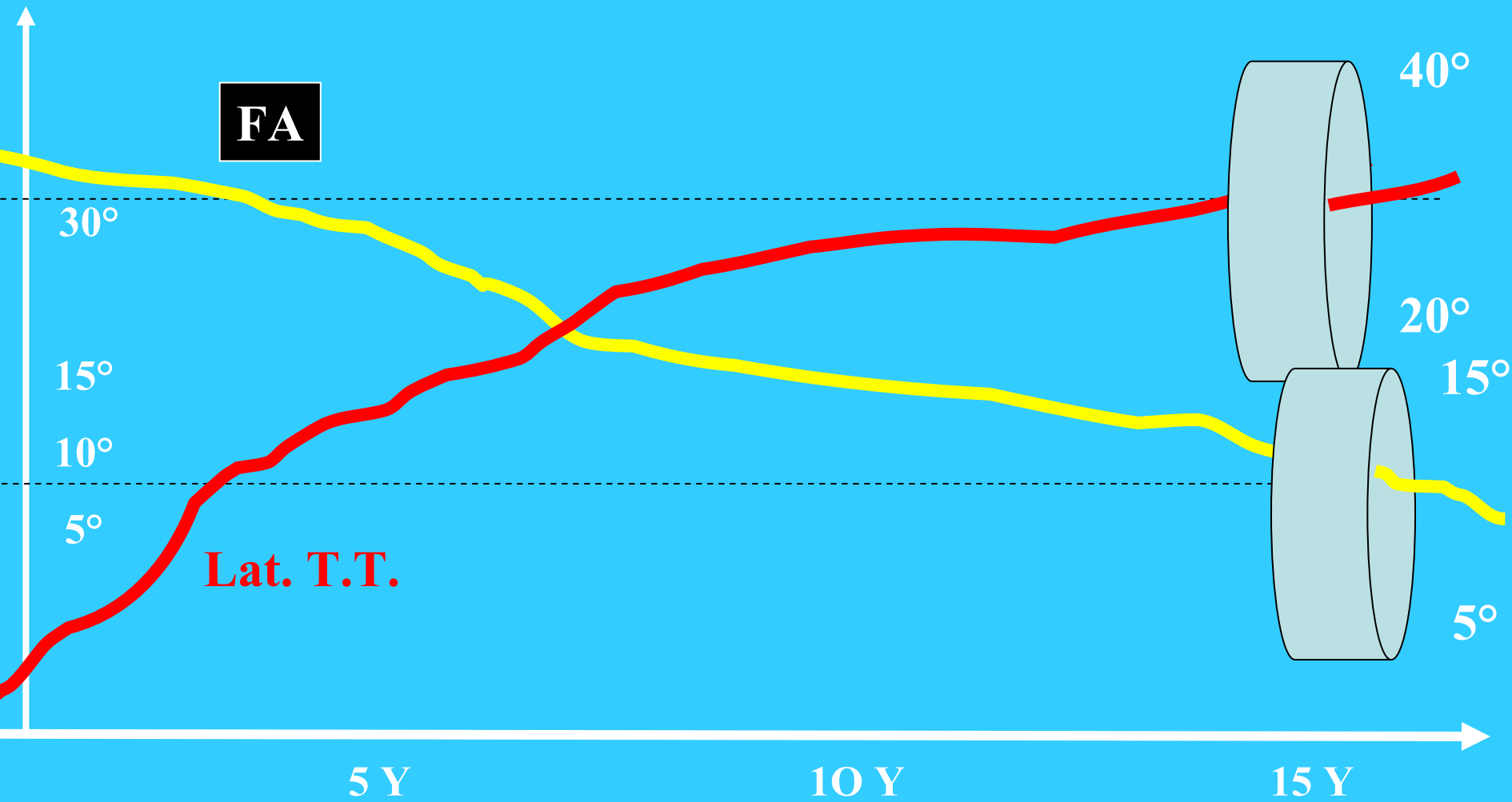


Ratio

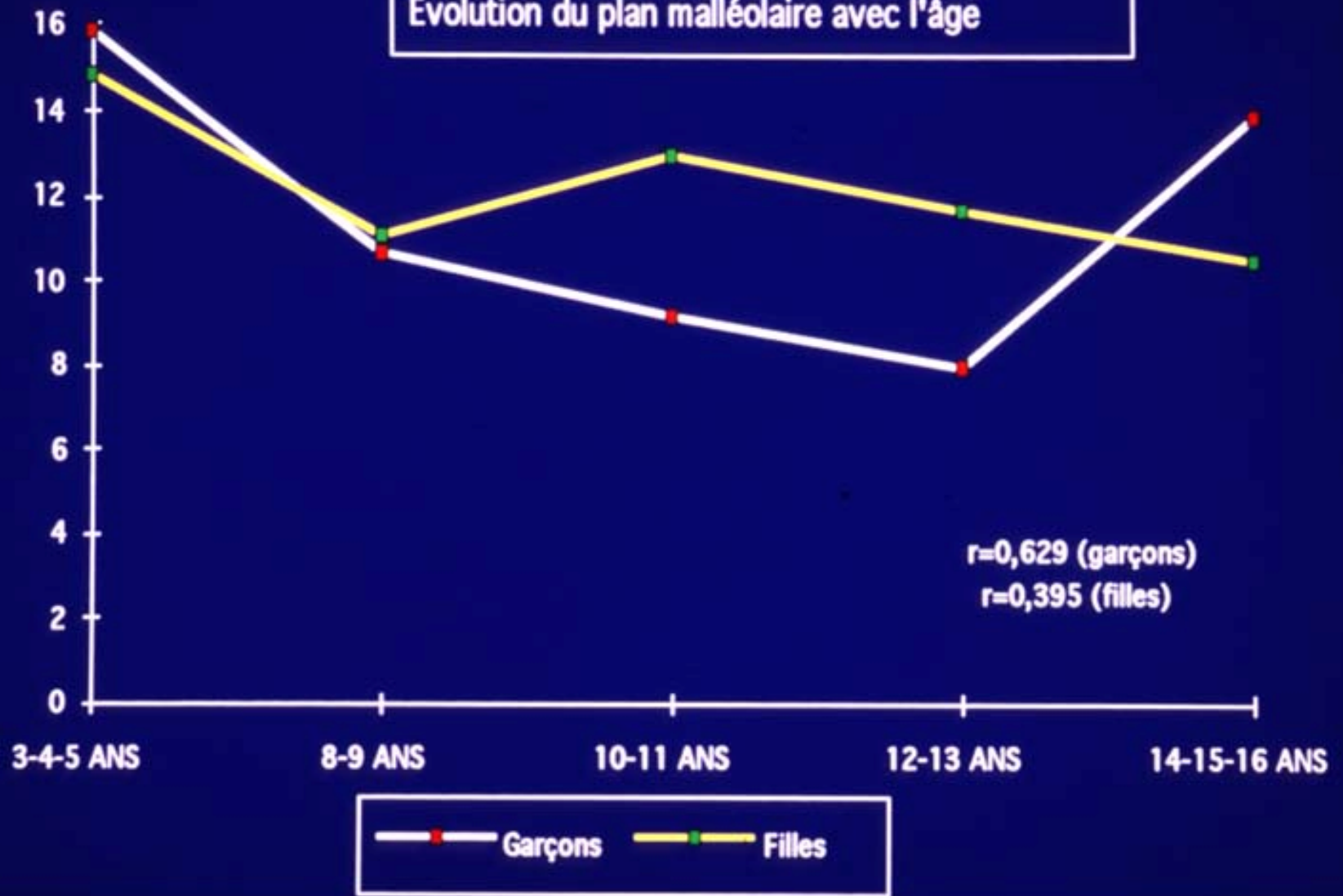


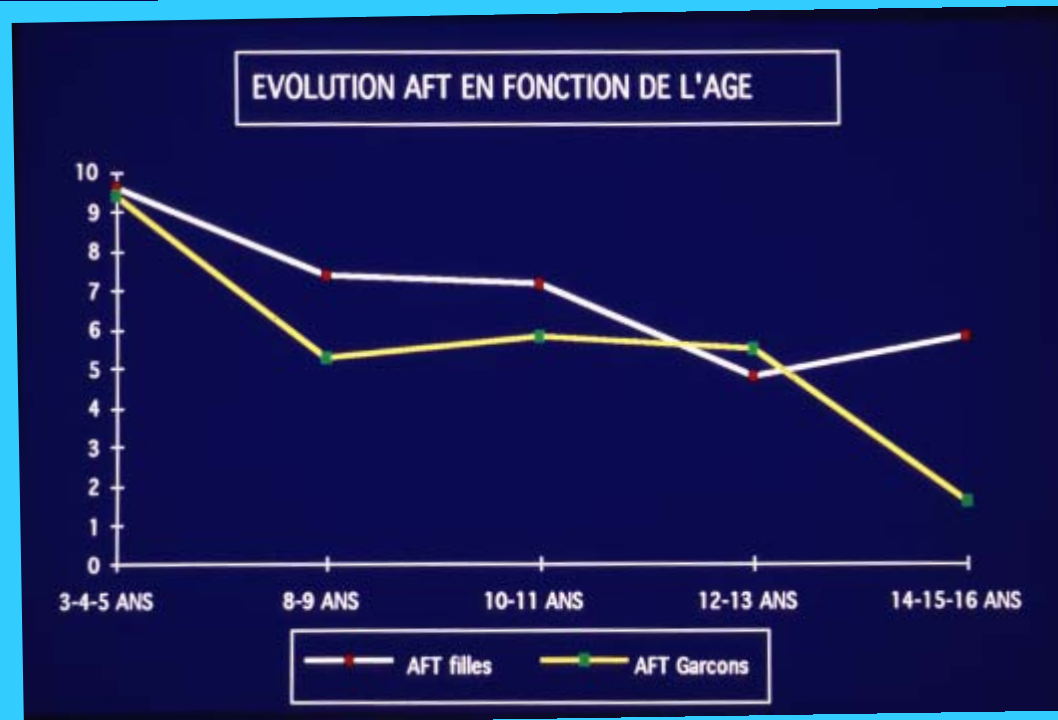
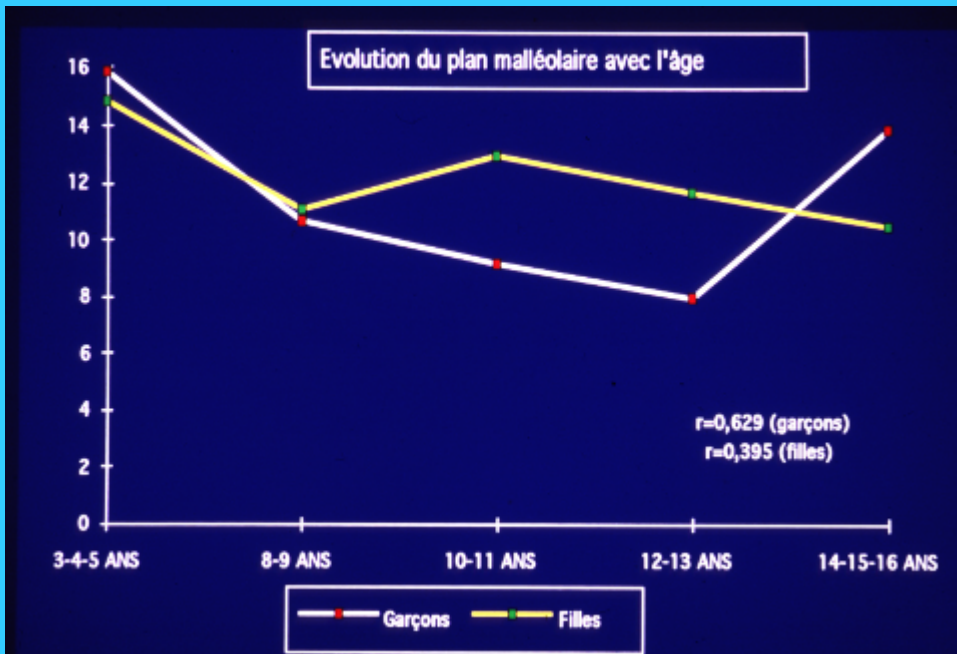
Courbes de Engel : 160 enfants normaux

Evolution of the normal femoral and tibial torsion / age



Evolution du plan malléolaire avec l'âge



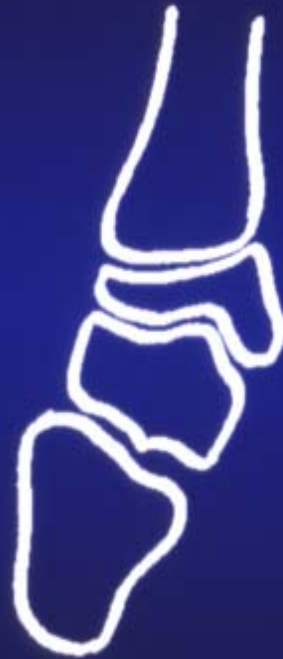

GENU VALGUM



3 ANS

ALIGNE

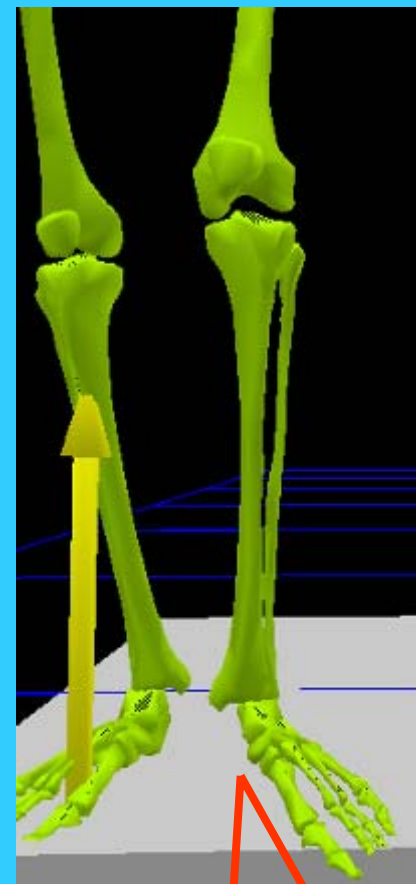
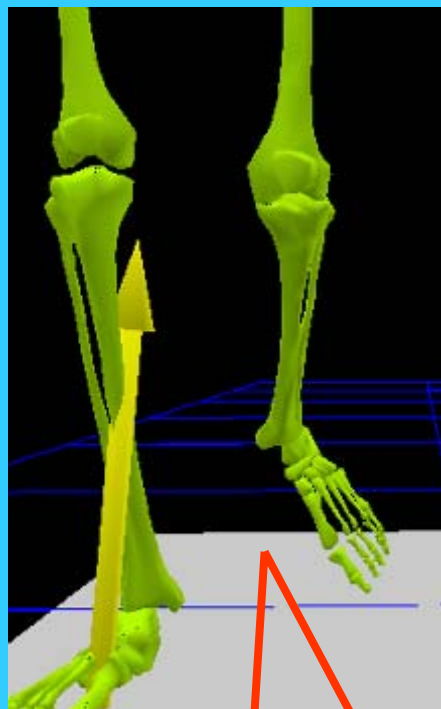
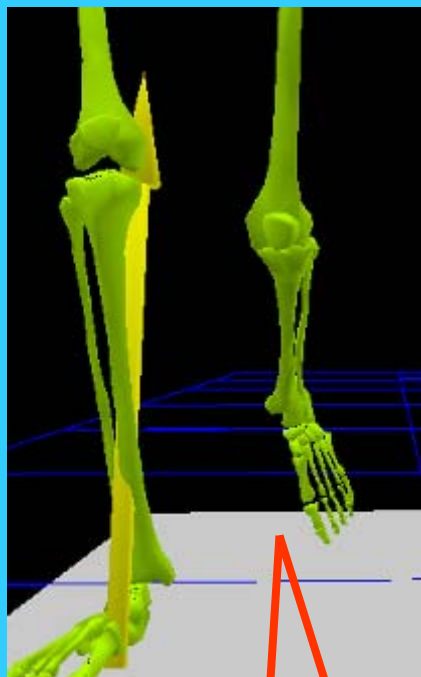
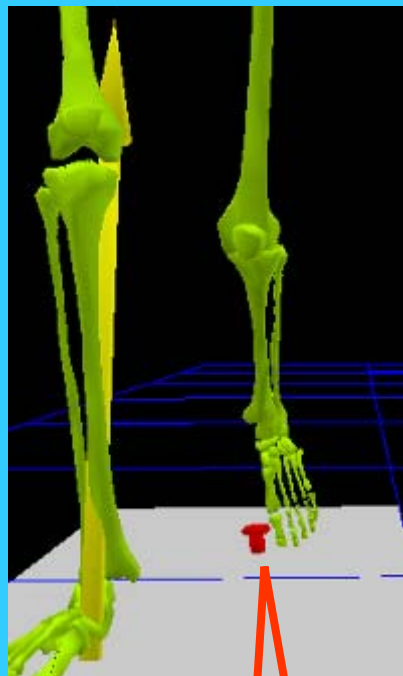


2 ANS

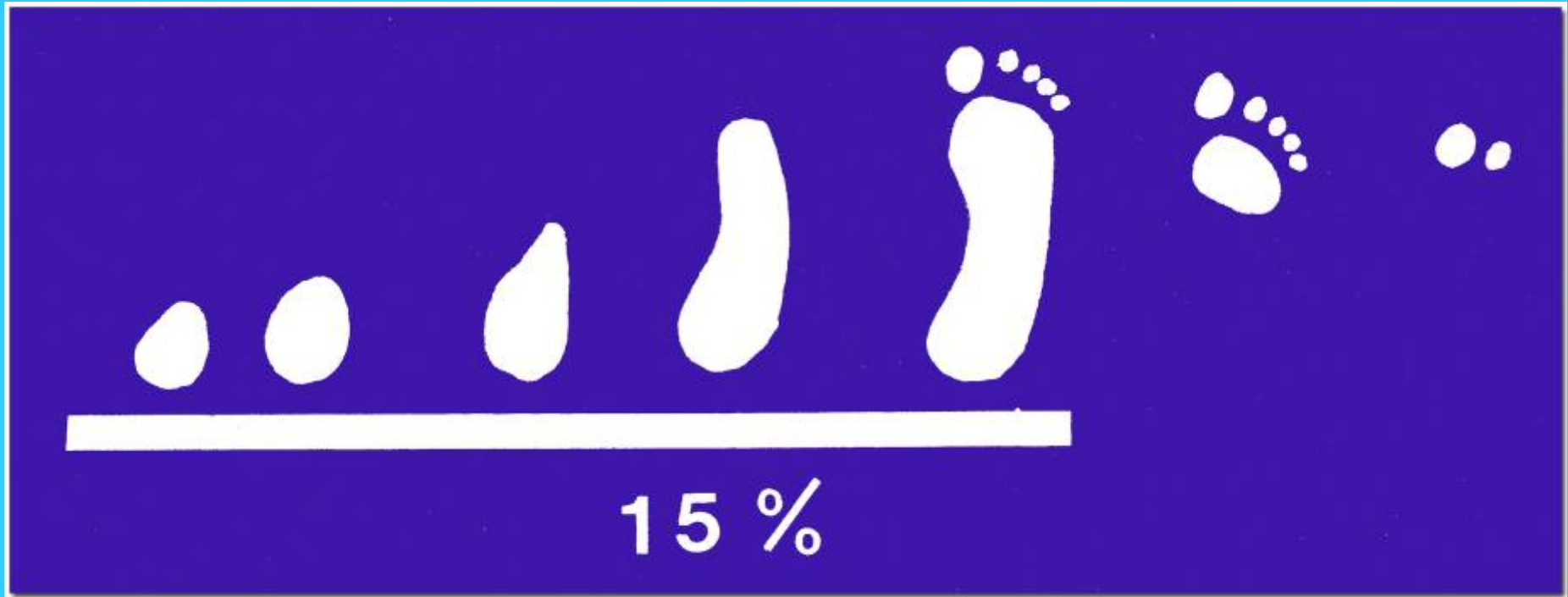
GENU VARUM

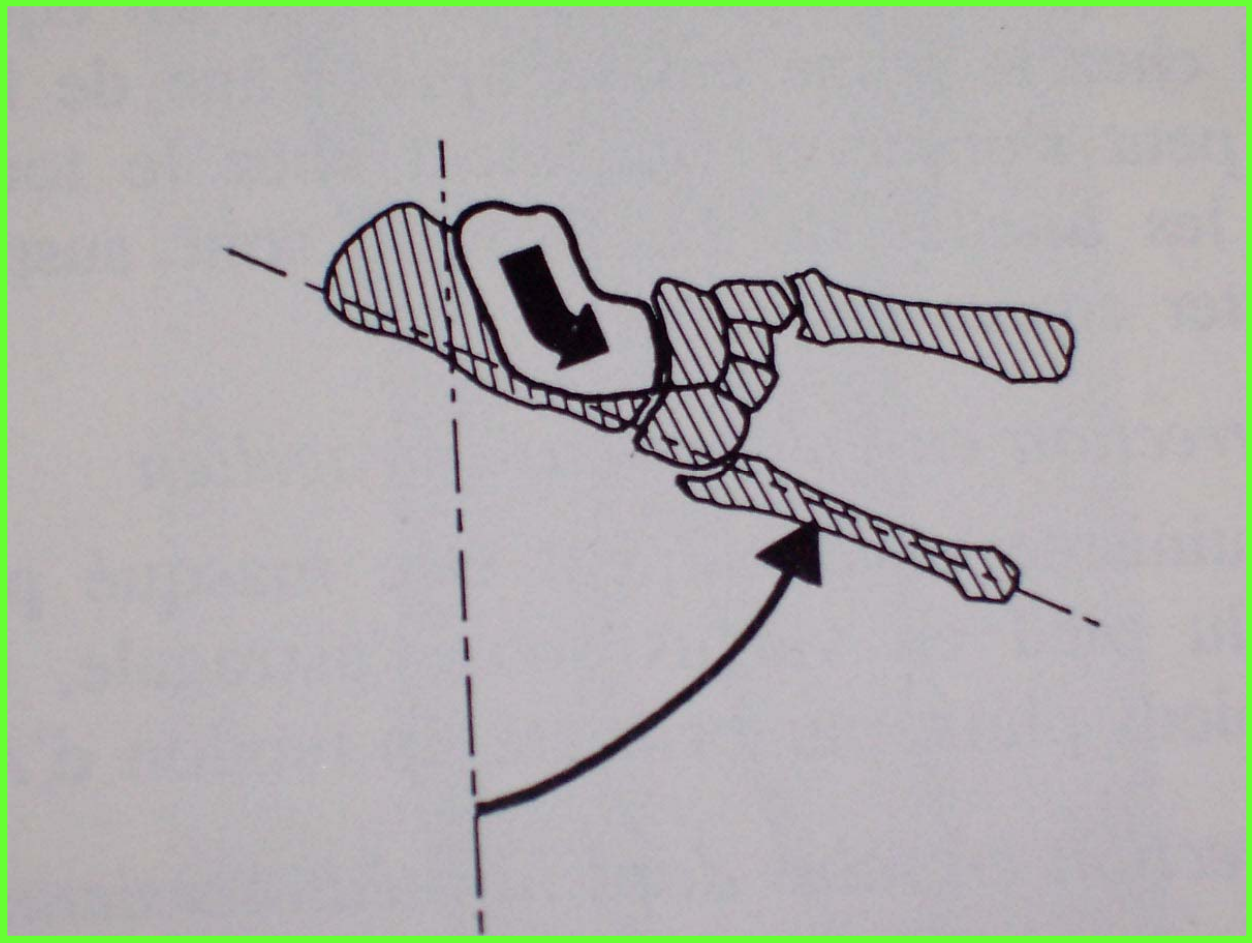



1 AN







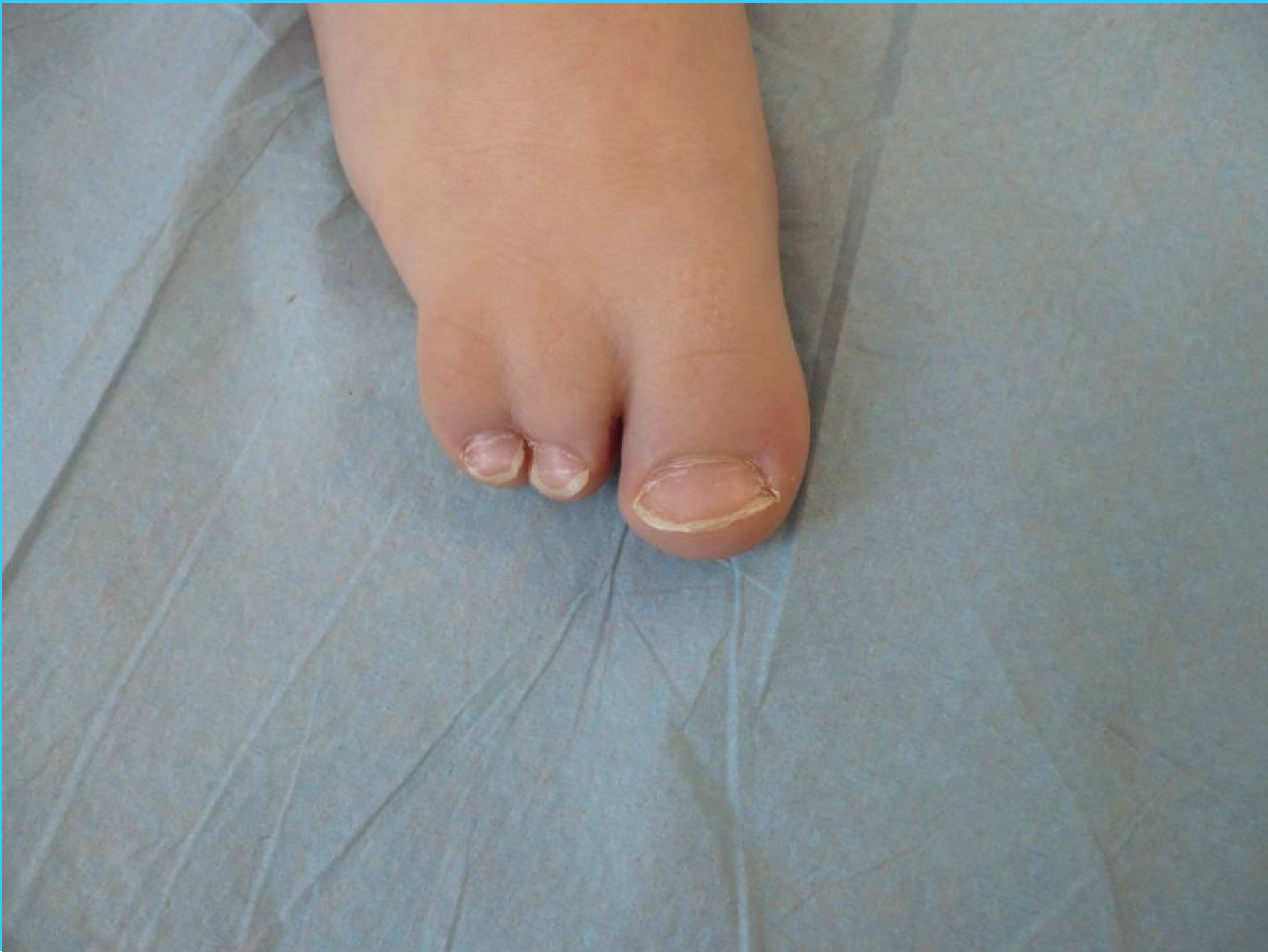






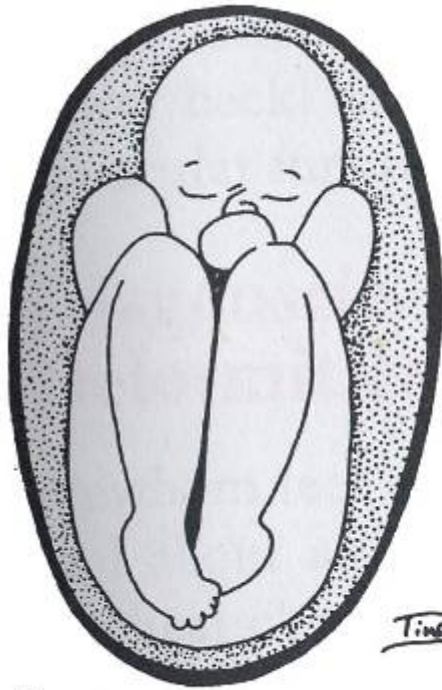CENTRE HOSPITALIER UNIVERSITAIRE
DE LIMOGES







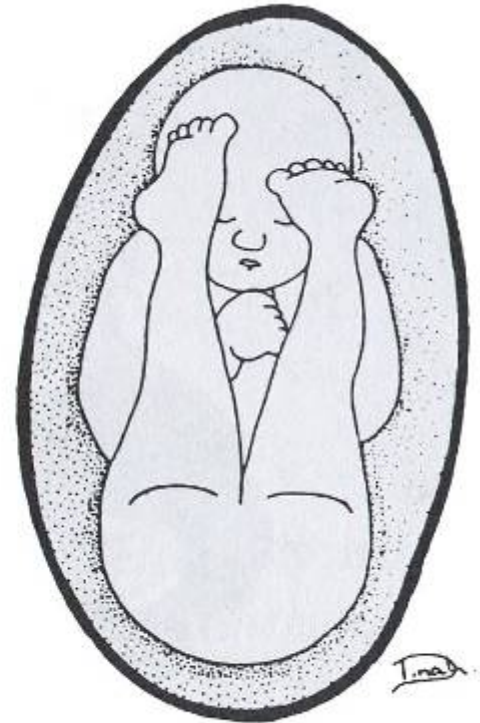CENTRE HOSPITALIER UNIVERSITAIRE
DE LIMOGES



Tina D.

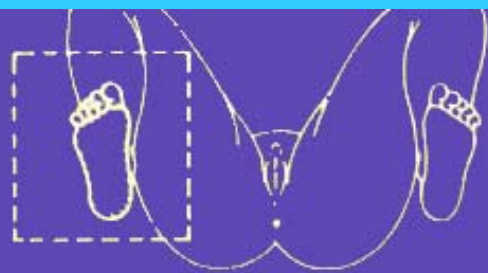

Tina D.



Tina D.

A

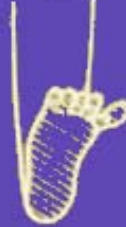

**PIED TALUS
PHYSIOLOGIQUE**

**PRESSION
INTERNE**

**PRESSION
DIRECTE**

**PRESSION
EXTERNE**



**PIED CONVEXE
CONGENITAL
(irréductible)**

**PIED TALUS
VALGUS
(réductible)**

**PIED TALUS
DIRECT**

**METATARSUS
ADDUCTUS**

**PIED TALUS
SUPINATUS**

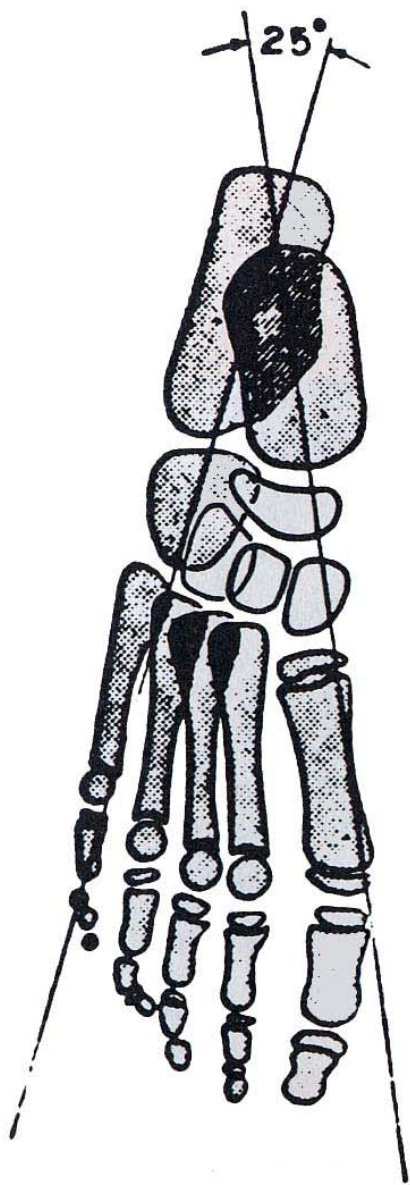
**PIED
VARUS
(réductible)**

**PIED BOT
VARUS EQUIN
(irréductible)**

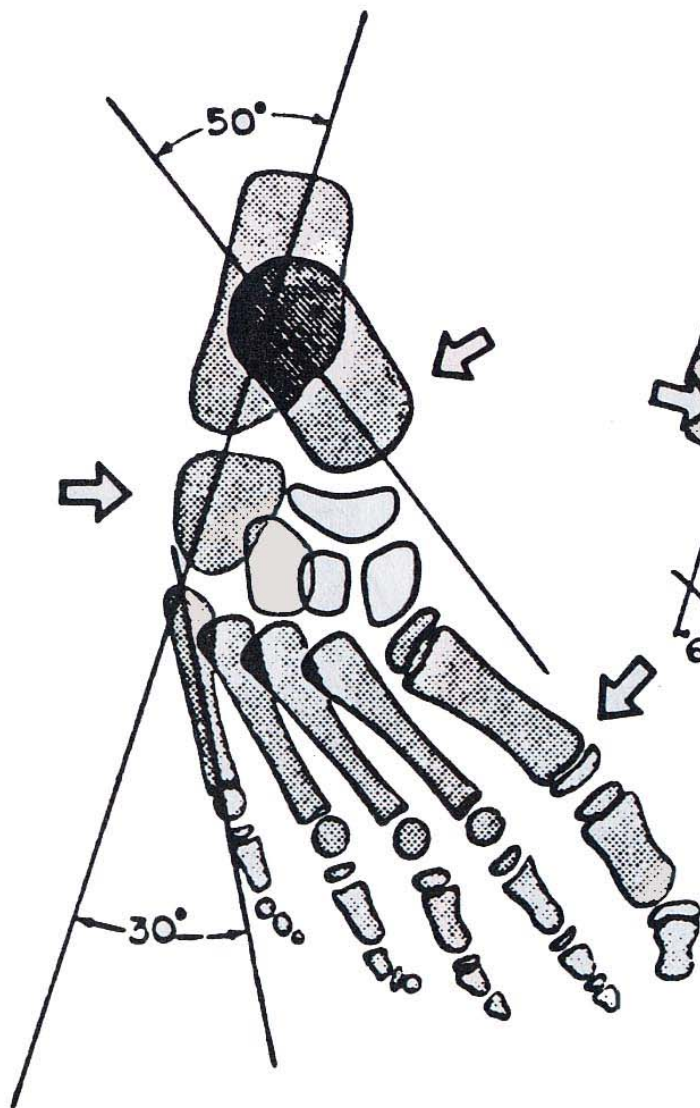
**ARRIÈRE - PIED
BLOQUÉ EN TALUS**

**EBAUCHE
DE BASCULE**

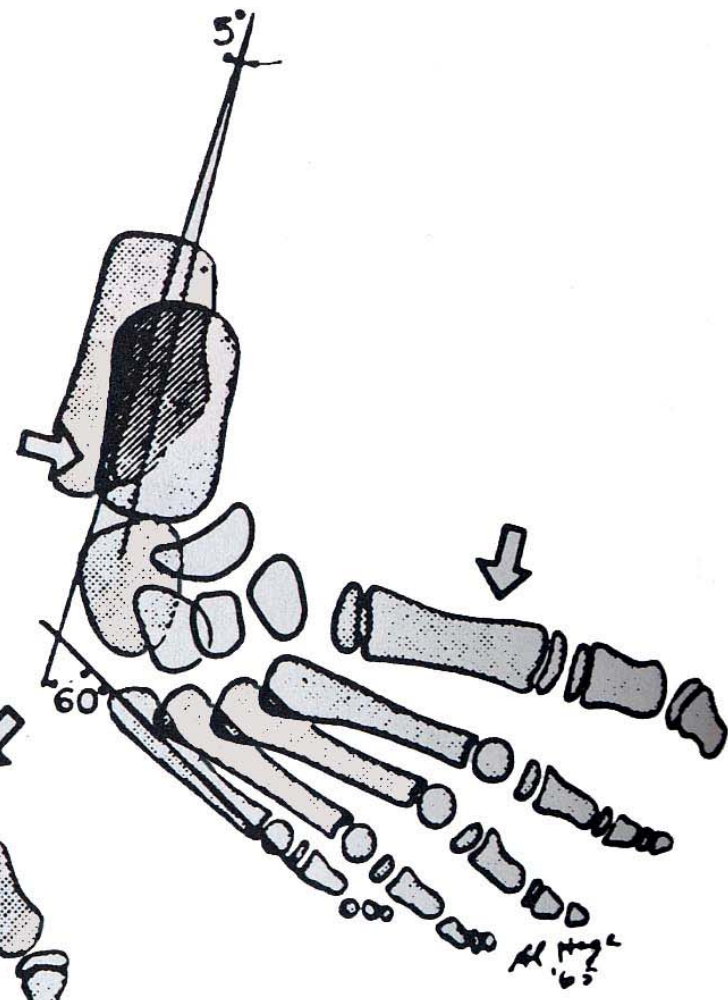
**BASCULE
COMPLÈTE**




NORMAL




MET. VARUS

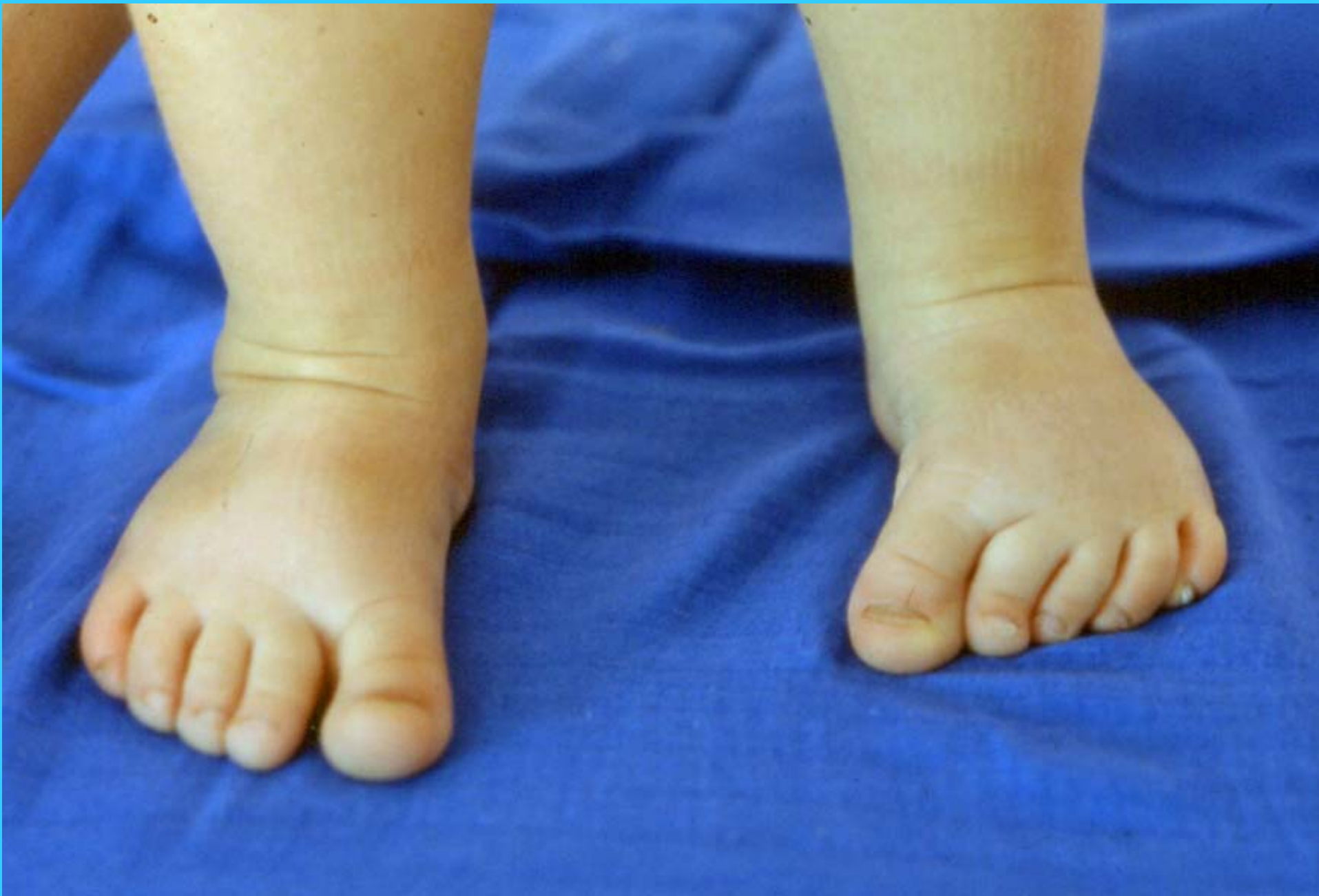

CLUBFOOT

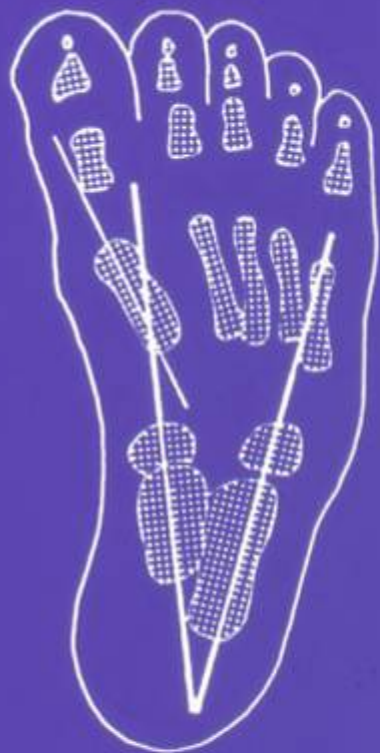











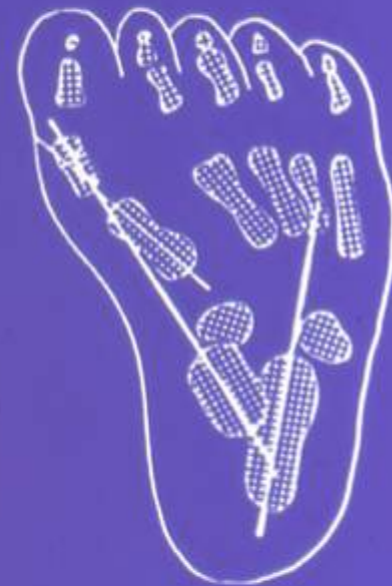A



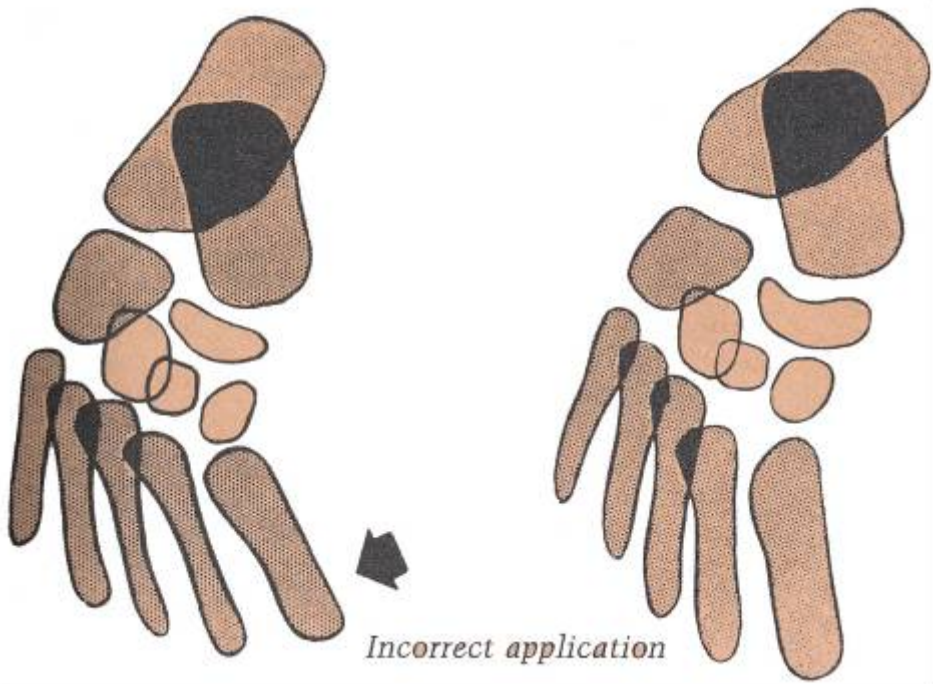
B



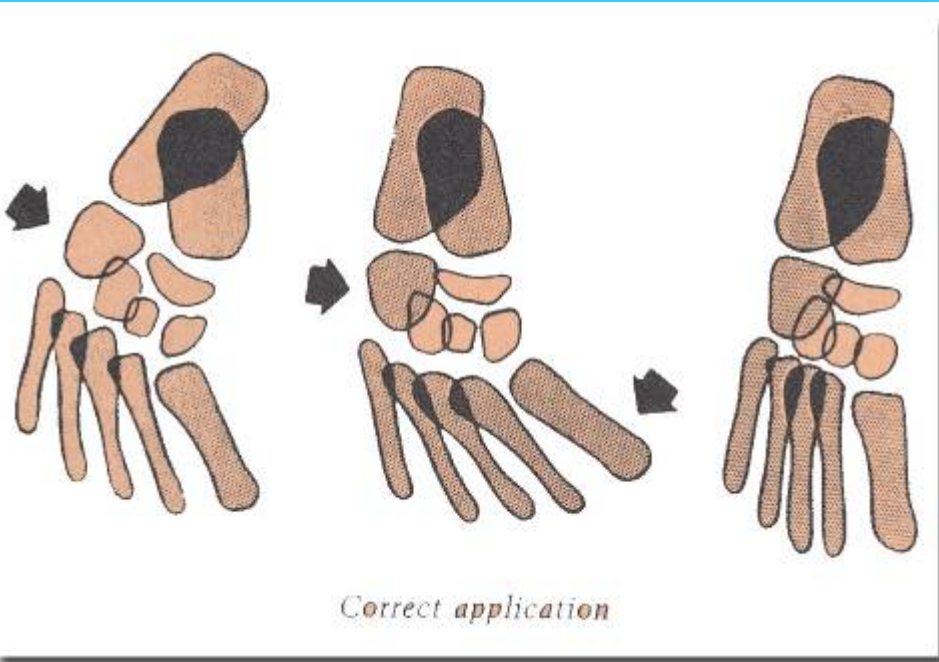
C



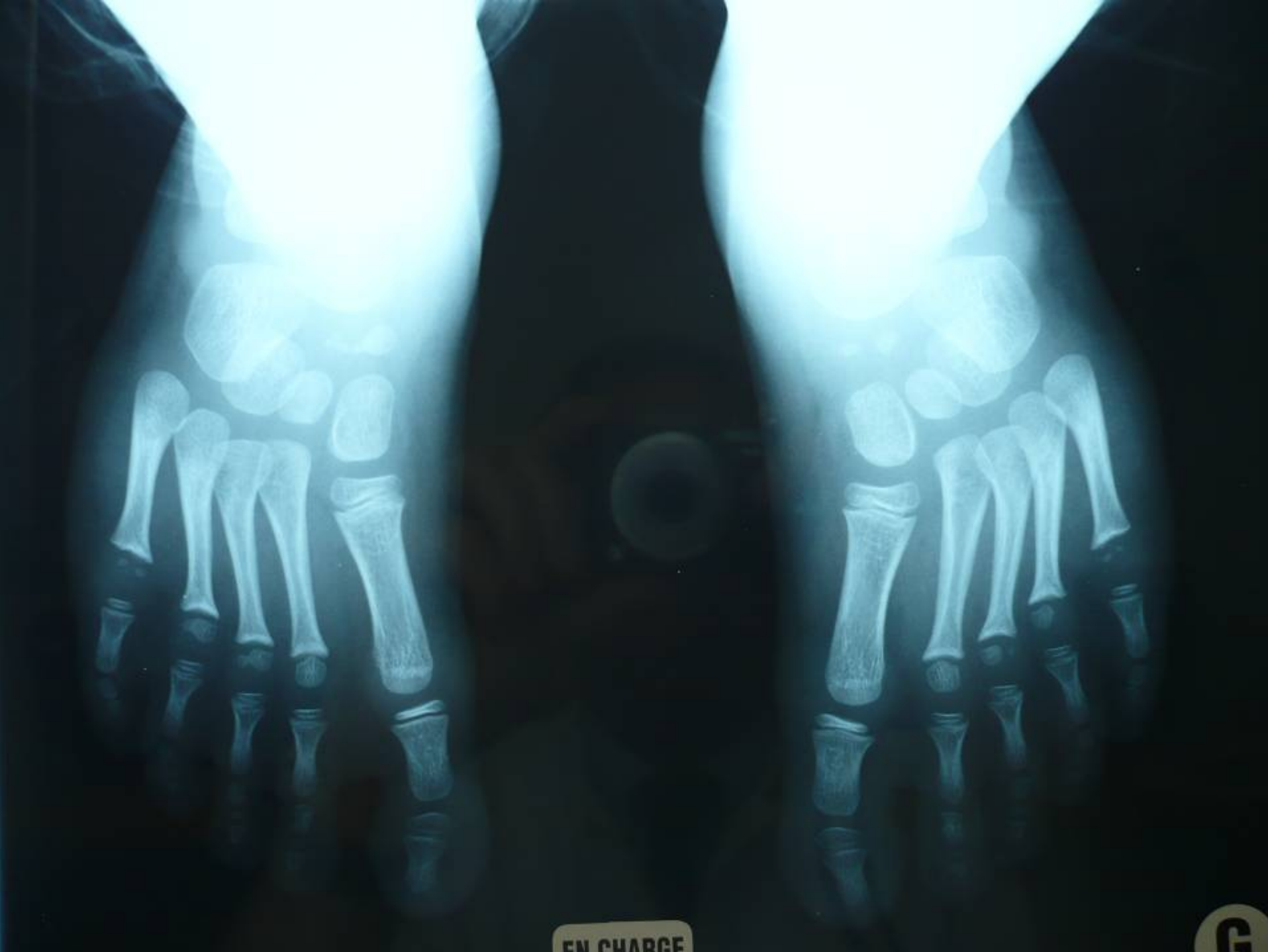D



Incorrect application

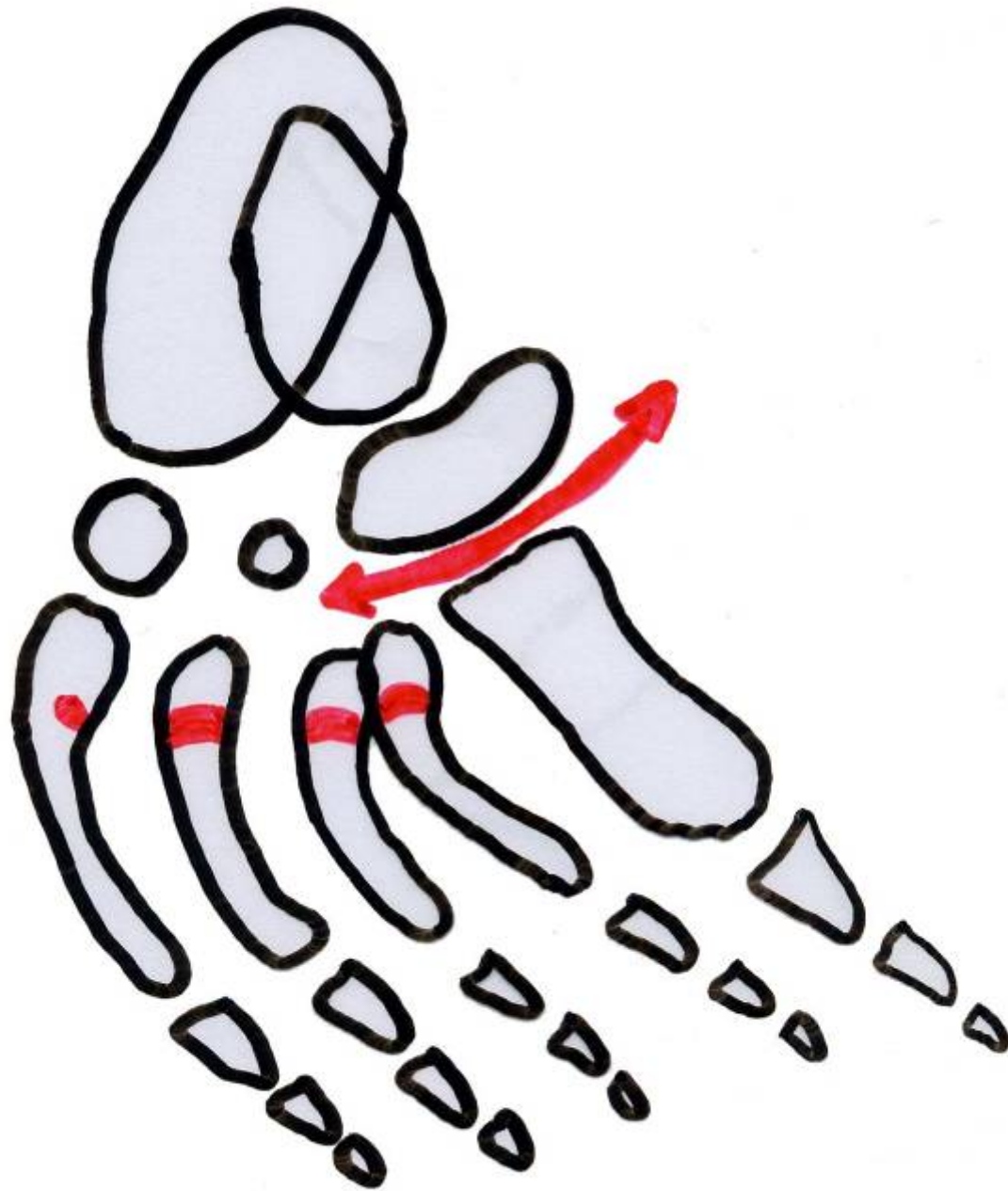


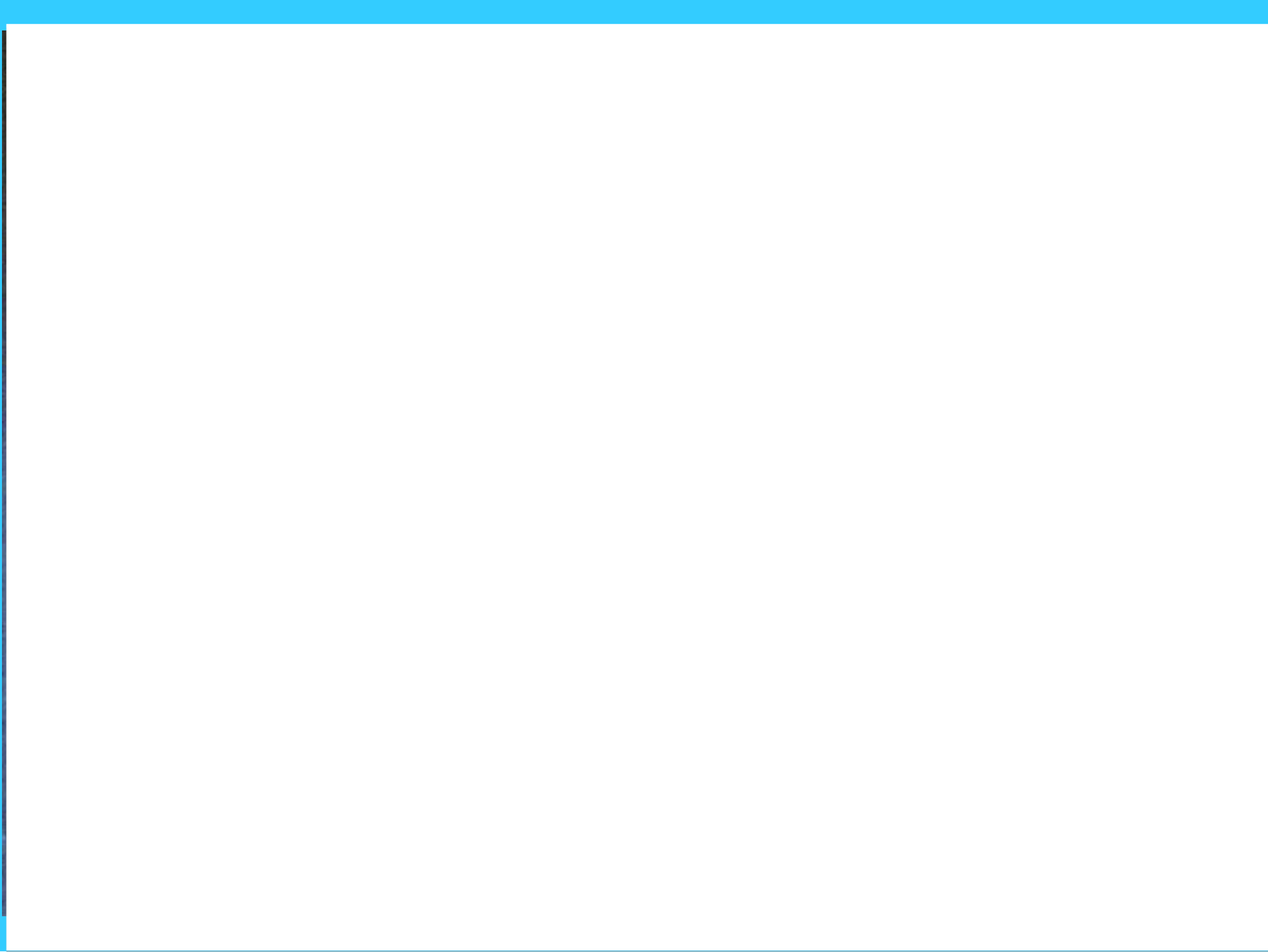
Correct application





EN CHARGE

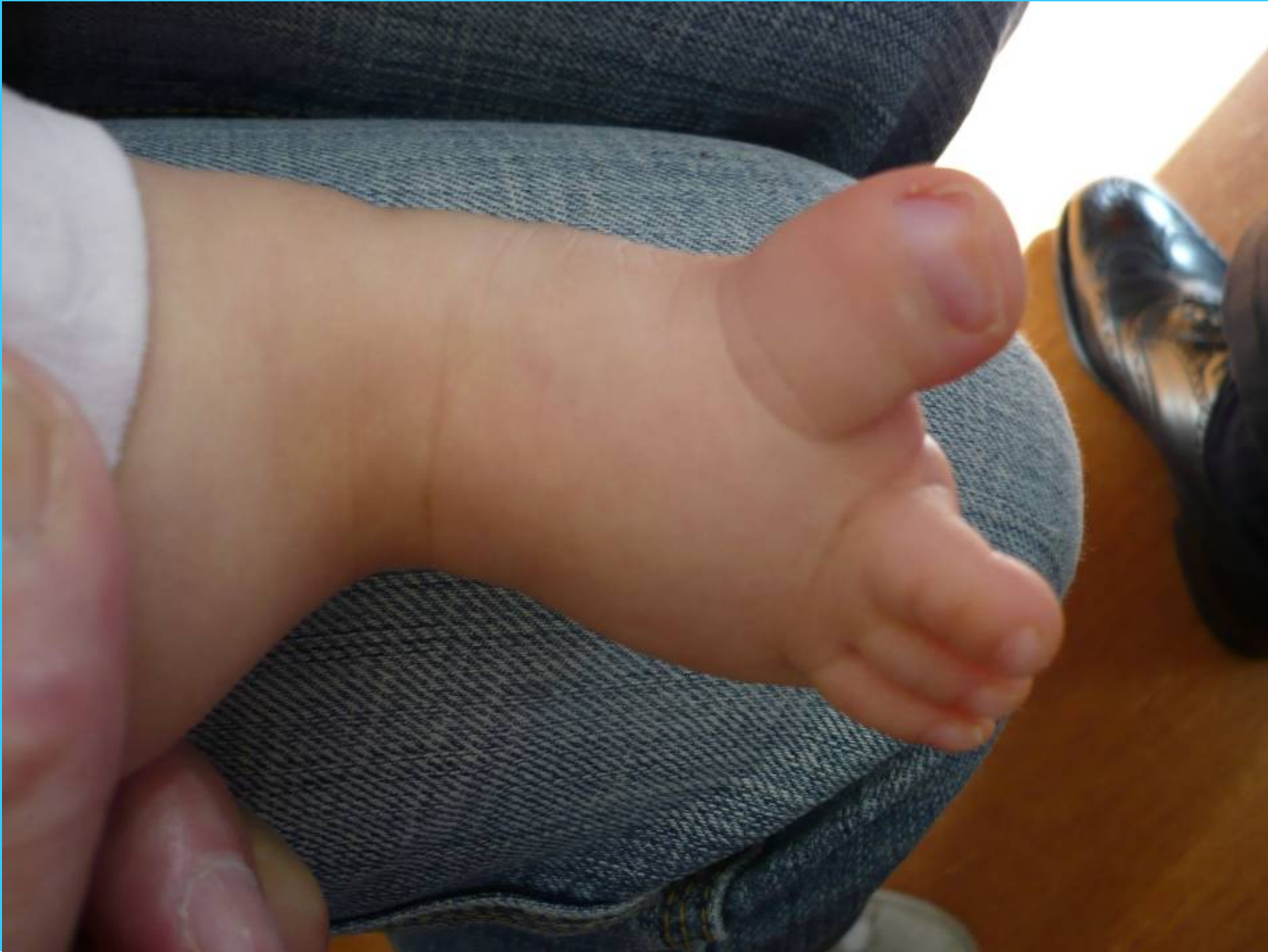


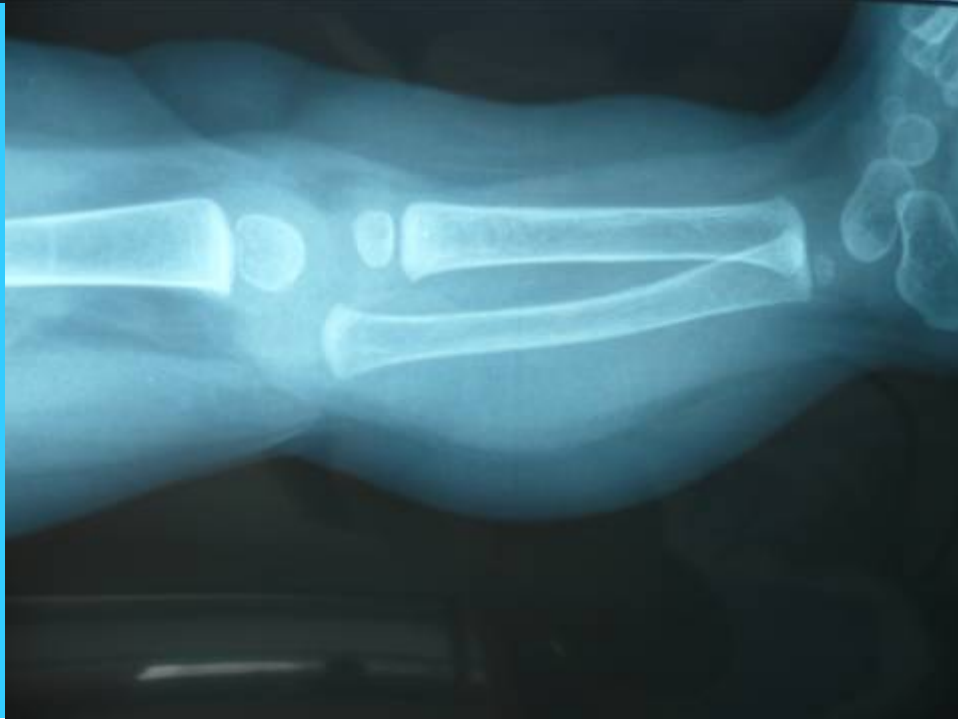
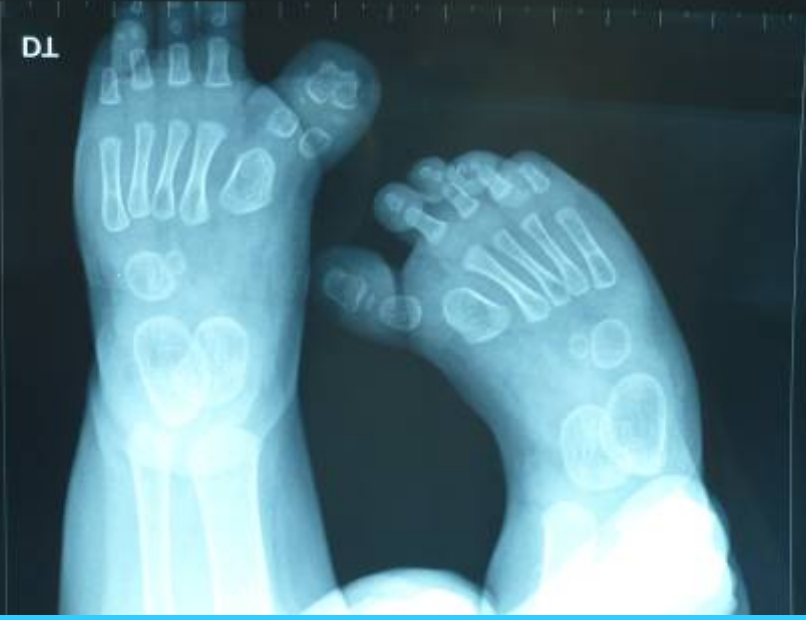


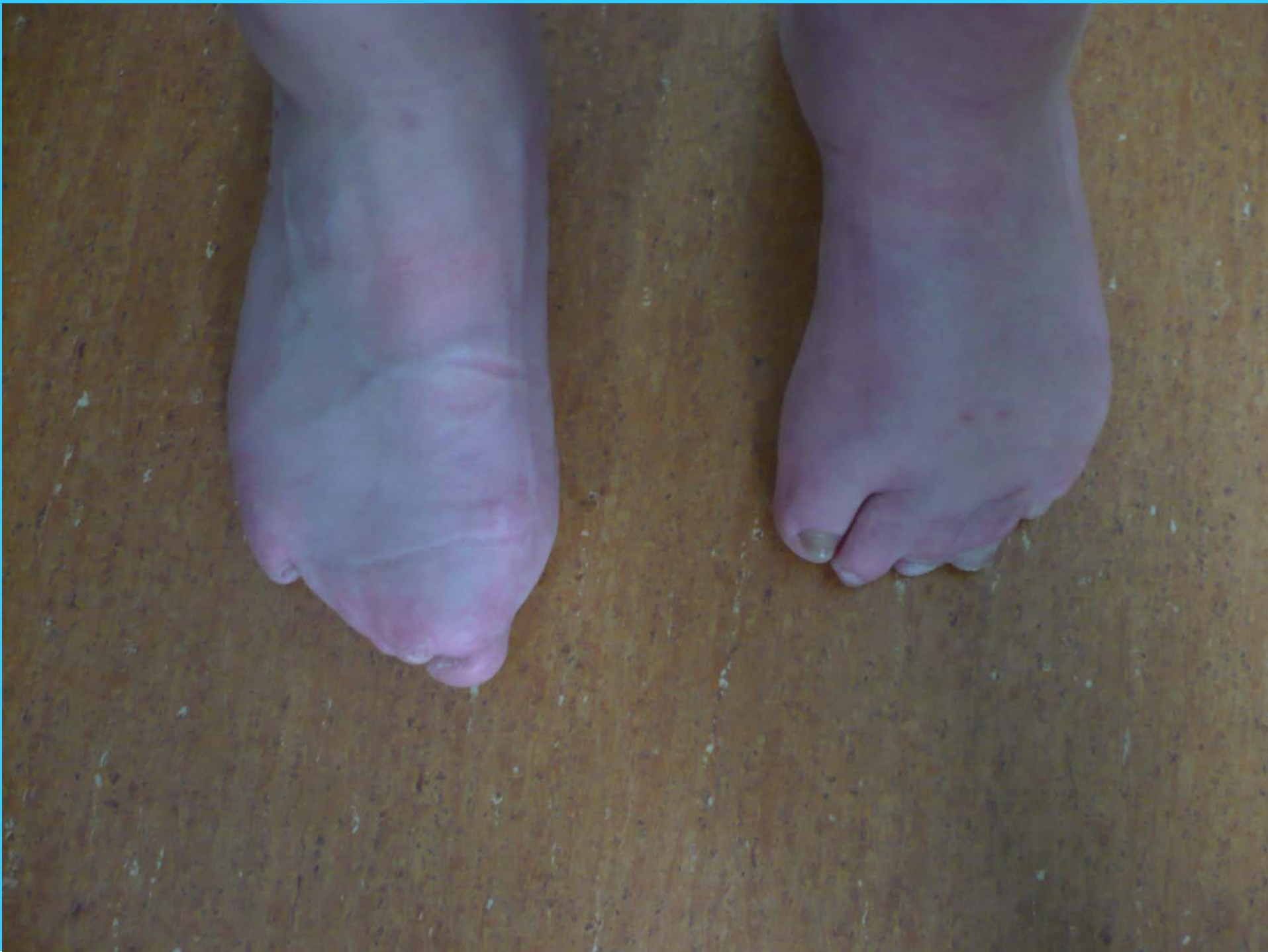


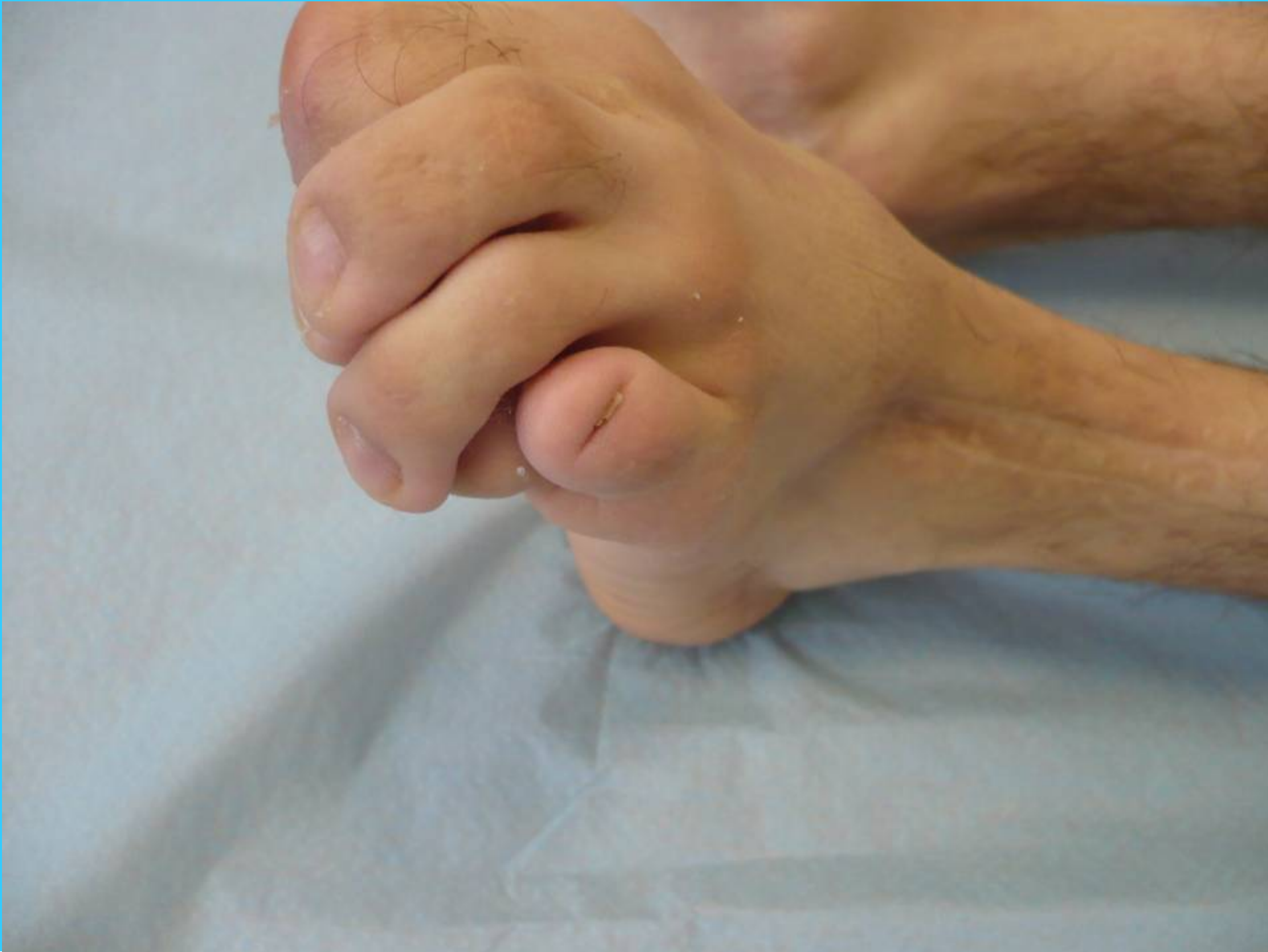








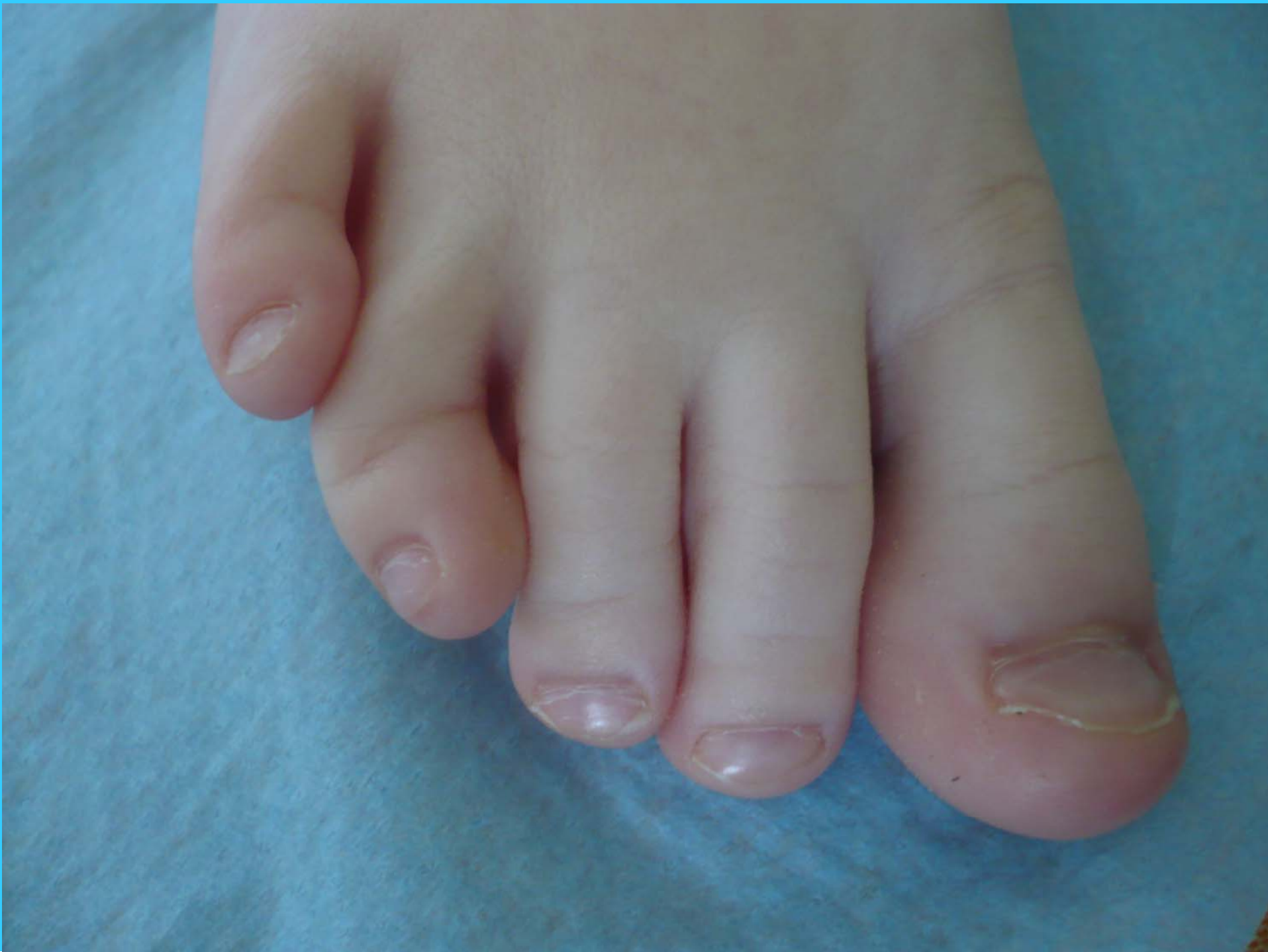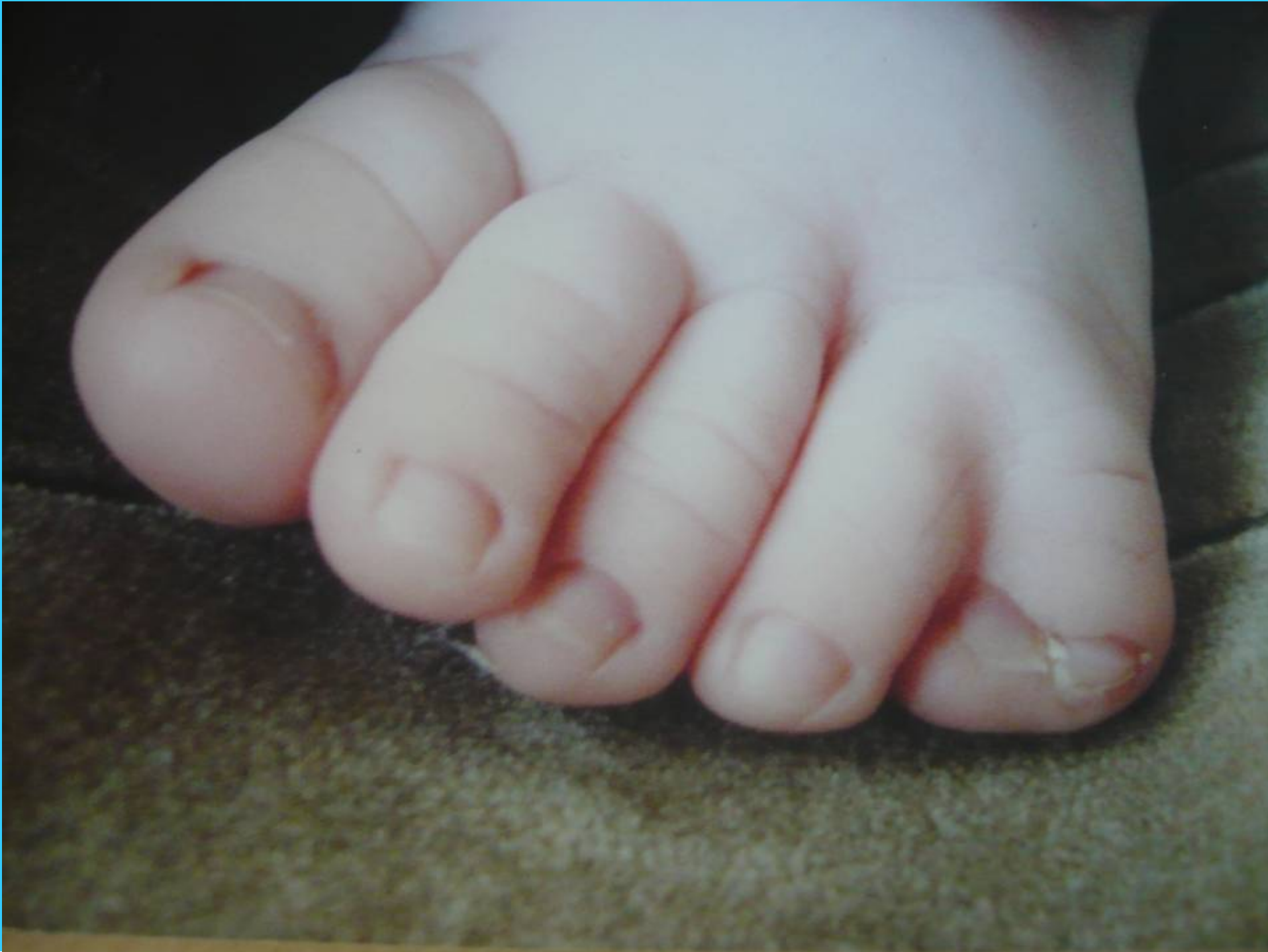The first part of the document discusses the importance of maintaining accurate records of all transactions. It emphasizes that proper record-keeping is essential for the success of any business and for the protection of the interests of all parties involved. The document then goes on to describe the various methods and techniques used to collect and analyze data, highlighting the need for consistency and reliability in the information gathered.

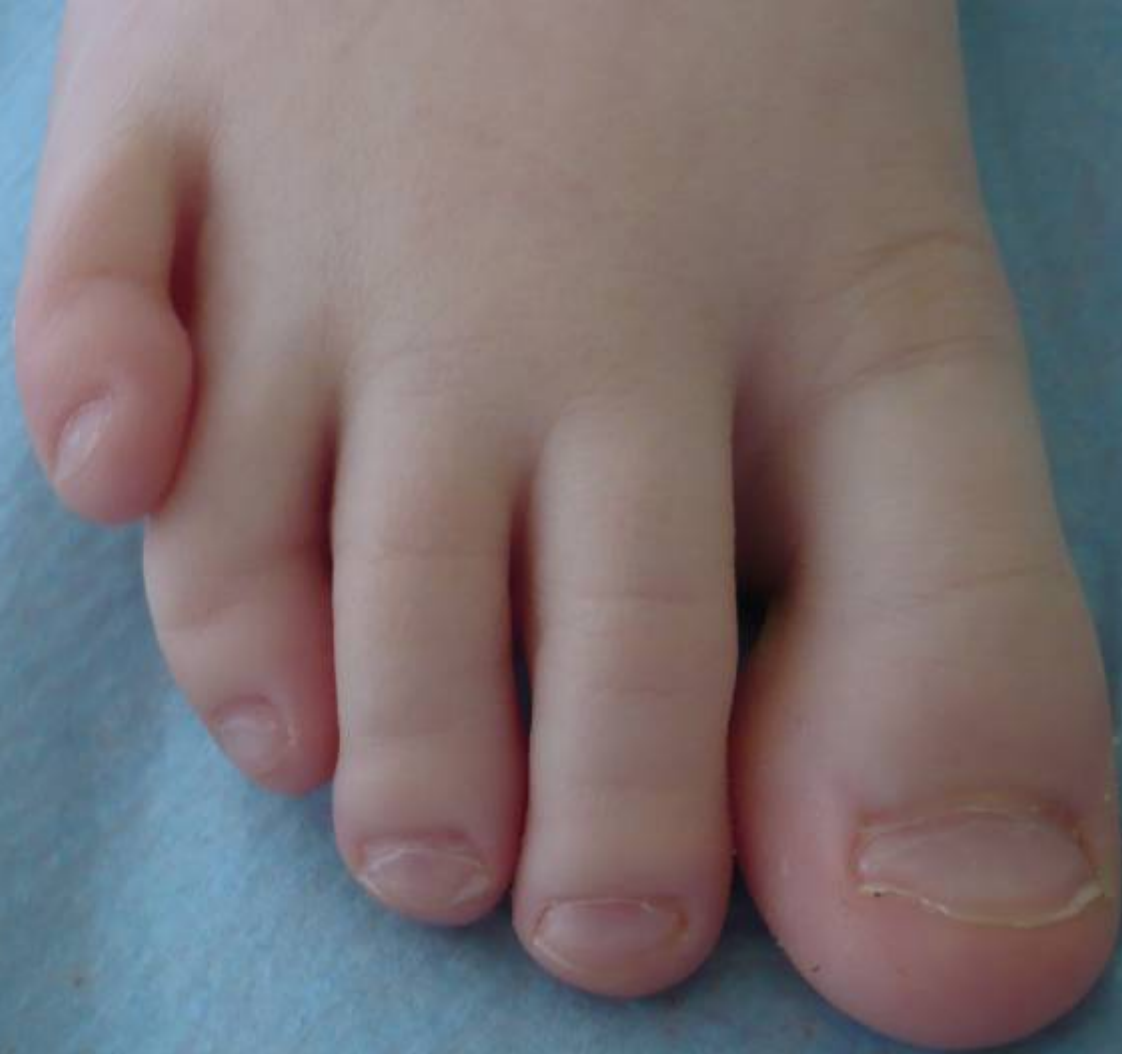In the second part, the author provides a detailed overview of the different types of data that can be collected and how they can be used to inform decision-making. This includes a discussion of both quantitative and qualitative data, as well as the challenges associated with each. The author also discusses the importance of data security and privacy, and provides recommendations for how to best protect sensitive information.

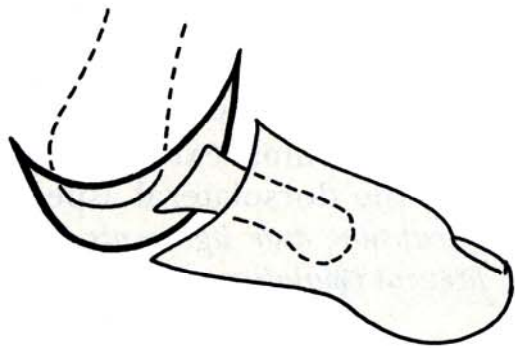
The final part of the document focuses on the practical application of the data collected. It discusses how the information can be used to identify trends, forecast future performance, and make strategic decisions. The author concludes by emphasizing the importance of ongoing monitoring and evaluation, and provides a framework for how to best implement these practices in a business setting.



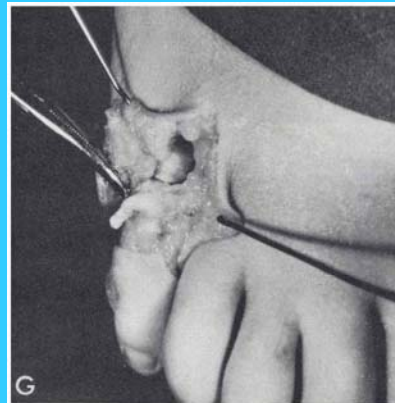
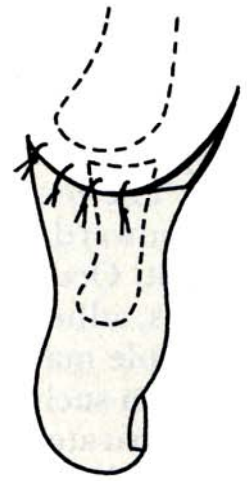
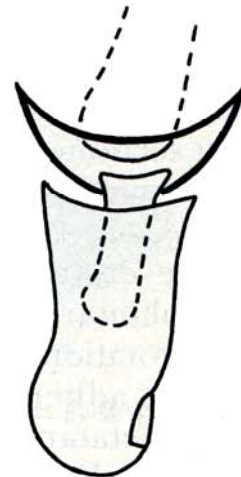
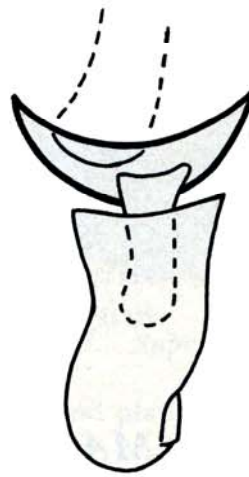




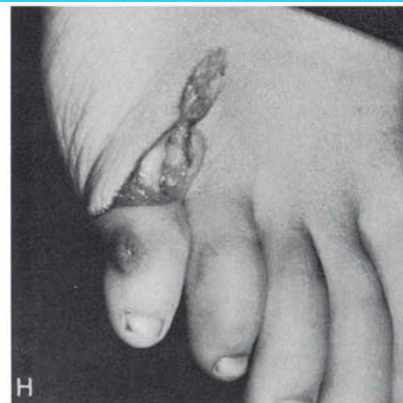




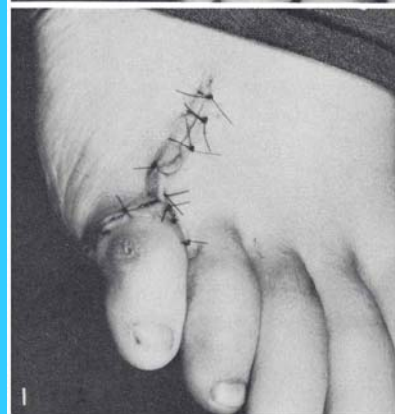
K



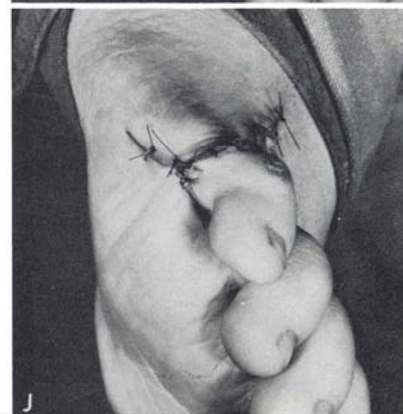
G



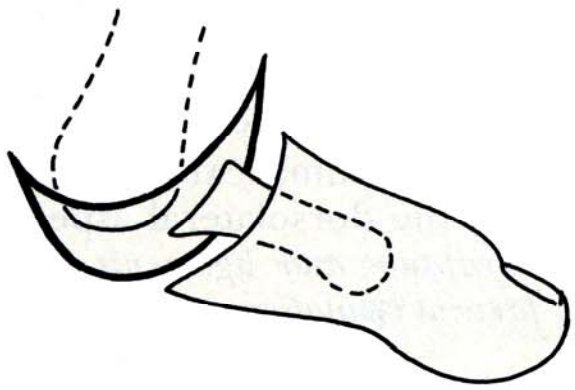
H



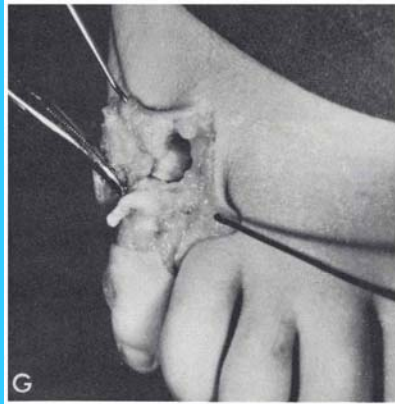
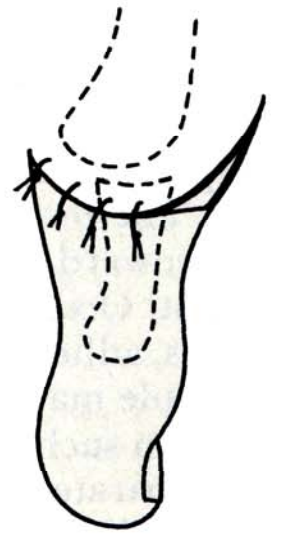
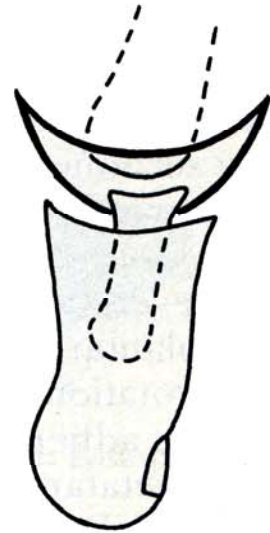
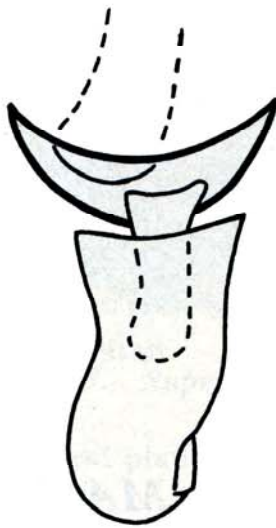
I



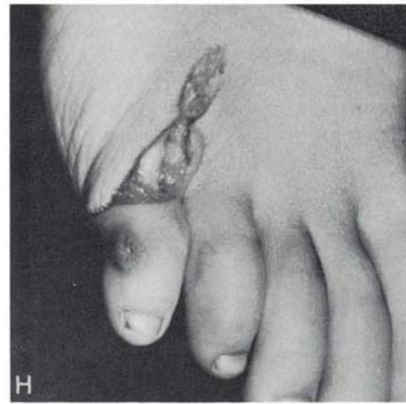
J



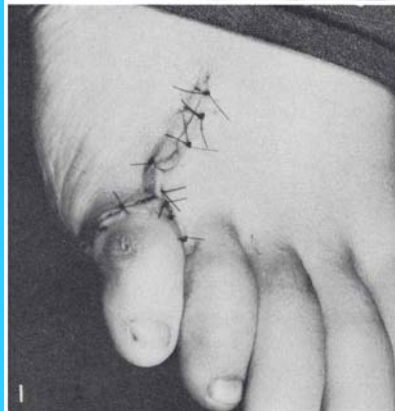
K



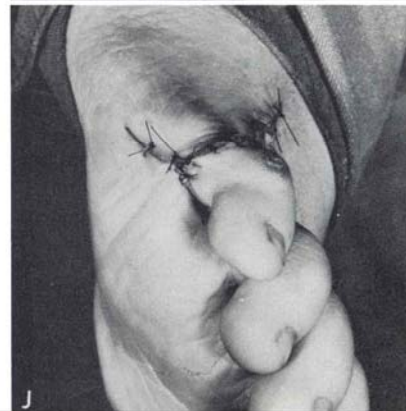
G



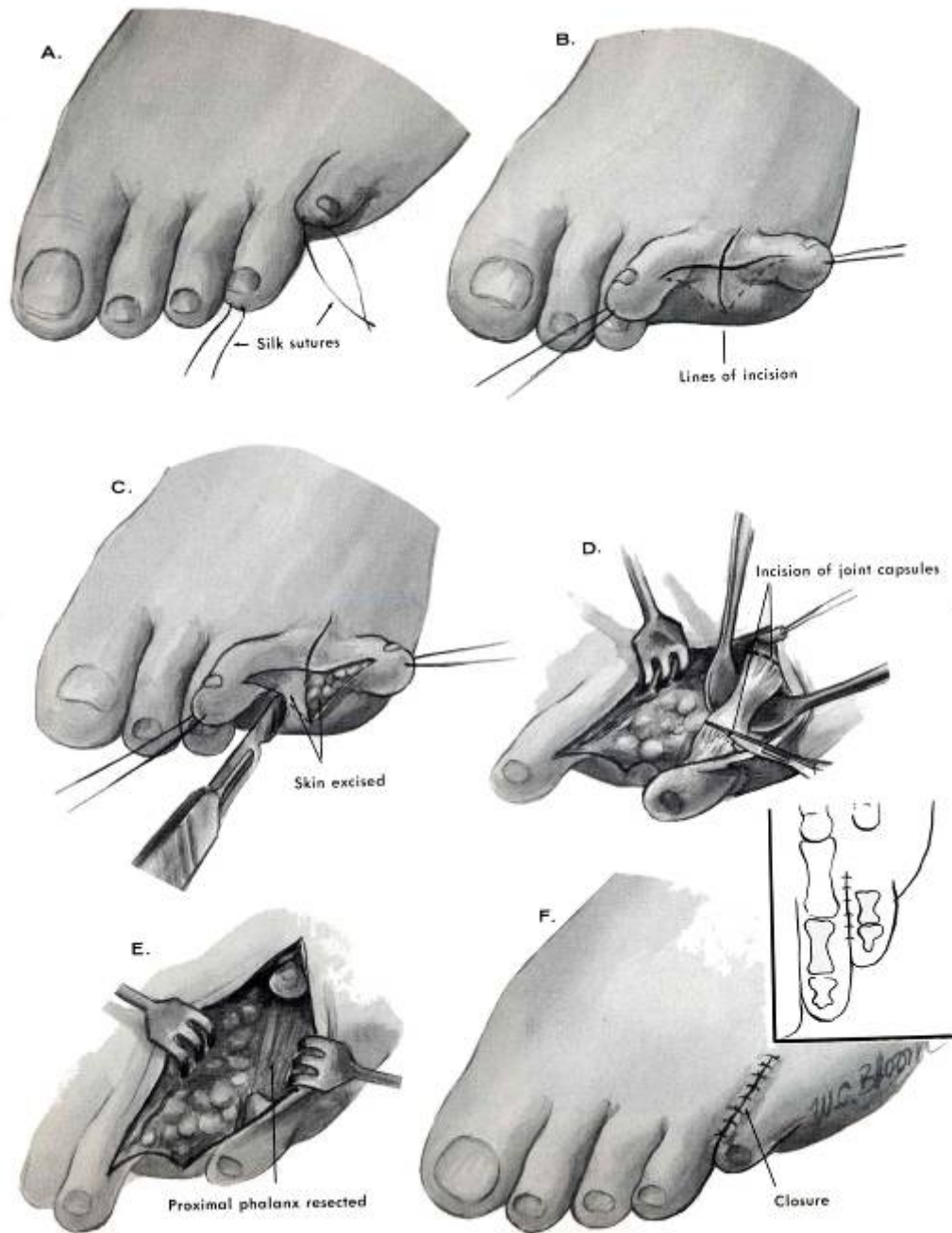
H

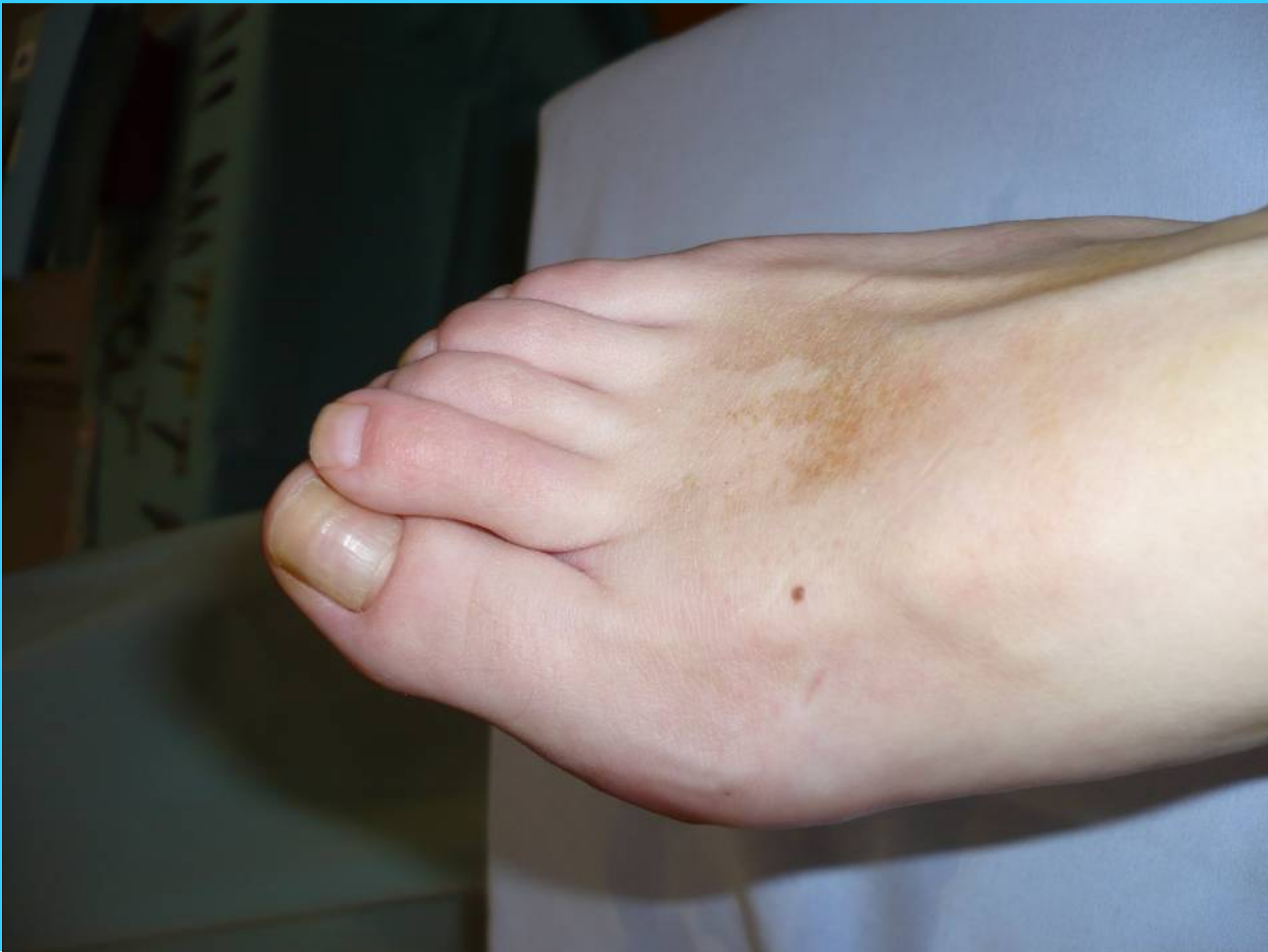

I



J



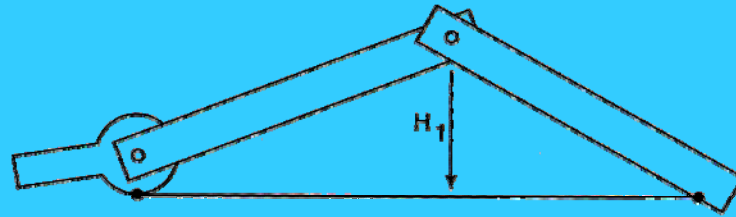
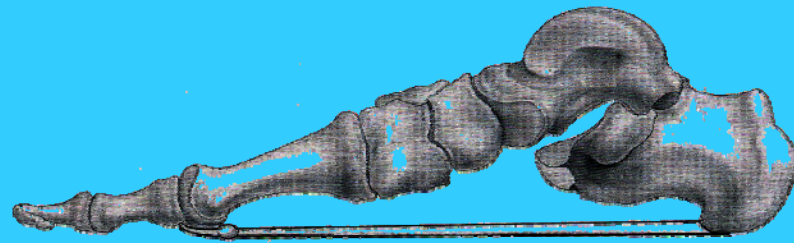


INTERDEPENDANCE

Sous- talienne
Medio-tarsienne
Avant-pied
Sol

Exemple du pied bot varus équin

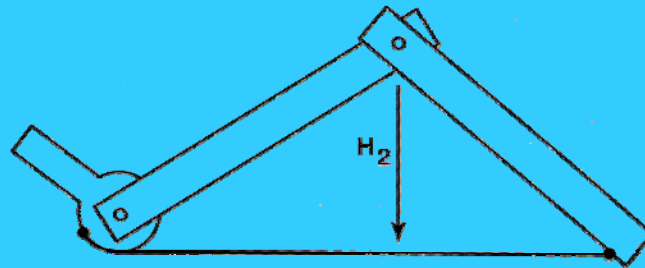

merci



C



A



C



B

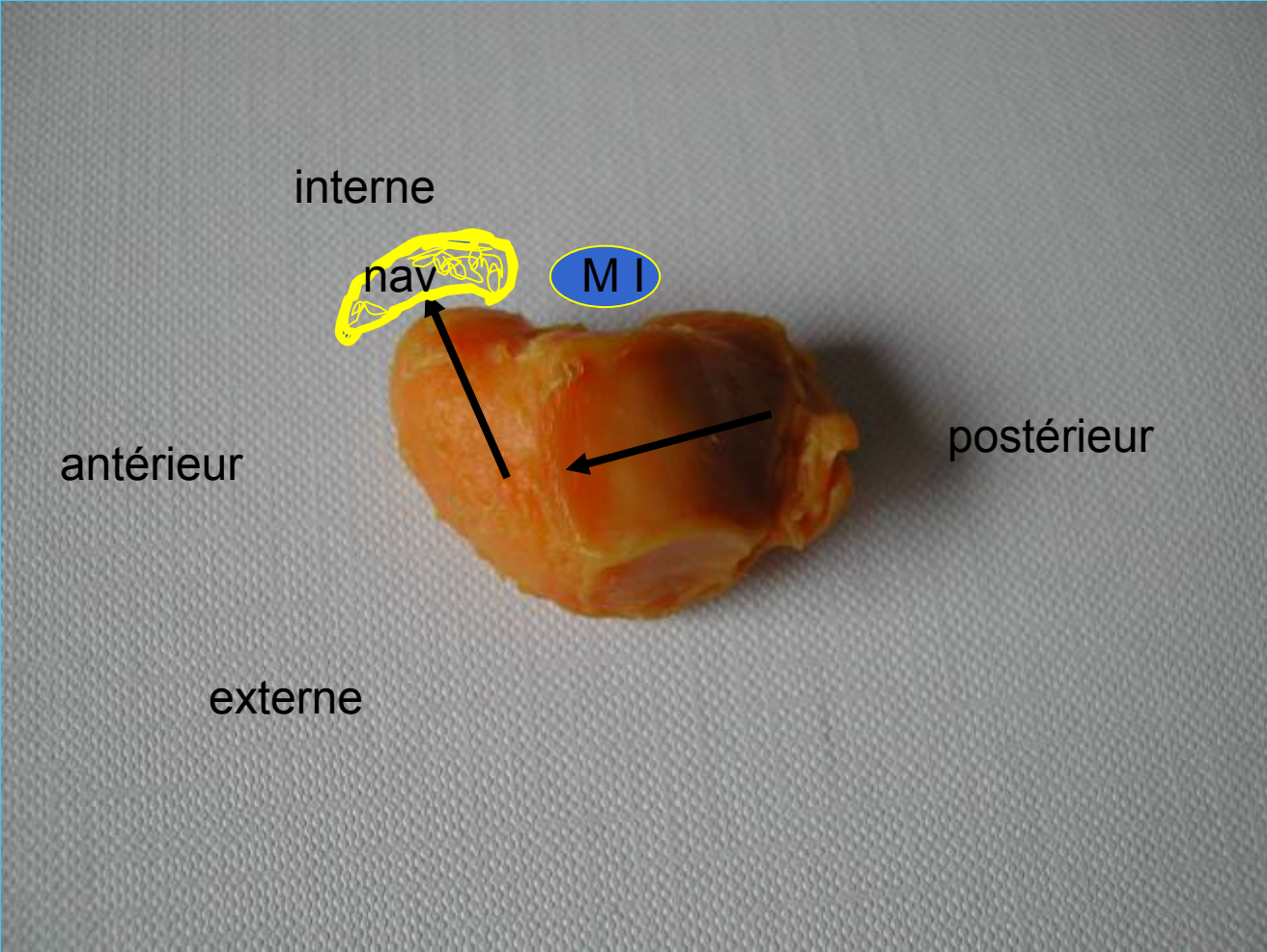


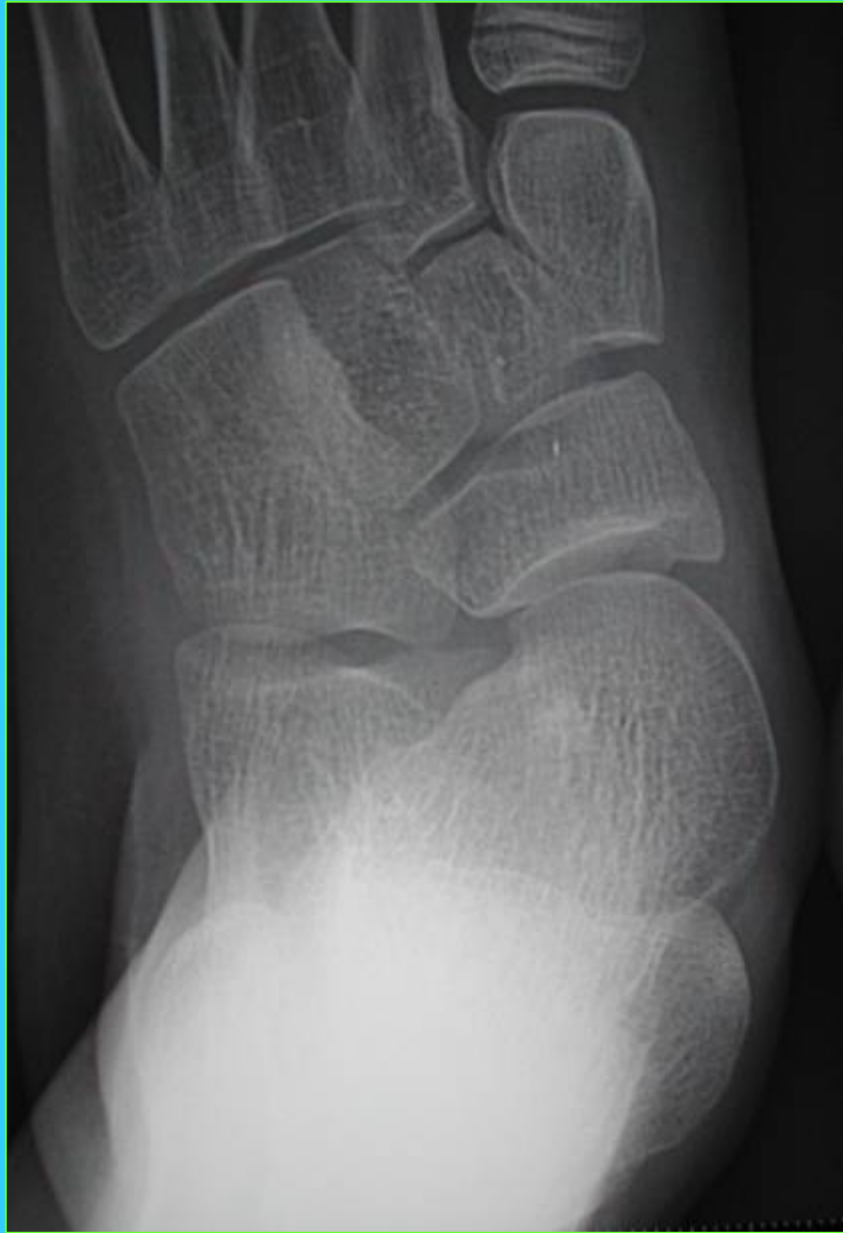



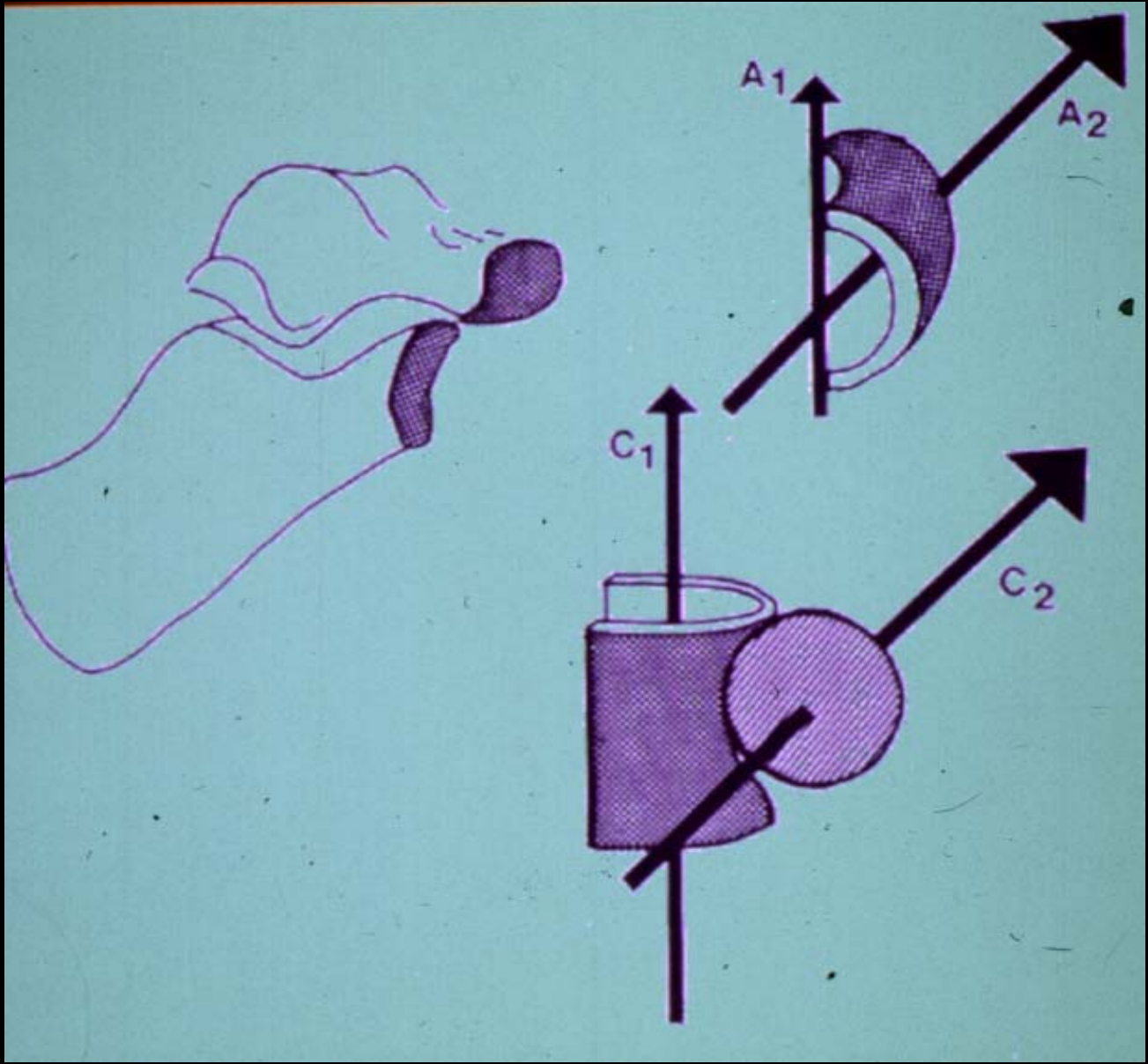





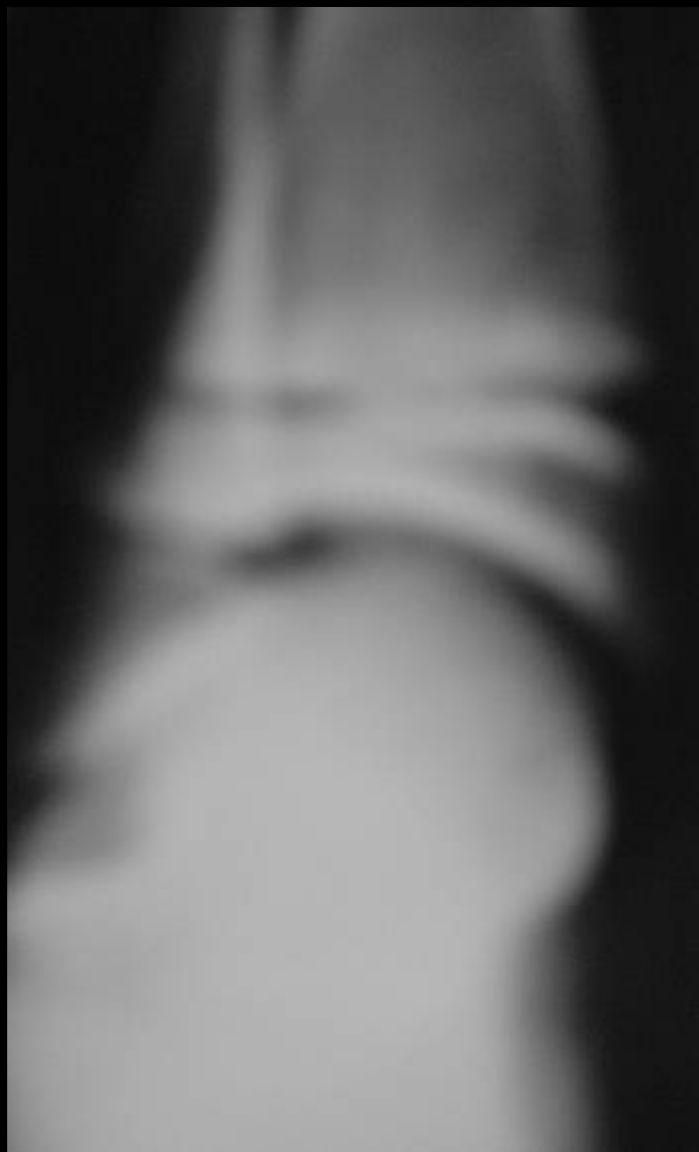

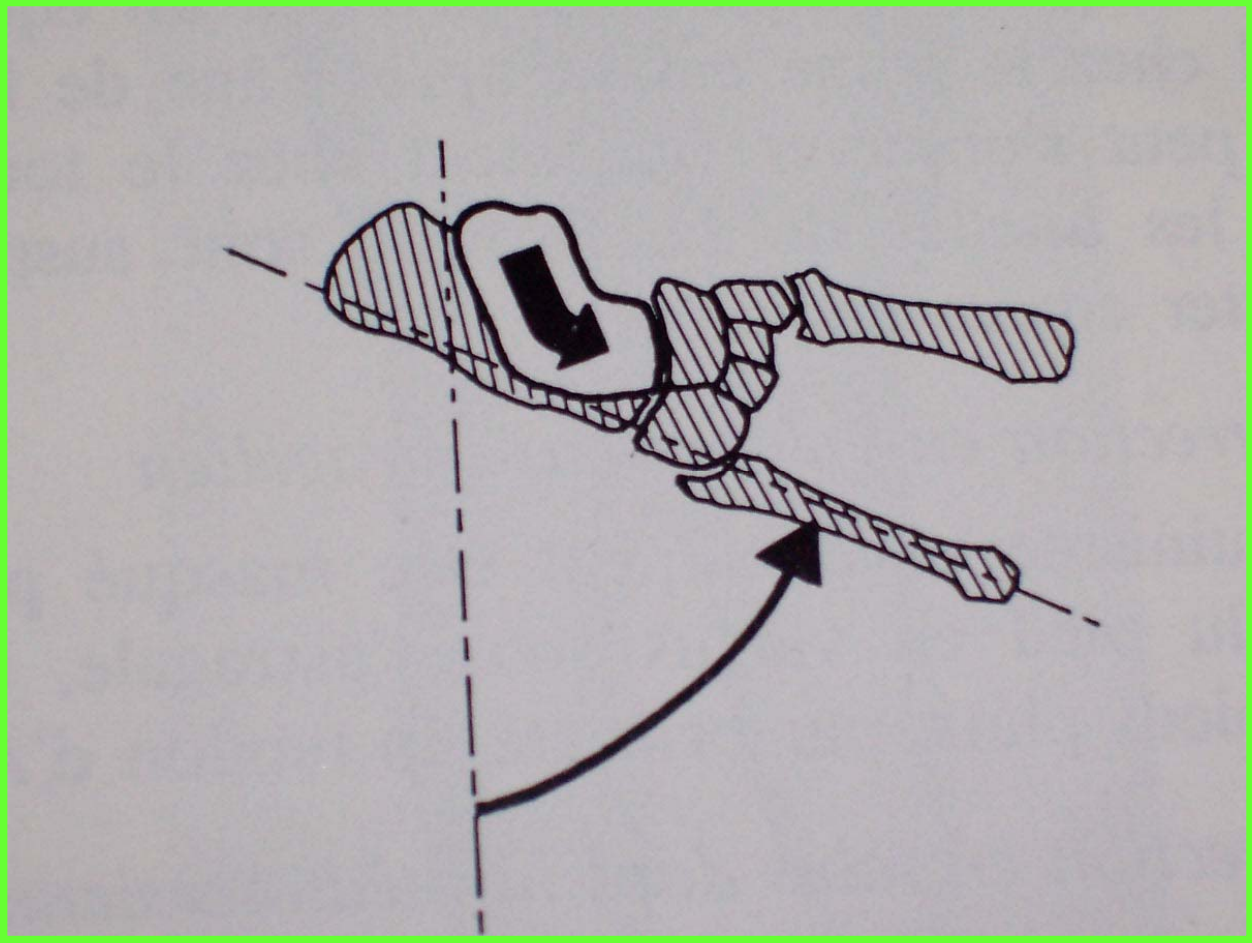


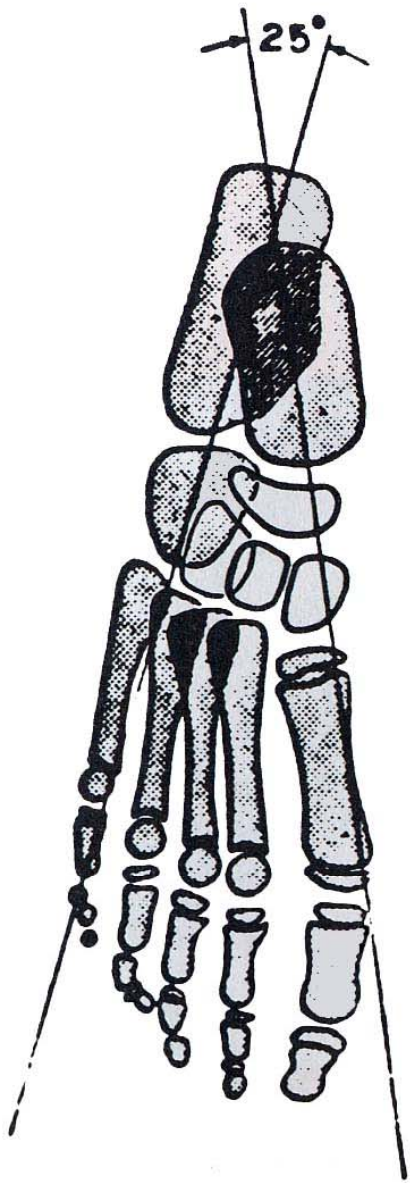




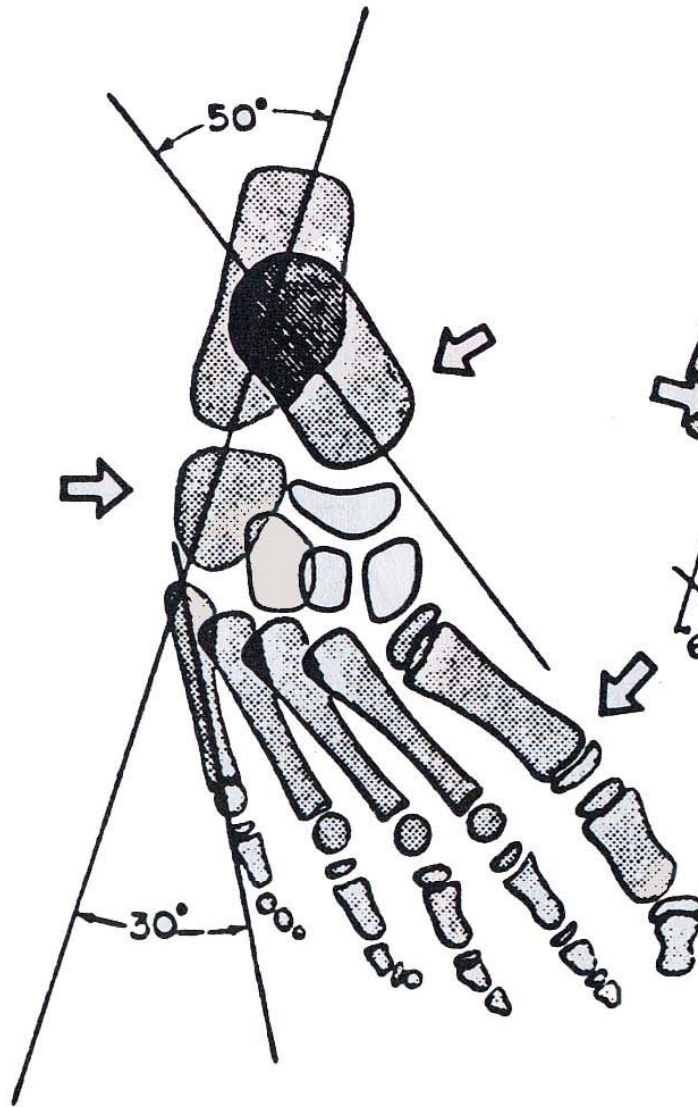




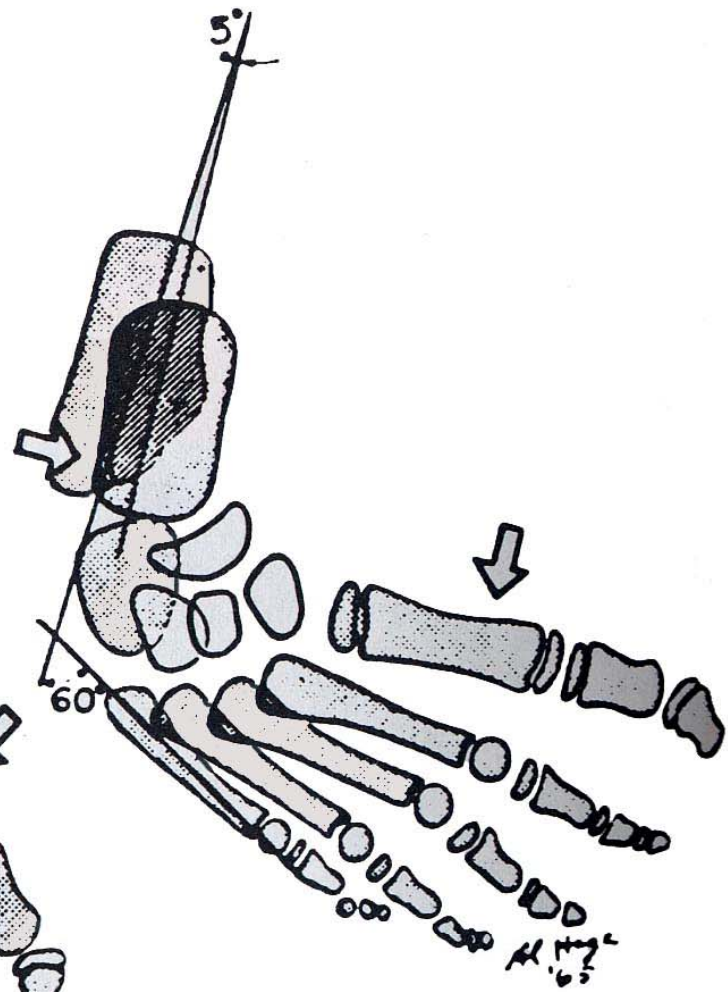




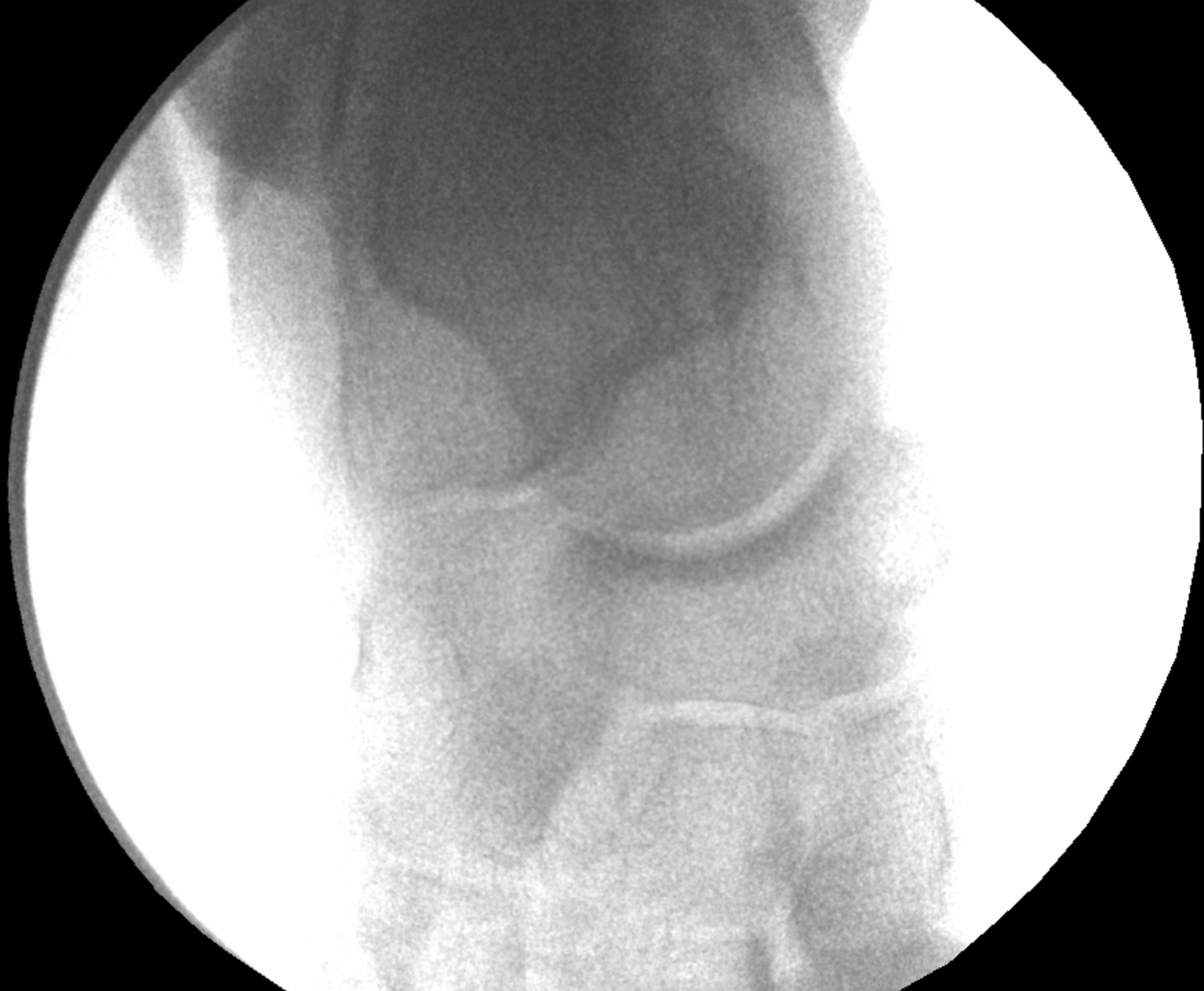NORMAL

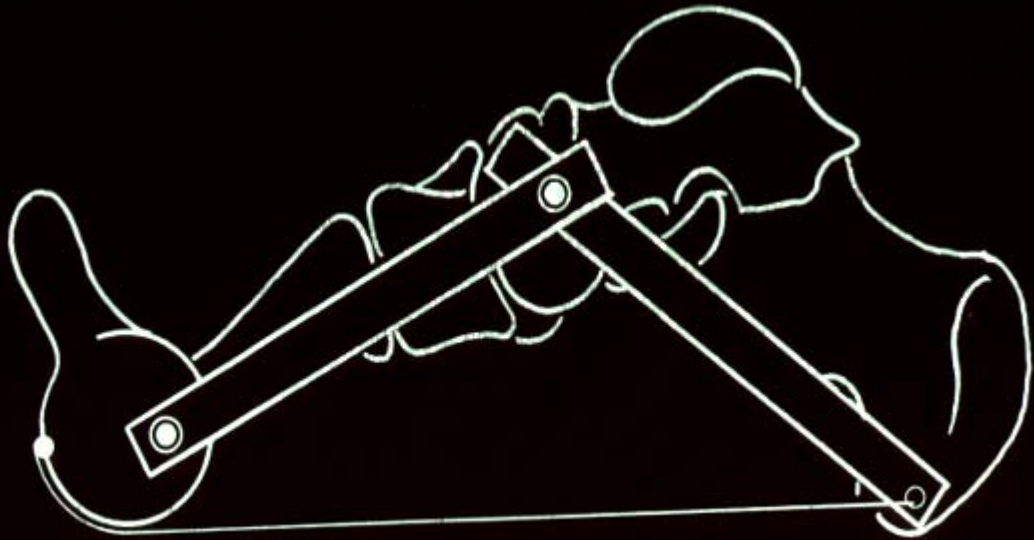
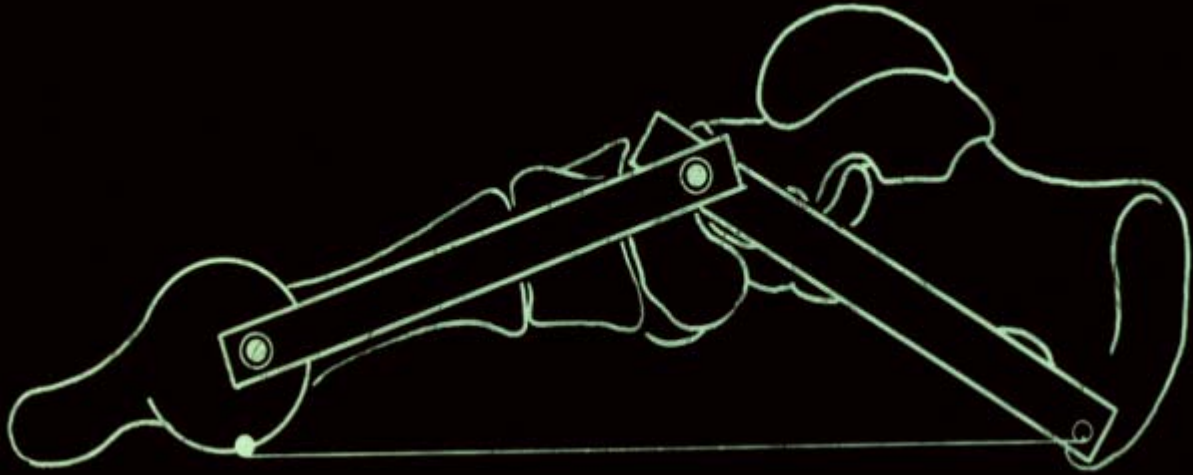


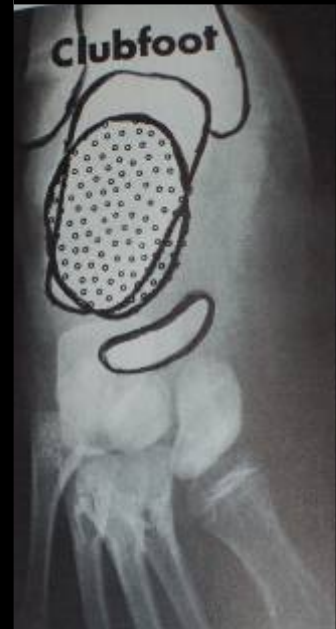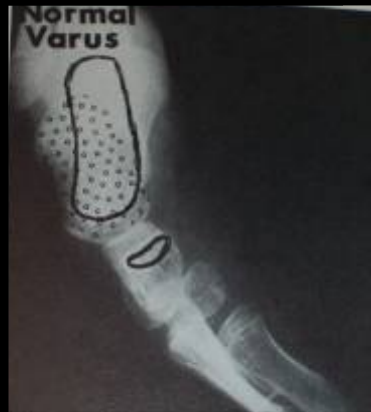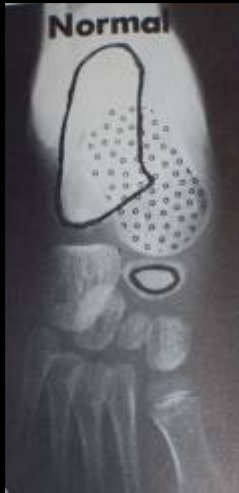MET. VARUS

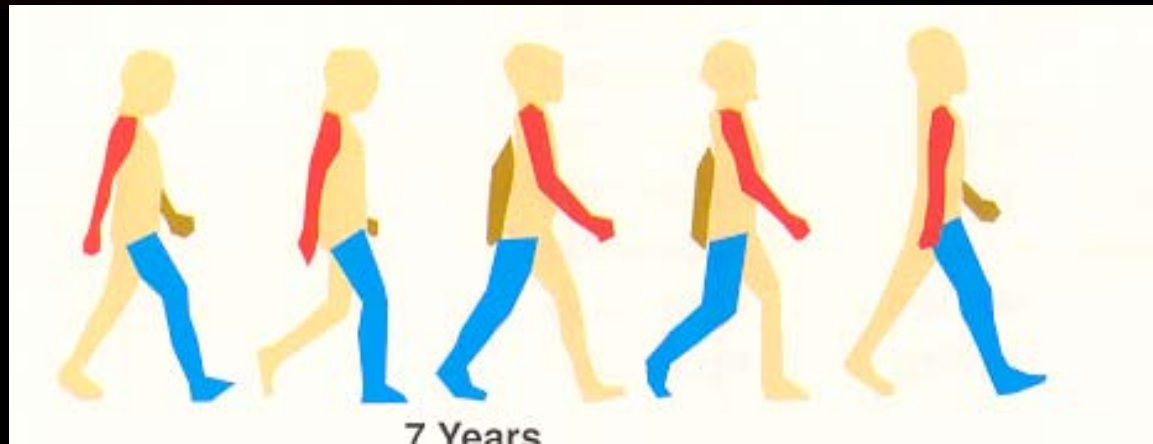
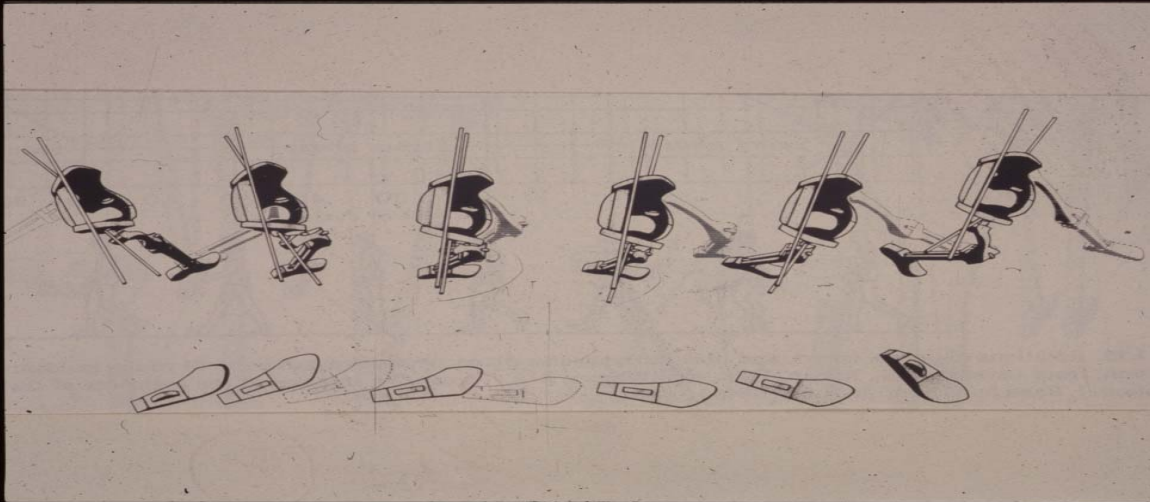


CLUBFOOT









D'après Lynn et Staheli, *Practice of pediatric orthopedics*
Edition Lippincott William et Wilkins 2001



