



Pieds plats

D. MOULIES

DER PLATTFUSS

KLINIK, PATHOLOGIE
KONSERVATIVE UND OPERATIVE
BEHANDLUNG

VON

KASPAR NIEDERECKER

o. B. Professor der Orthopädie an der Universität Würzburg
Direktor der orthopädischen Klinik König-Ludwig-Haus

MIT 344 DARUNTER 26 FARBIGEN ABBILDUNGEN
UND 15 TABELLEN

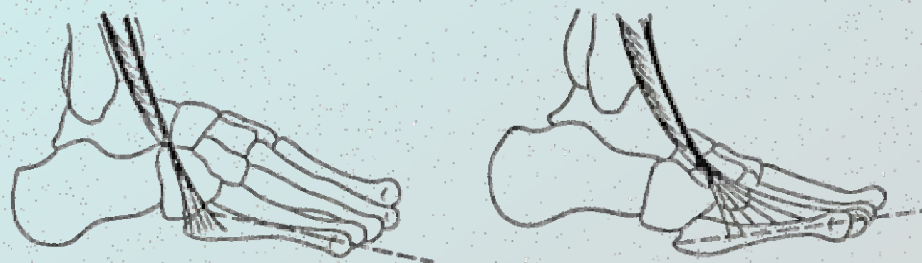


Abb. IV/25. M. peroneus tertius (Unterschied zwischen normalem und anomalem Ansatz).



1 . 9 . 5 . 9

FERDINAND ENKE VERLAG STUTT GART

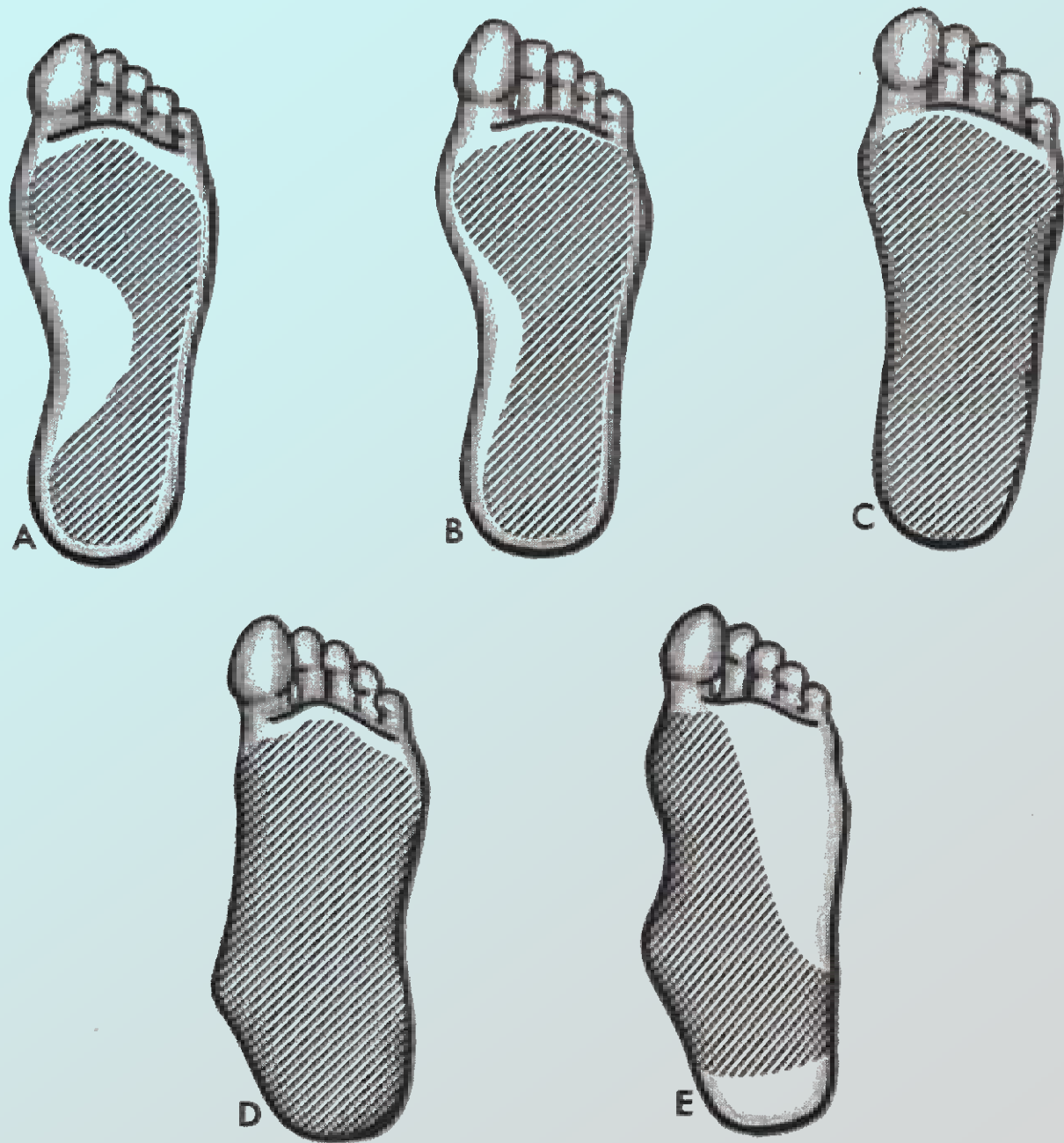


FIGURE 5-10. Foot prints of varying degrees of flat foot.

Exemple du pied plat

Intrinsèque
Extrinsèque
Physiologique

PIED PLAT STATIQUE

1° 2° degré

s'améliore spontanément

5% restent déformés

La tolérance dépend du mode de vie

PIED CONSTITUTIONNEL

2° ou 3° degré

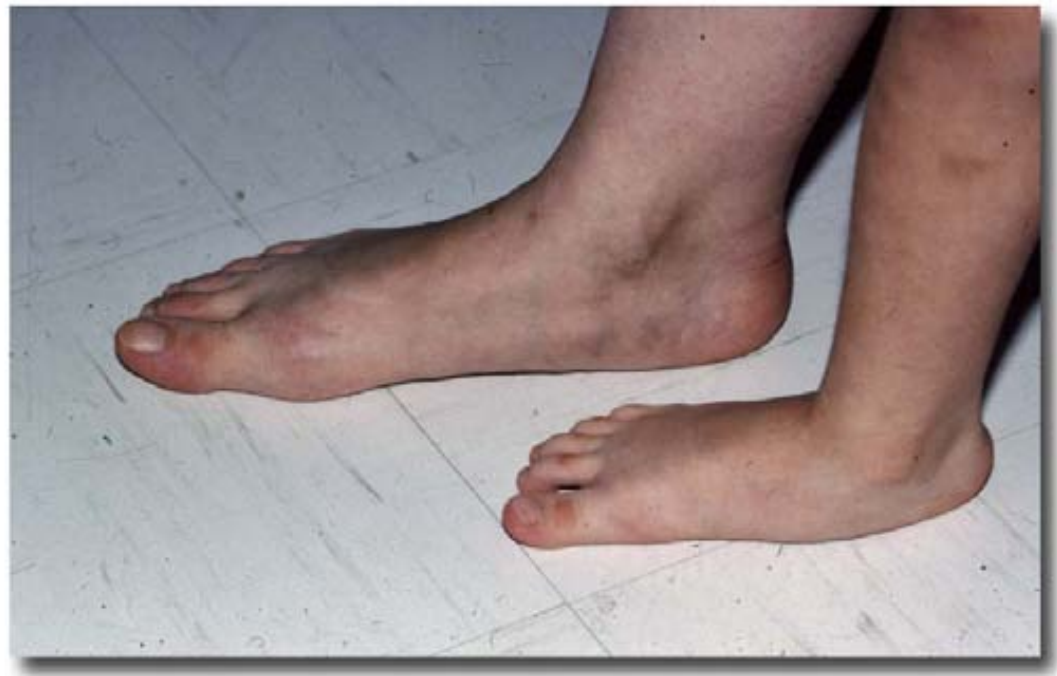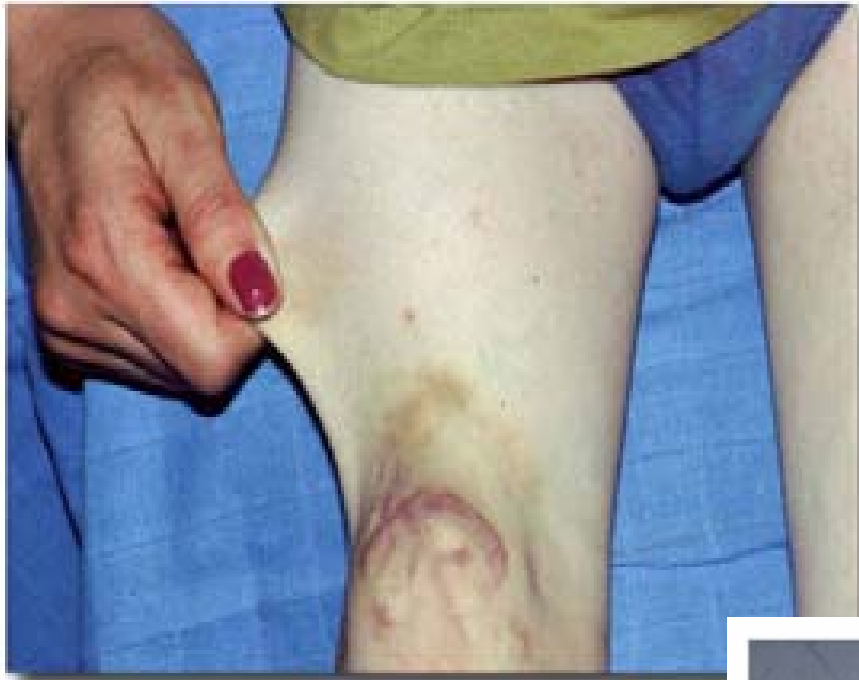reconnu dès l'enfance

Adolescent maladroit

Marche en rotation externe

Souvent familial

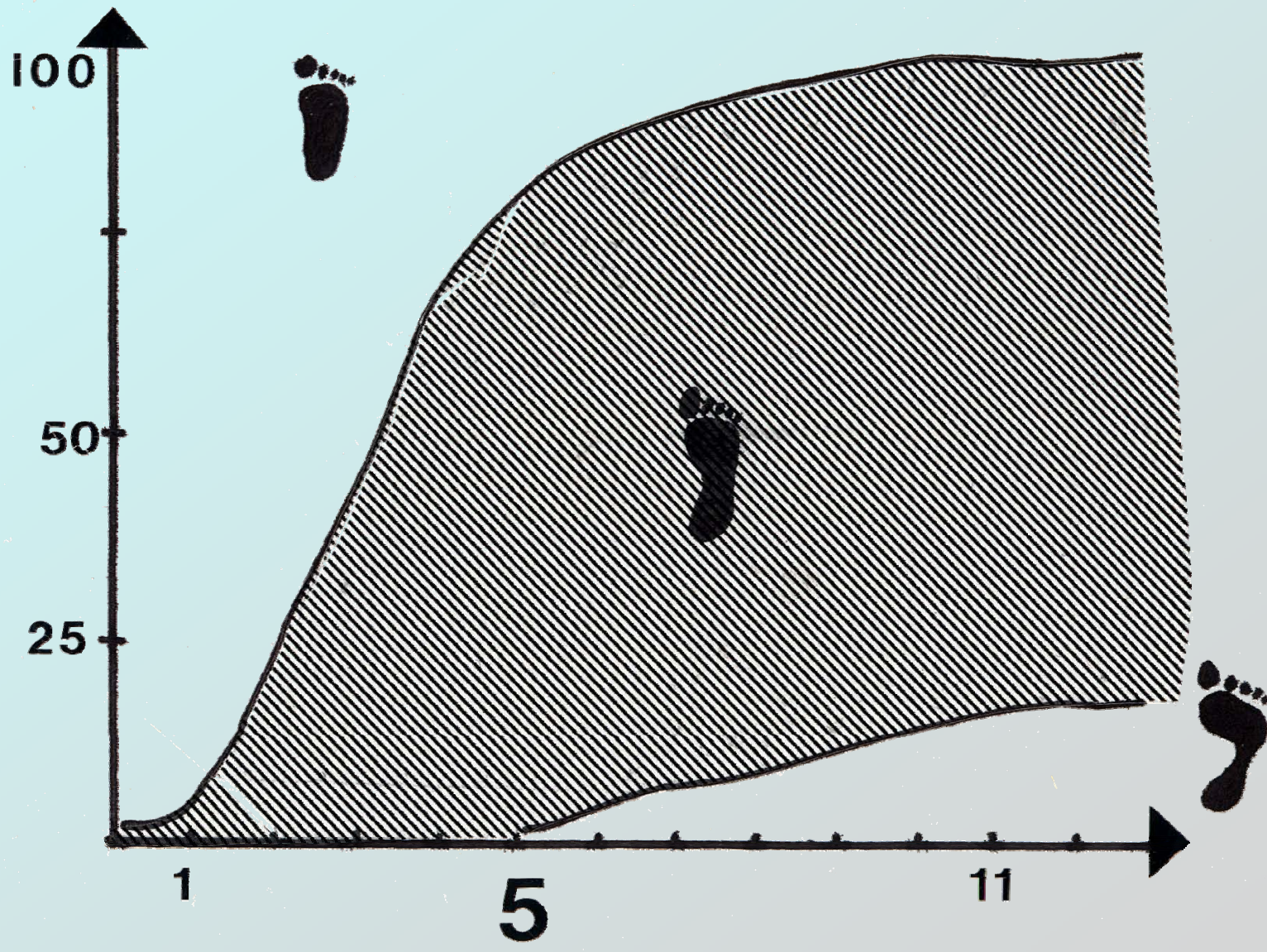
Arthrose possible à 50-60 ans



PALACIOS

53 PIEDS PLATS OPERES A L'AGE ADULTE

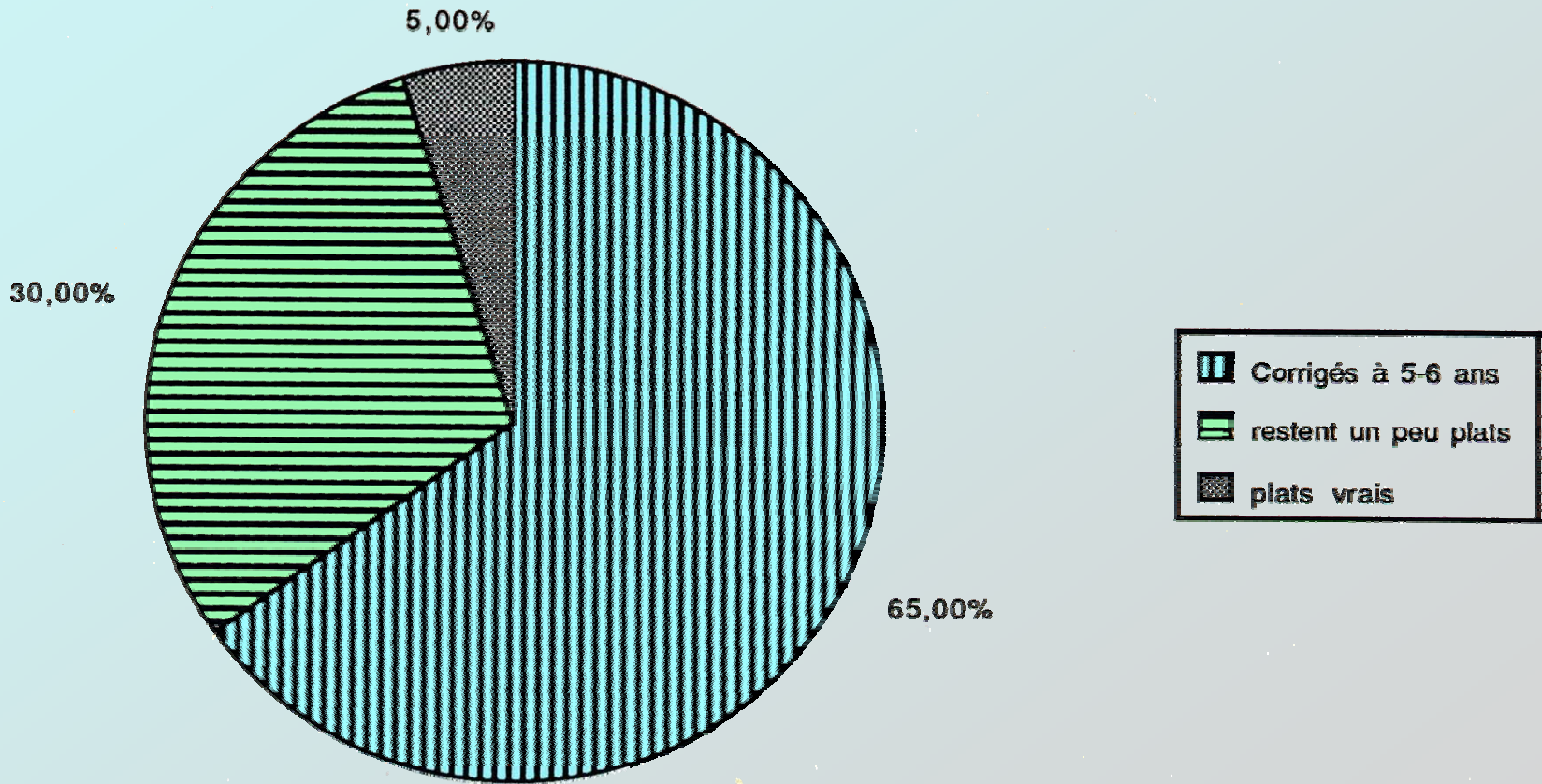
14 PIEDS DECOMPENSES CONNUS DEPUIS L'ENFANCE



MORLEY

97 % DES ENFANTS DE MOINS DE 2 ANS
ONT UN PIED PLAT

MEARY



F.EURLY

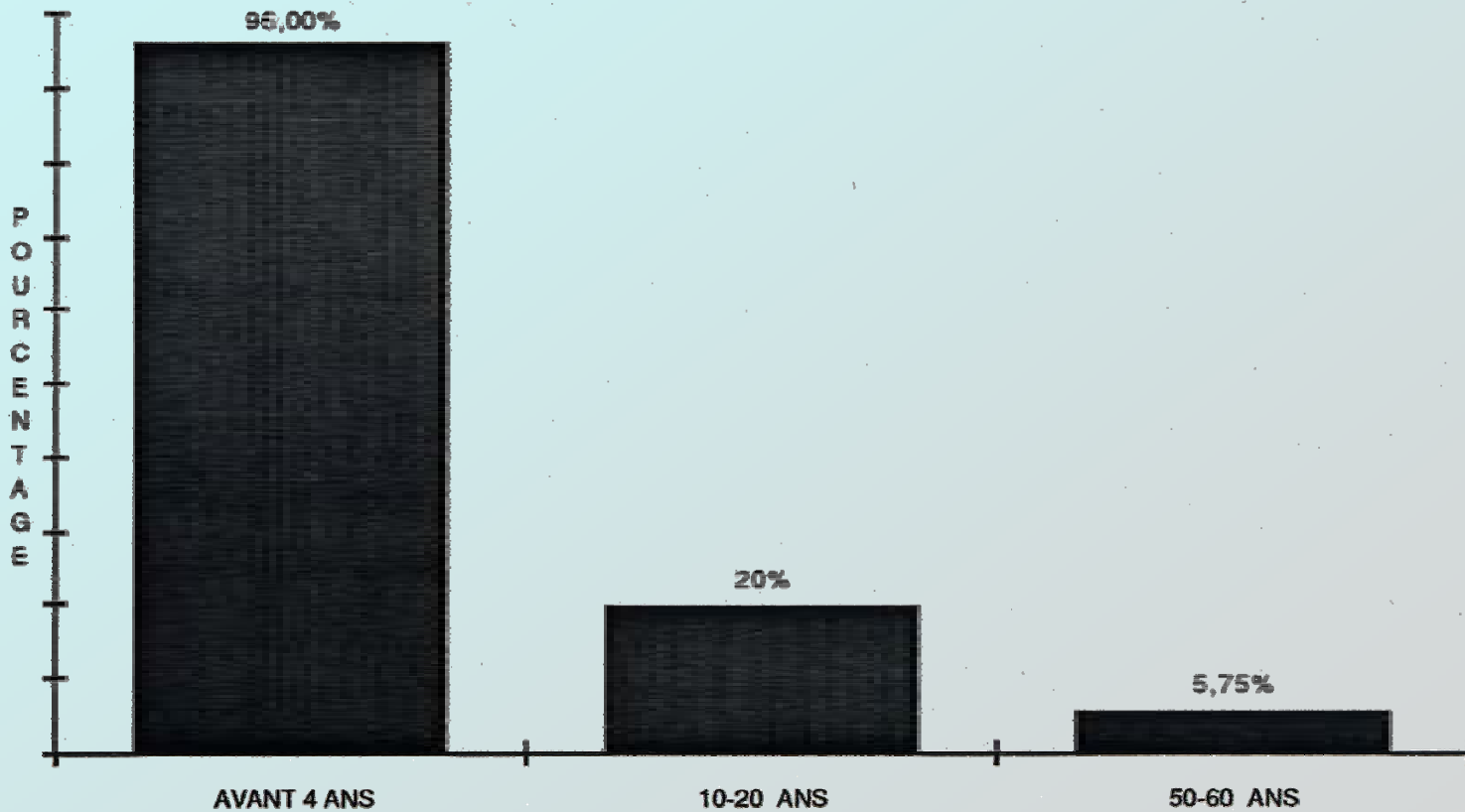
1134 Jeunes soldats « consultants »

154 pieds plats

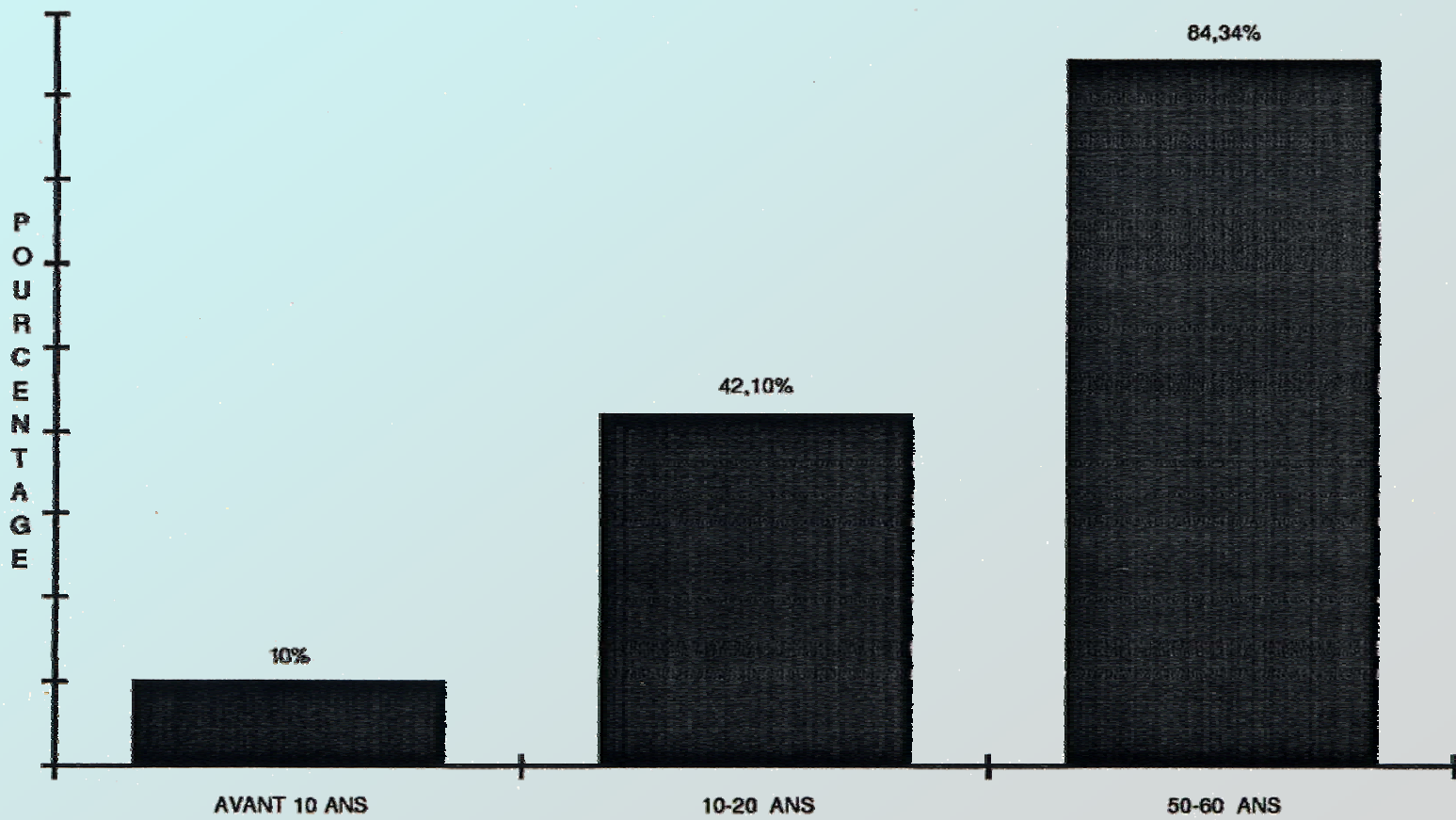
977 pieds creux

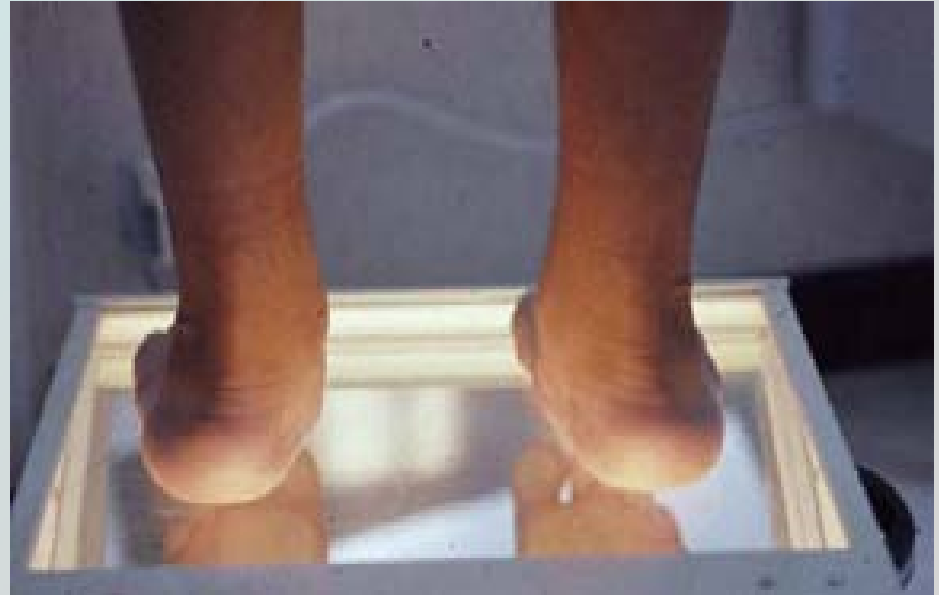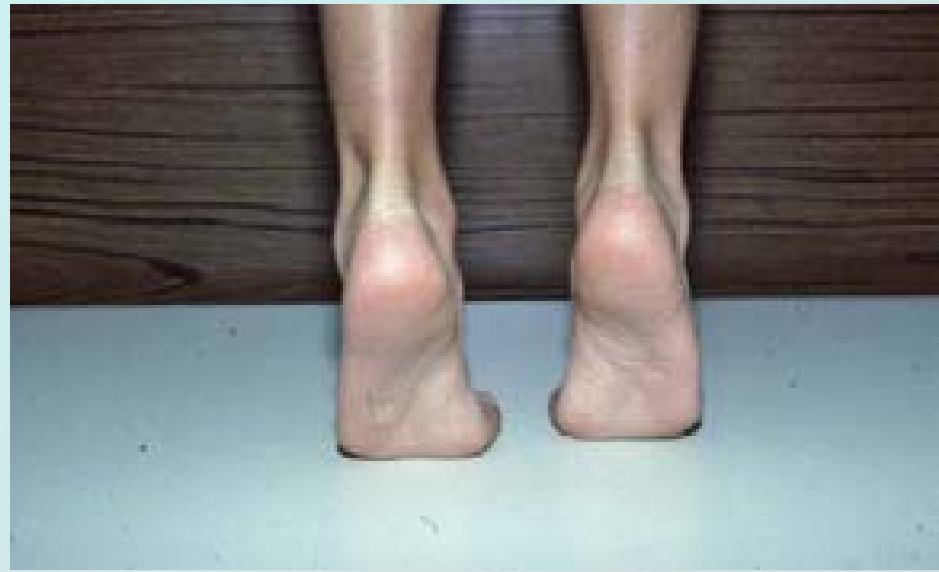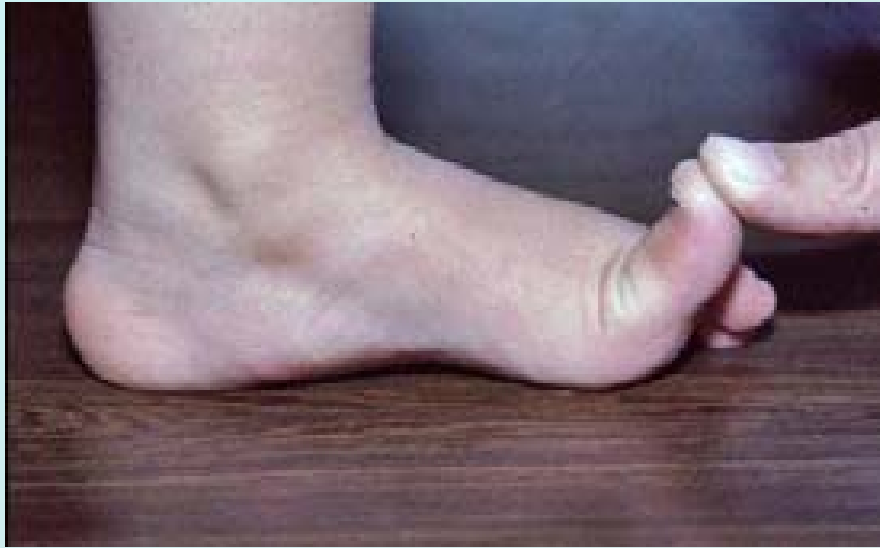1° et 2° degré
Sous malléolaire int.
Bord int. du tarse
Obésité
Exercice
Chaussage

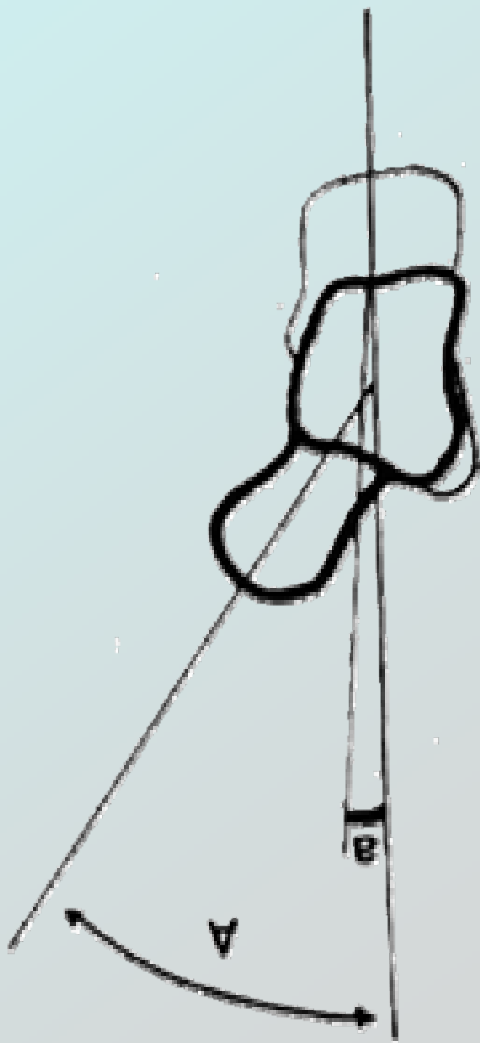SALVATI PIEDS PLATS

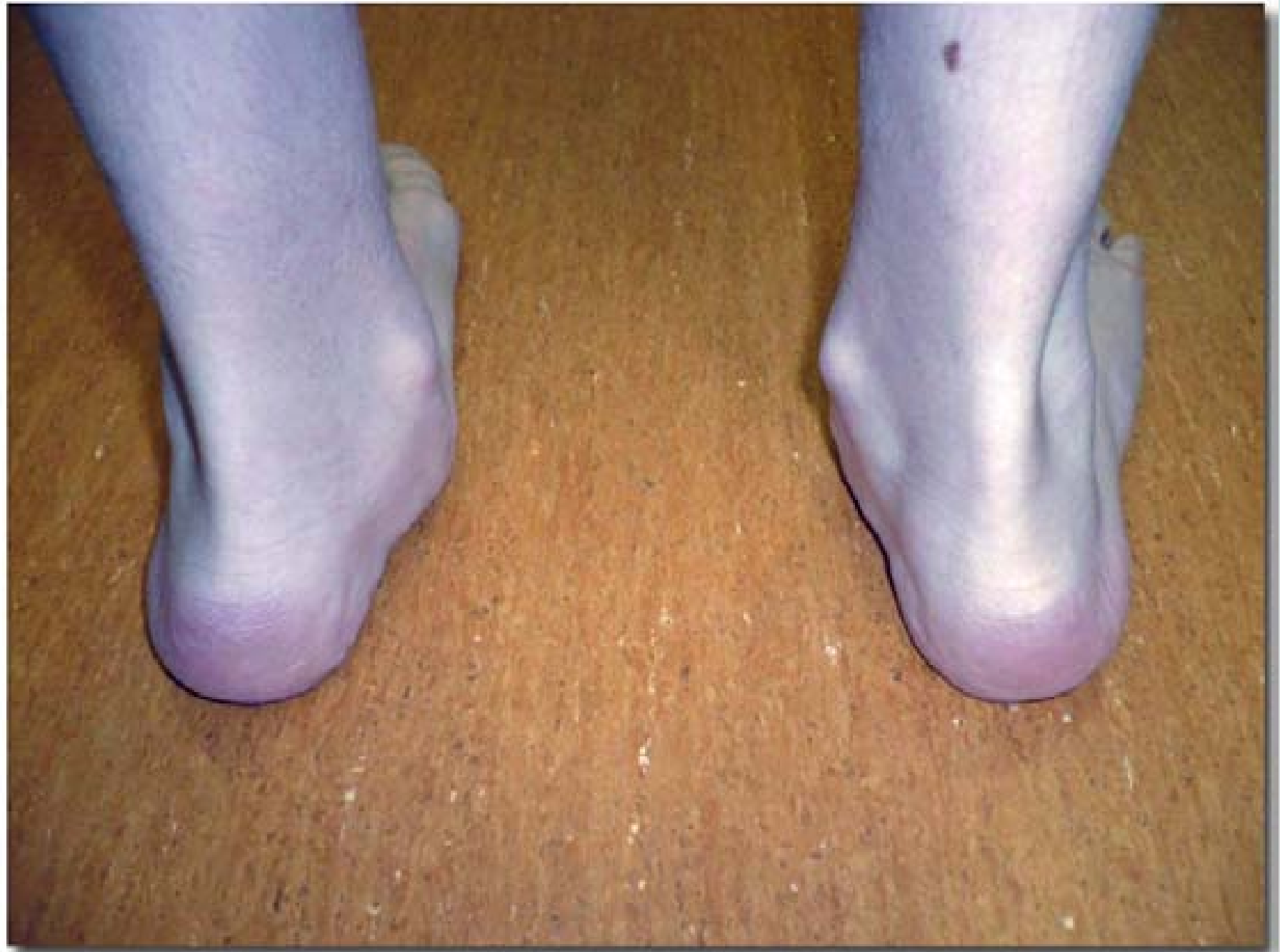

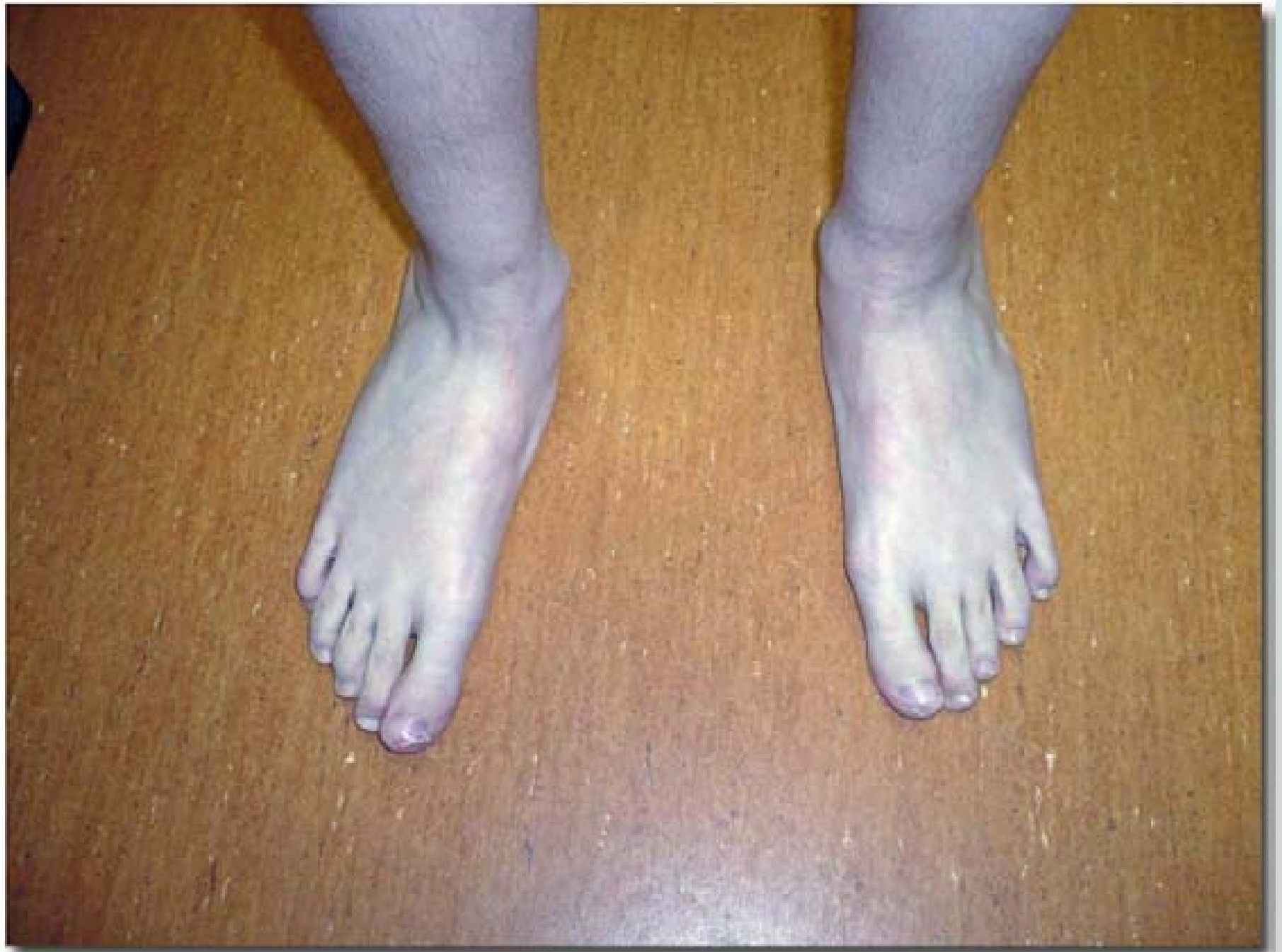SALVATI PIEDS CREUX

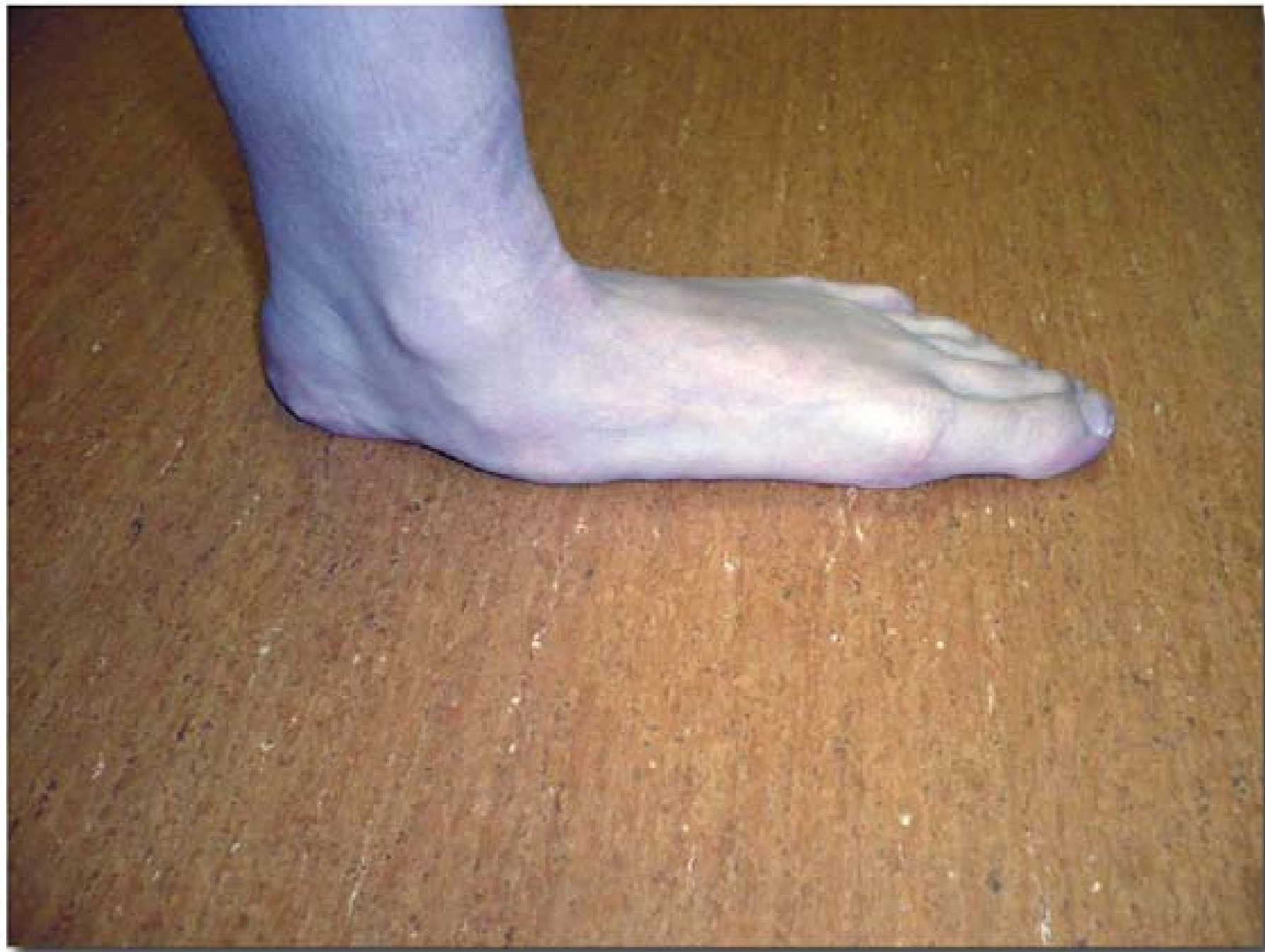


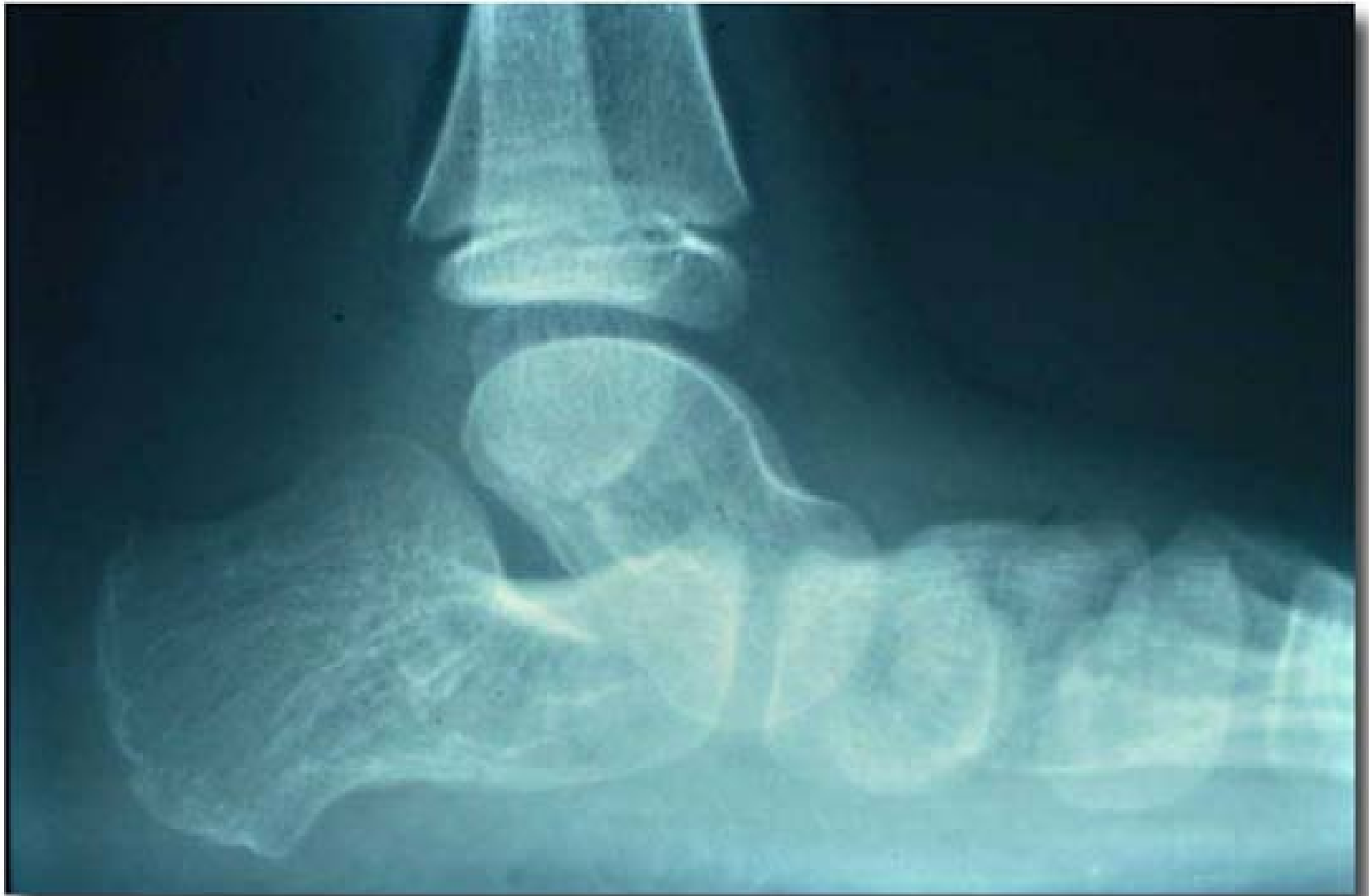


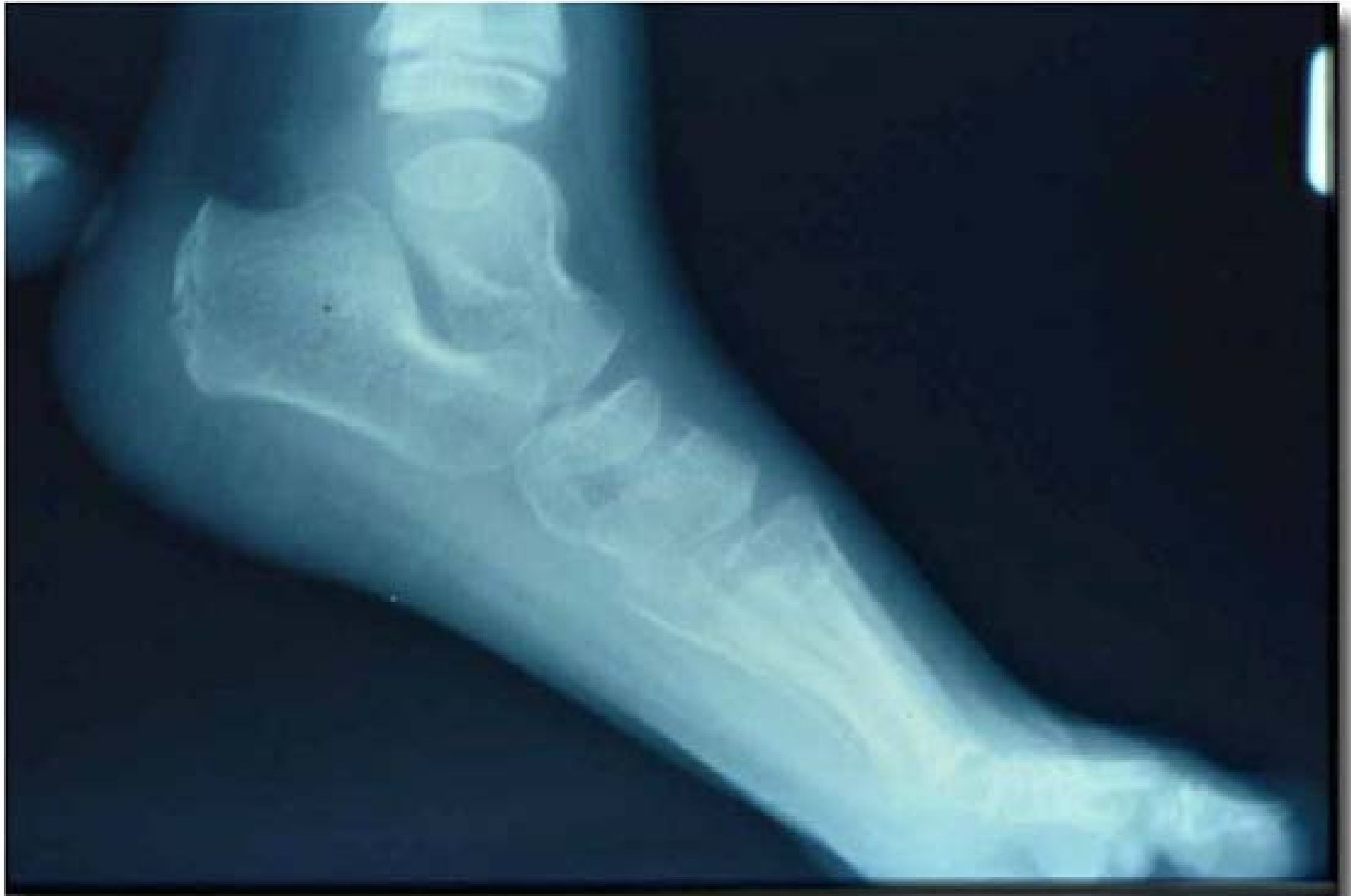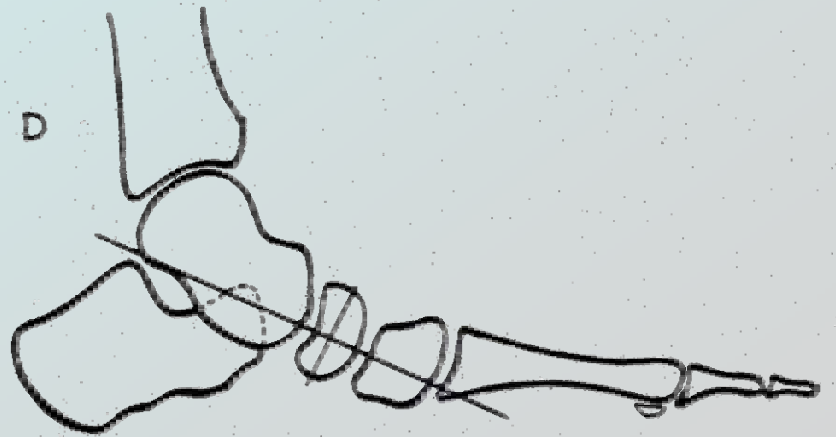
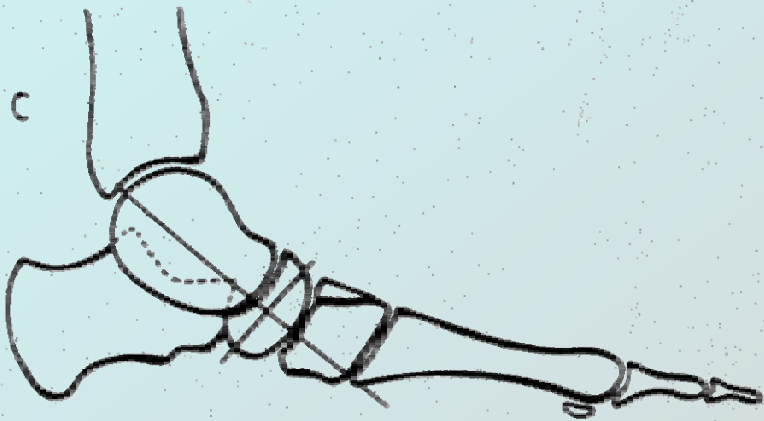
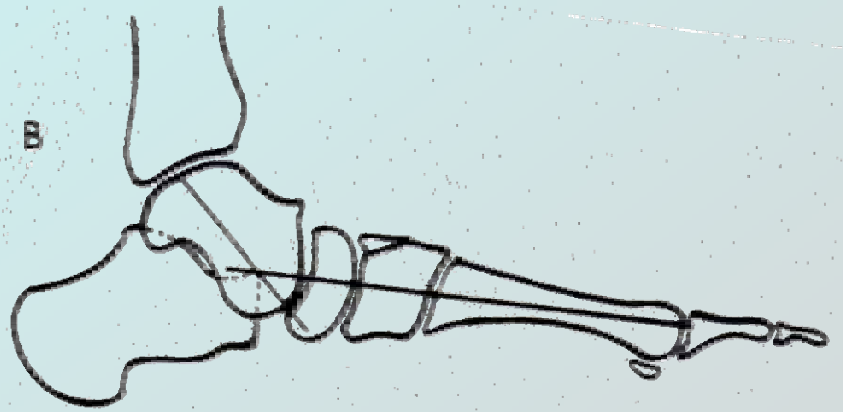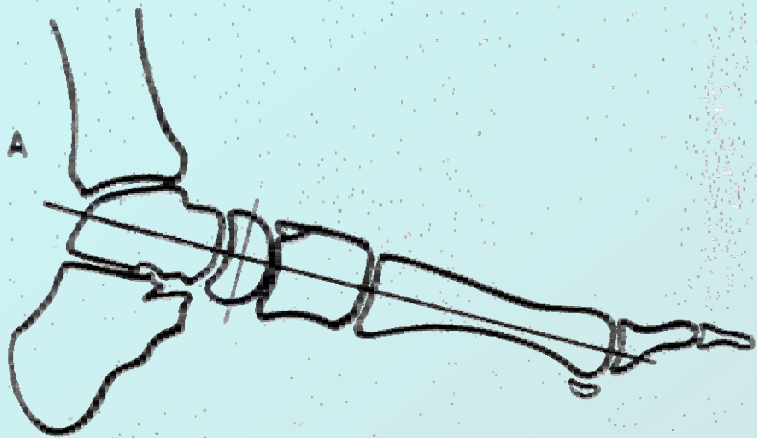


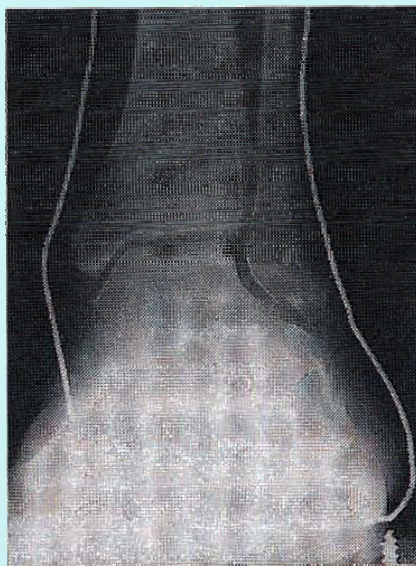




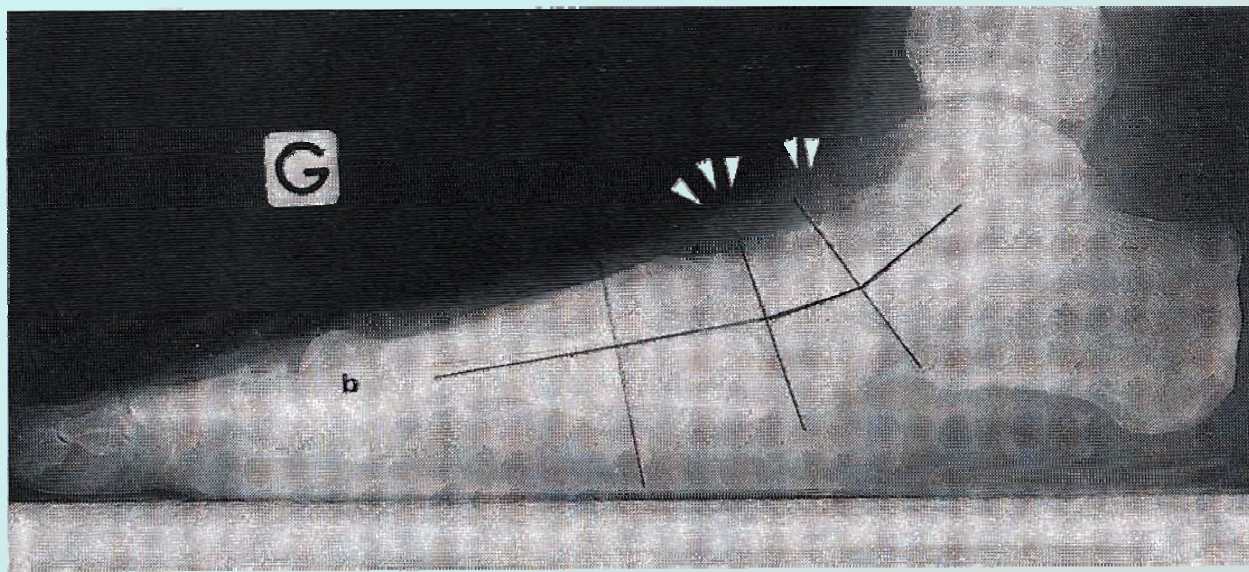








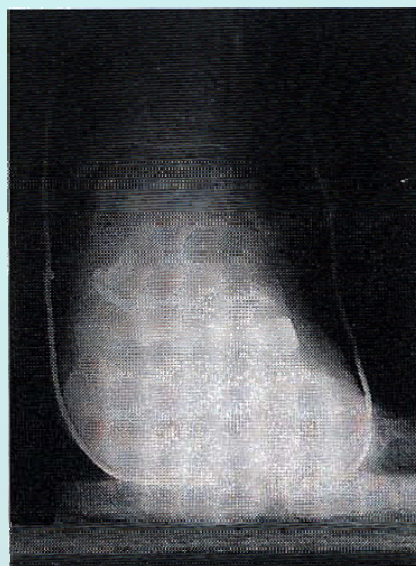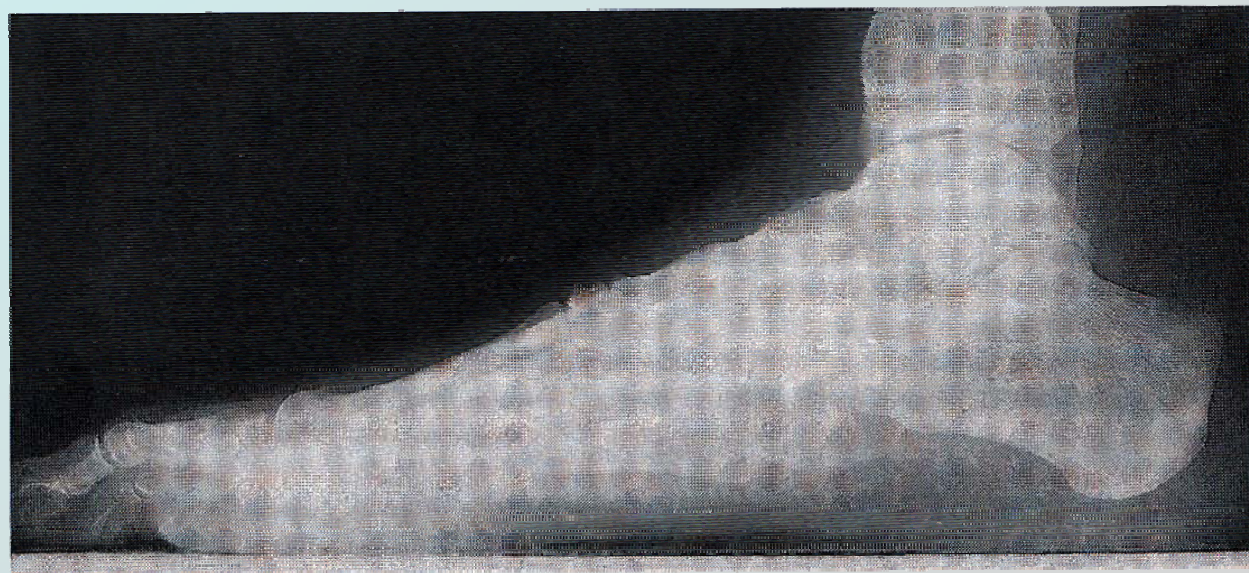
A



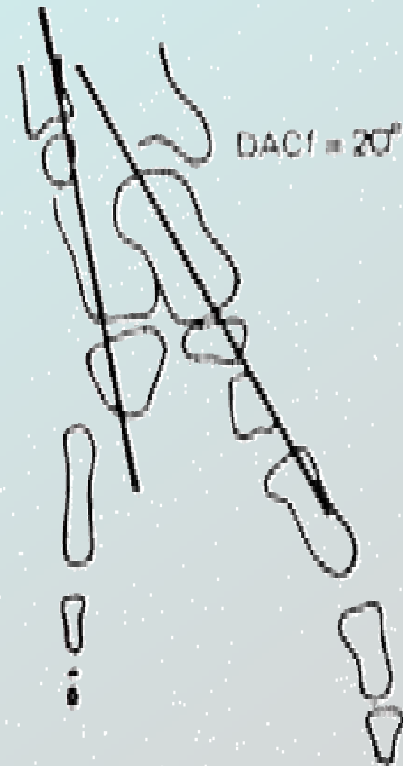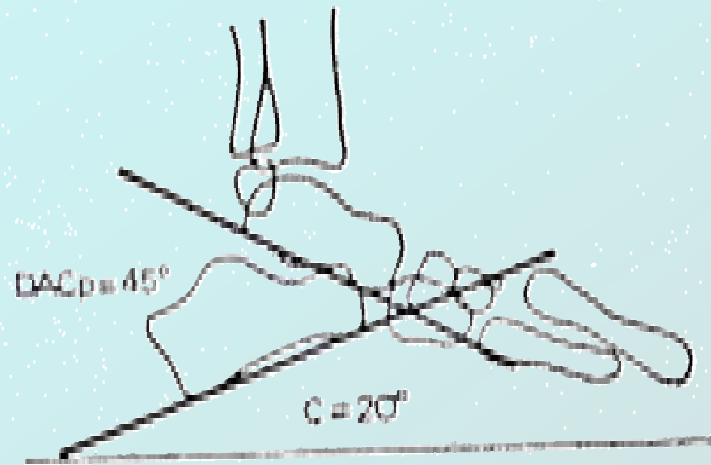
B

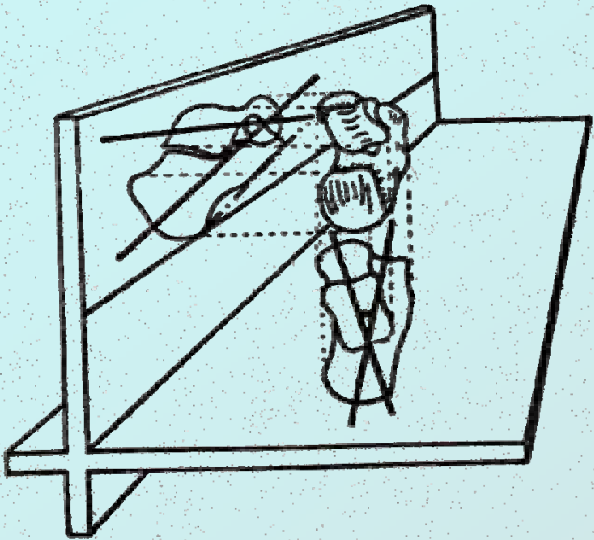


C

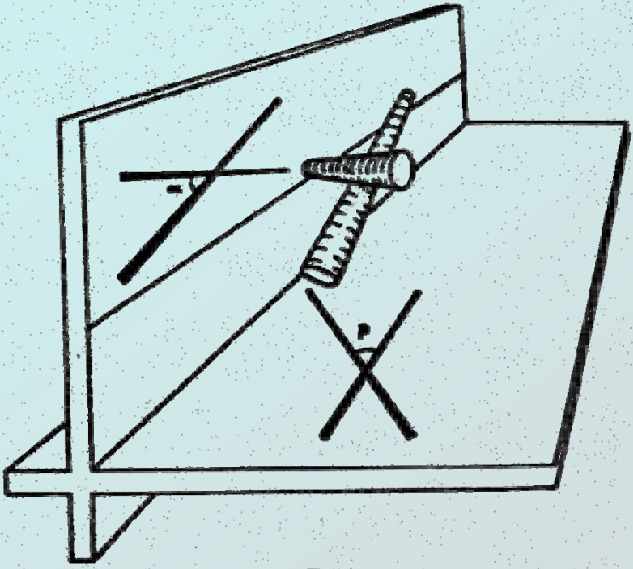


D

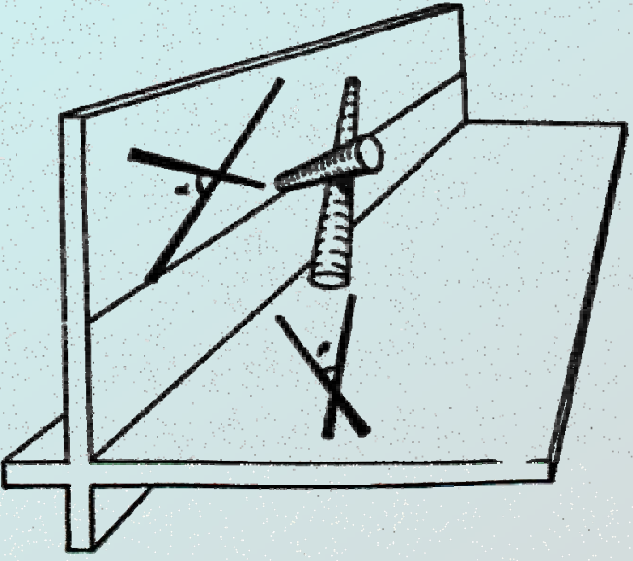




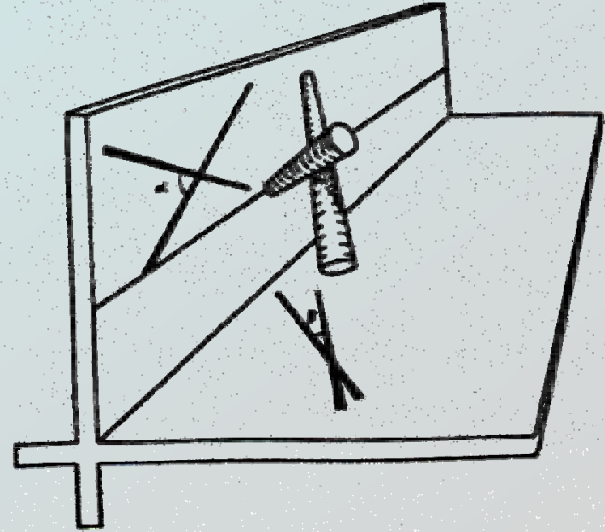
A



B

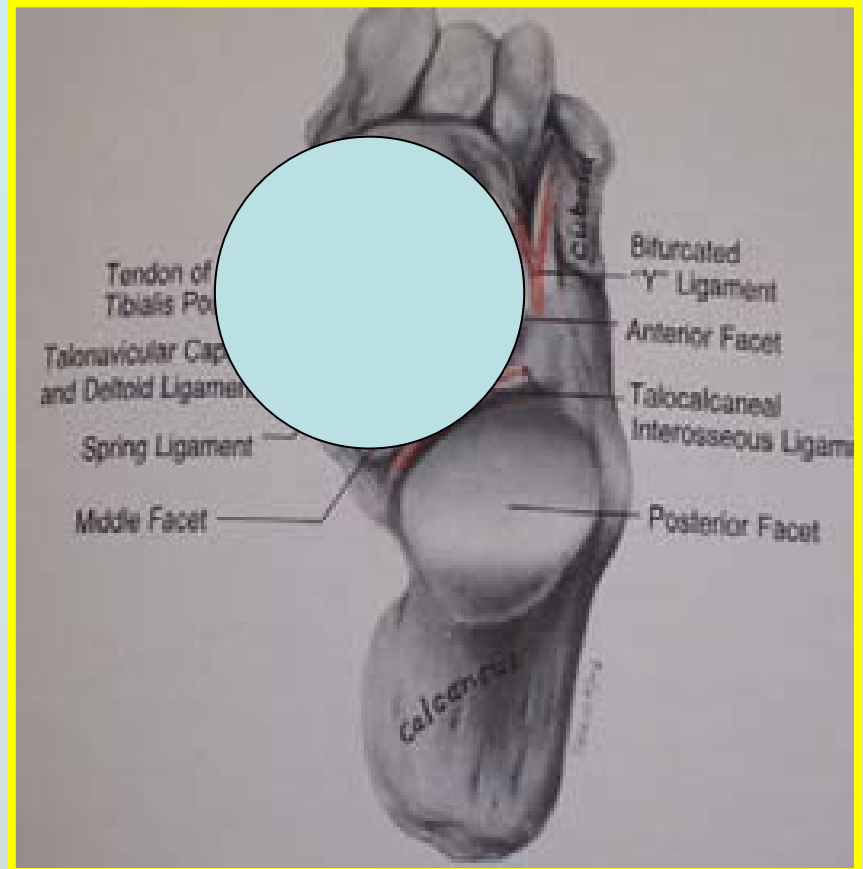


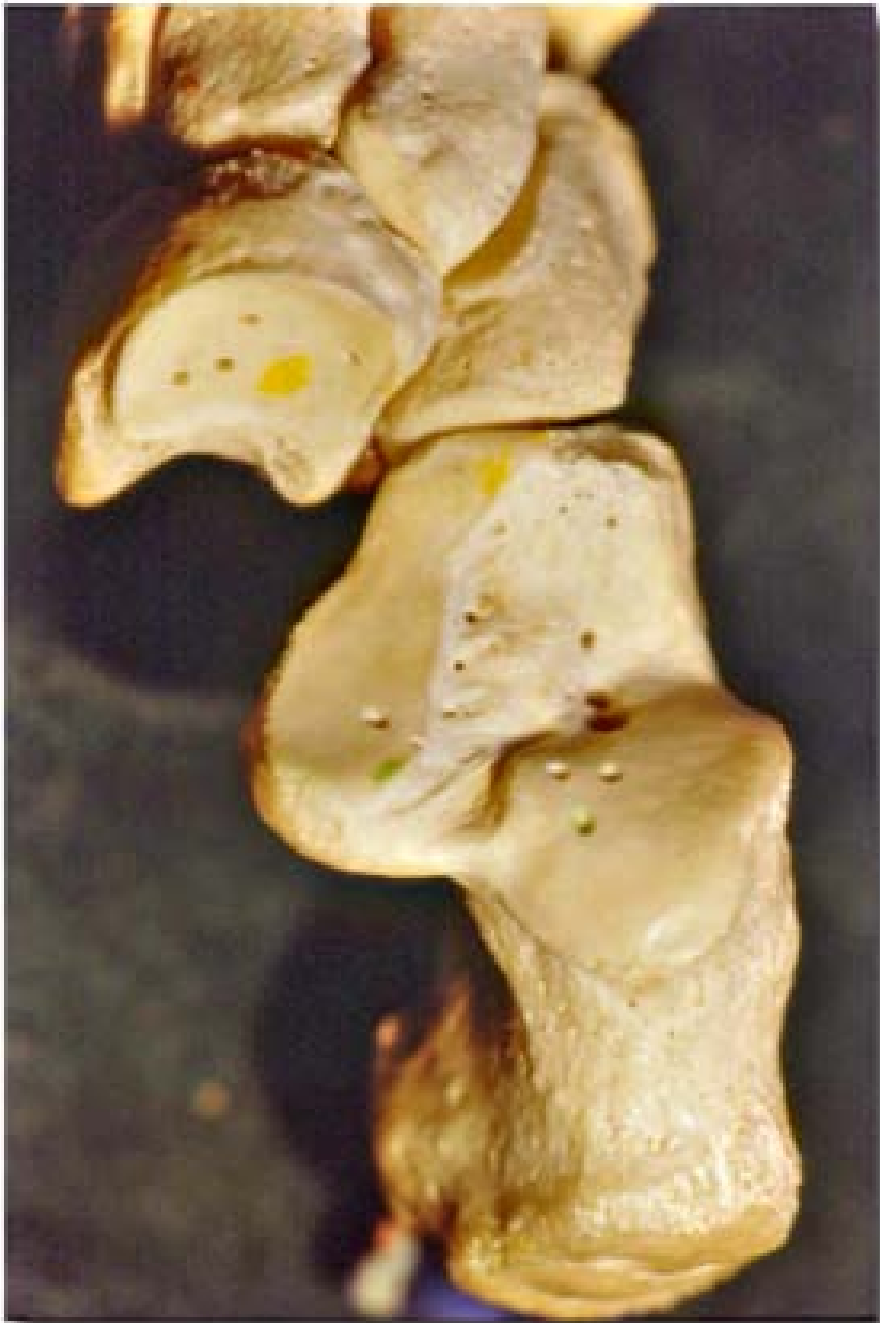C



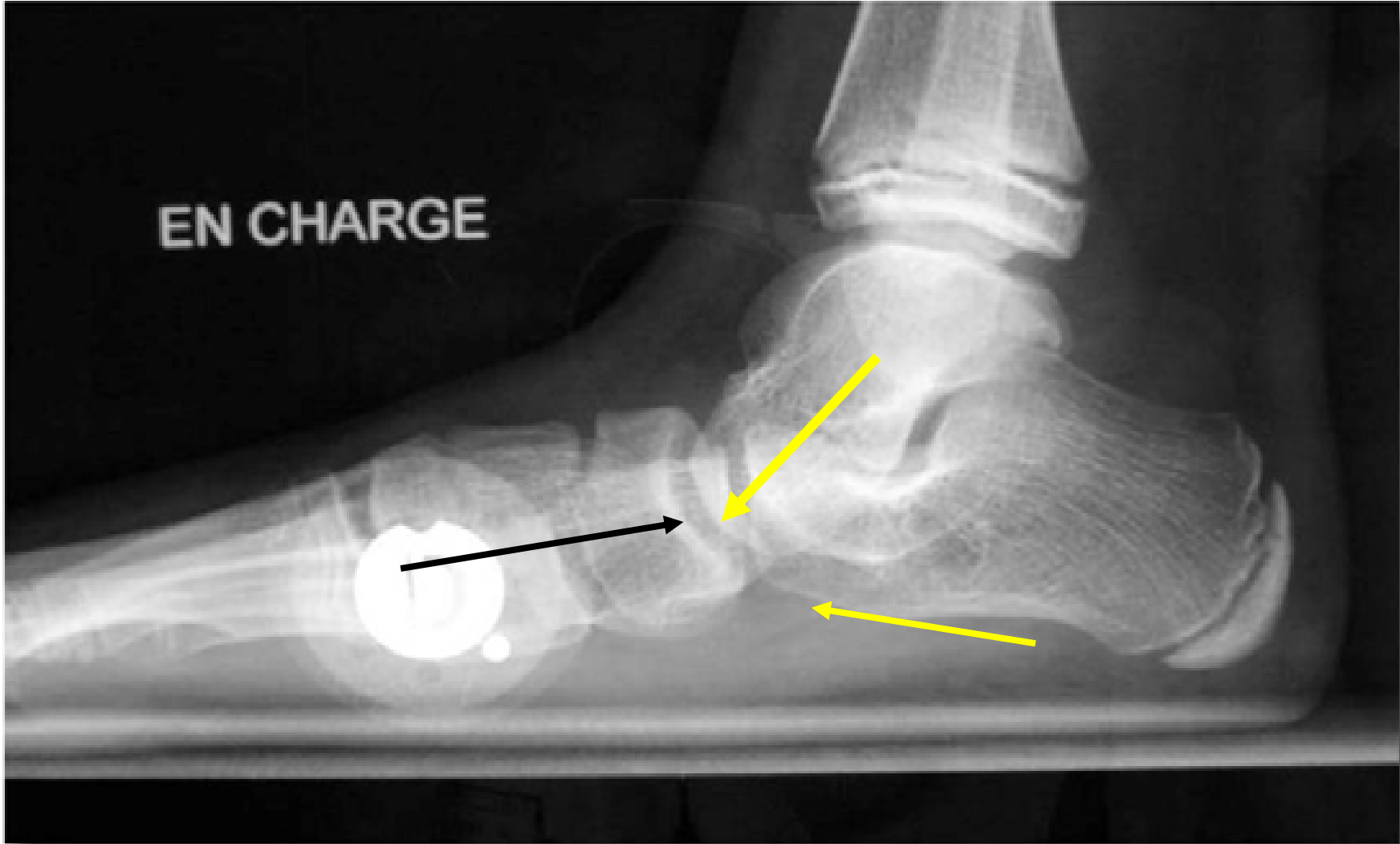D

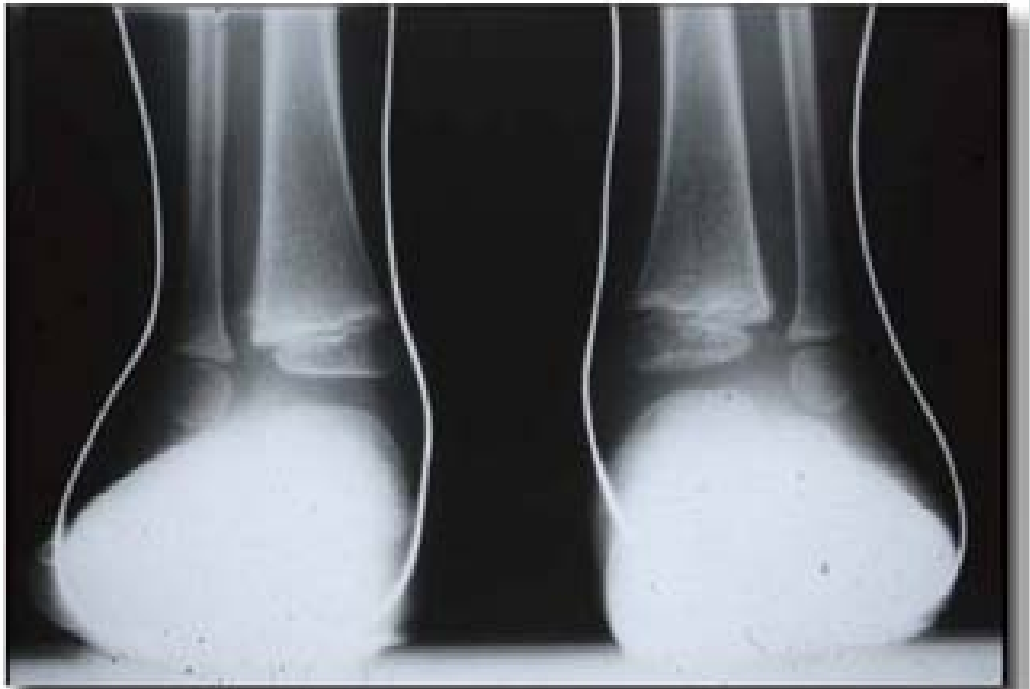
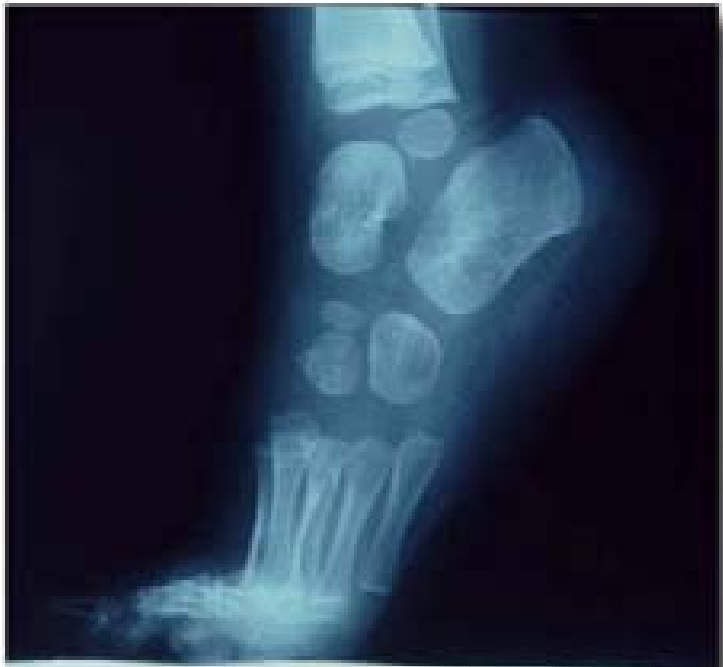
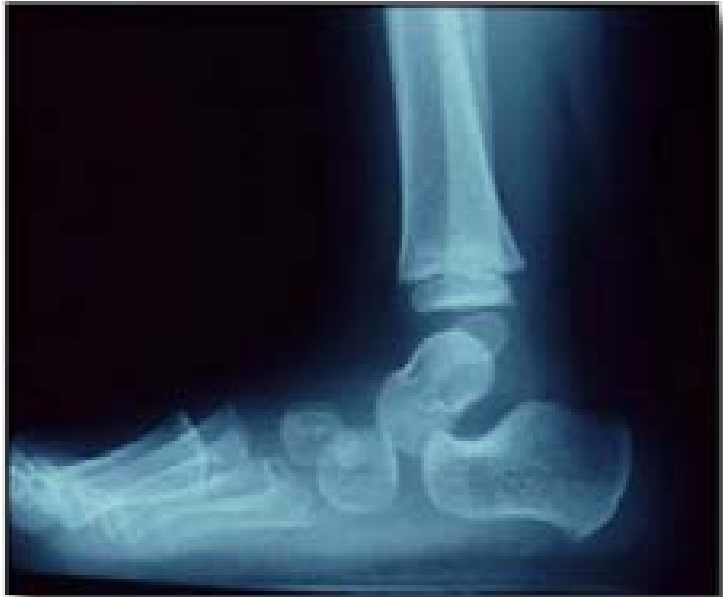



EN CHARGE

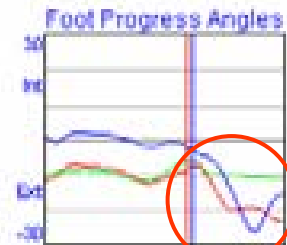
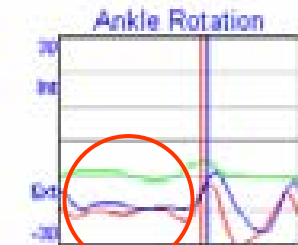
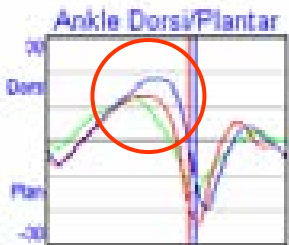
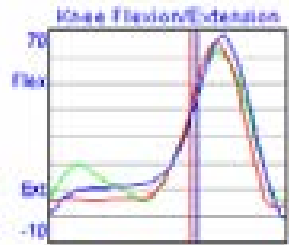
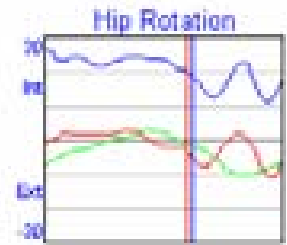
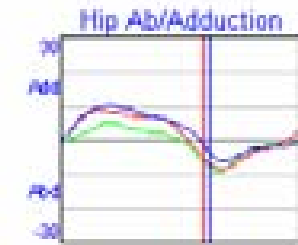
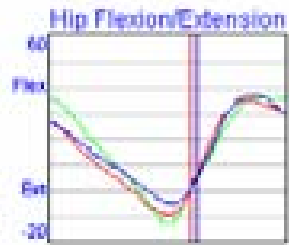
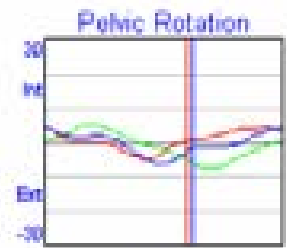
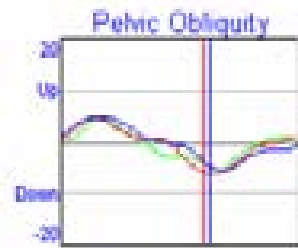
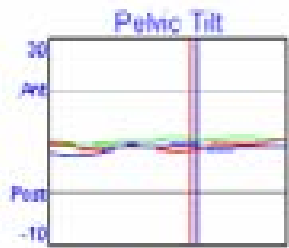




PIED PLAT : CINEMATIQUE, CINETIQUE, EMG

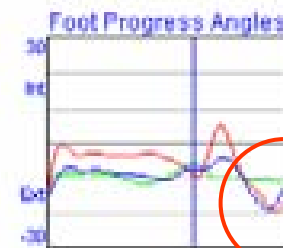


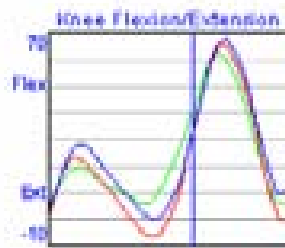
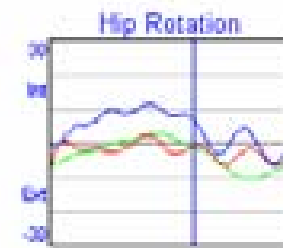
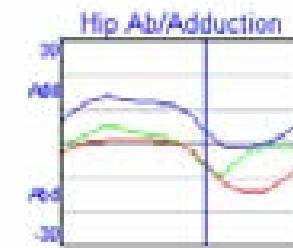
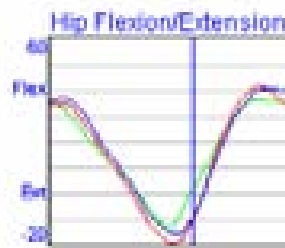
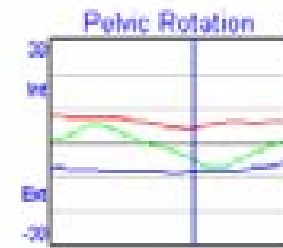
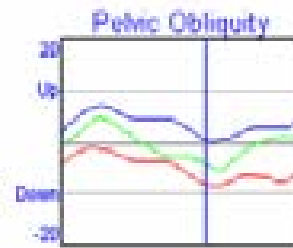
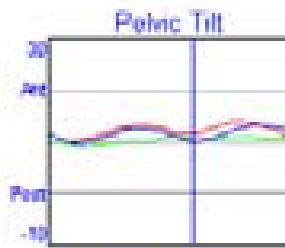




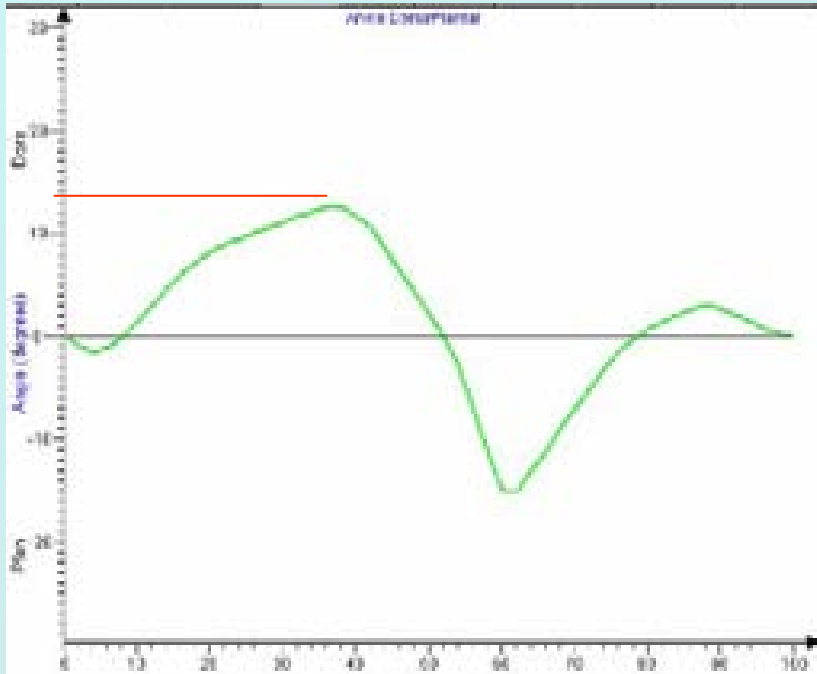




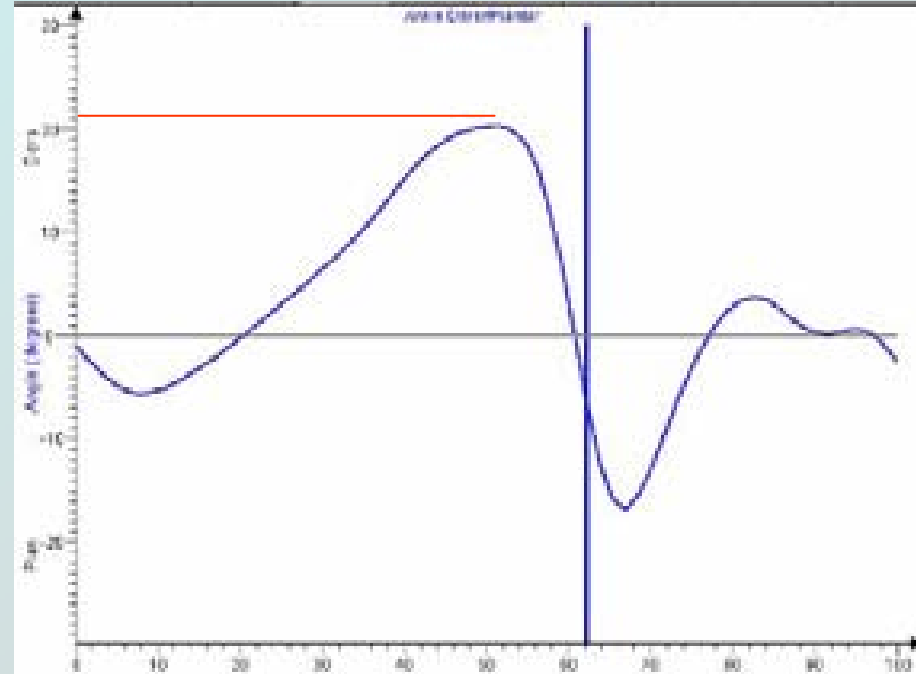




Accentuation flex dorsale de cheville



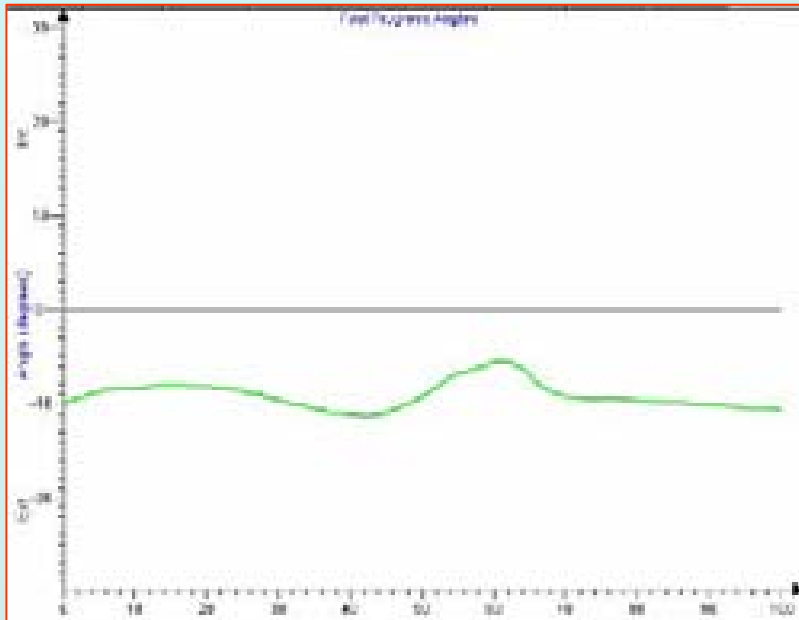
Normal



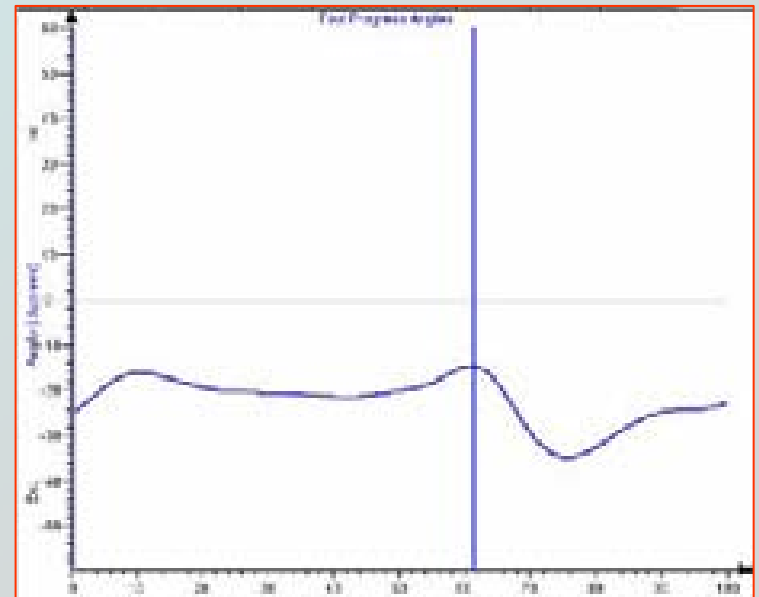
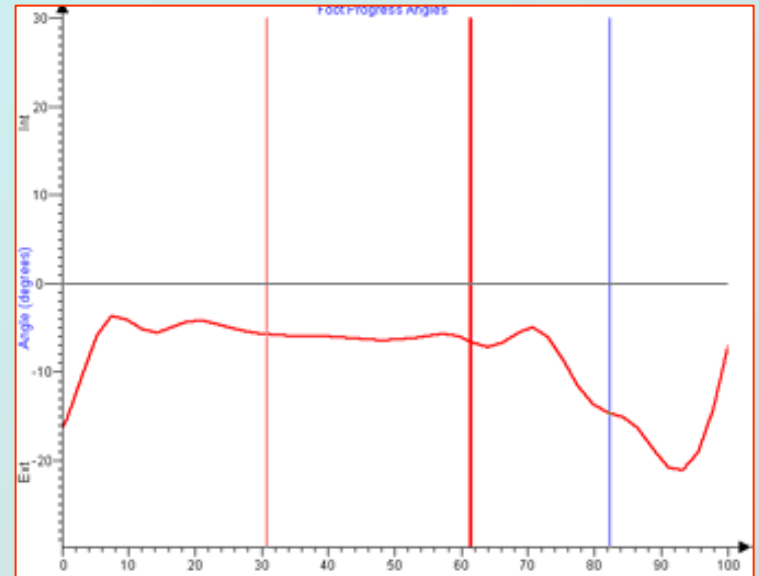
Pied plat

Anomalies

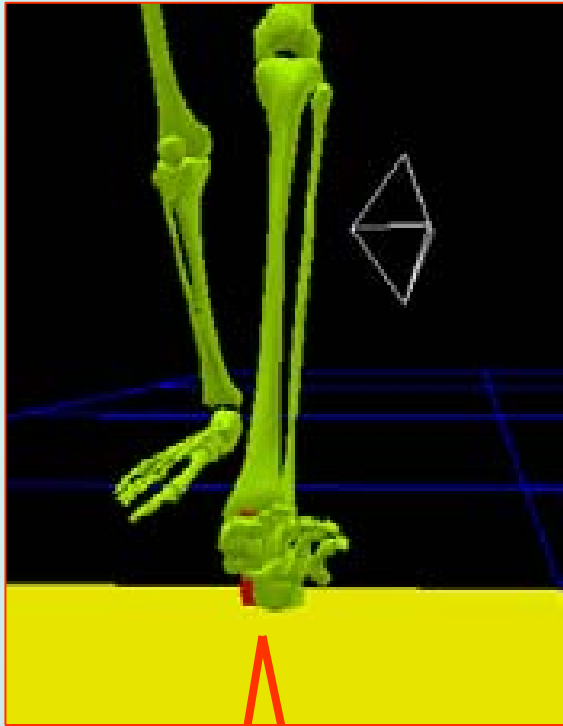
Angle de progression




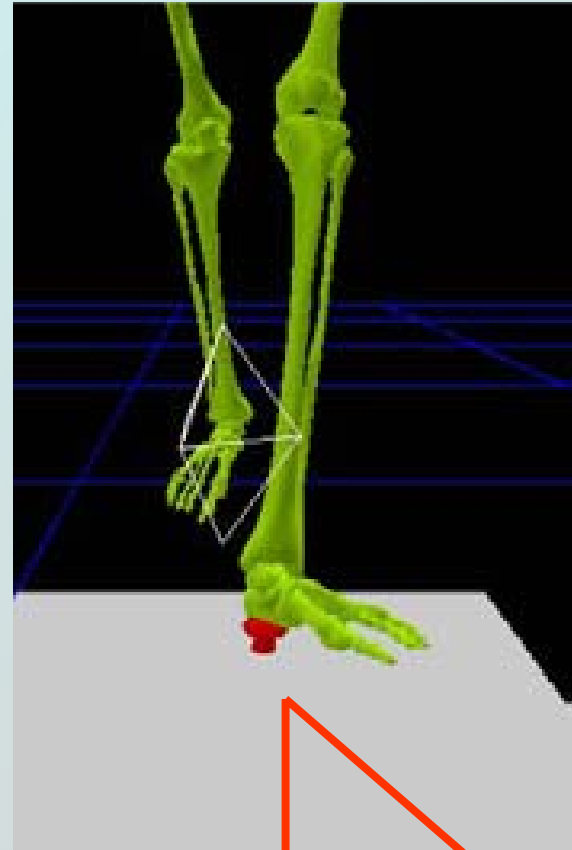
Normal



Normal



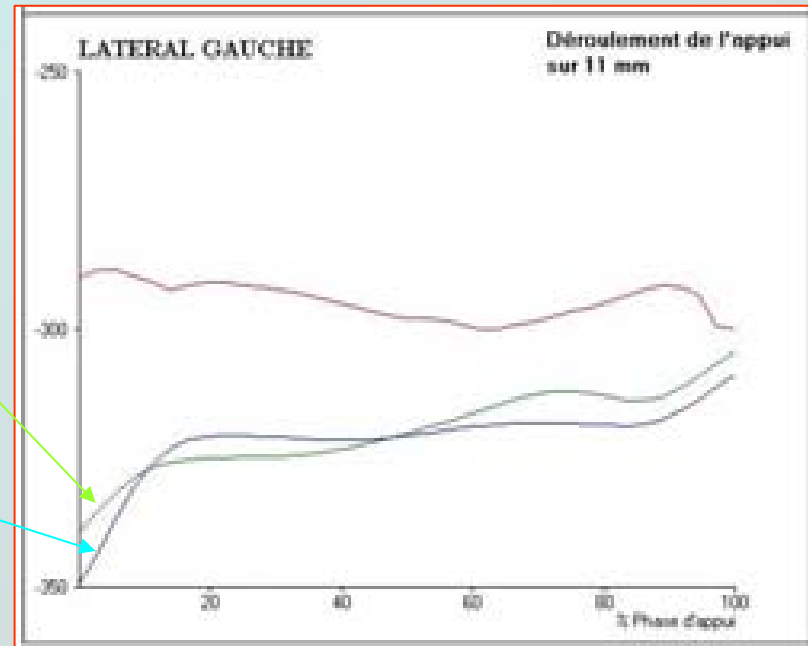
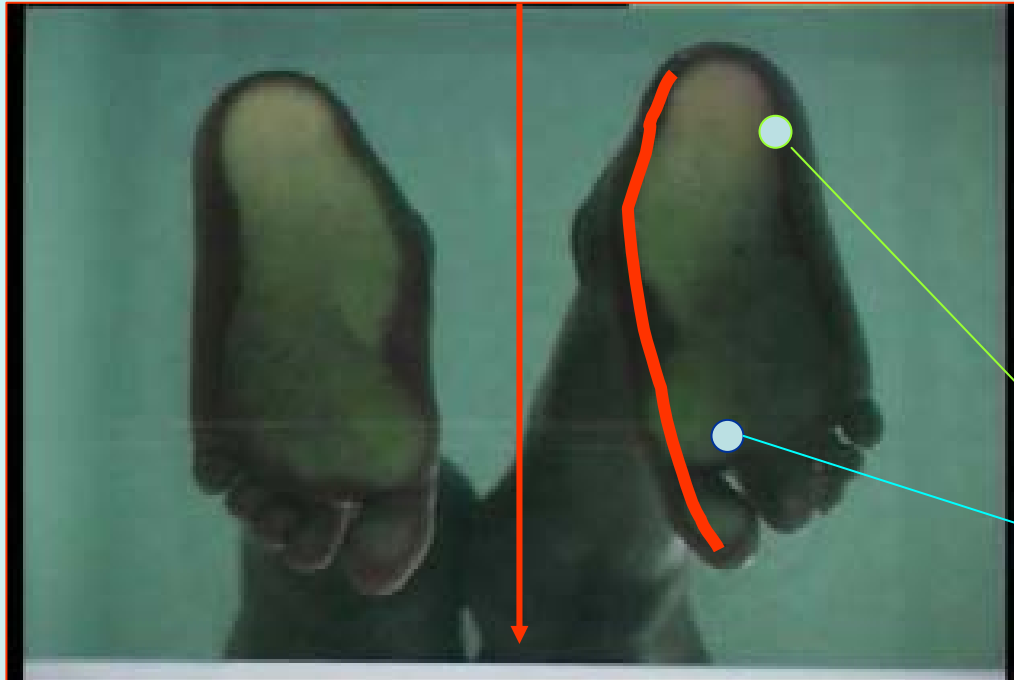
Pied plat

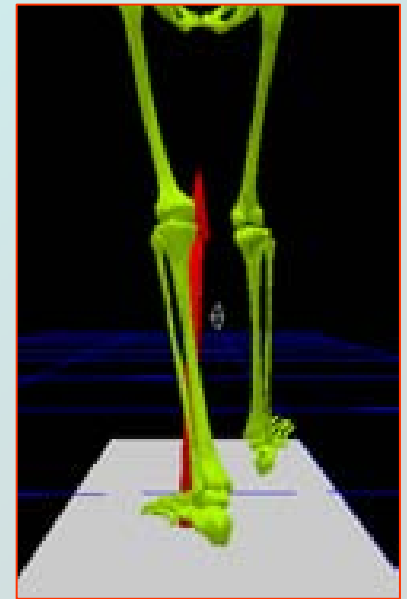
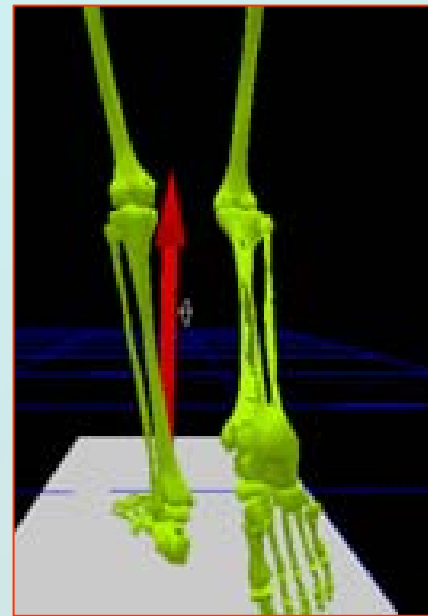
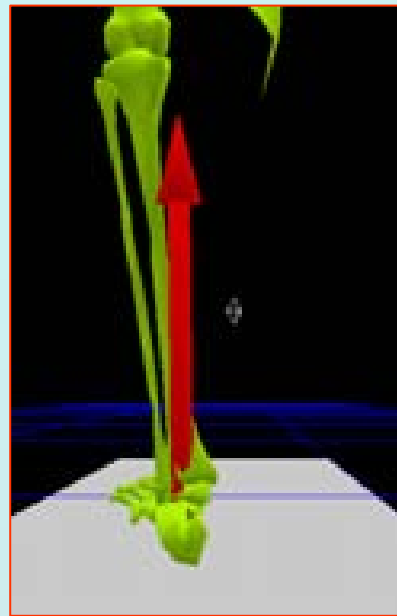
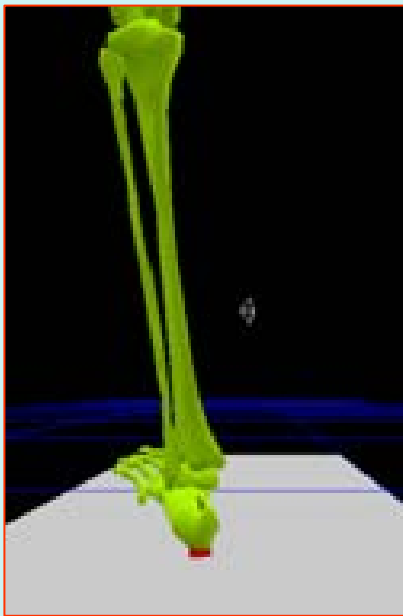


CINETIQUE

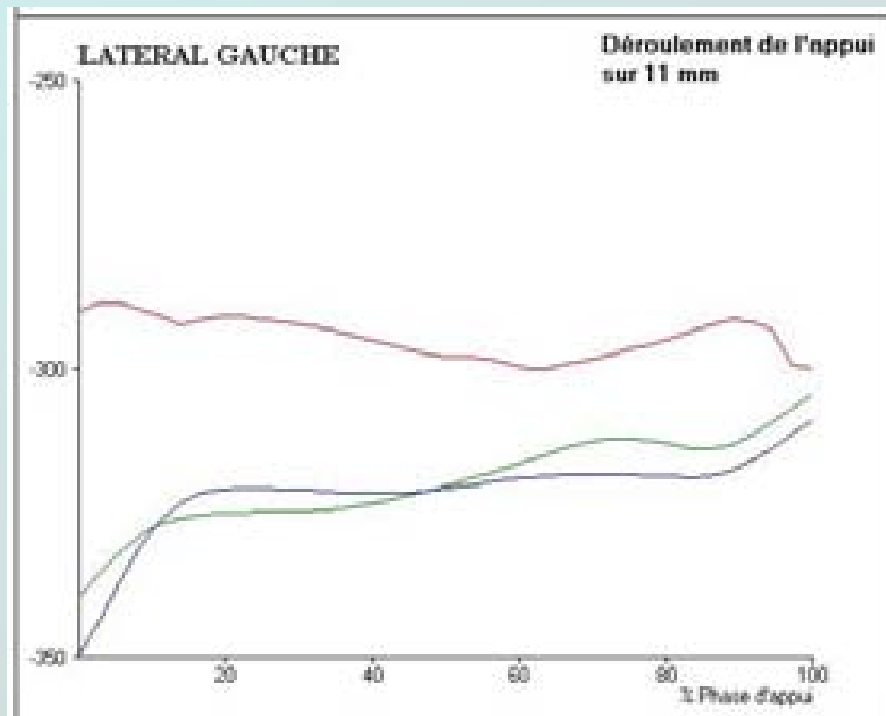


Point d'appui trop interne lors du déroulement du pas

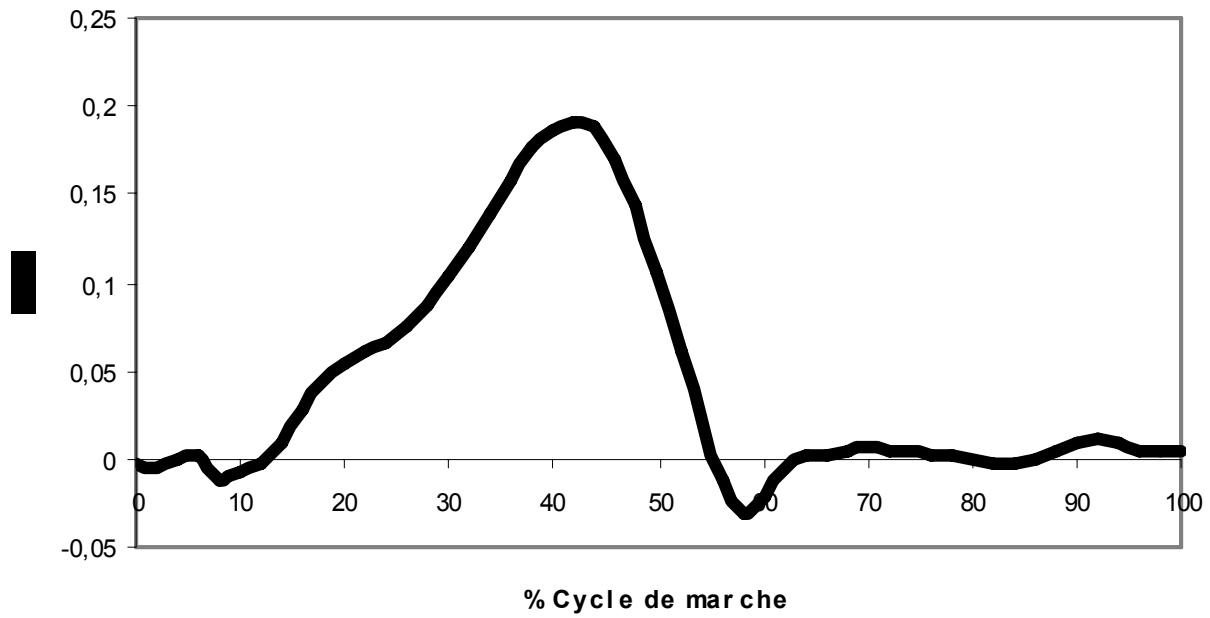




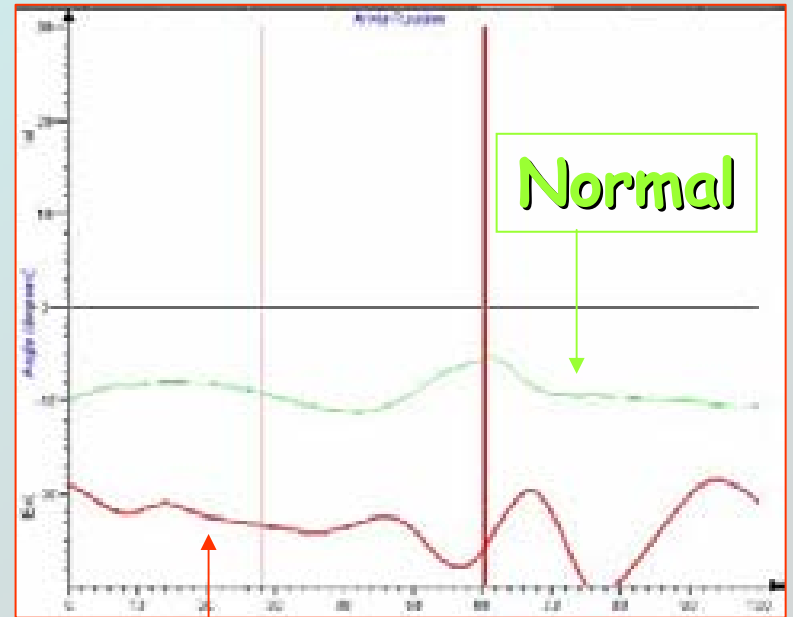
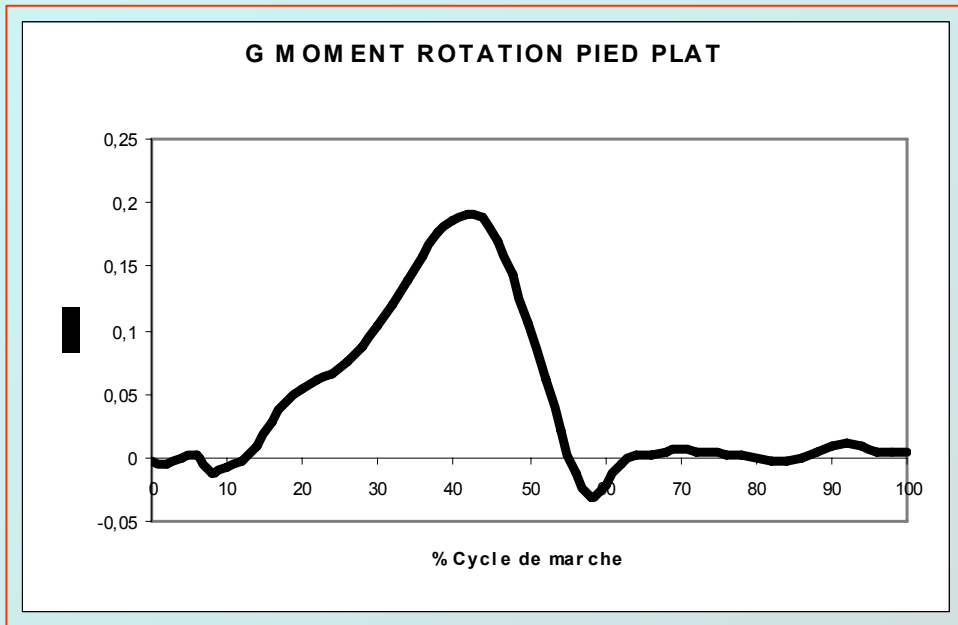
Pied plat



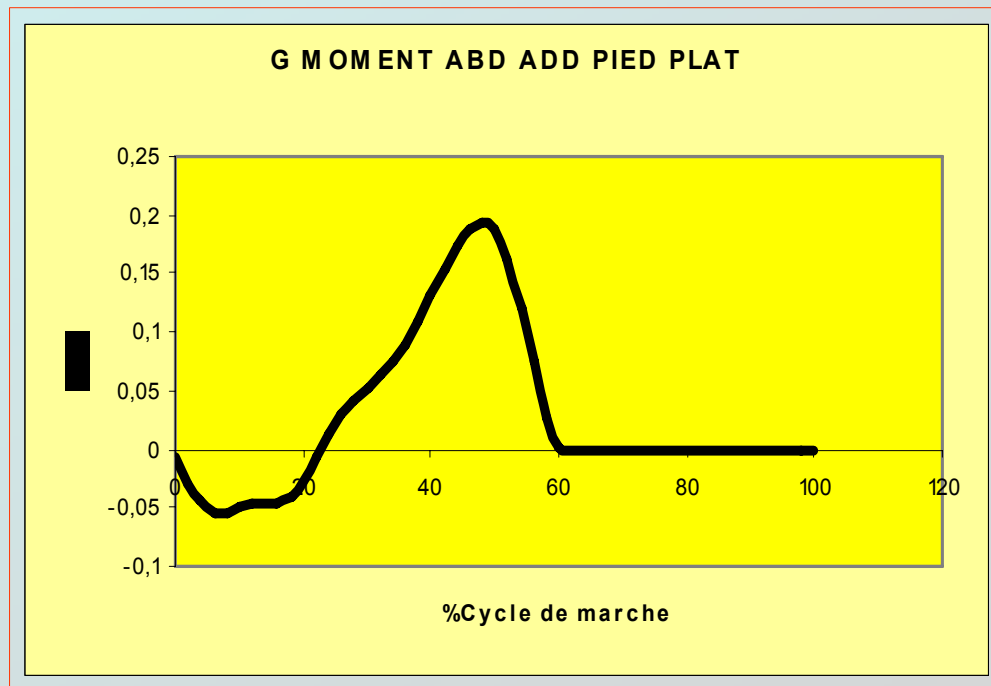
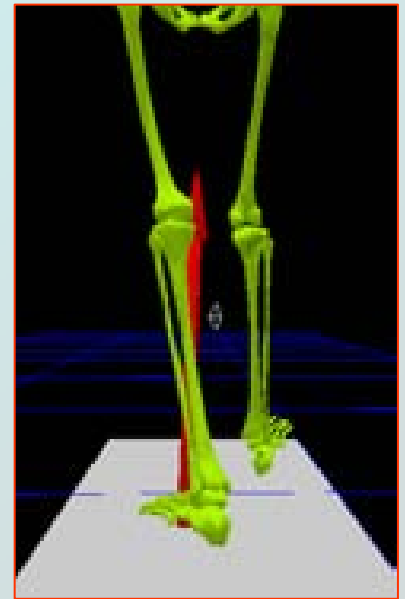
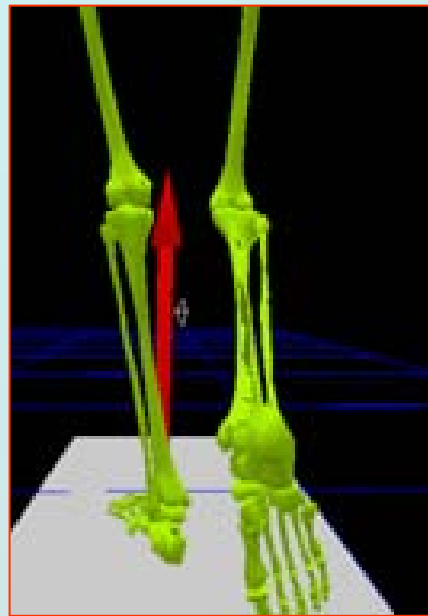
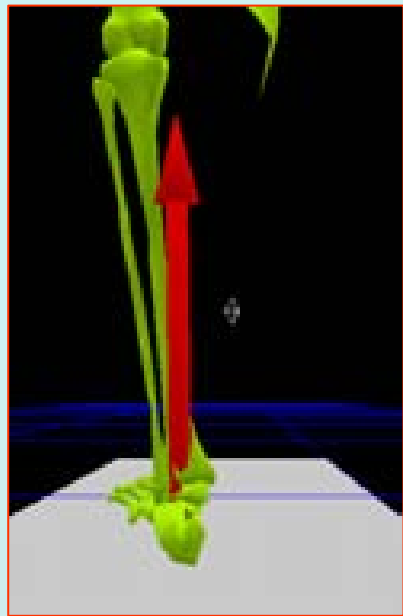
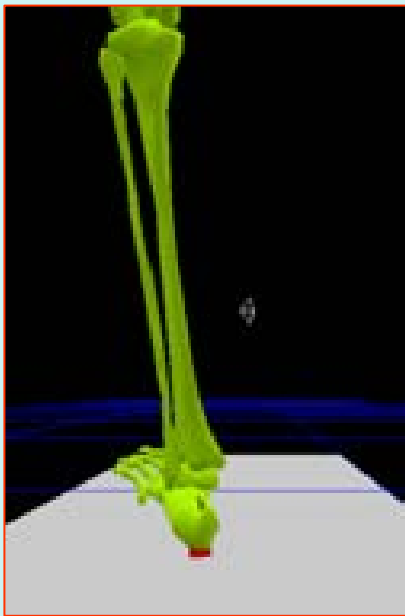
G MOMENT ROTATION PIED PLAT



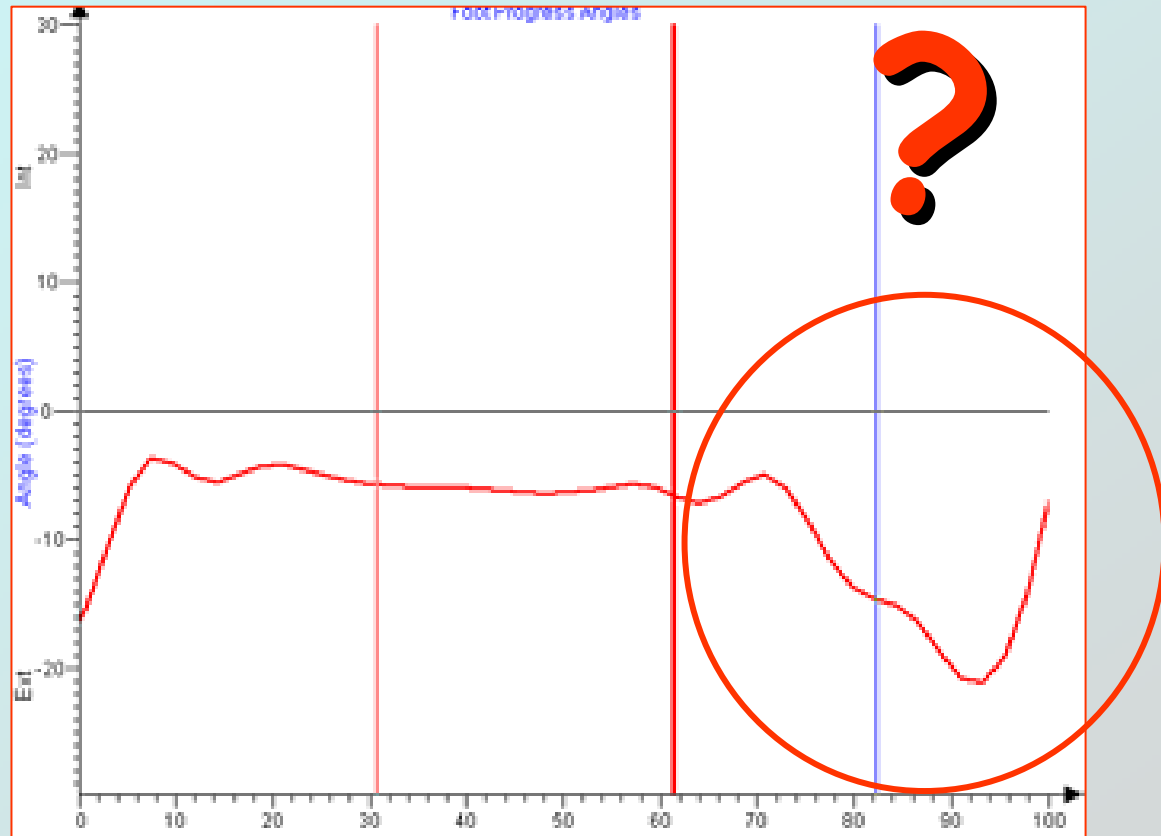
Le moment de rotation externe entraîne L'accentuation de la divergence talo calcanéenne



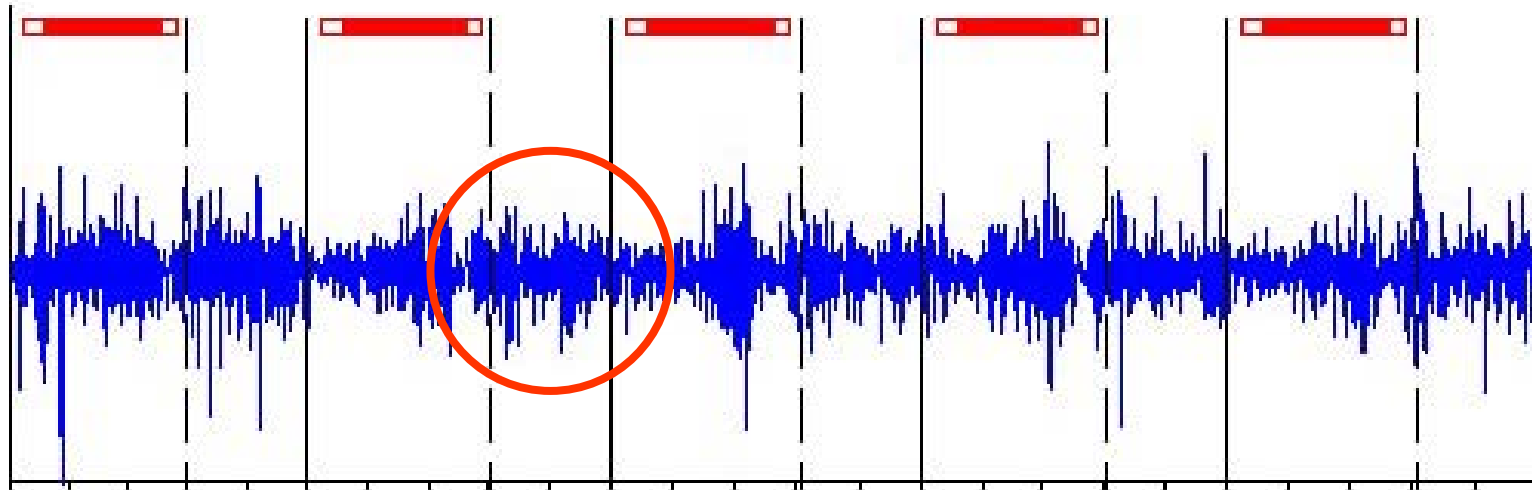
Pied plat



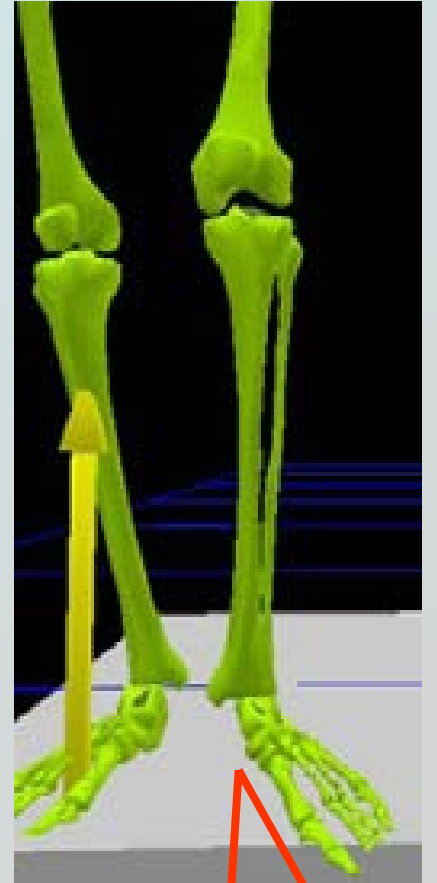
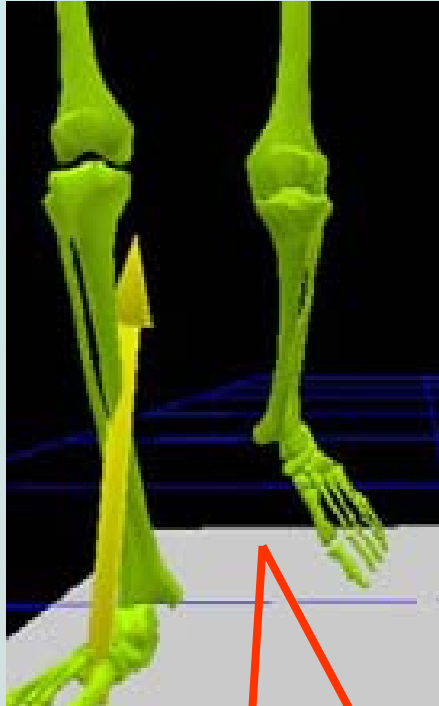
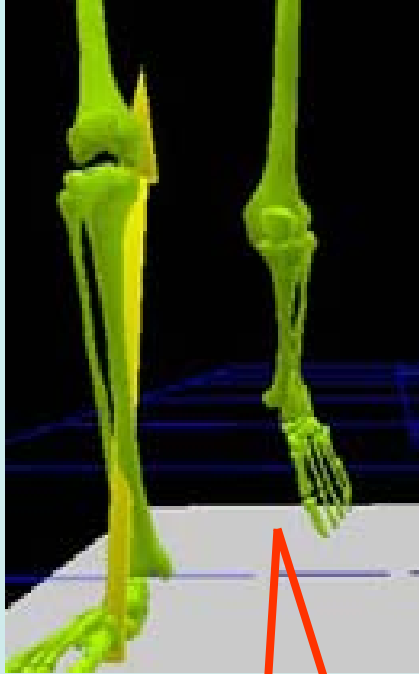
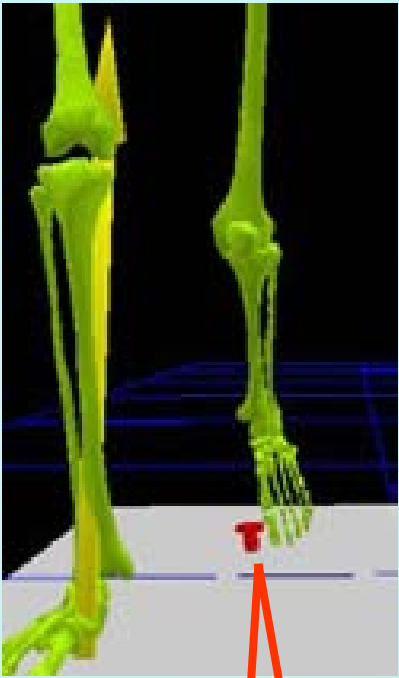
Accentuation de la rotation externe du pied en phase oscillante



Péroniers Gauche



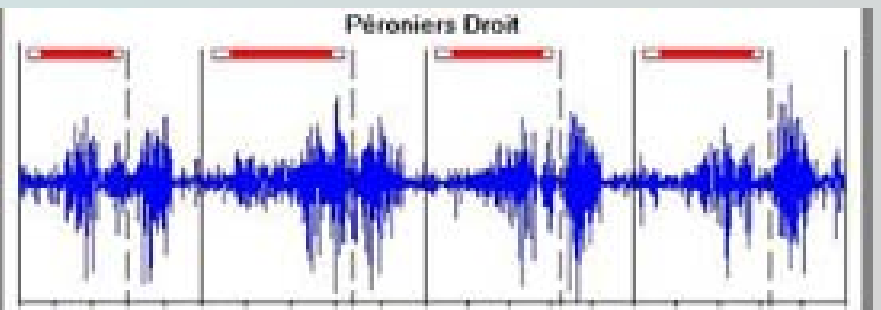
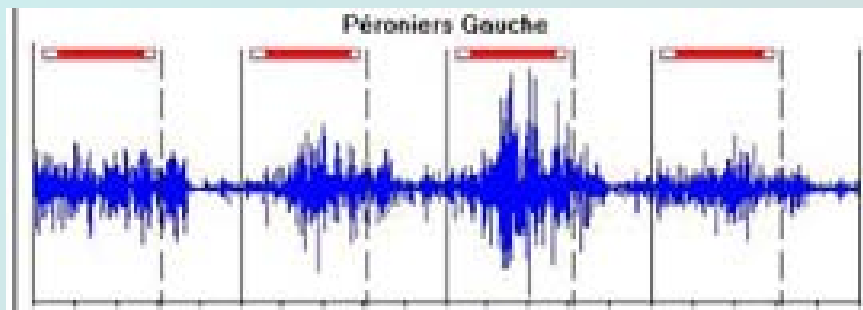
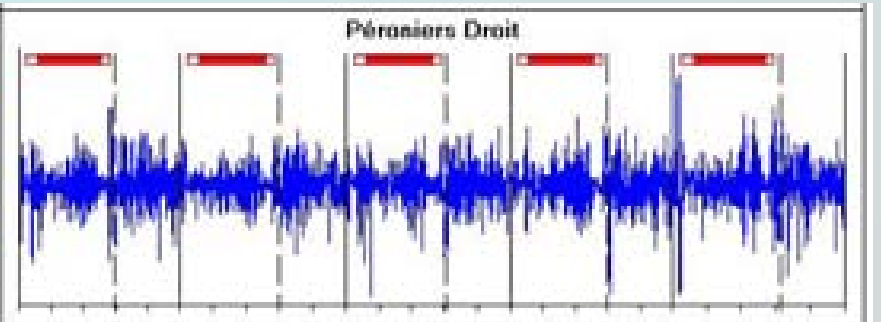
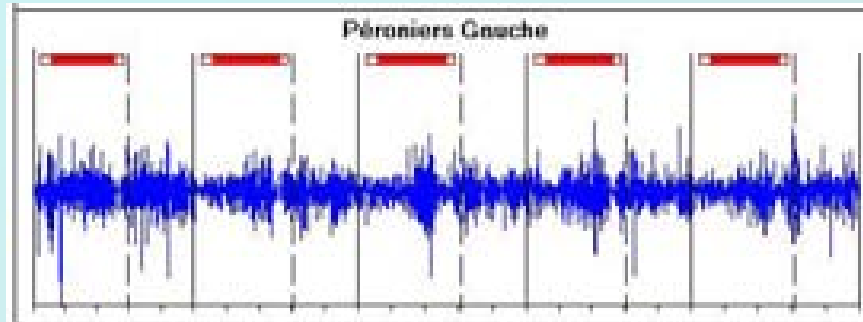
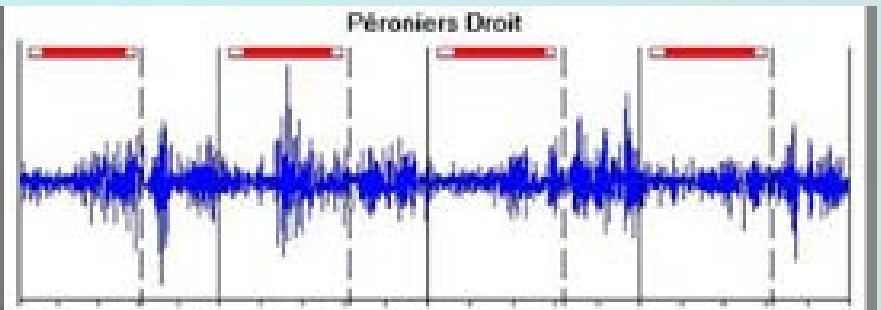
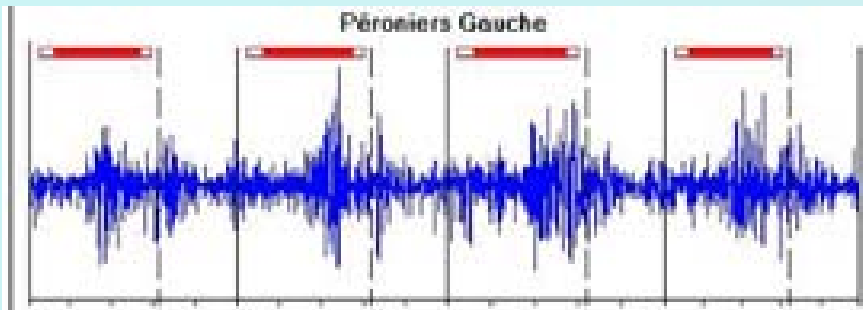




15 ENFANTS

avec pieds plats idiopathiques :

**30 Anomalies d'activité des
muscles fibulaires**



HYPOTHESES

Activité anormale des M fibulaires

Abduction Rotation externe

Moment d'abduction rot ext anormale

Augmentation de la divergence talo calc

Distension capsulo ligamentaire

ETIOLOGIE

- Pied plat valgus statique
- Pied creux externe
- Pied en serpent
- Anomalies neuro-musculaires
- Malformations intrinsèques osseuses et cartilagineuses

Résolutifs

Invétérés

ETIOLOGIE

ANOMALIE CONSTITUTIONNELLE

- Pied plat valgus
- Pied convexe
- Pes abductus

ANOMALIE ARTICULAIRE

- Synostose
- Traumatique
- Inflammatoire

ETIOLOGIE II

AFFECTION NEURO-MUSCULAIRE

- Fonctionnel
 - Rupture du JP ou naviculaire
- Paralytique
 - Paralysie spastique, hémiplégie

DESEQUILIBRE PROPRIOSEPTIF

- I.M.C.
- Retard mental
- Cécité congénitale

COLLAGENOSSES

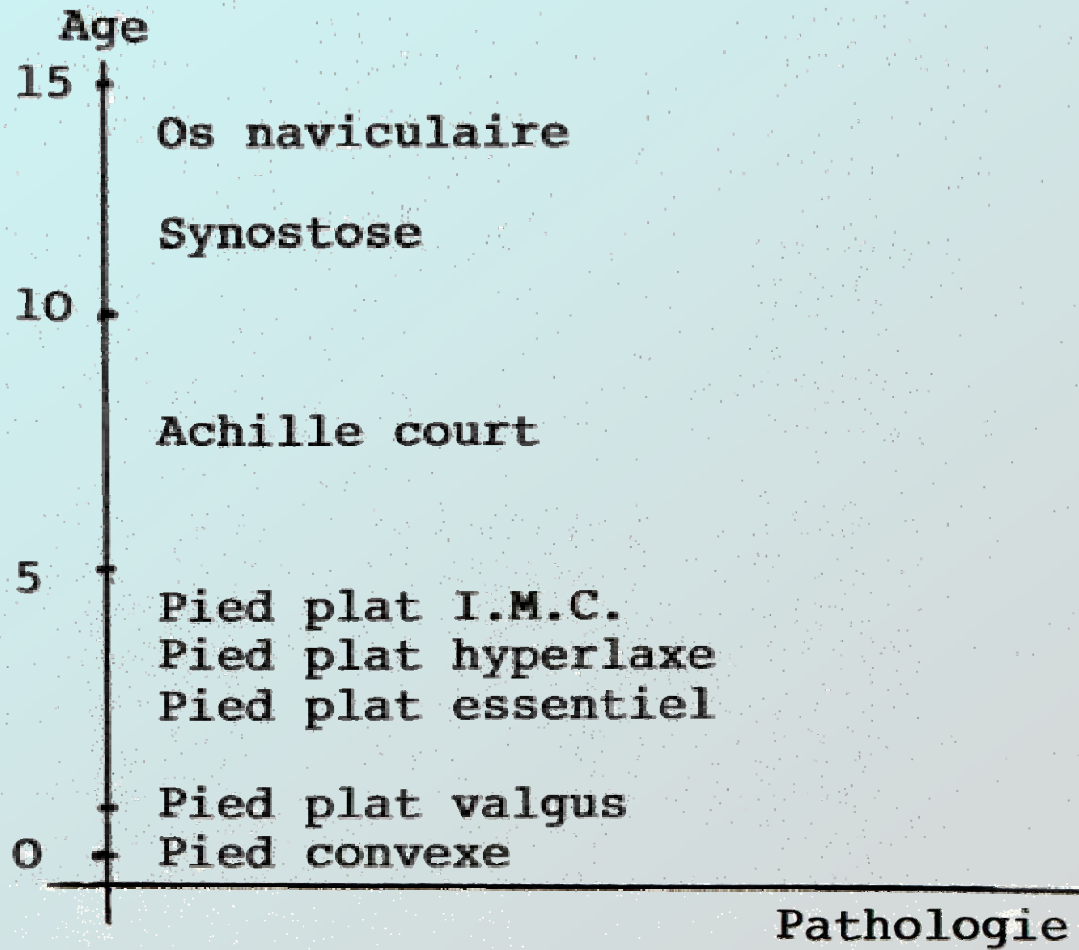
- Marfan
- Larsen

PIED PLAT CONSTITUTIONNEL

PIED PLAT STATIQUE

PIED PLAT SECONDAIRE

- Genu valgum
- Tibia varum
- Torsion squelette jambier
- Achille court
- Anomalie tendineuse
- Os naviculaire
- Synostoses



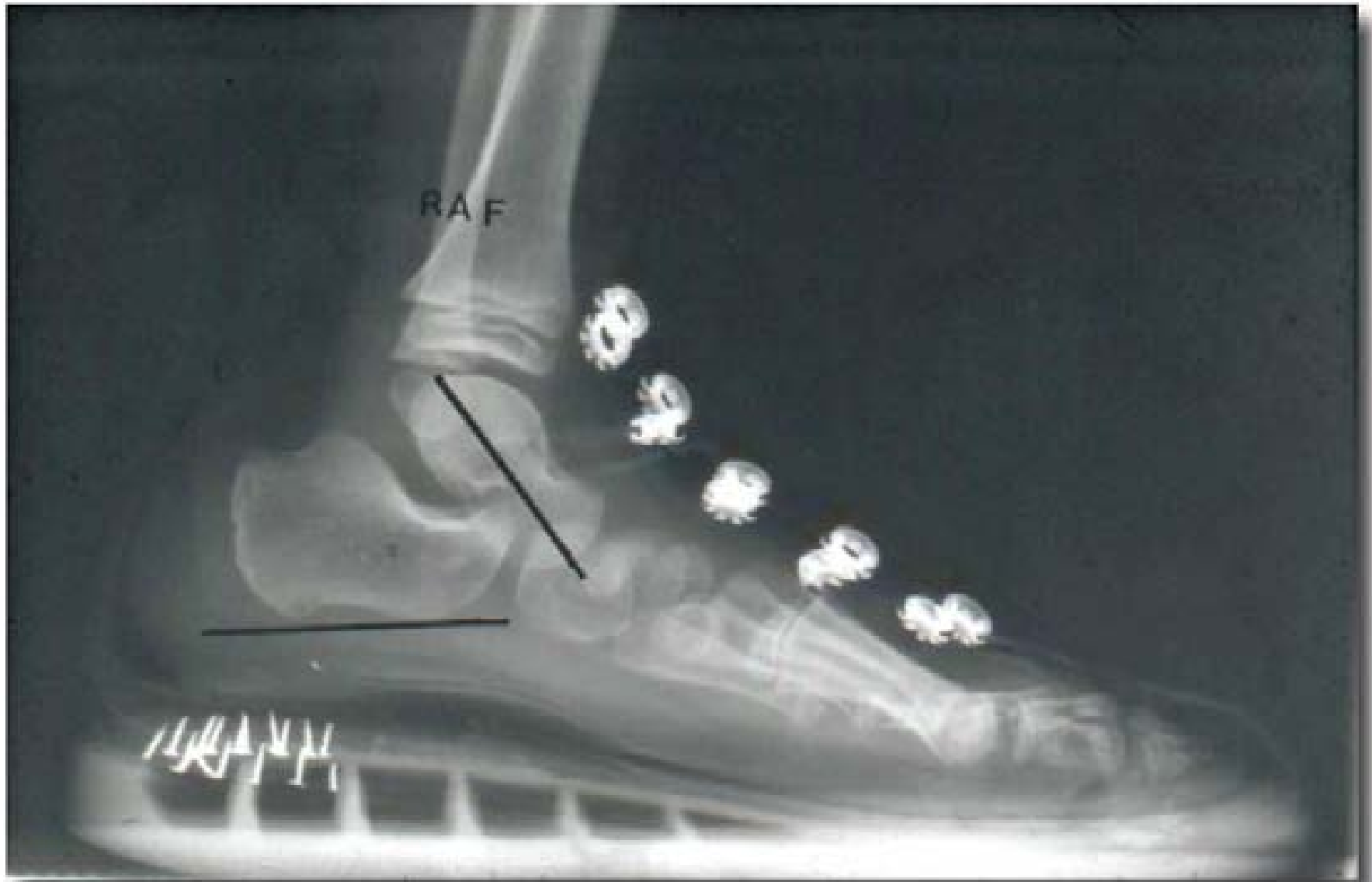TRAITEMENT

Kinésithérapie

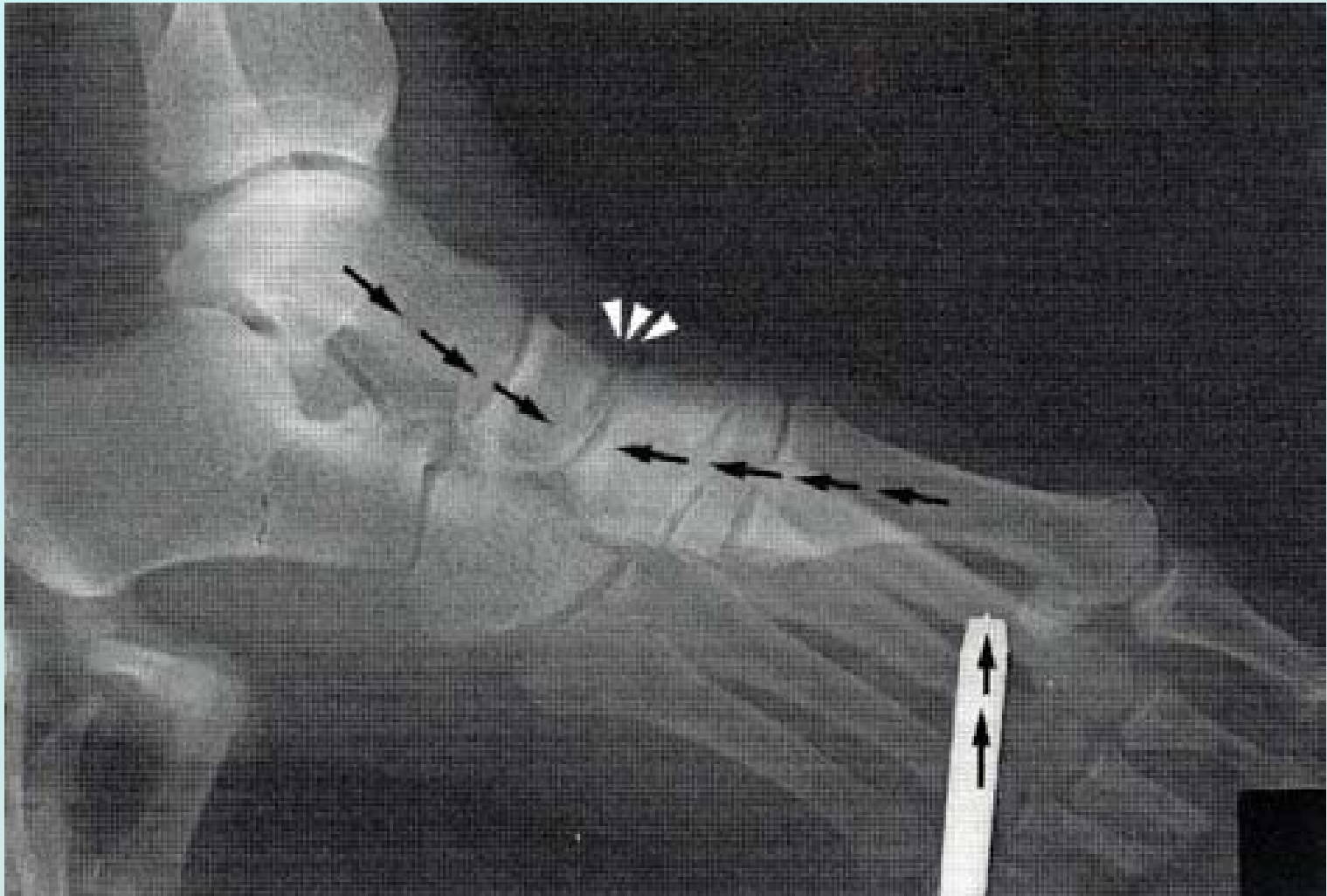Orthèses, UCBL, Wenger 1989

Chirurgie

- Grice
- Implant
 - Voutey
 - Giannini
- Cavalier
- Parties molles
 - (Giannestras)
- Ostéotomie calcanéum







PLACE DE LA « Chirurgie »

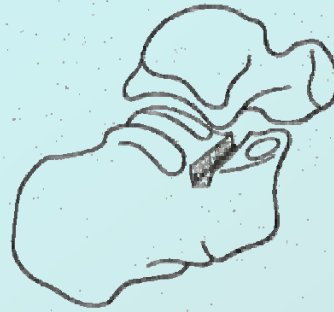

FIG. 1. — Préparation de la tranche calcanéenne.

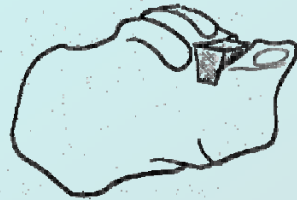
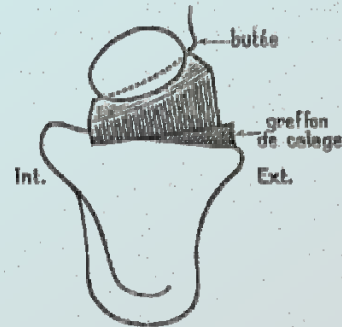


FIG. 3. — Position du greffon sur la tranche calcanéenne.

FIG. 4. — Mise en place du greffon dans le sinus du tarso.



Traitement chirurgical du pied plat de l'enfant

par

H. VOUTEY

(Dijon)

B.

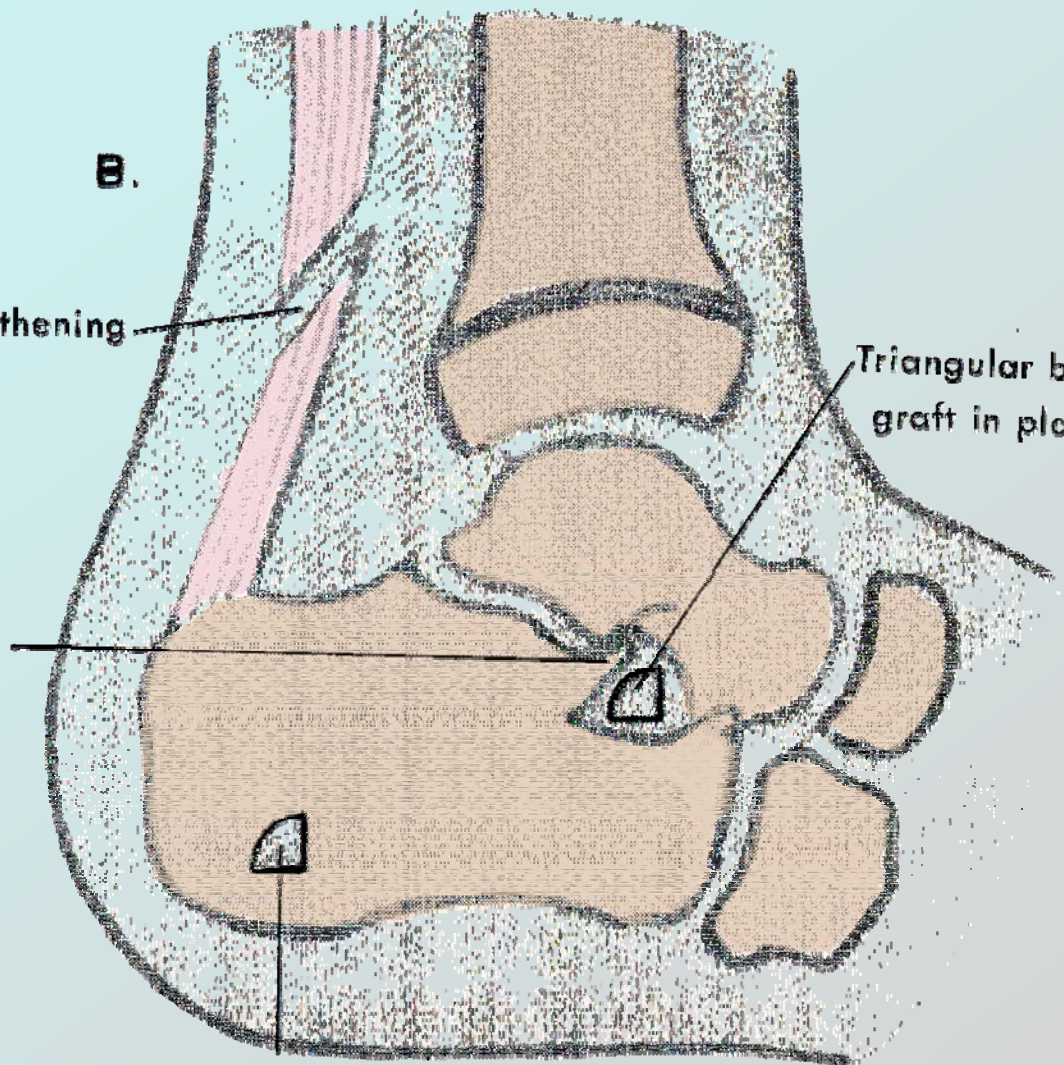
Coronal heel cord lengthening

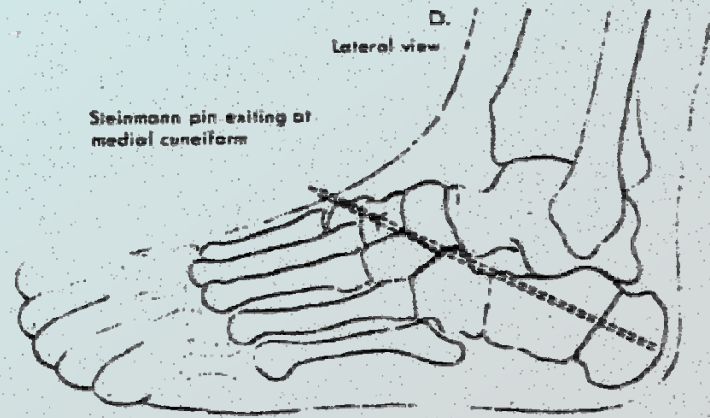
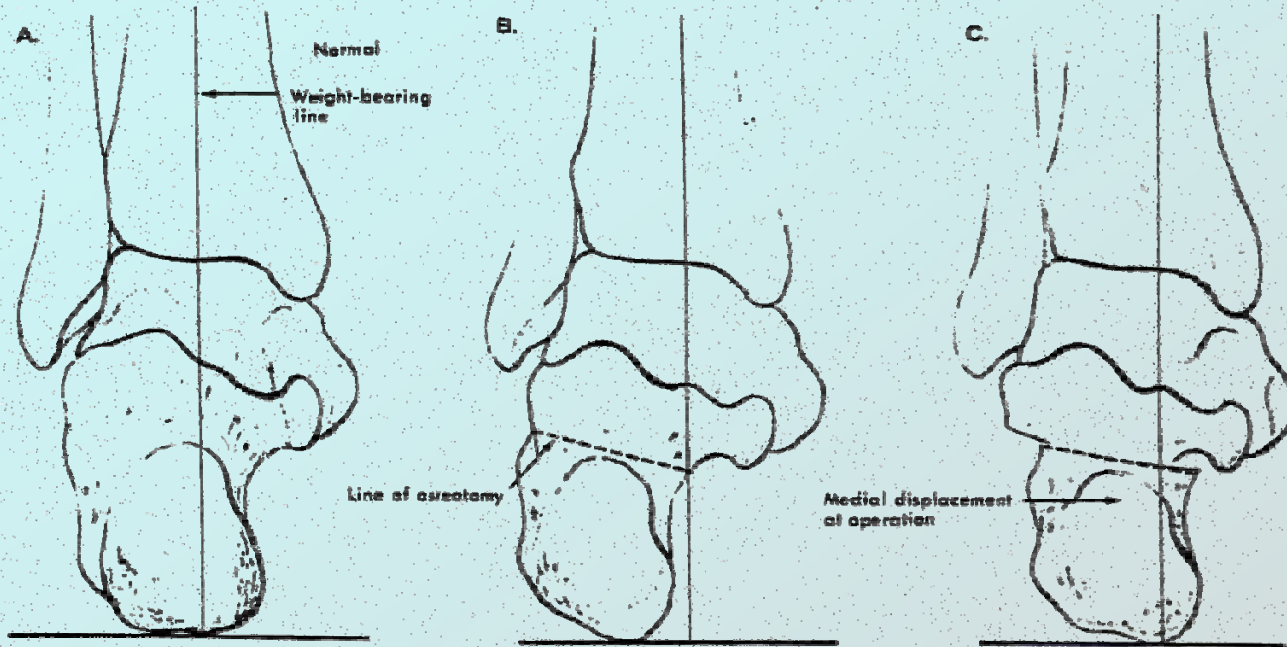
Bone flap rotated upward and inward against shoulder of talus

Triangular bone graft in place

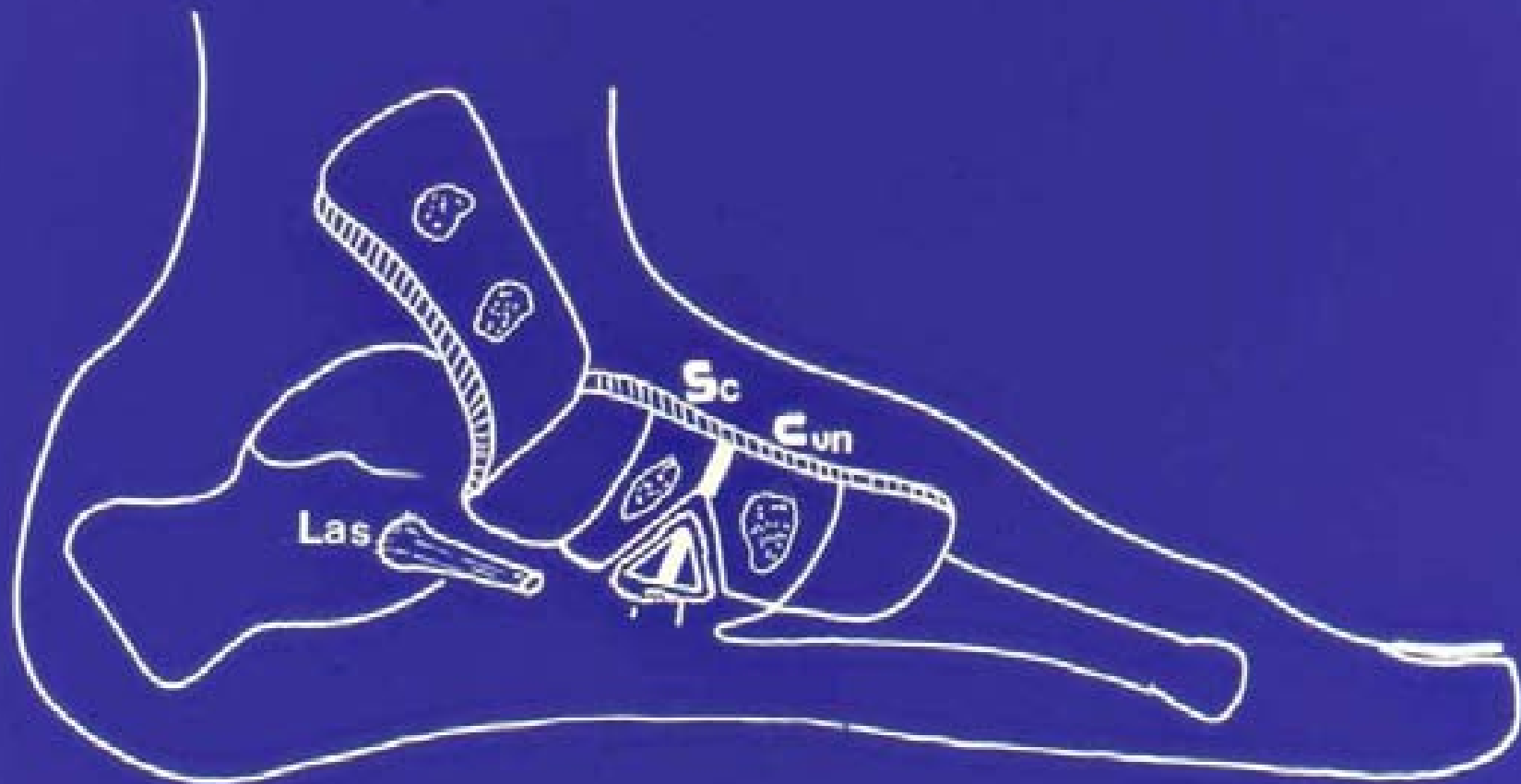
Donor area of bone graft
(beneath peroneal tendons)

T. Brack





Medial displacement osteotomy of the calcaneus in severe pes planovalgus.





Flexible Pes Planovalgus (Flat Foot)

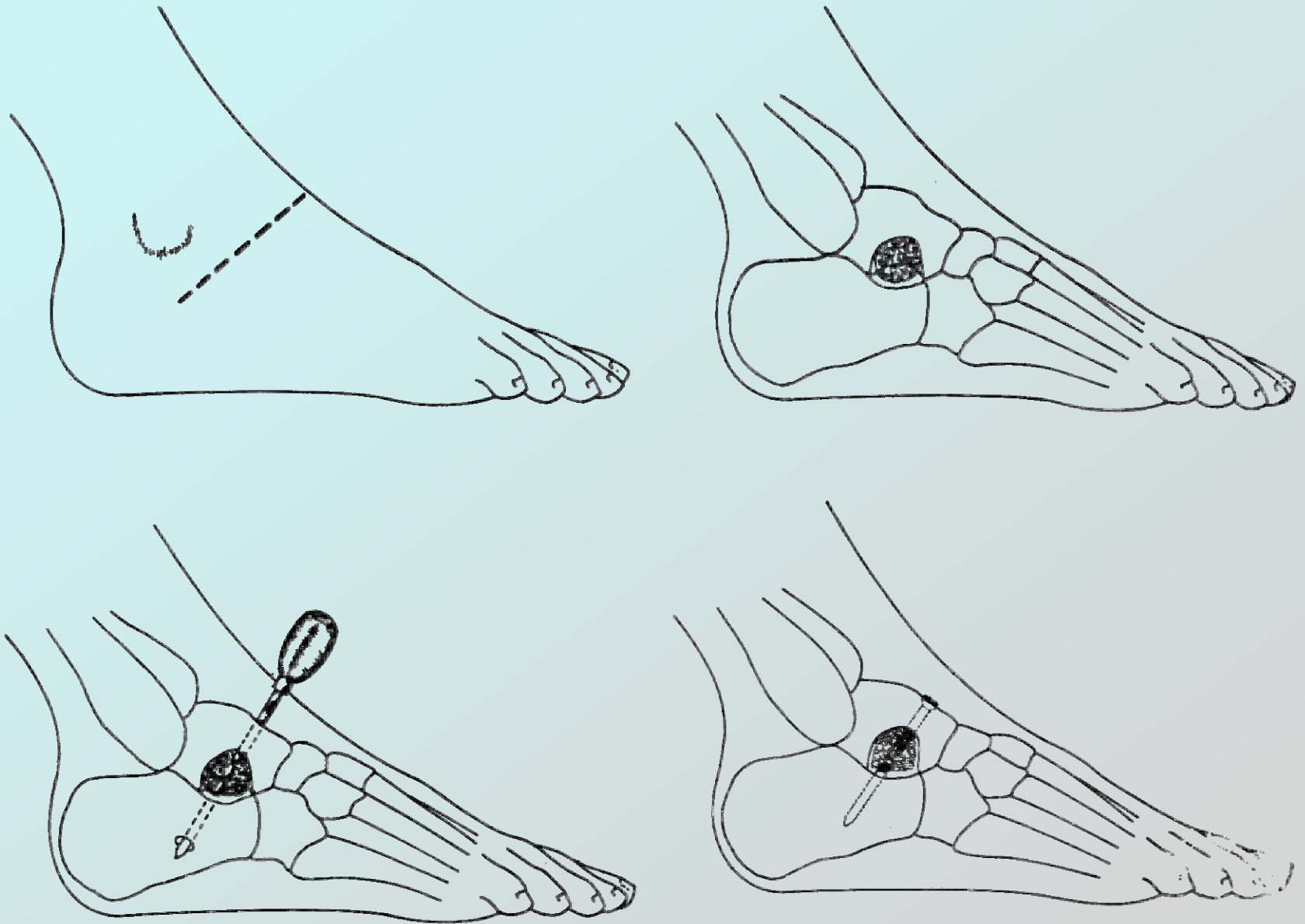


FIGURE 5-16. *Subtalar arthrodesis by cancellous grafts and metallic internal fixation.*

