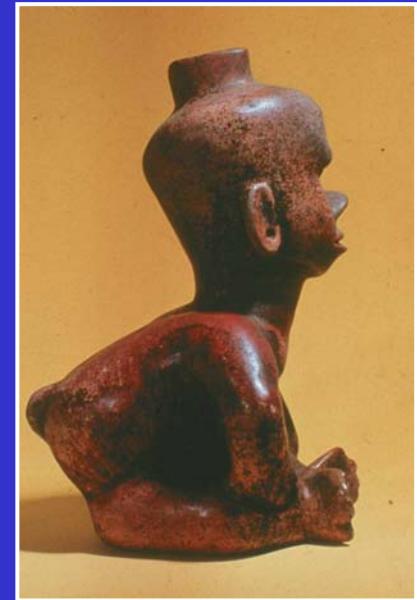


CYPHOSE CONGENITALE

G. Bollini, J.L. Jouve, F. Launay, E. Viehweger, P.L. Docquier
J.M. Sobler, M. Jacquemier

Hôpital TIMONE enfants MARSEILLE



EXAMEN CLINIQUE NEUROLOGIQUE TRES ATTENTIF

RADIOGRAPHIES STANDARDS + BENDING

IRM

ECHOGRAPHIE APPAREIL URINAIRE

+/- POTENTIEL EVOQUE SENSITIF ET MOTEUR

+/- EMG DES SPHINCTERS

**LE RISQUE NEUROLOGIQUE PAR INSTABILITE
IMMEDIATE, DIFFEREE OU IATROGENE DOIT ETRE
UNE PREOCCUPATION PERMANENTE**

CLASSIFICATION DE WINTER

DEFAUT DE FORMATION

TYPE I

DEFECT ANTERO-LATERAL

DEFECT ANTERO-CENTRAL

+ DEFECT SEGMENTAIRE COMPLET ET DEFECT POSTERIEUR

DEFAUT DE SEGMENTATION

TYPE II

FUSION ANTERIEURE TOTALE

FUSION ANTERIEURE PROGRESSIVE

MALFORMATION COMPLEXE

TYPE III

DISLOCATION ROTATOIRE

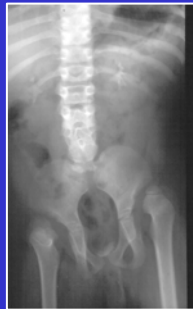INSTABILITE et RISQUE NEUROLOGIQUE !!!

DEFECT SEGMENTAIRE COMPLET



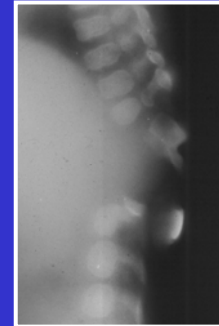
TERMINAL

AGENESIE LOMBO-SACREE

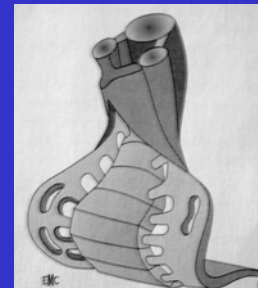


INTERCALAIRE

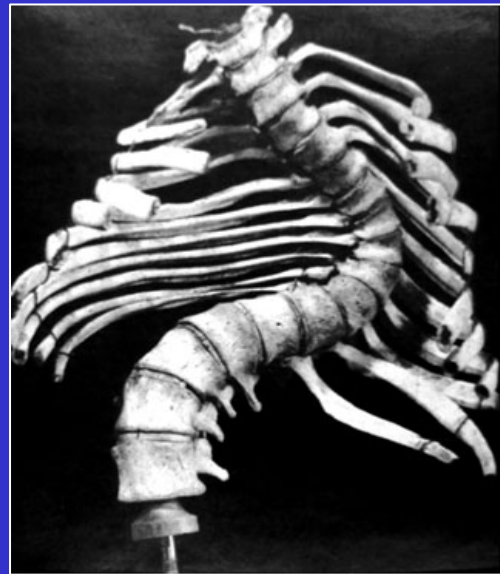
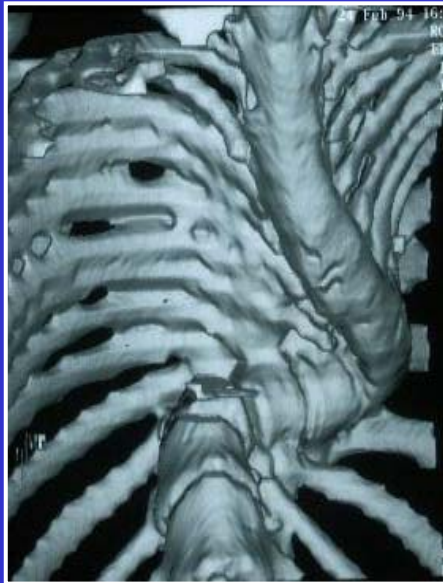
AGENESIE VERTEBRO MEDULLAIRE



DEFECT POSTERIEUR



MALFORMATION COMPLEXE



DISLOCATION ROTATOIRE

J. DUBOUSSET

CLASSIFICATION DE WINTER

DEFAUT DE FORMATION

TYPE I

DEFECT ANTERO-LATERAL

DEFECT ANTERO-CENTRAL

DEFECT SEGMENTAIRE COMPLET

TERMINAL

INTERCALAIRE

AGENESIE LOMBO-SACREE

AGENESIE VERTEBRO MEDULLAIRE

INSTABILITE et RISQUE NEUROLOGIQUE !!!

LORDOSE

Barre postérieure

Barre postero-latérale

Barre latérale

SCOLIOSE

Bloc complet

Vertèbre binucléée T-L

Ossification ant. Prog.

Barre antérieure

Agénésie corp. Ant.

HVNS

HV1/2 S

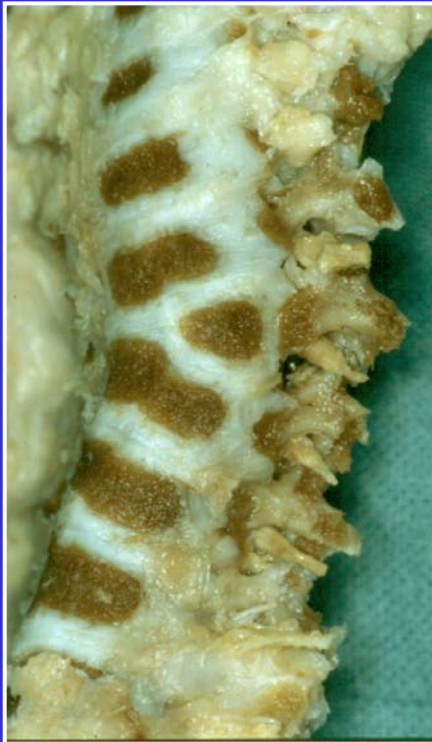HV Trap Libre

HV Libre

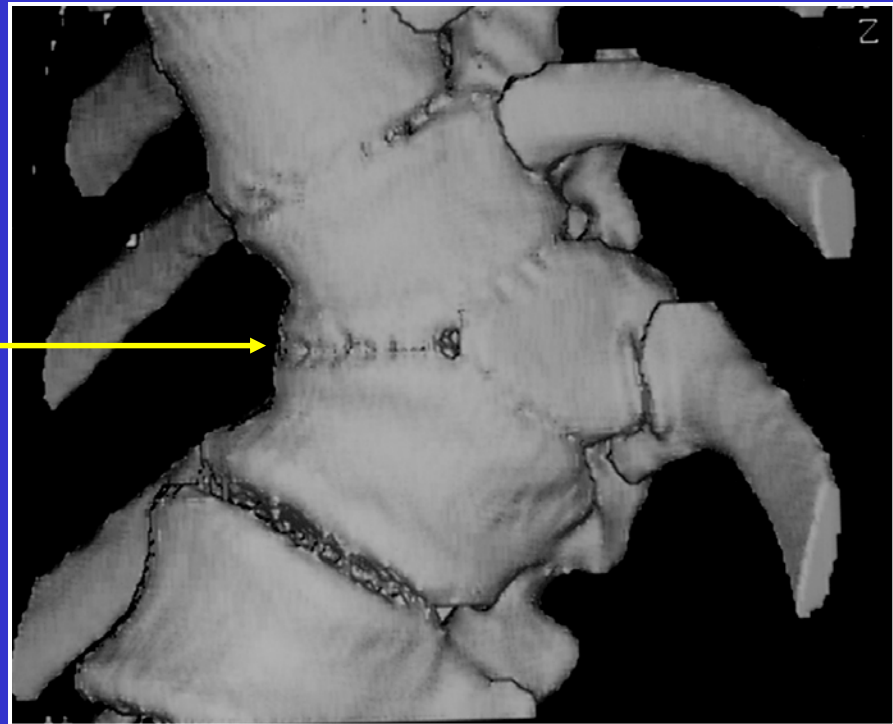
Barre antéro-latérale

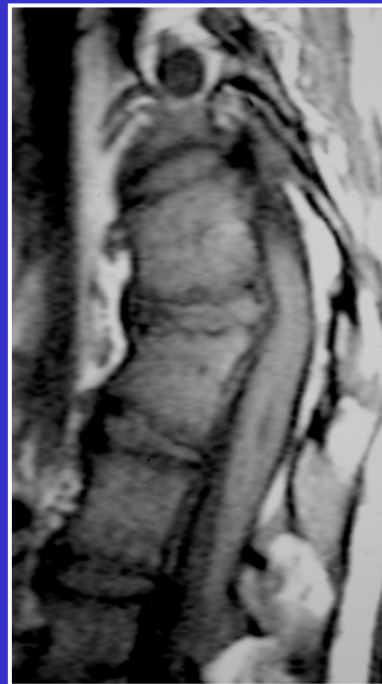
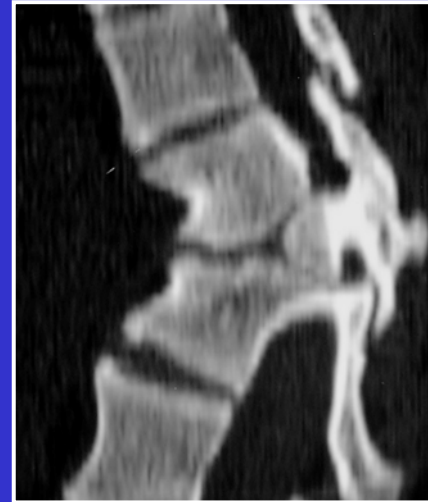
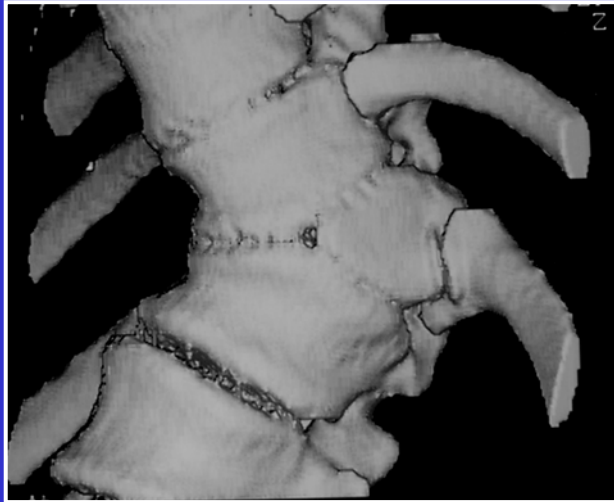CYPHOSE

DEFAUT DE FORMATION

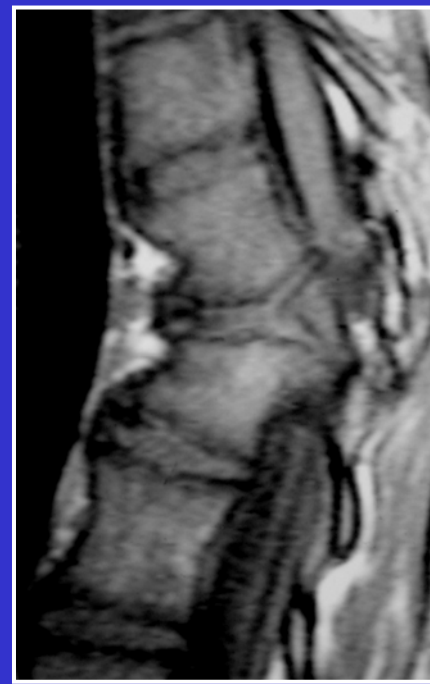


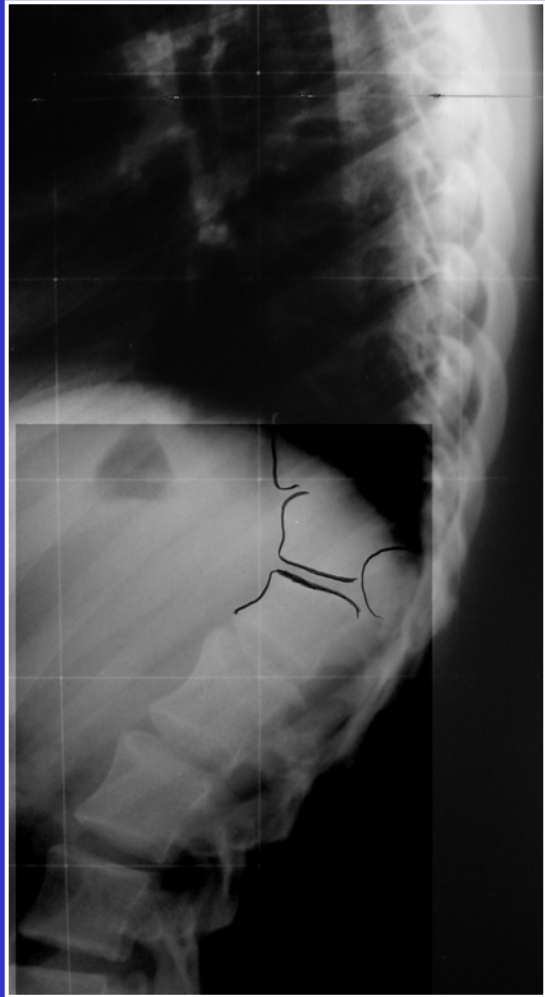
ANTERO
LATERAL



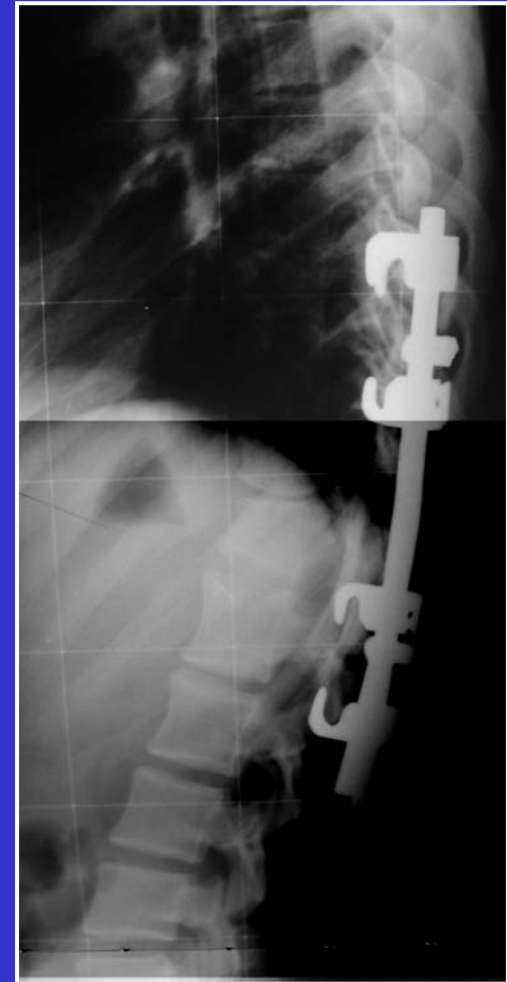
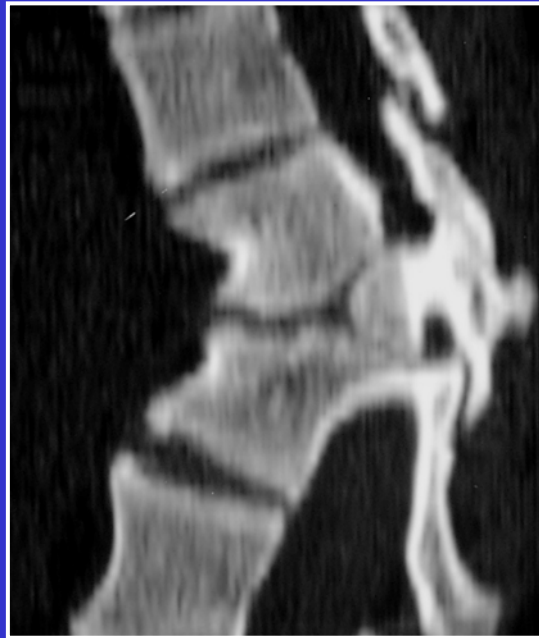


12 Y



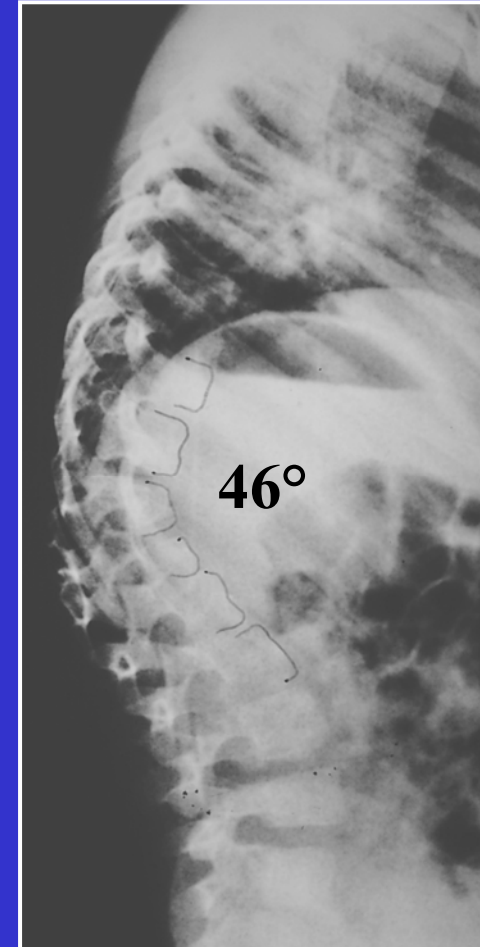
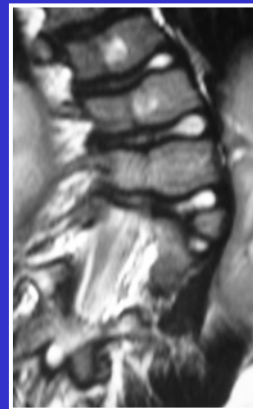
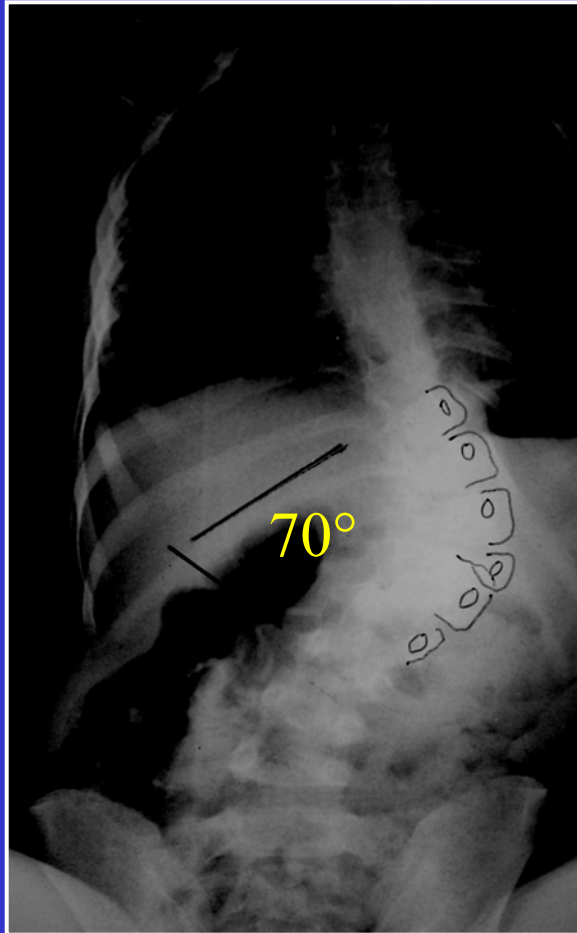


12 Y

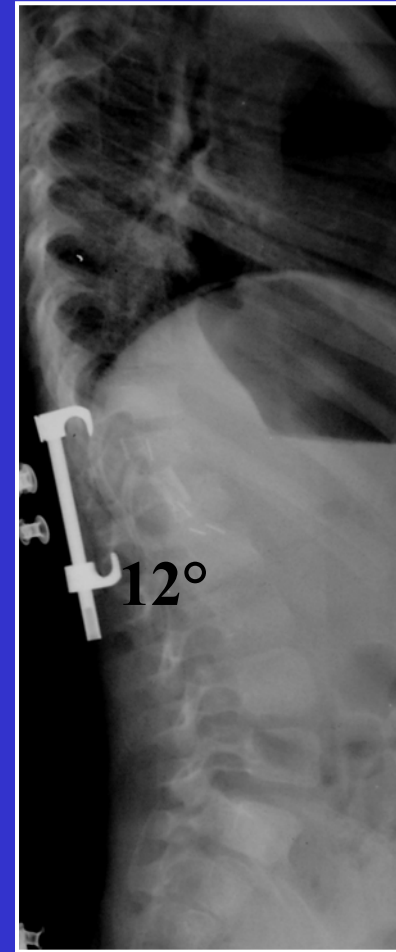
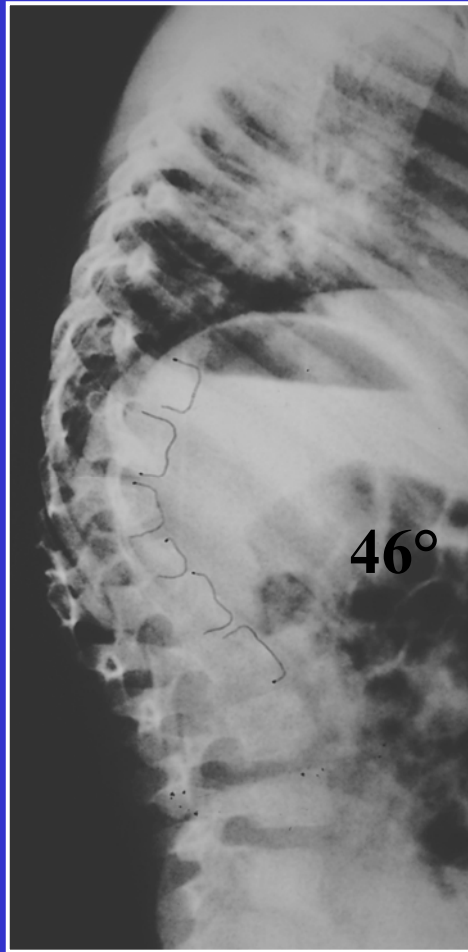


15 Y

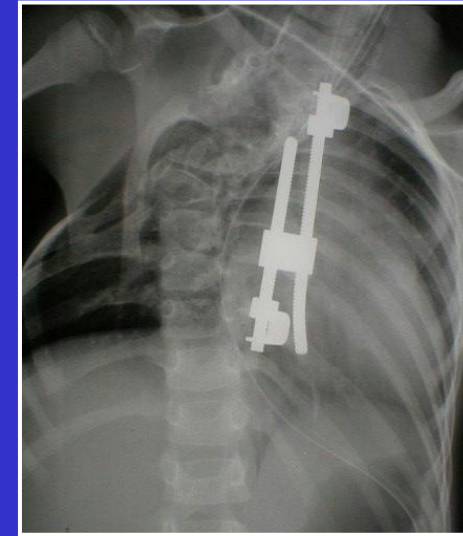
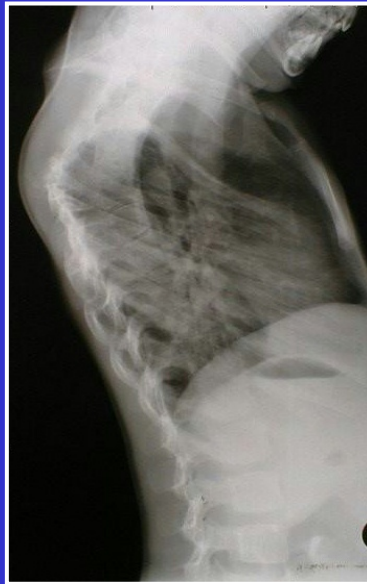
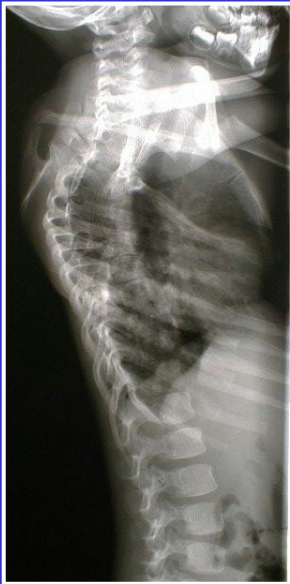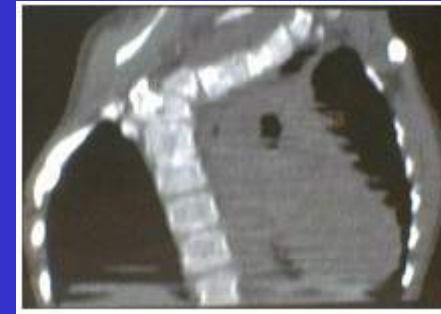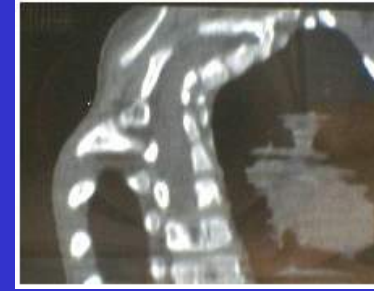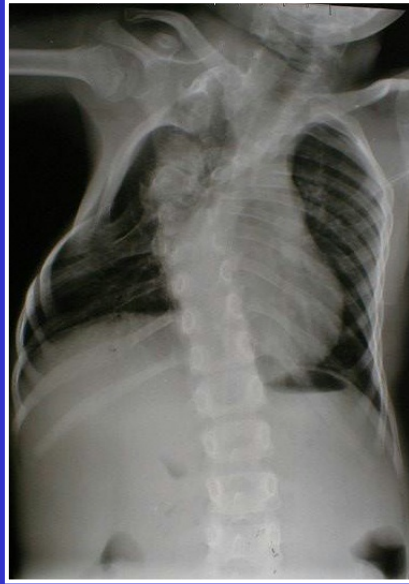
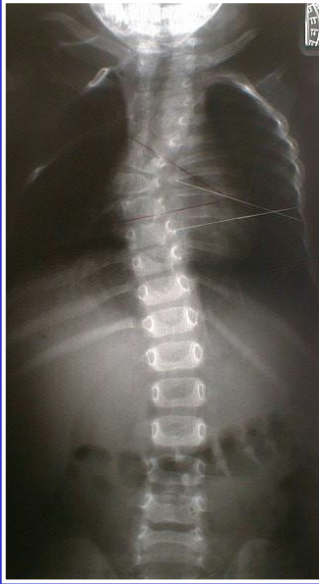H.V. Libre T12 L1 gauche



3 A 9 M



3 A 9 M



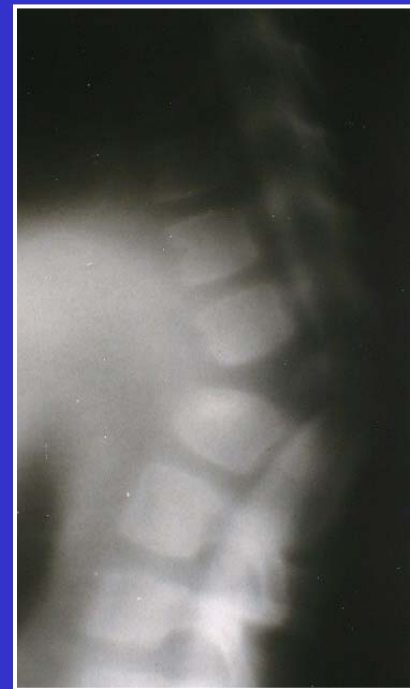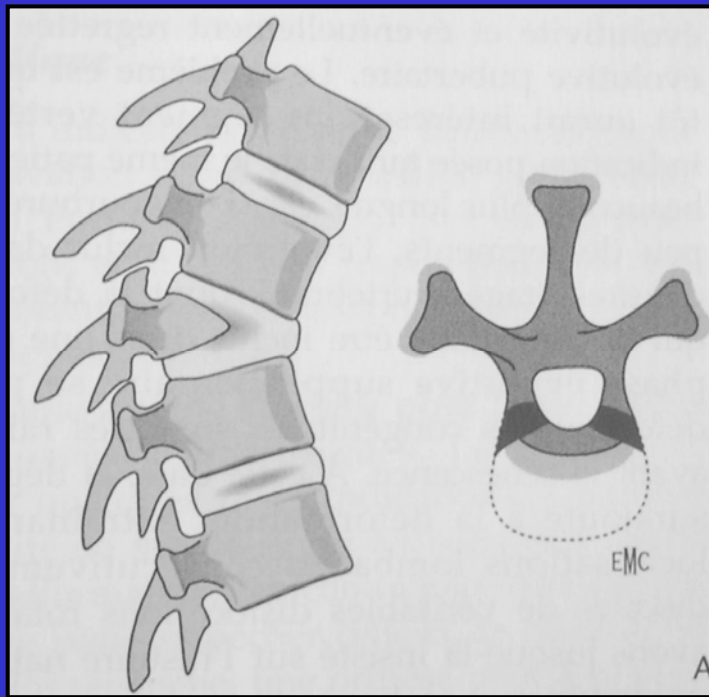
CLASSIFICATION DE WINTER

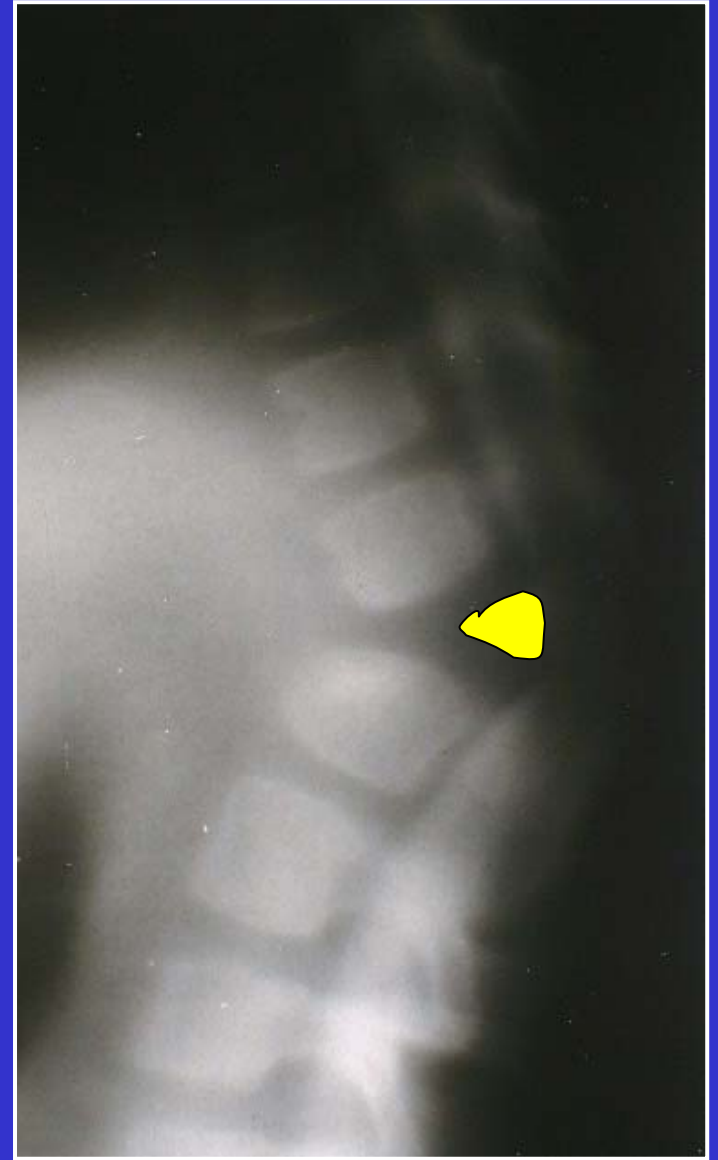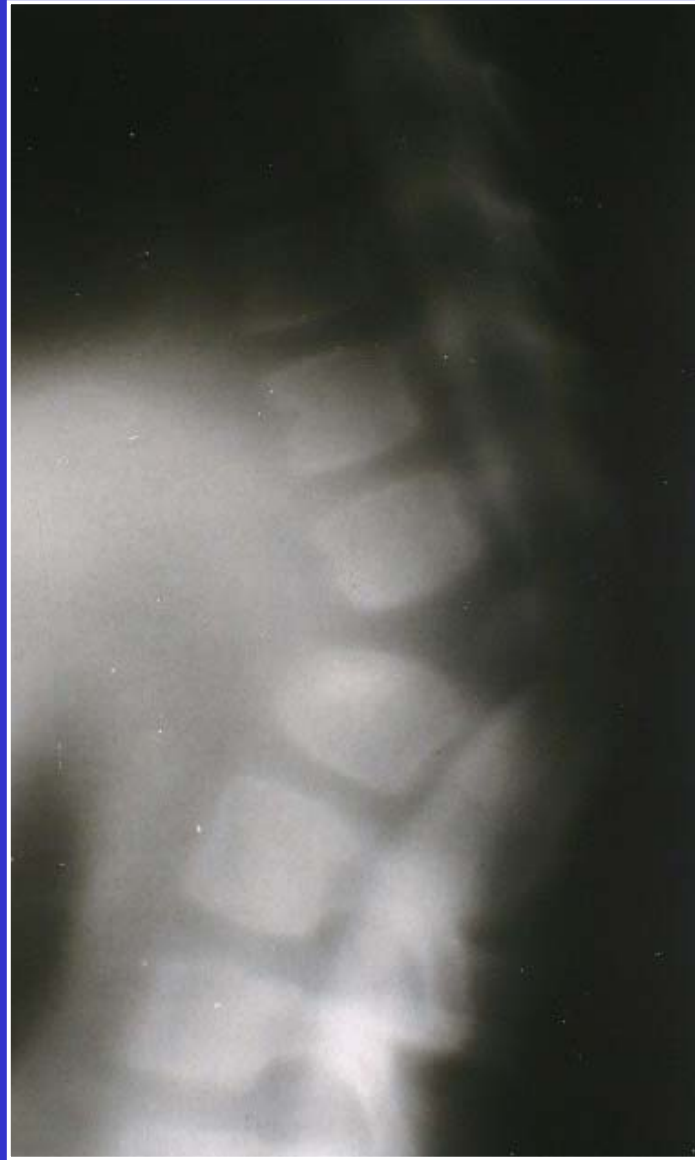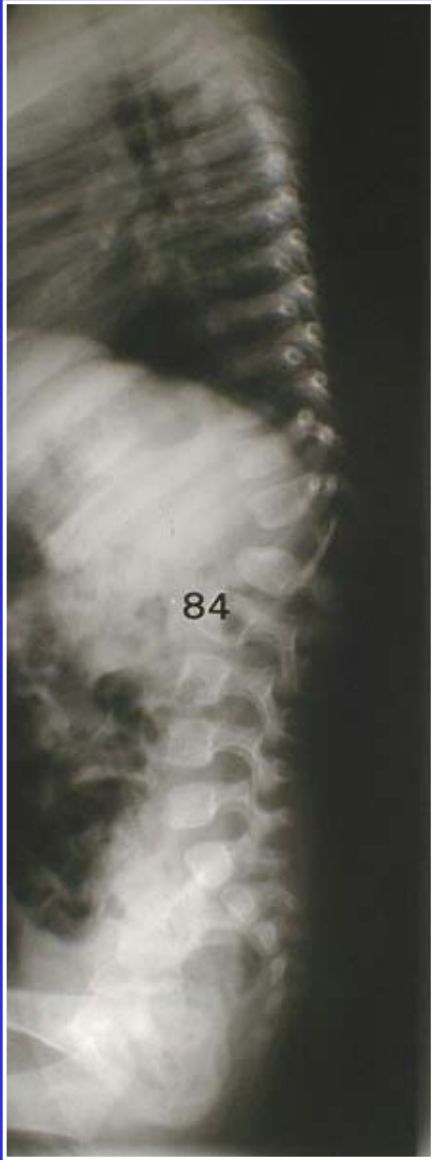DEFAUT DE FORMATION

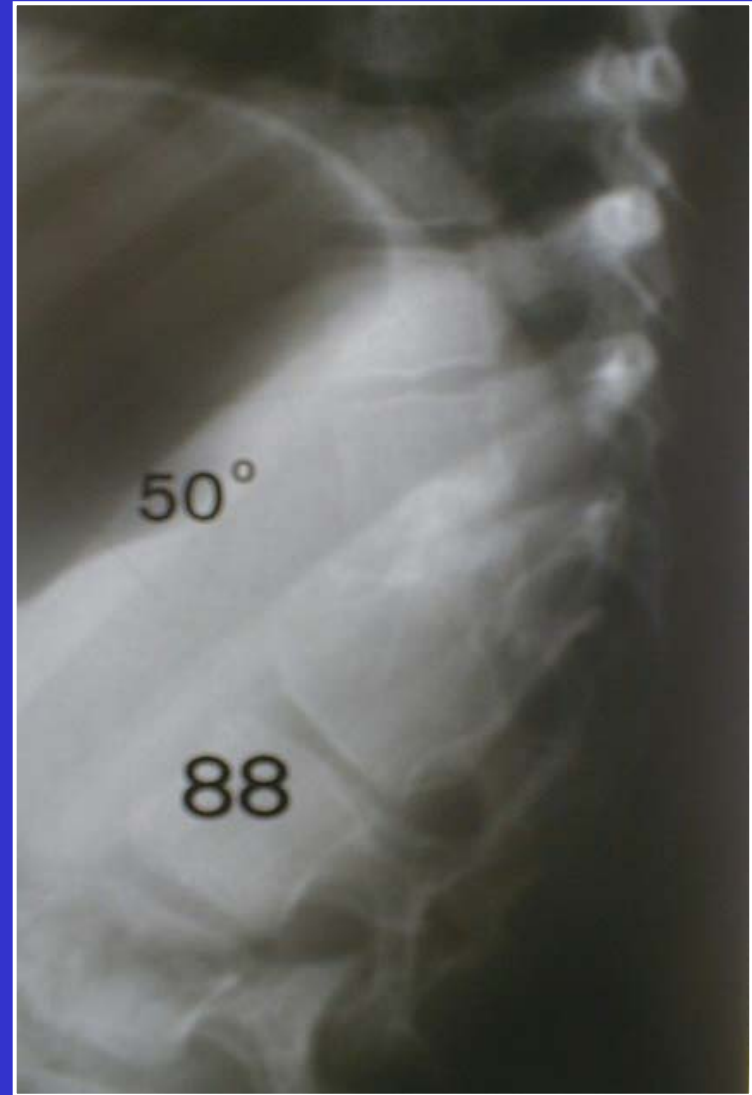
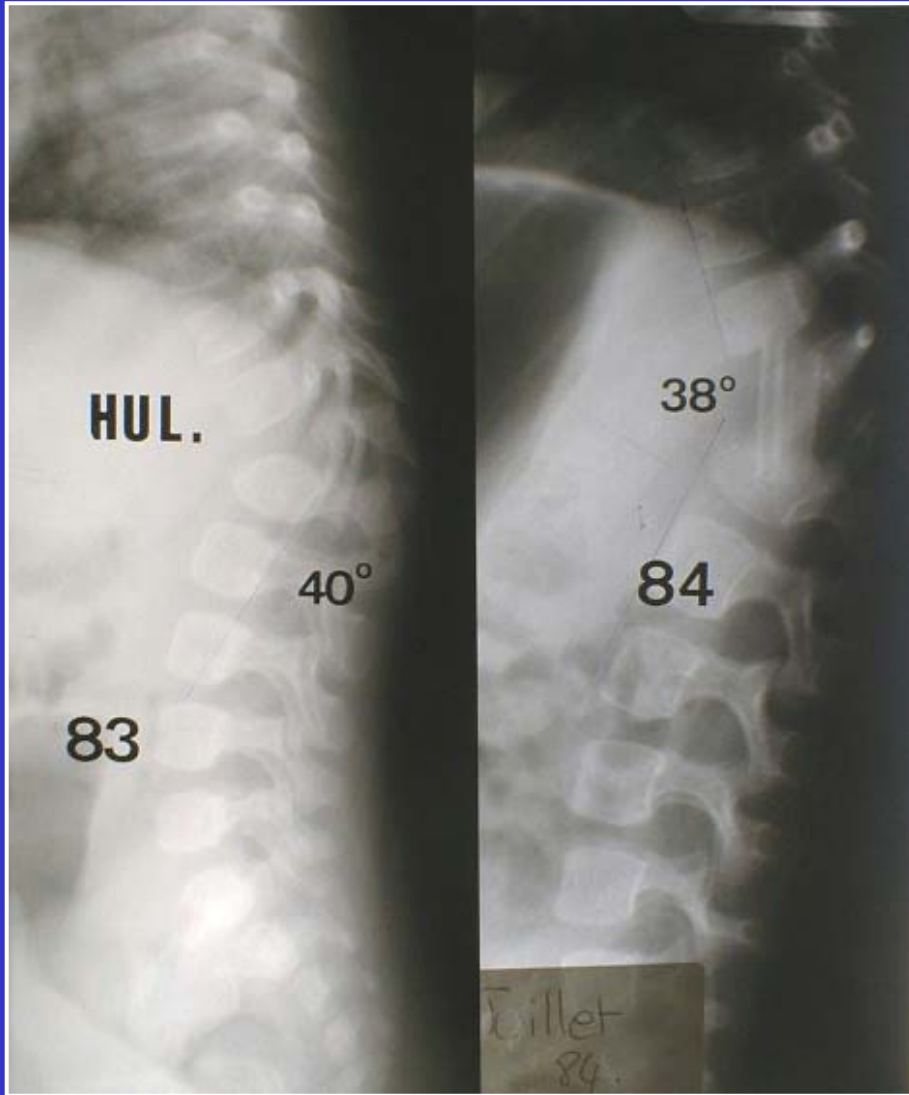
TYPE I

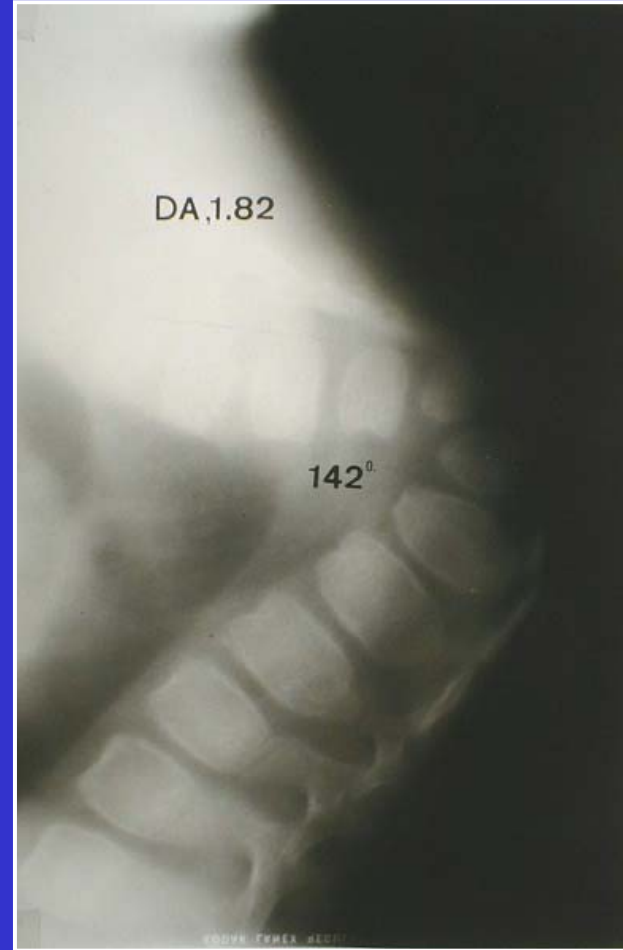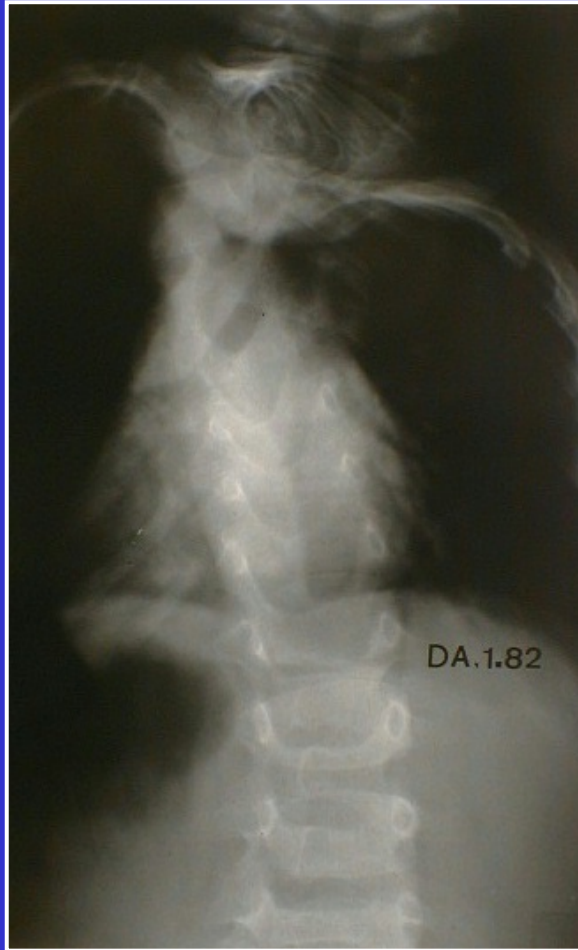DEFECT ANTERO-LATERAL

DEFECT ANTERO-CENTRAL



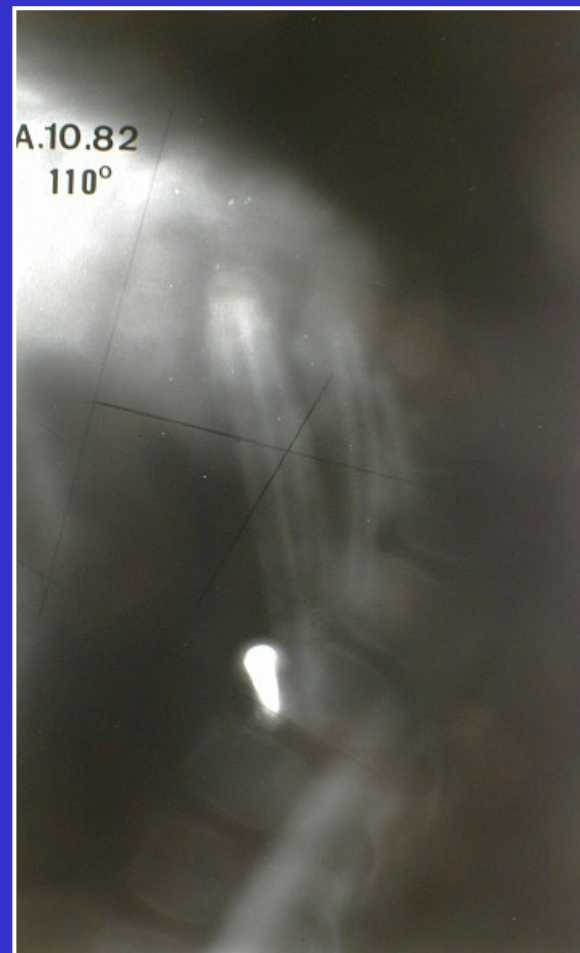
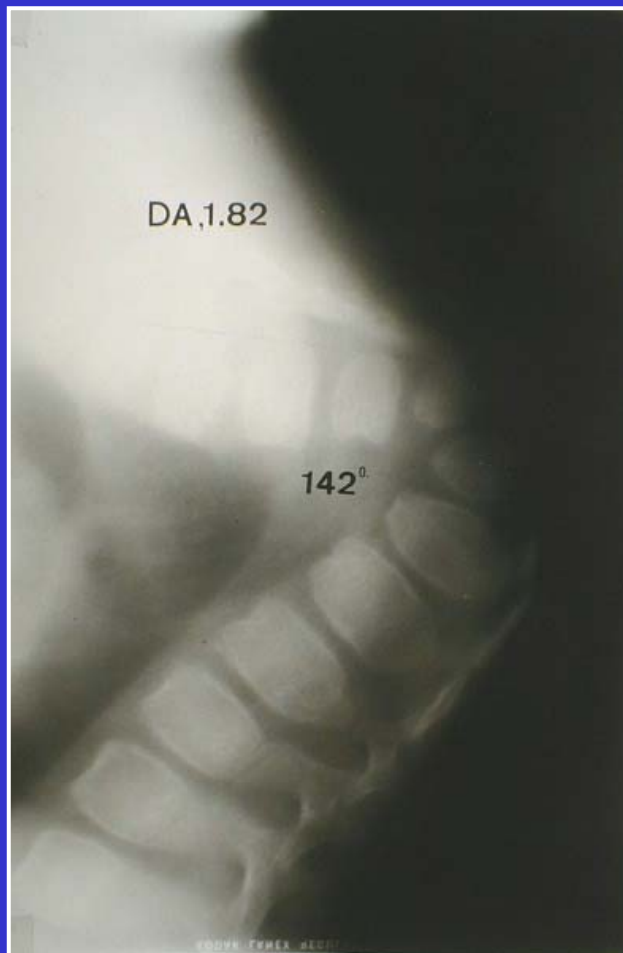
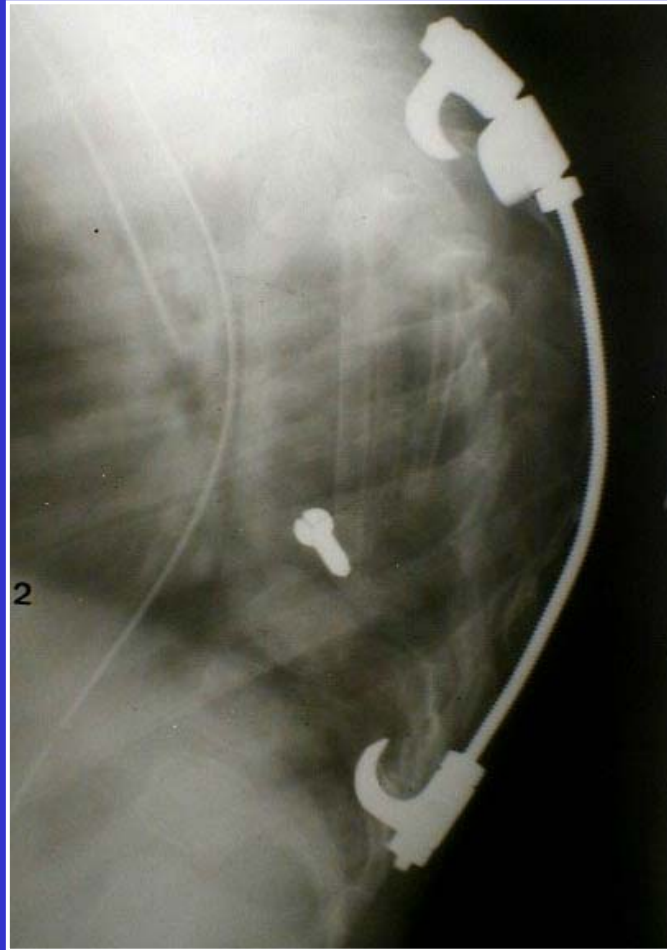




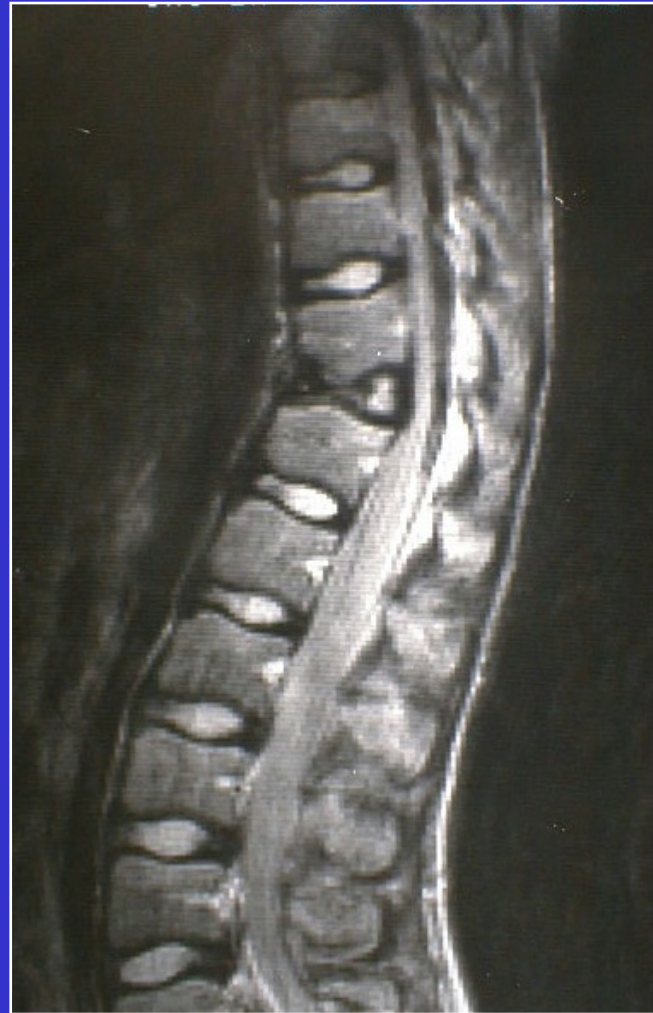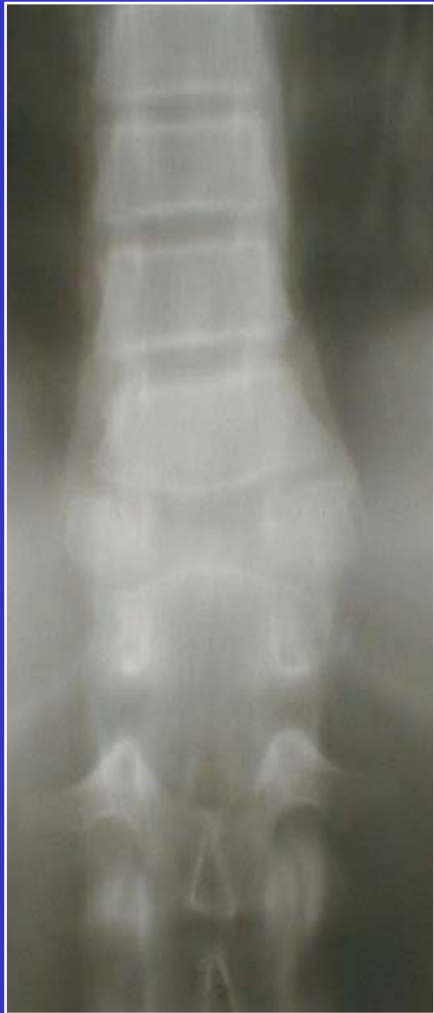RISQUE NEUROLOGIQUE PAR COMPRESSION MECANIQUE !

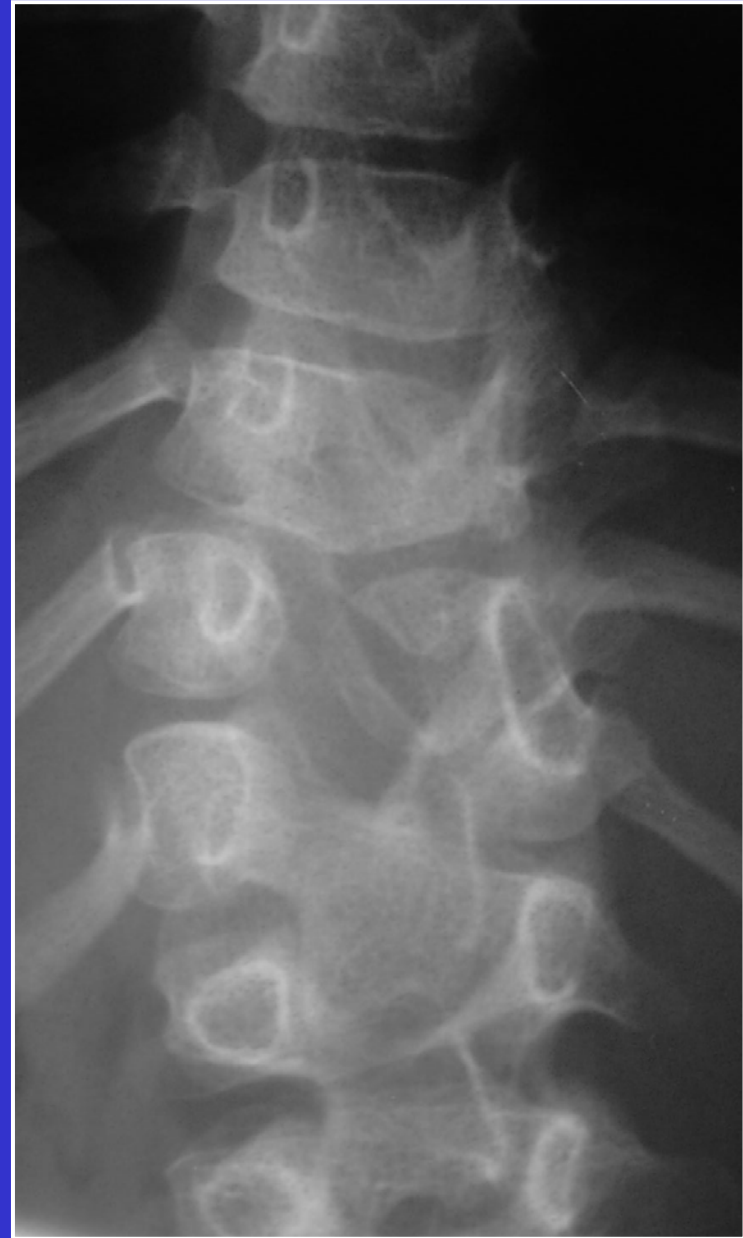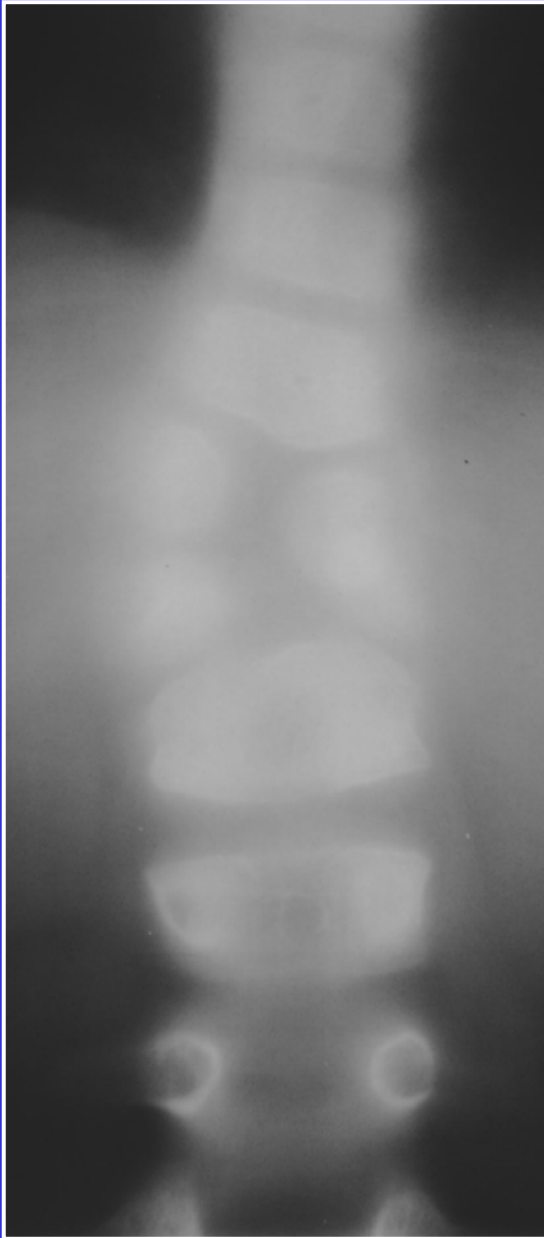
RISQUE NEUROLOGIQUE CHIRURGICAL +++

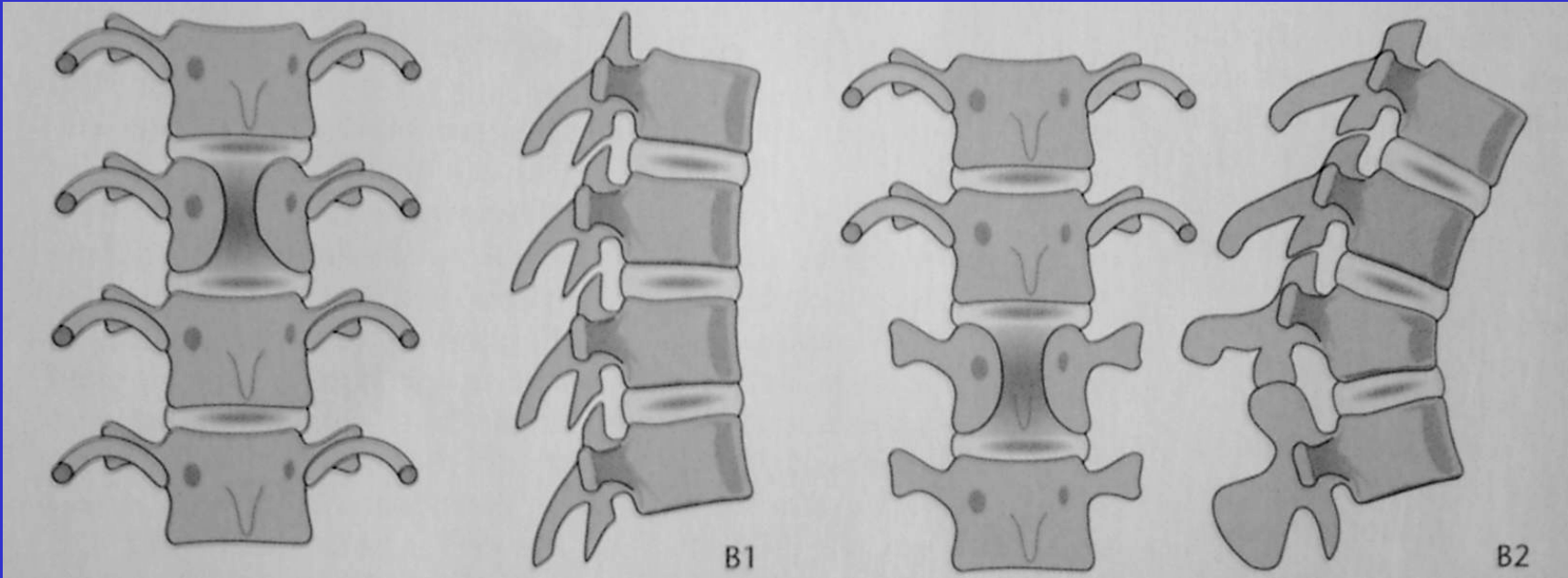






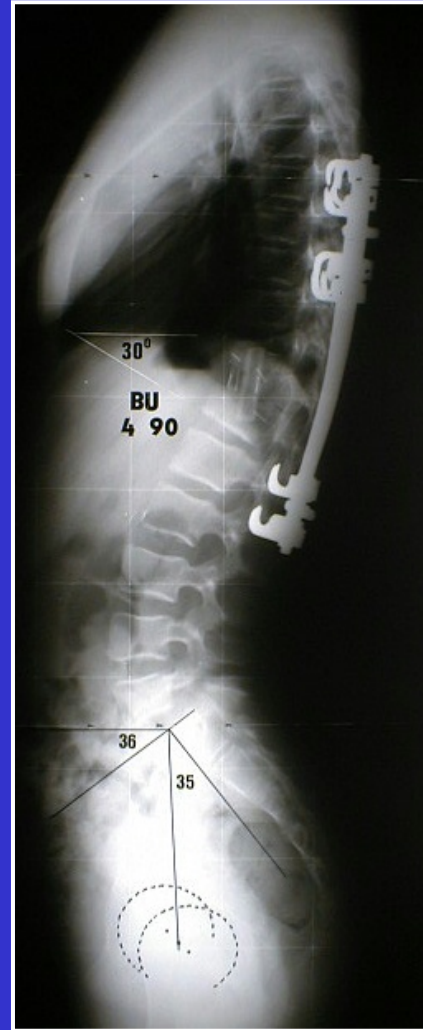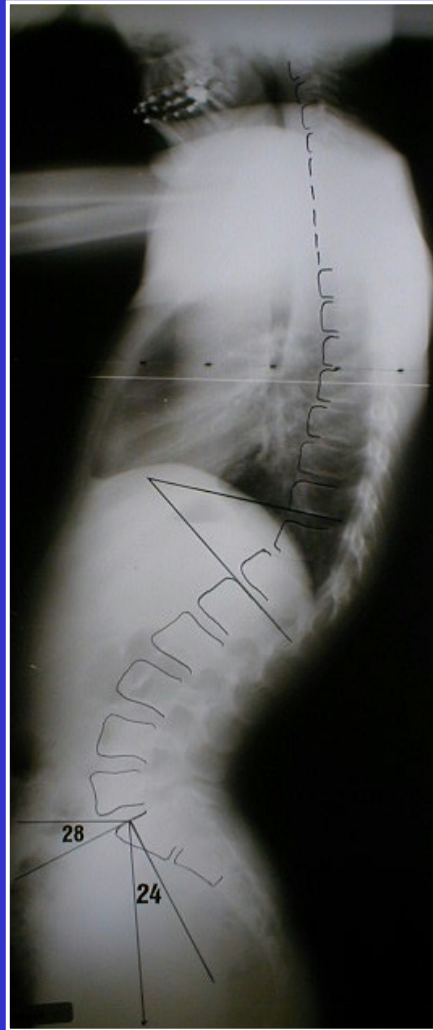
VERTEBRES EN « AILES DE PAPILLON »





B1

B2



CLASSIFICATION DE WINTER

DEFAUT DE FORMATION

TYPE I

DETECT ANTERO-LATERAL

DETECT ANTERO-CENTRAL

DETECT SEGMENTAIRE COMPLET

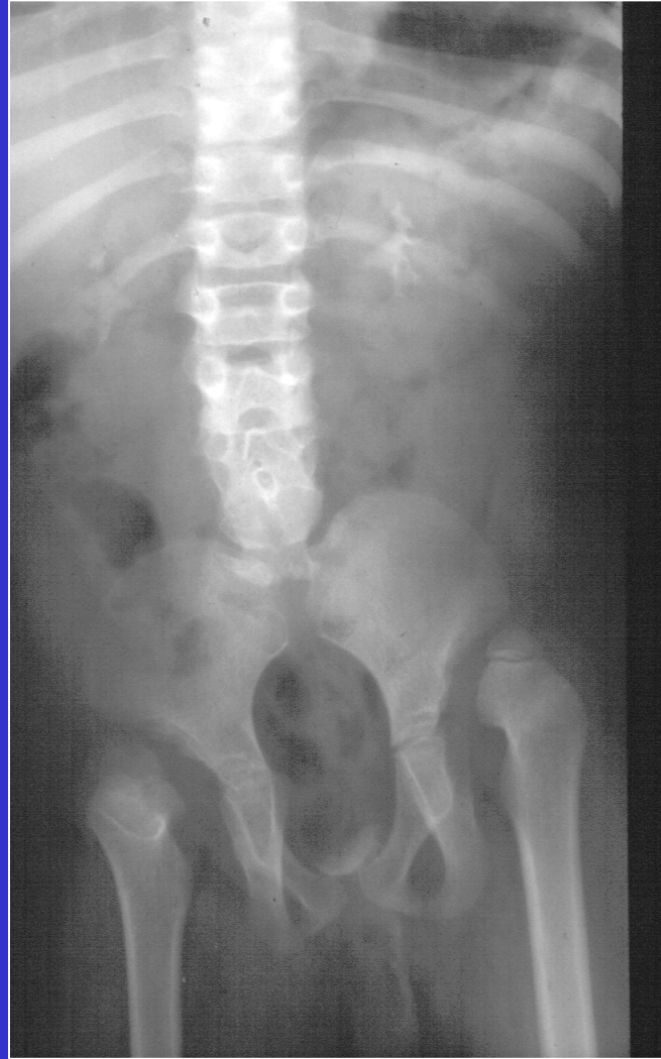TERMINAL


AGENESIE LOMBO-SACREE


INTERCALAIRE

AGENESIE VERTEBROMEDULLAIRE

INSTABILITE et RISQUE NEUROLOGIQUE !!!







SPINO – ILIAC INSTABILITY

Spinal – pelvic fusion recommended by *Perry and Pirkey*

Allows patients to sit with the hands free, permits stretching of the hip – flexion contractures, and protects the viscera from unphysiologic compression.

Spinal – pelvic fusion is not recommended for *Philips and Andrish*

It may cause problems with hip – flexion contractures that previously were compensated for by the hypermobile spinal pelvic junction.

Seventeen of Philip's nineteen surviving patients sit without support and have no apparent problems.

CLASSIFICATION DE WINTER

DEFAUT DE FORMATION

TYPE I

DETECT ANTERO-LATERAL

DETECT ANTERO-CENTRAL

DETECT SEGMENTAIRE COMPLET

TERMINAL

AGENESIE LOMBO-SACREE

INTERCALAIRE

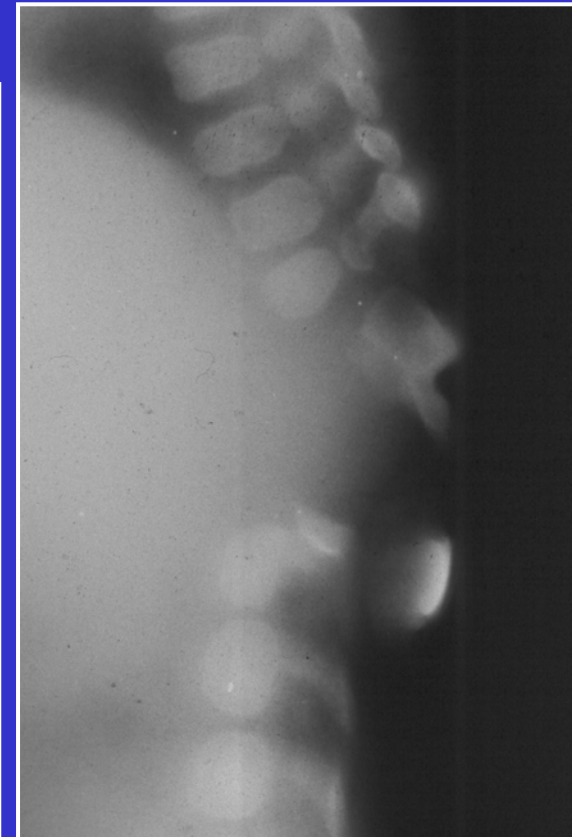
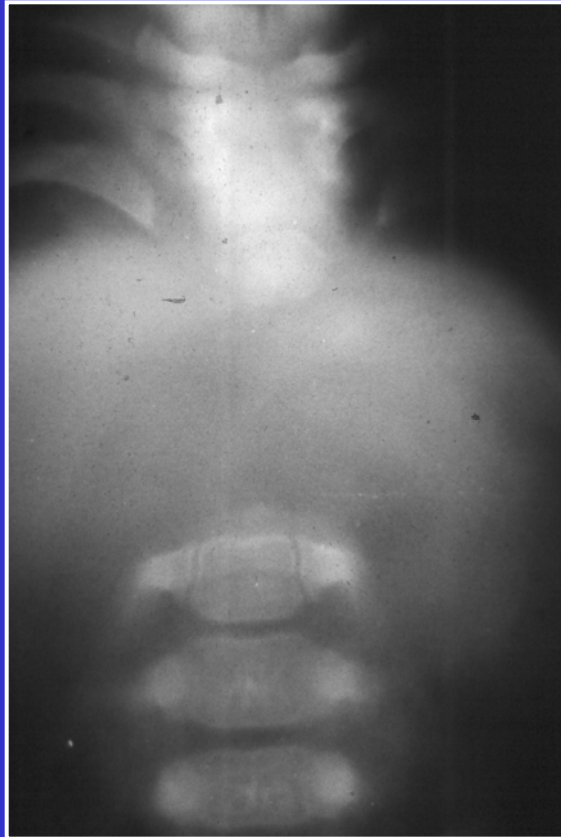
LUXATION CONGENITALE DU RACHIS

AGENESIE VERTEBRO MEDULLAIRE

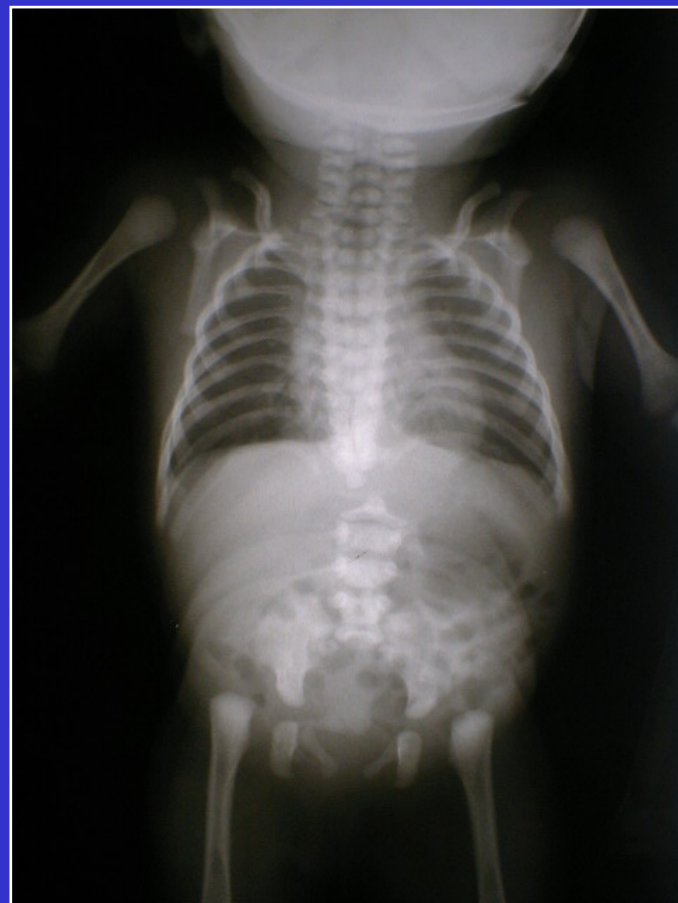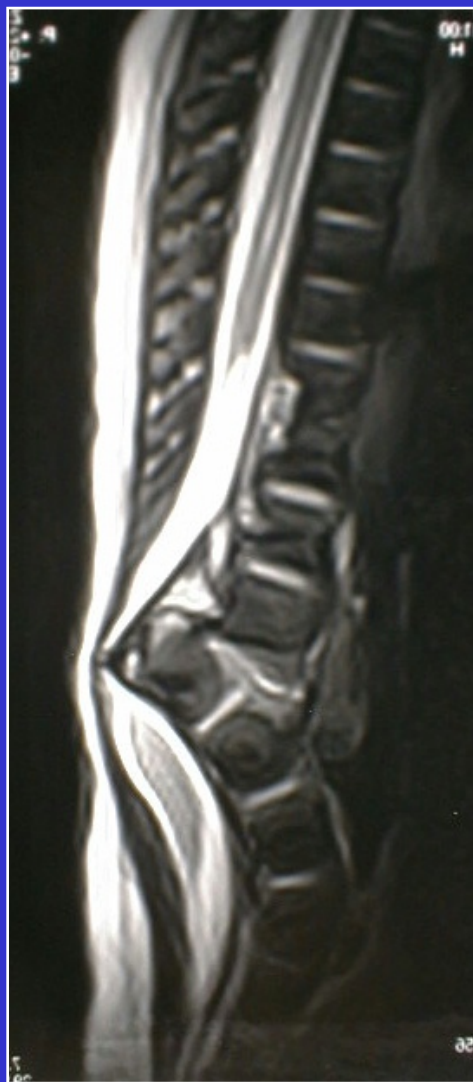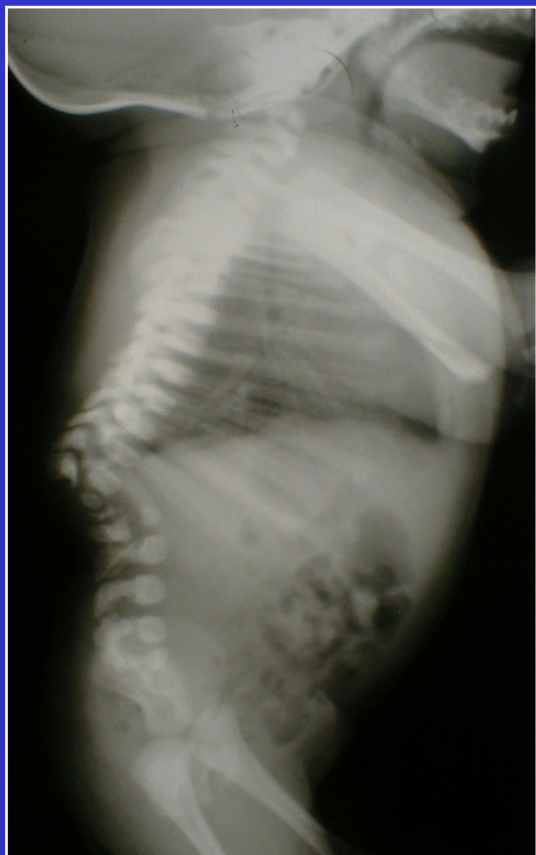INSTABILITE et RISQUE NEUROLOGIQUE !!!

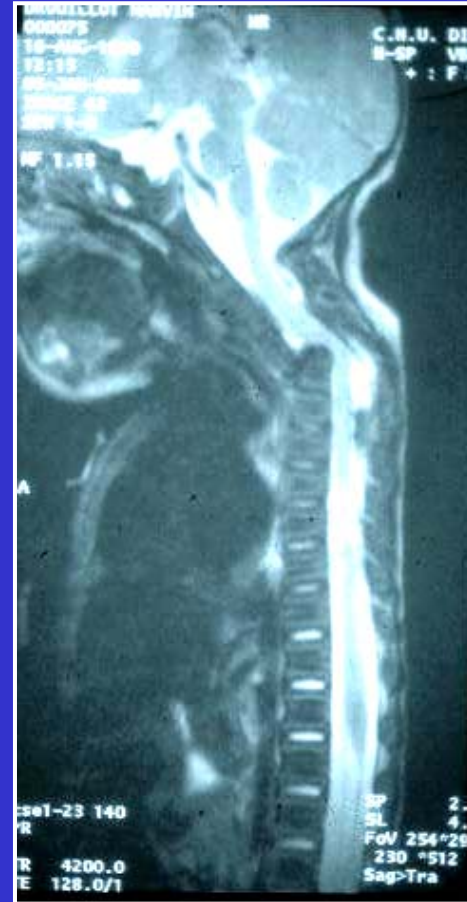
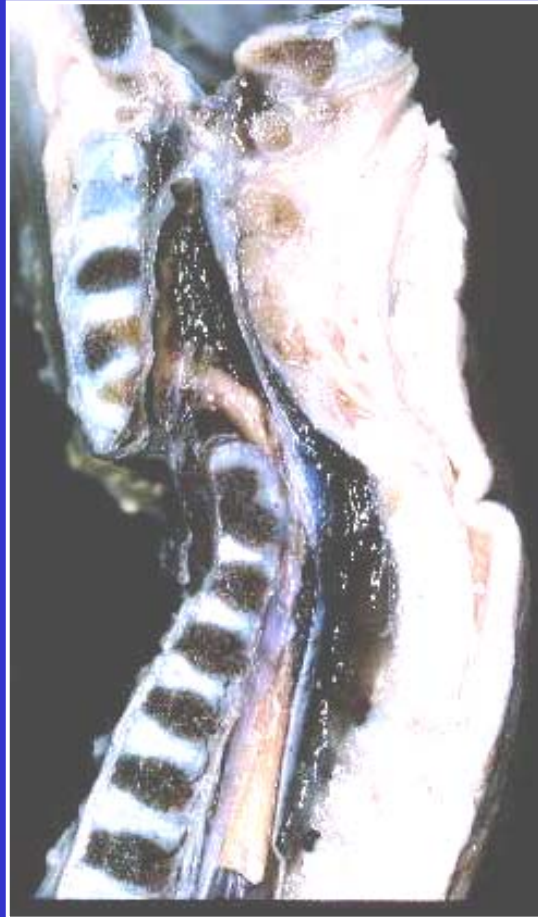DEFECT SEGMENTAIRE COMPLET

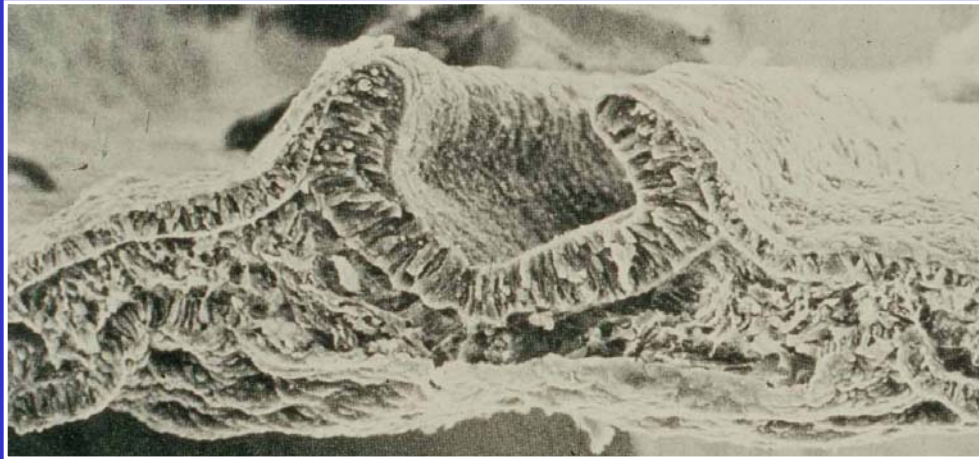
INTERCALAIRE



LUXATION CONGÉNITALE DU RACHIS

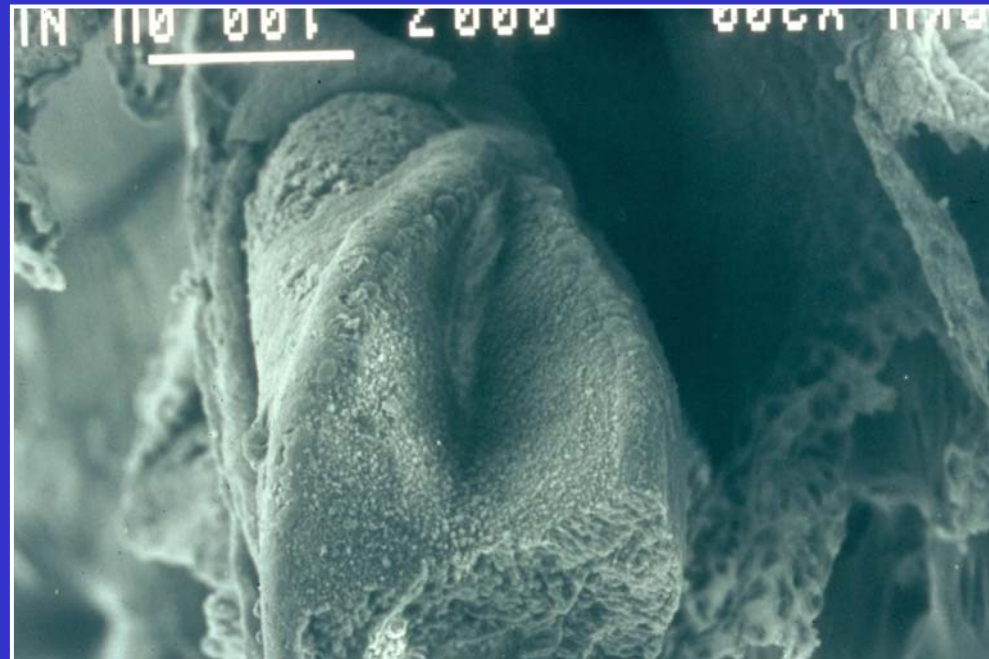




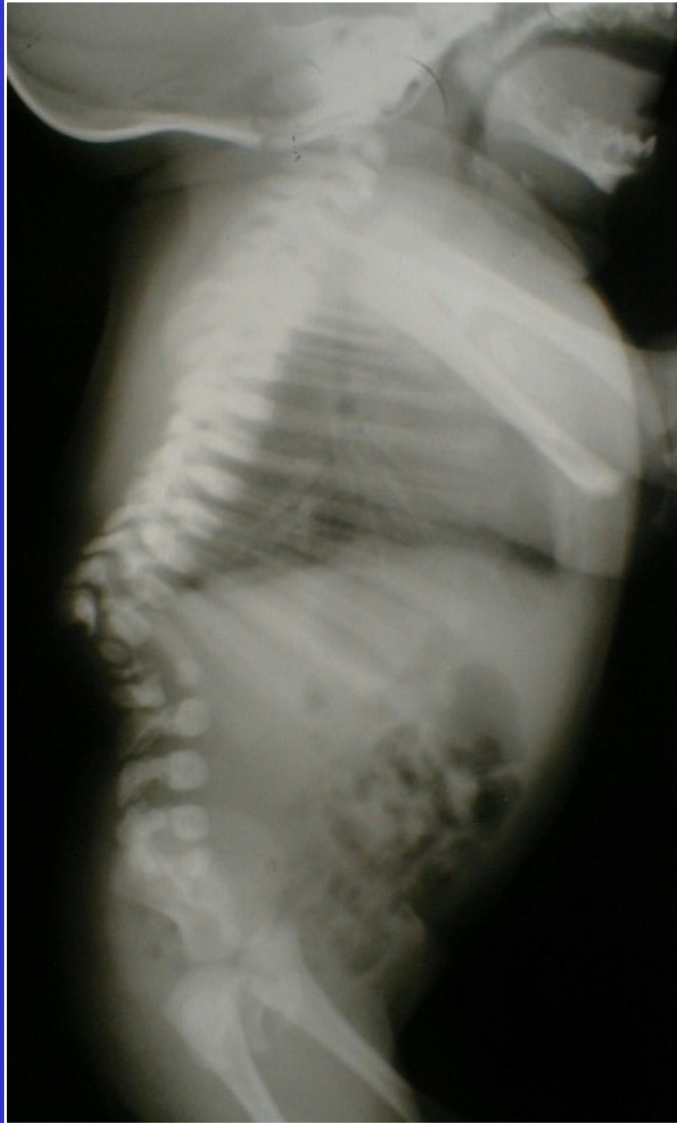
NEURULATION

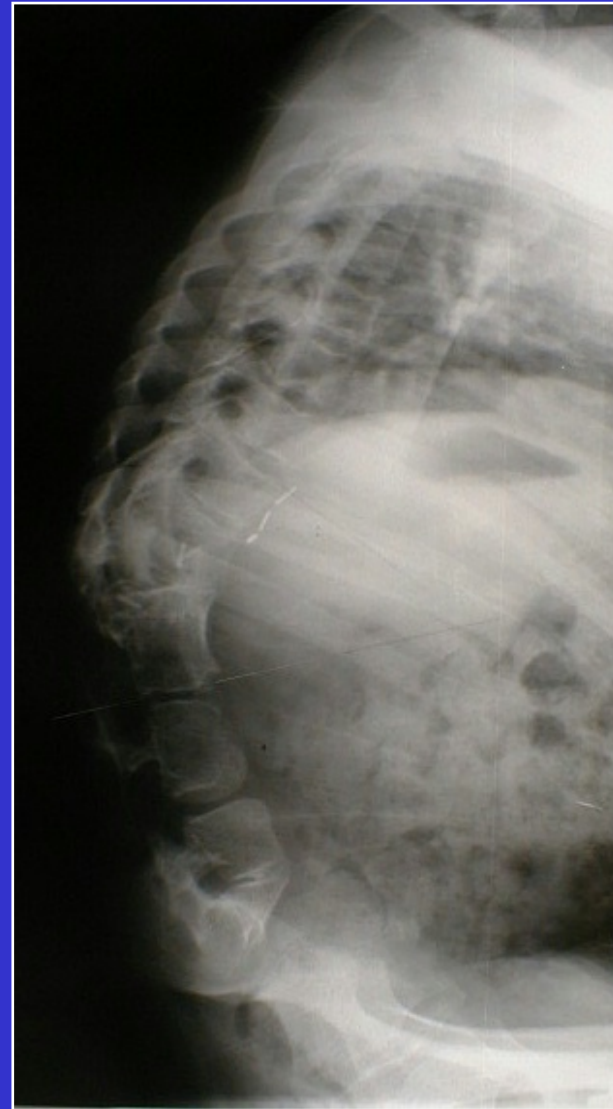**NEUROPORE
POSTERIEUR**



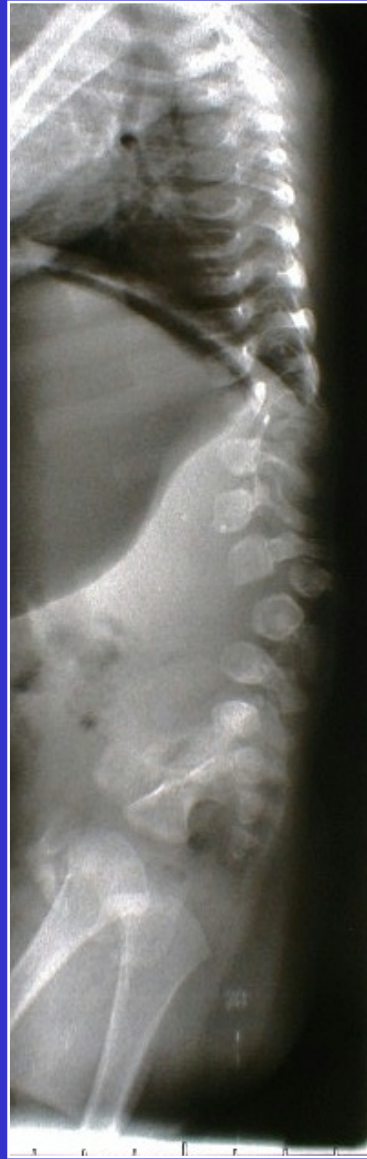BIRTH



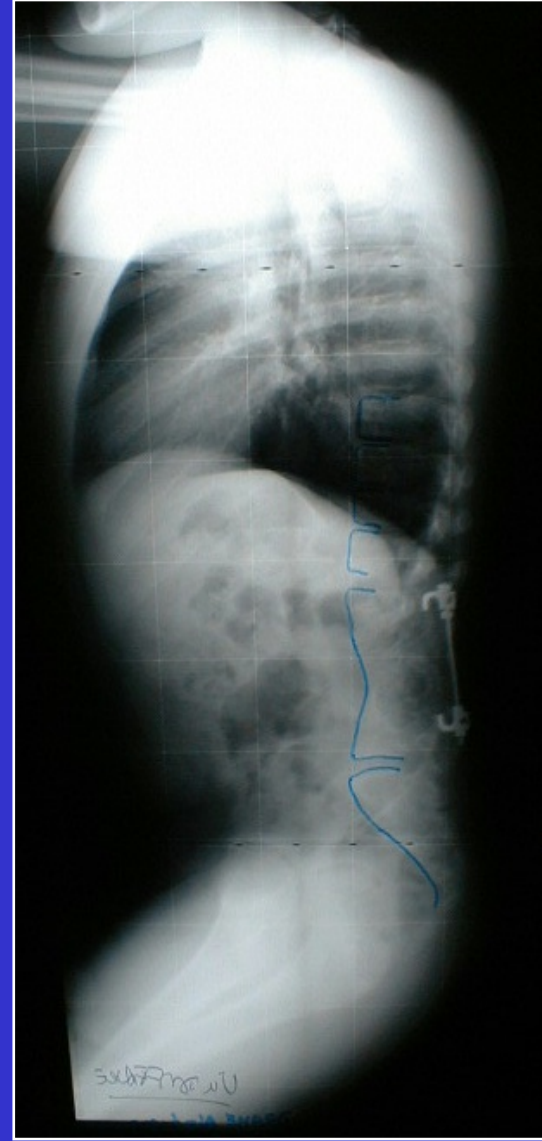9 Y

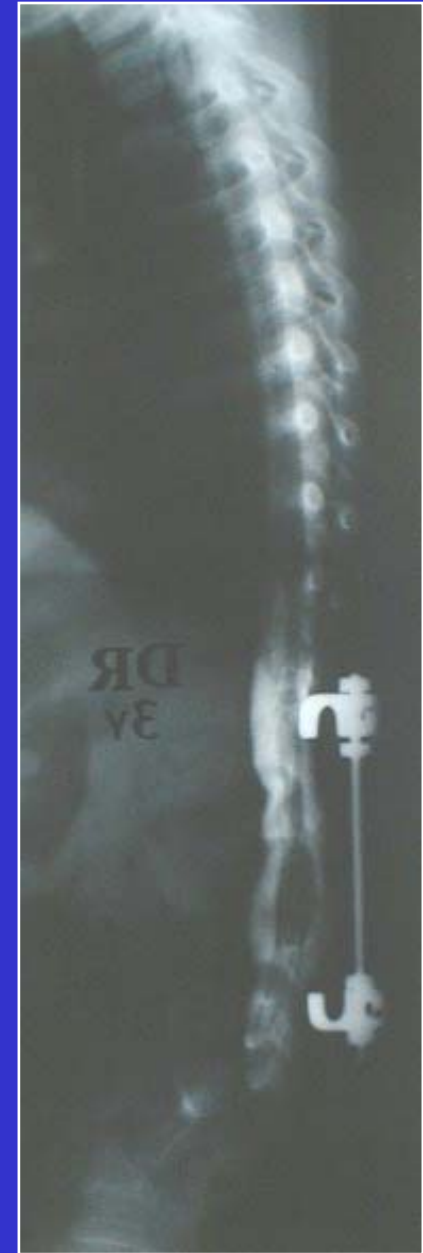
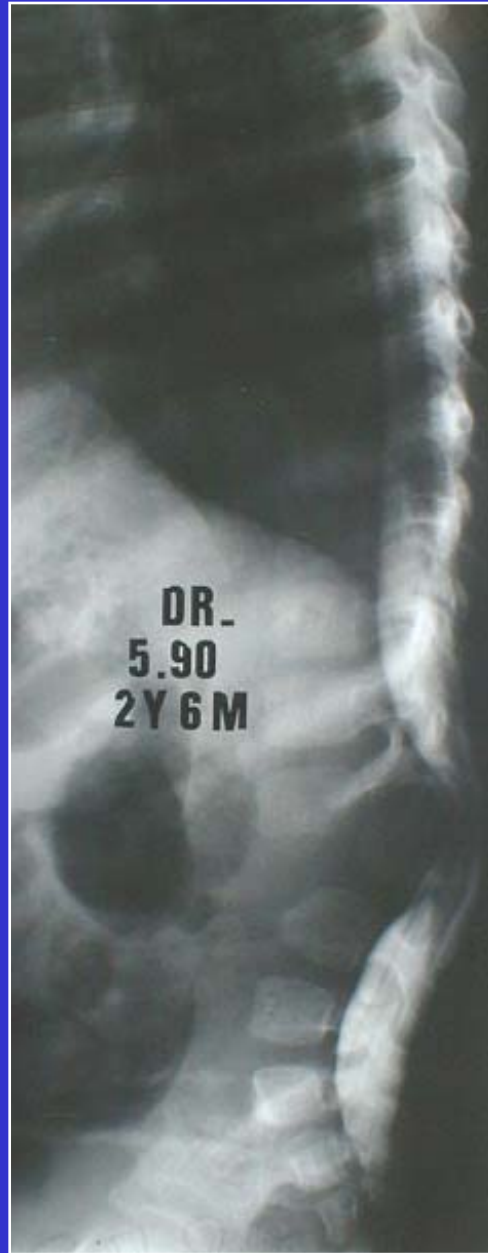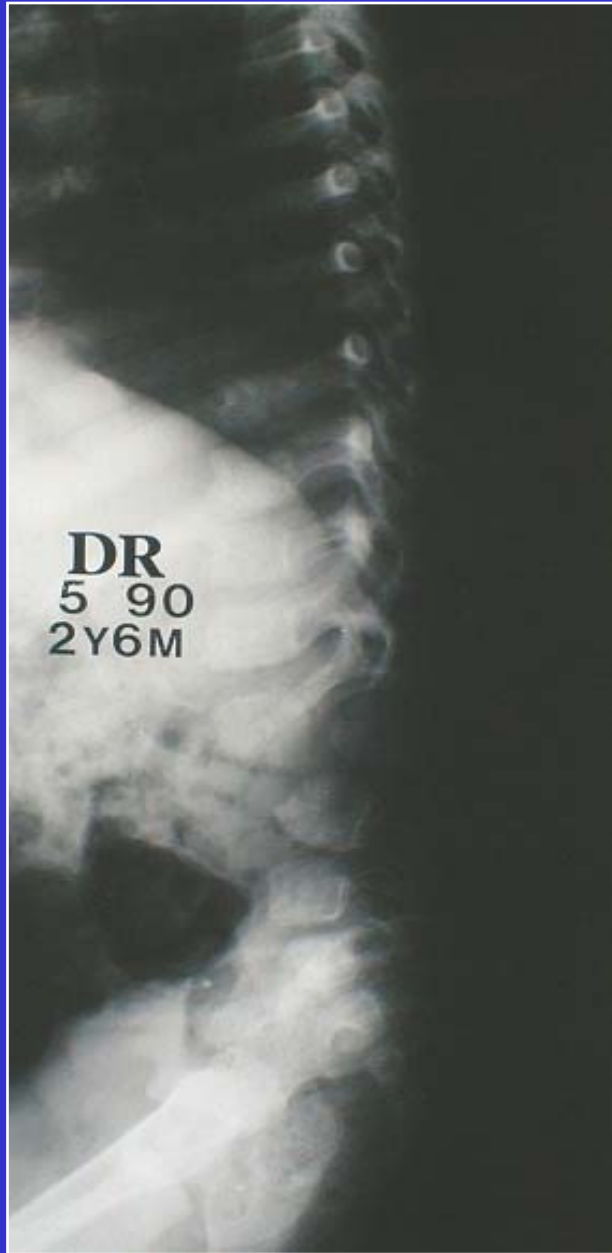


2+6 Y



13 Y

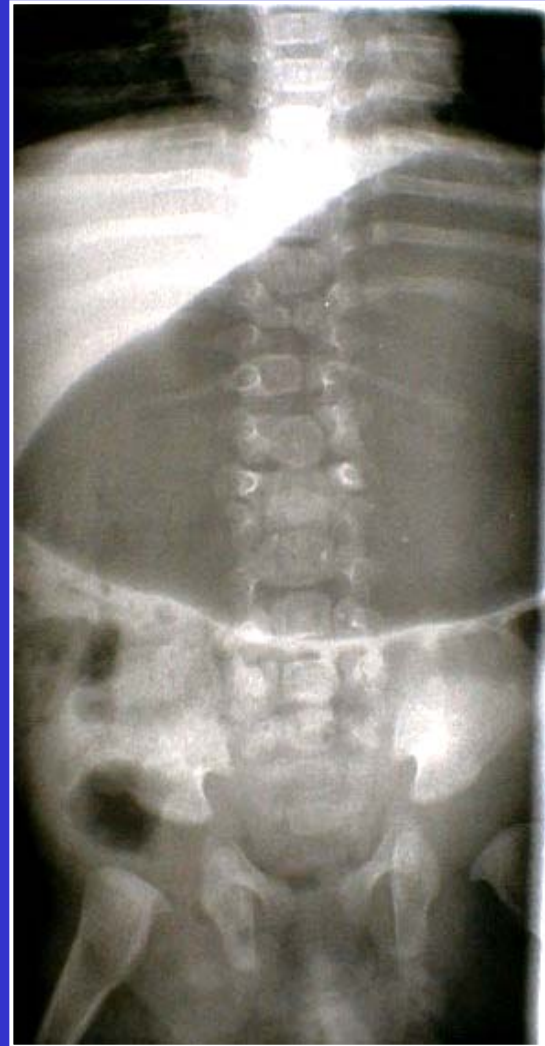
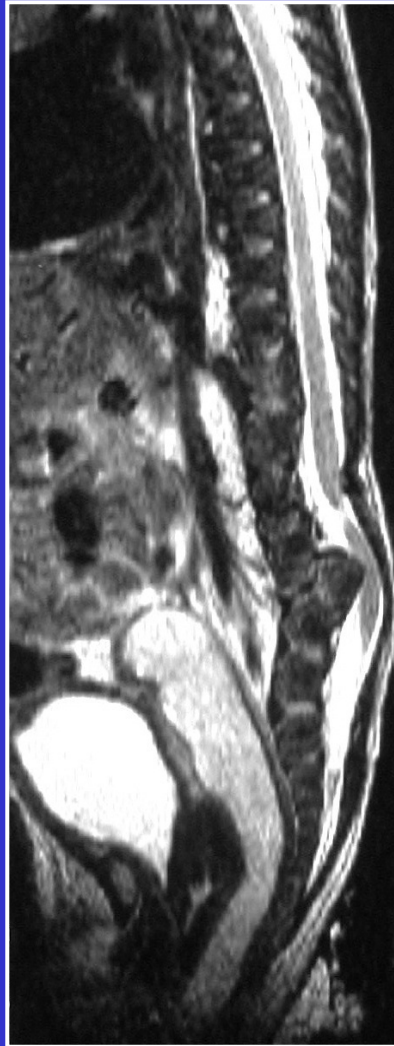
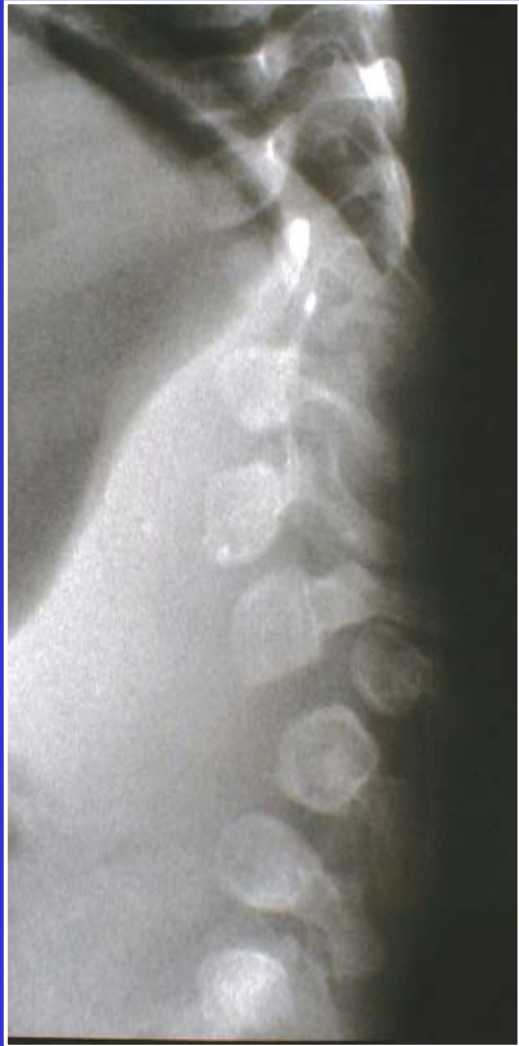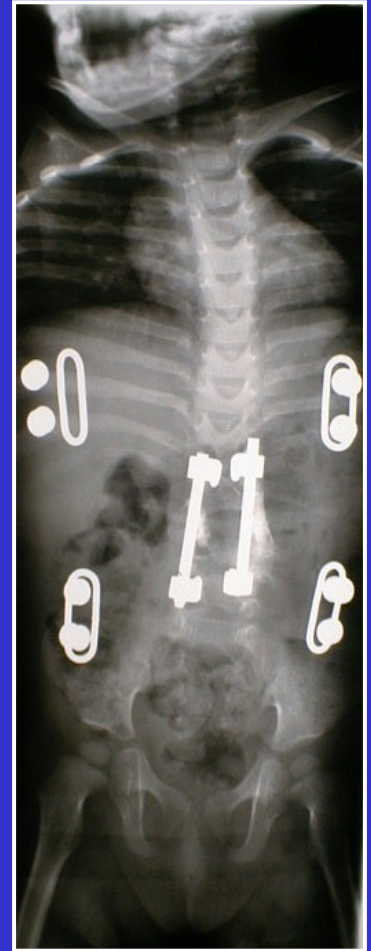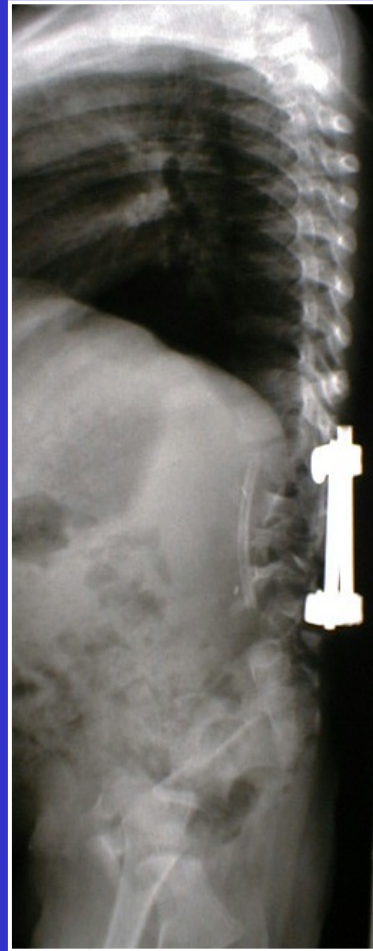


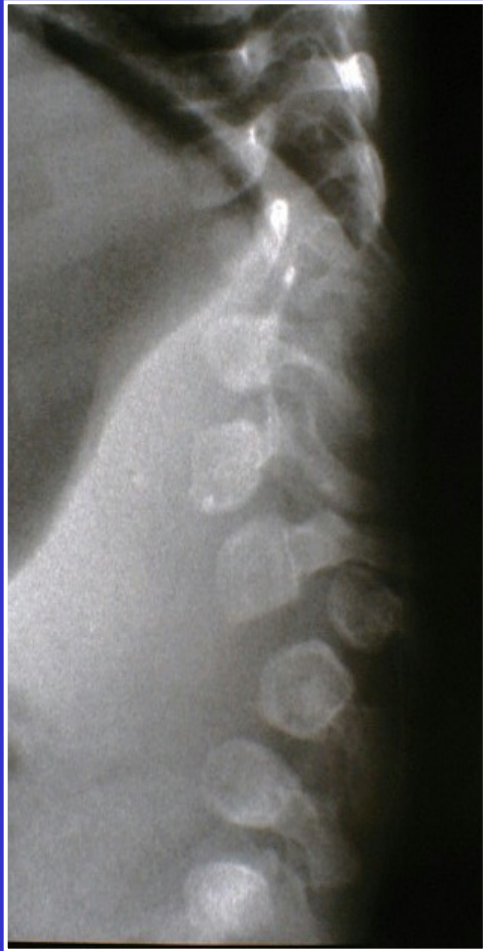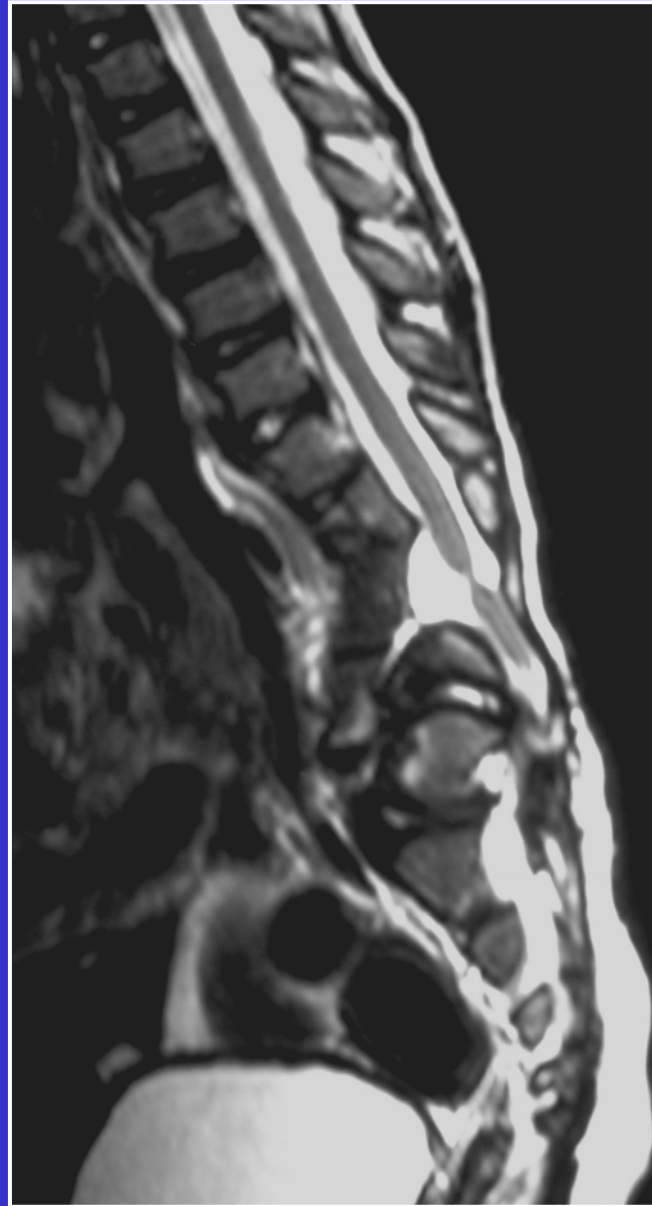
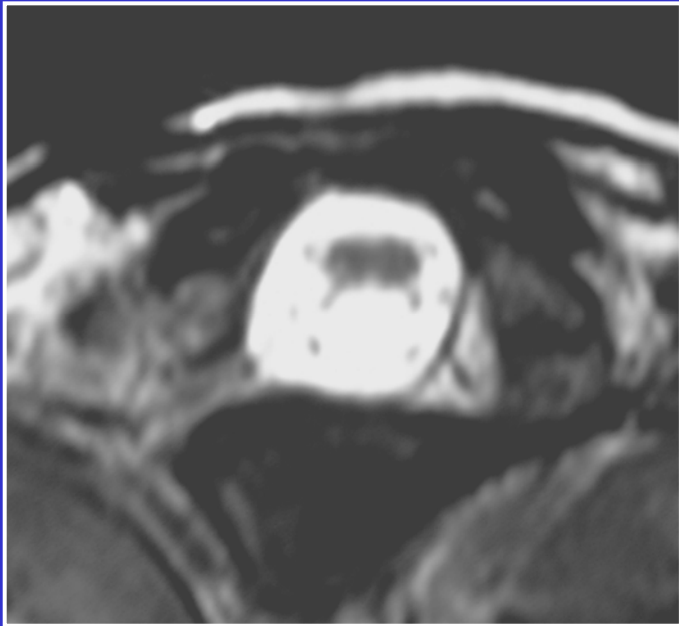
LUXATION CONGENITALE DU RACHIS


ATTEINTE NEUROLOGIQUE
VARIABLE ALLANT D'UNE
PARAPLEGIE COMPLETE A
UNE PARAPRESIE











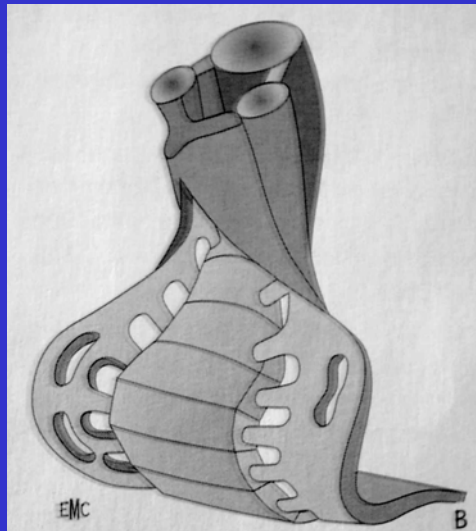
CLASSIFICATION DE WINTER

DEFAUT DE FORMATION

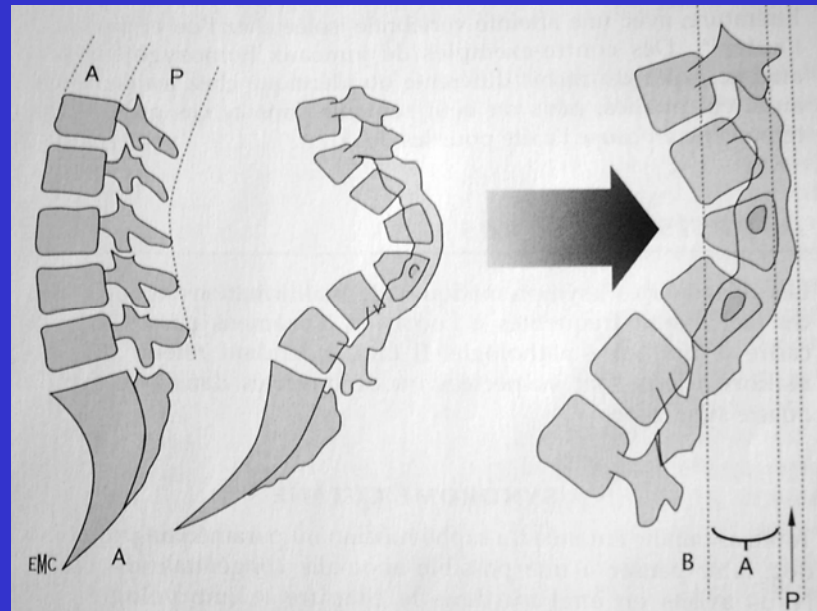
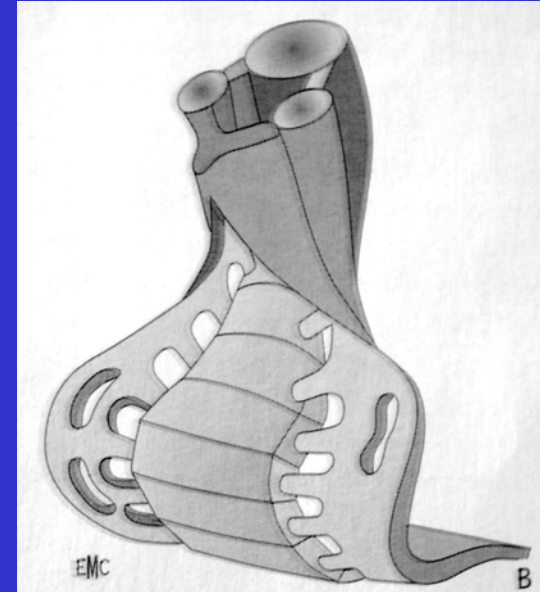
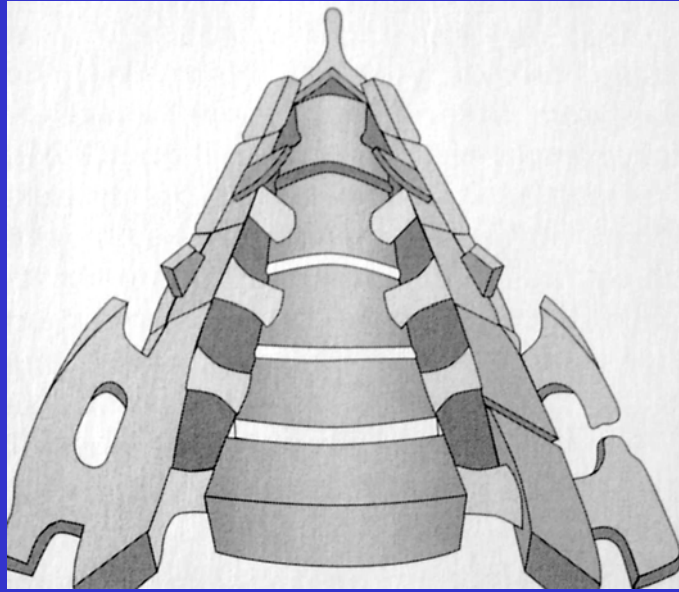
TYPE I

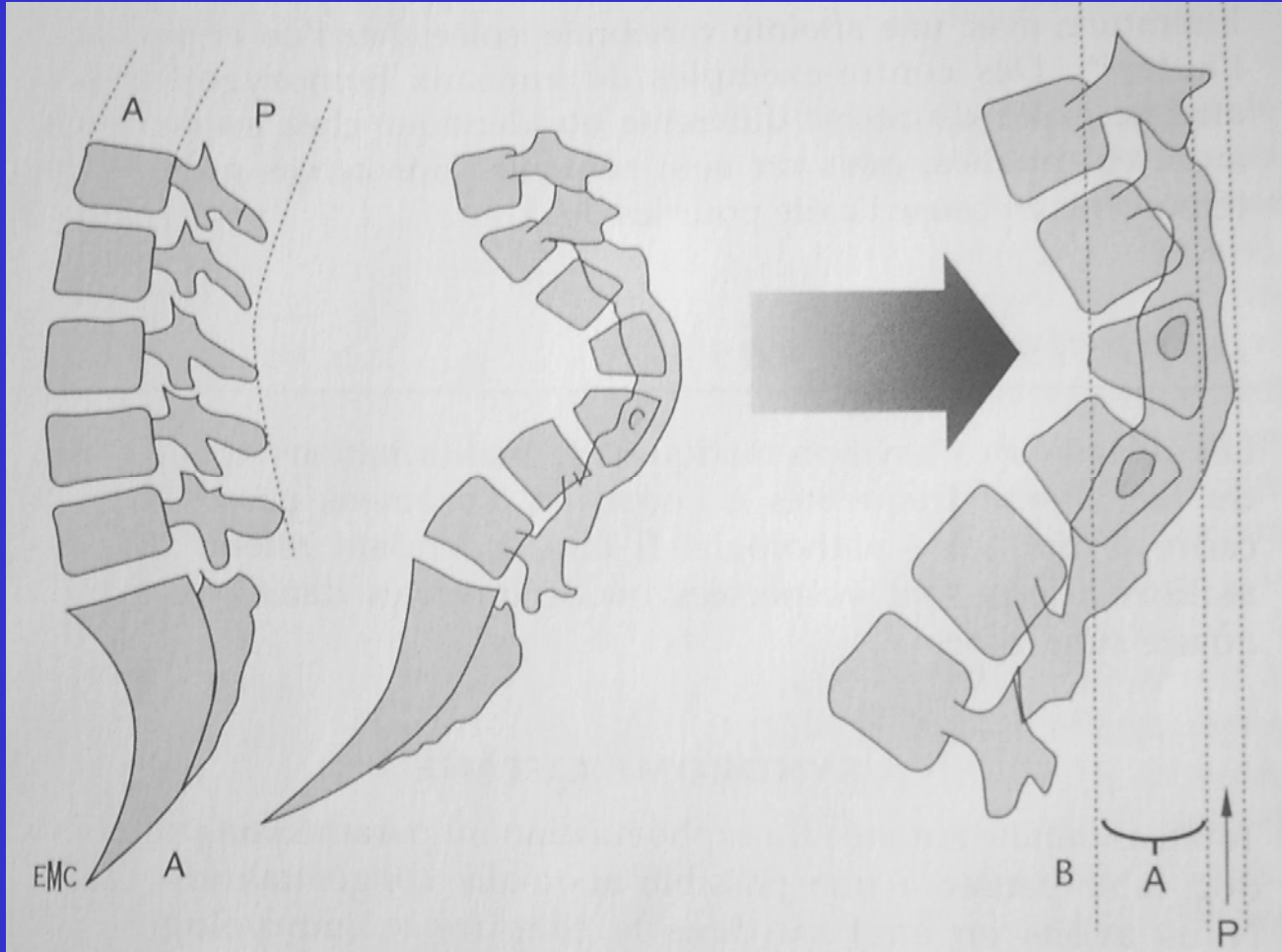
DEFECT ANTERO-LATERAL

DEFECT ANTERO-CENTRAL

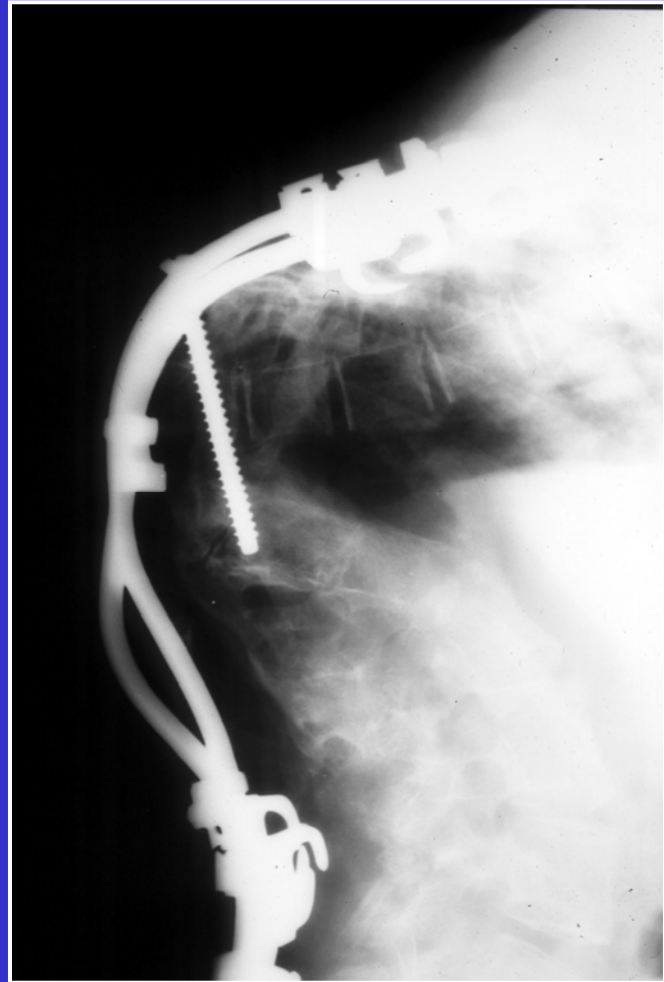
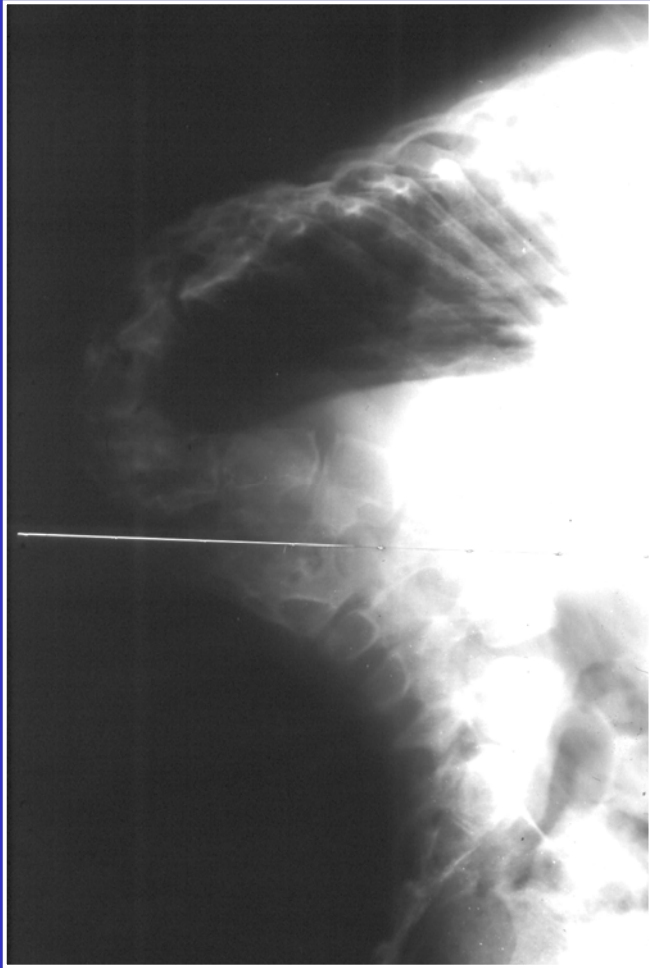

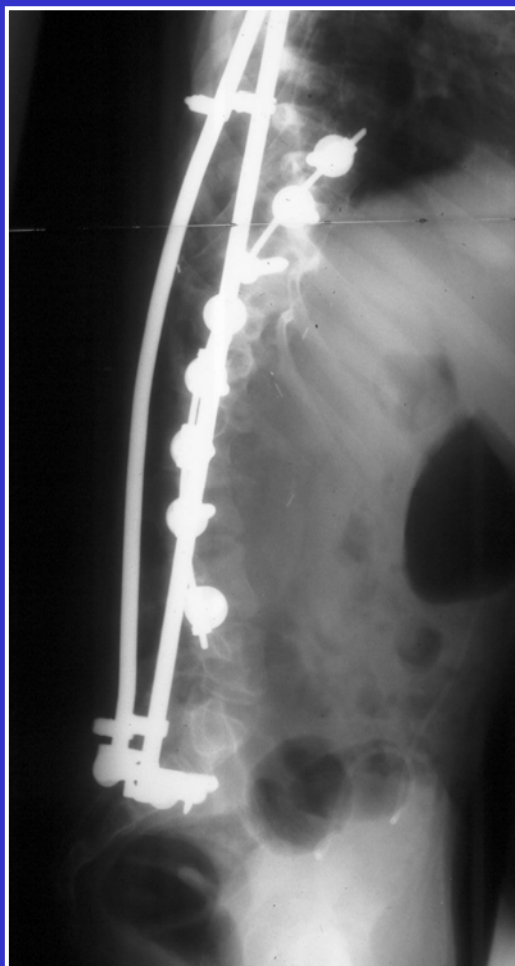
DEFECT POSTERIEUR

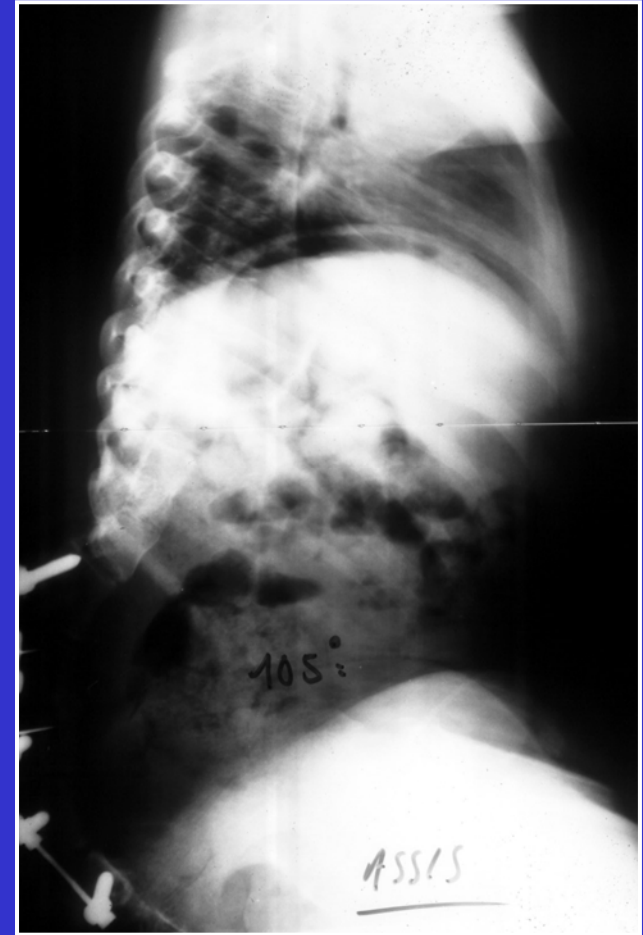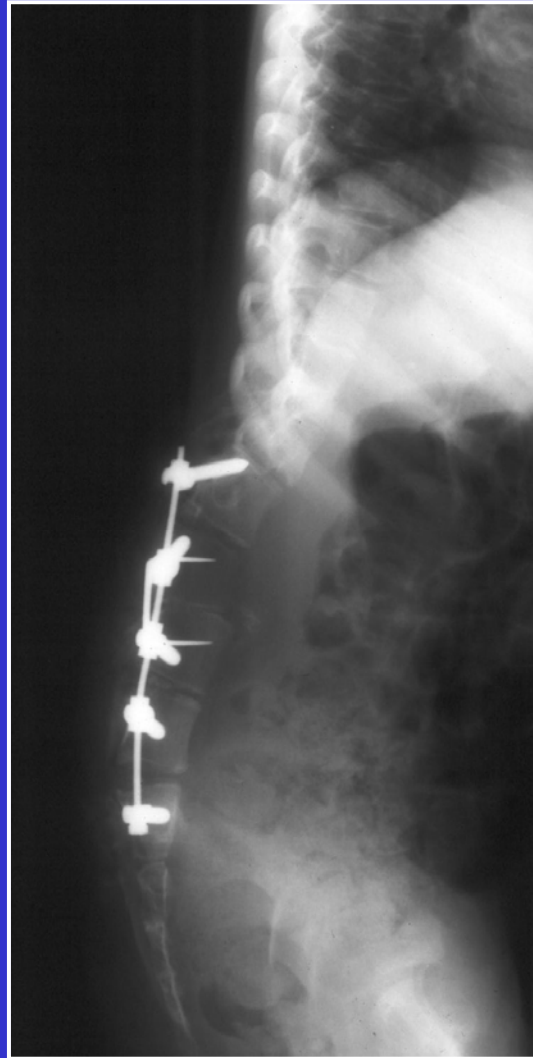
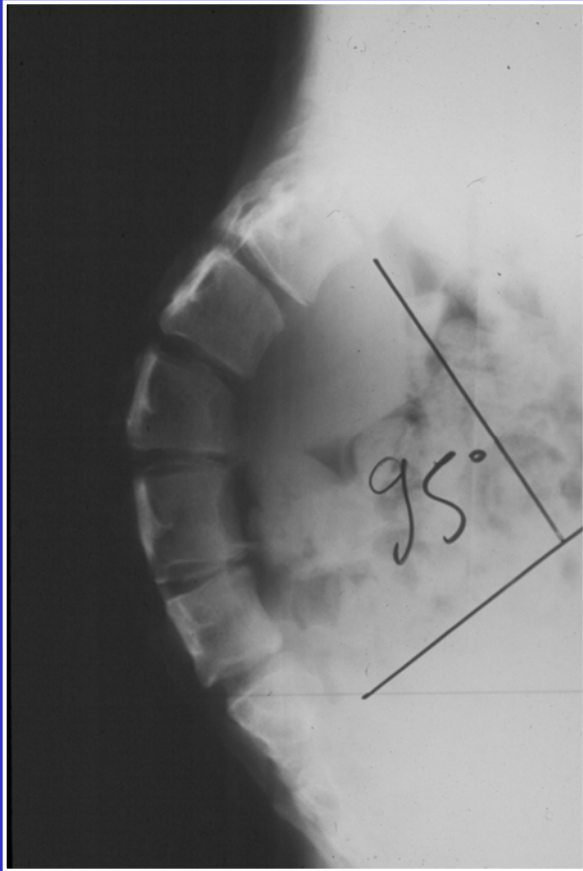


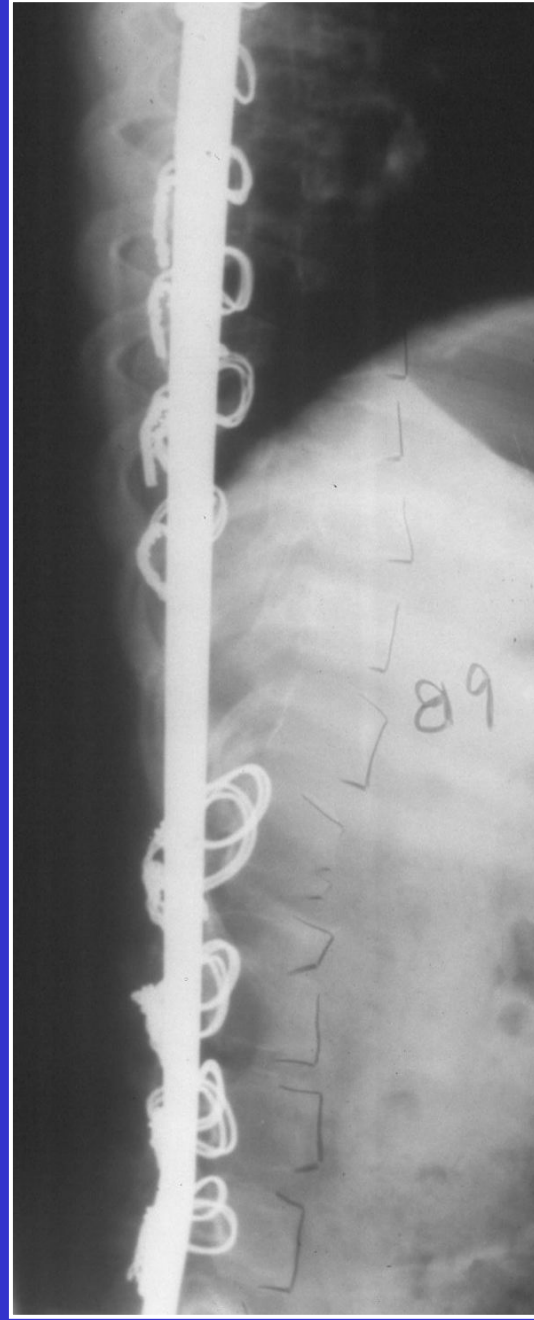
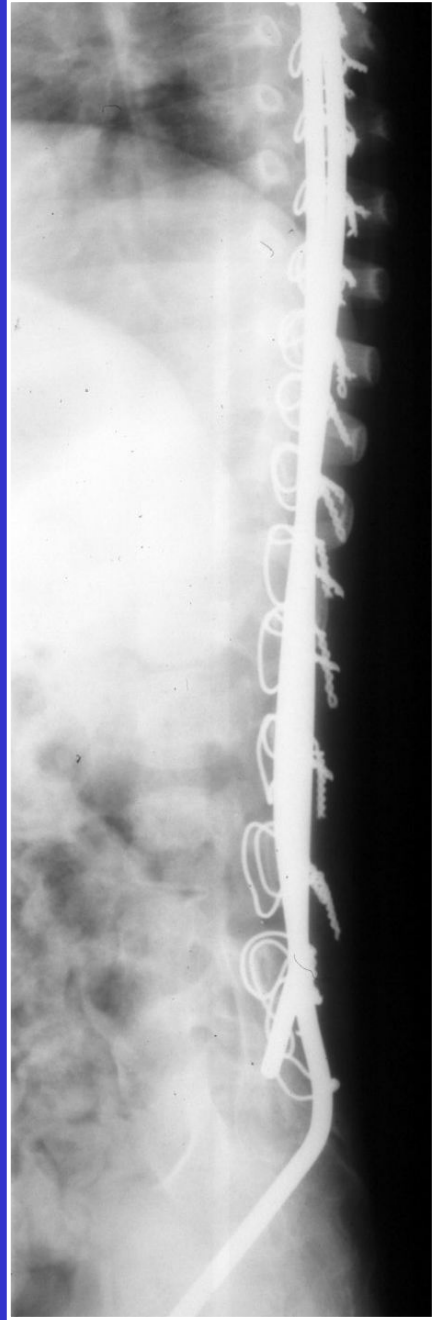












CLASSIFICATION DE WINTER

DEFAUT DE FORMATION

TYPE I

DEFECT ANTERO-LATERAL

DEFECT ANTERO-CENTRAL

DEFAUT DE SEGMENTATION

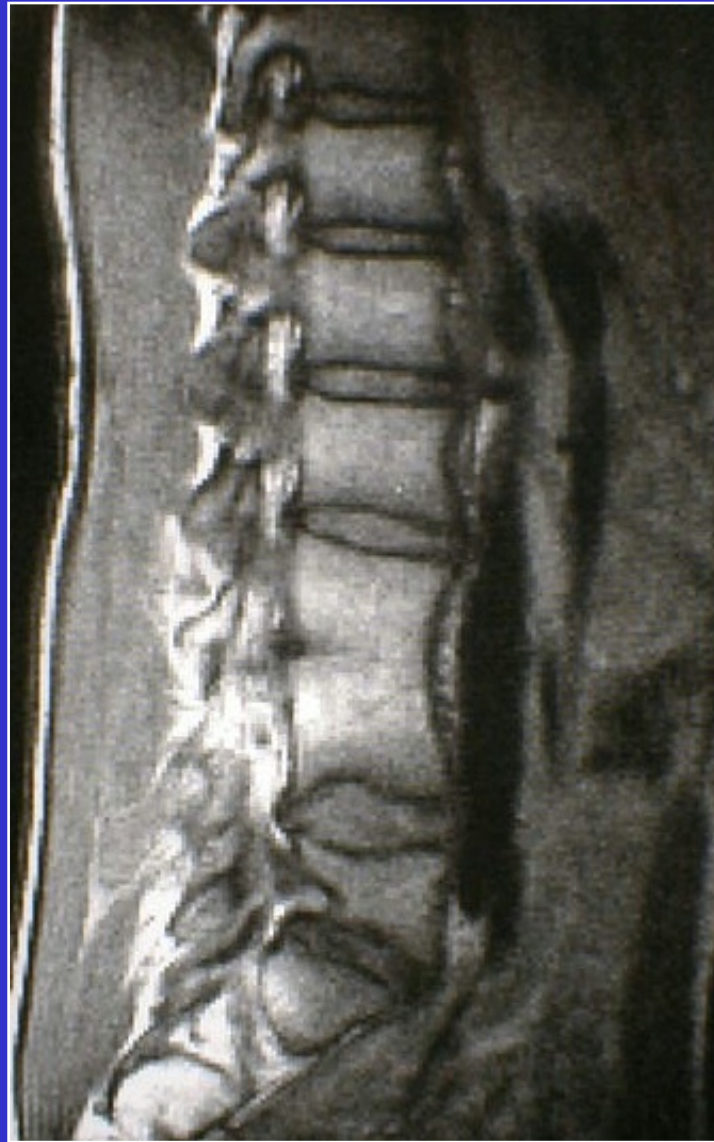TYPE II

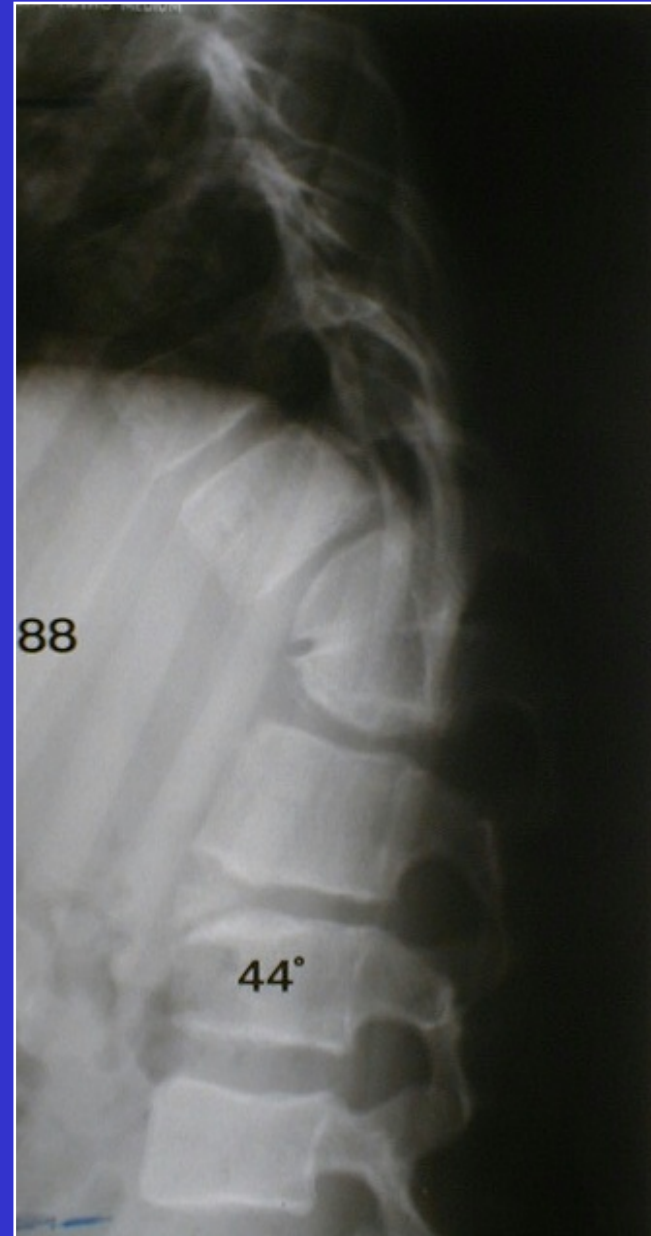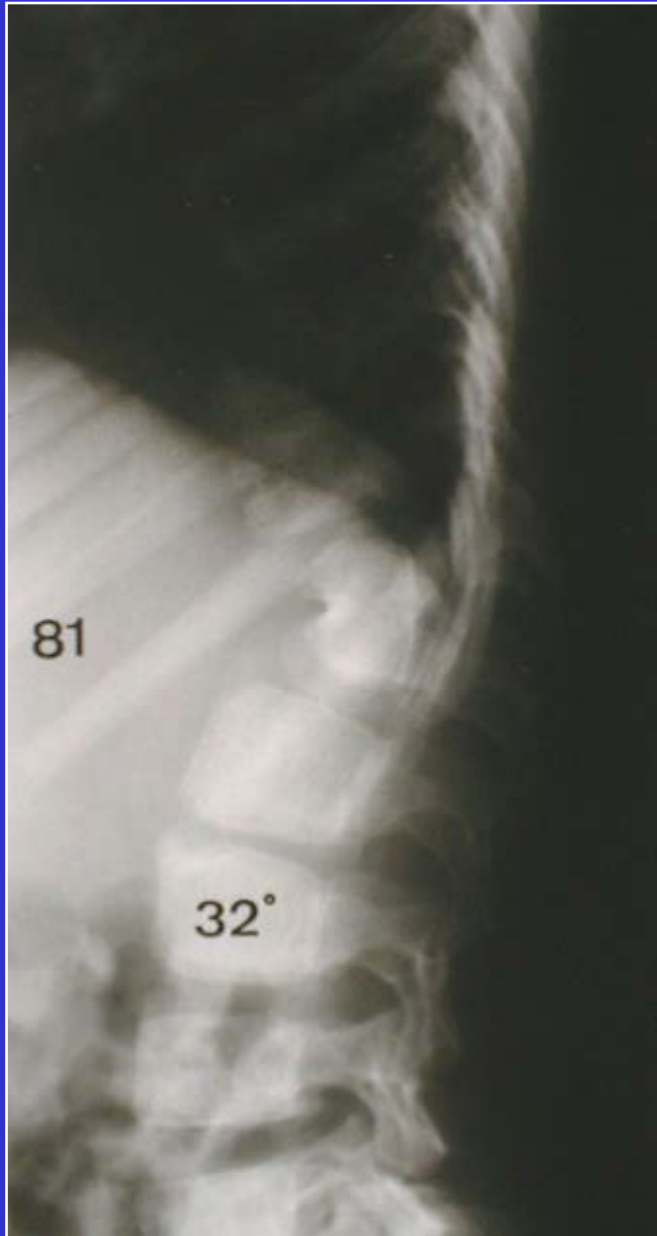
FUSION ANTERIEURE TOTALE

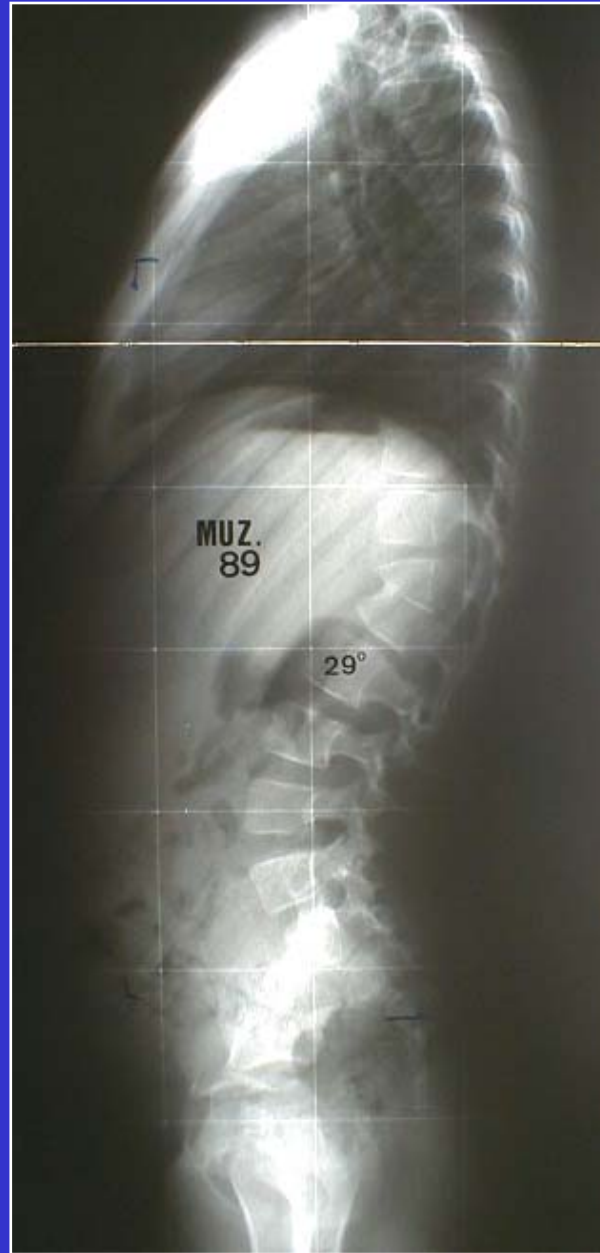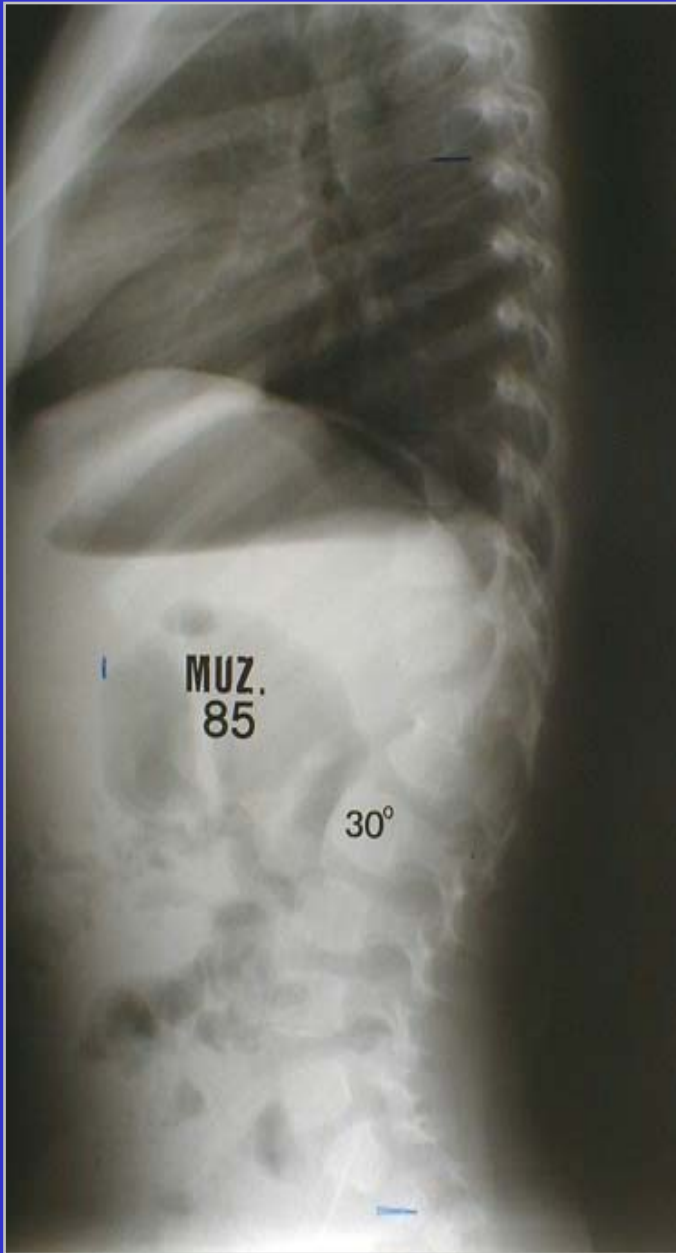
FUSION ANTERIEURE PROGRESSIVE

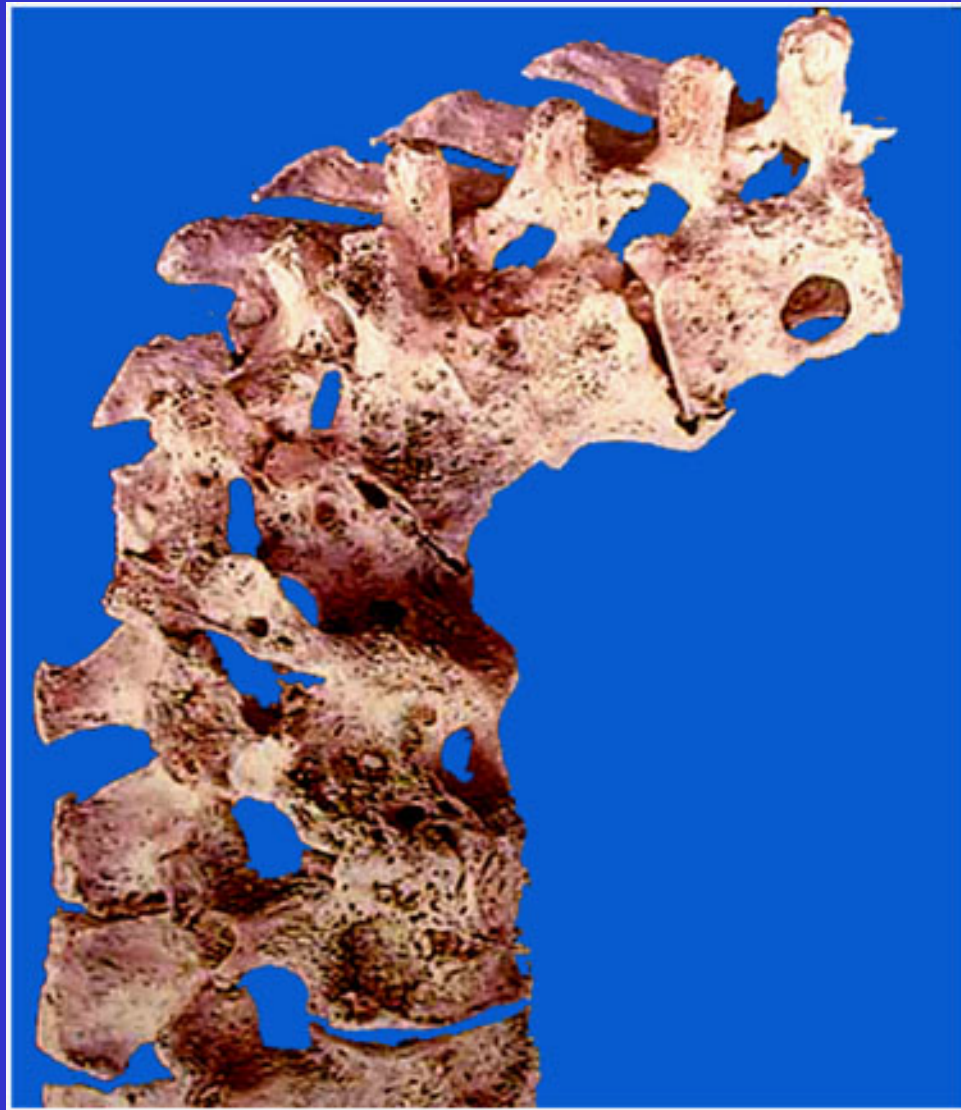MALFORMATION COMPLEXE

TYPE III

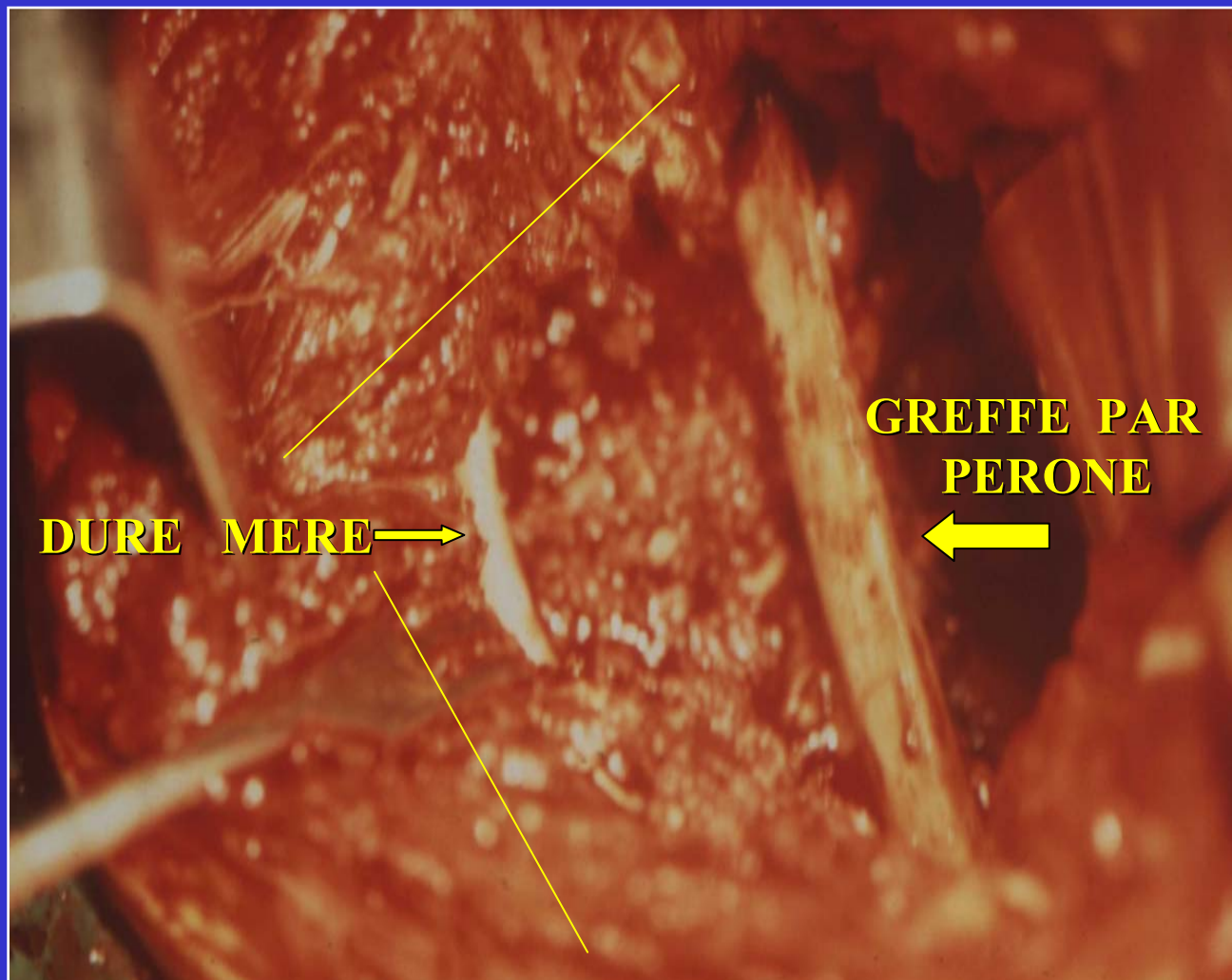
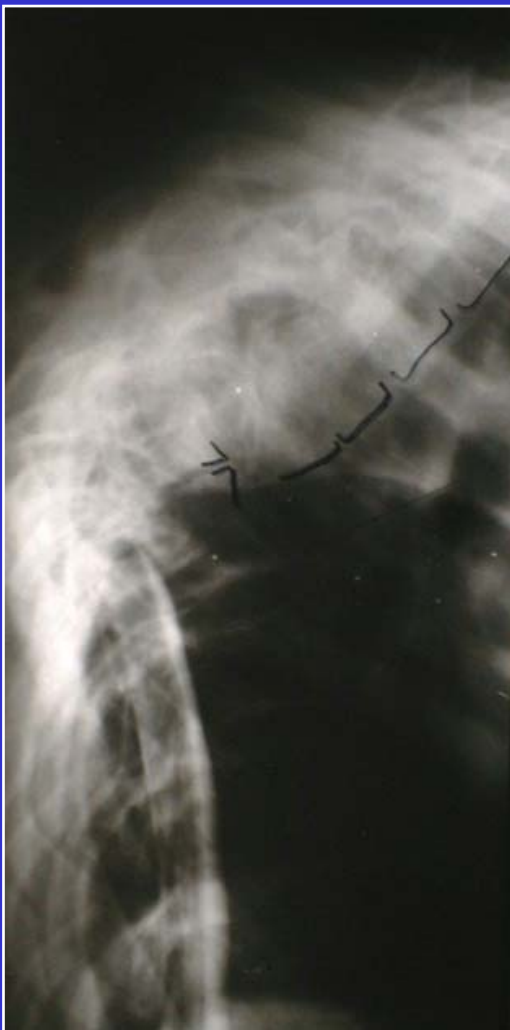

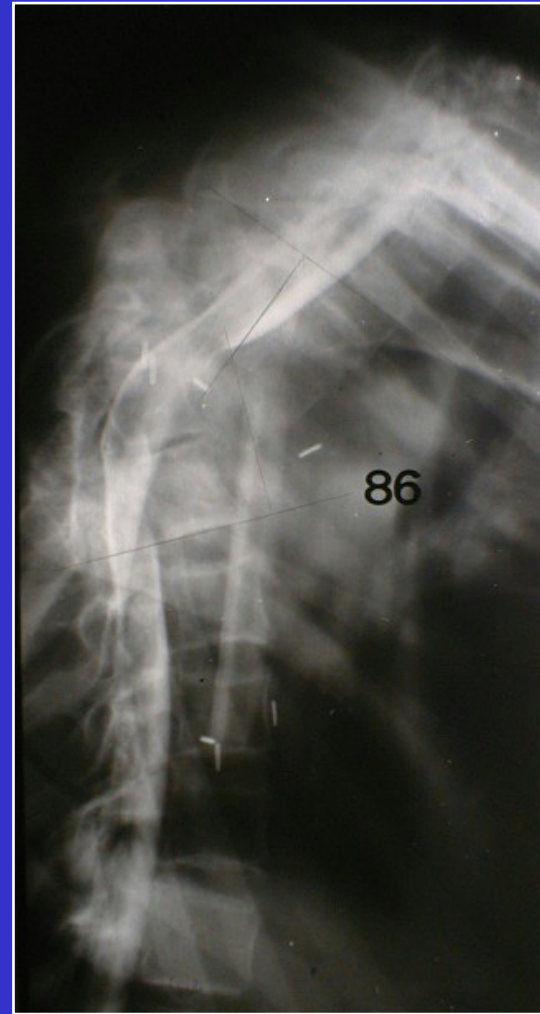

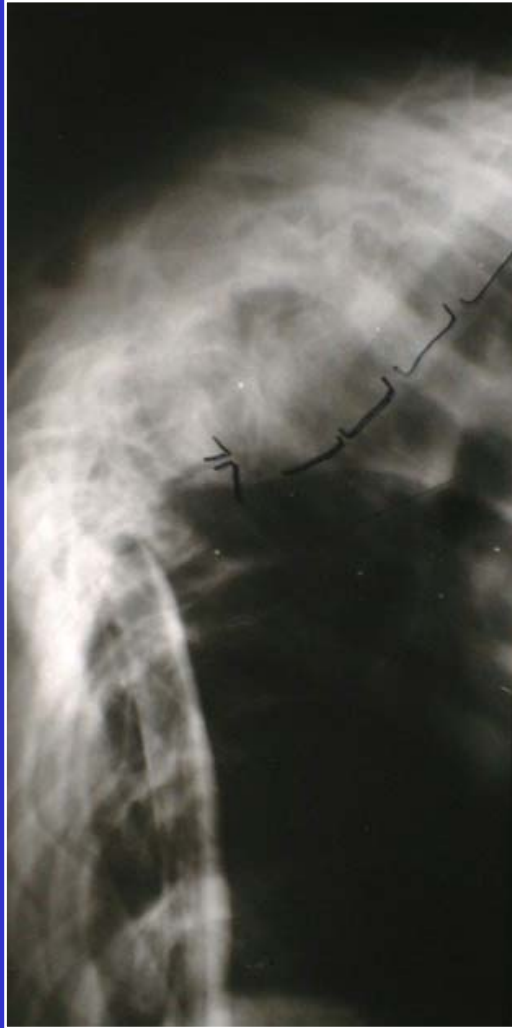


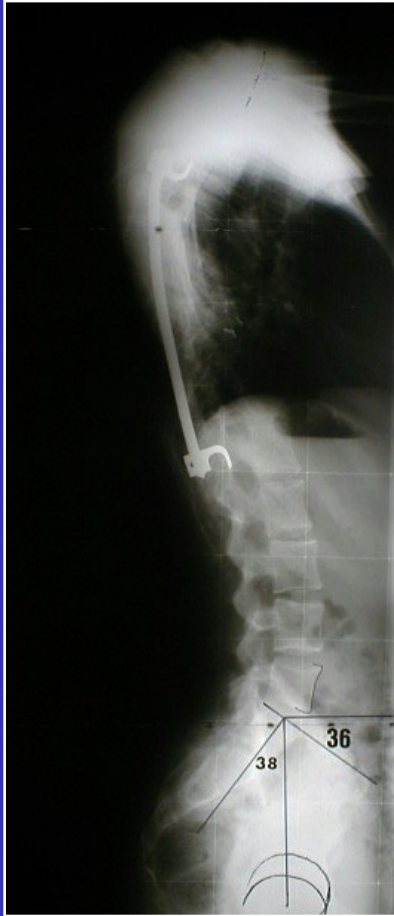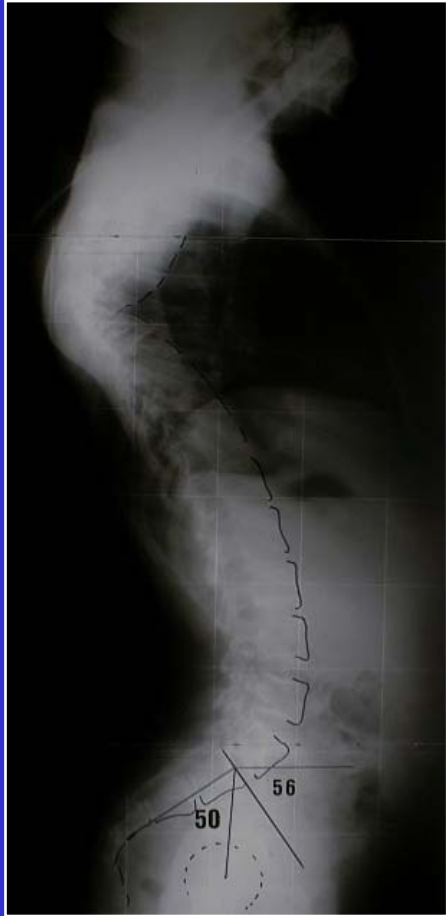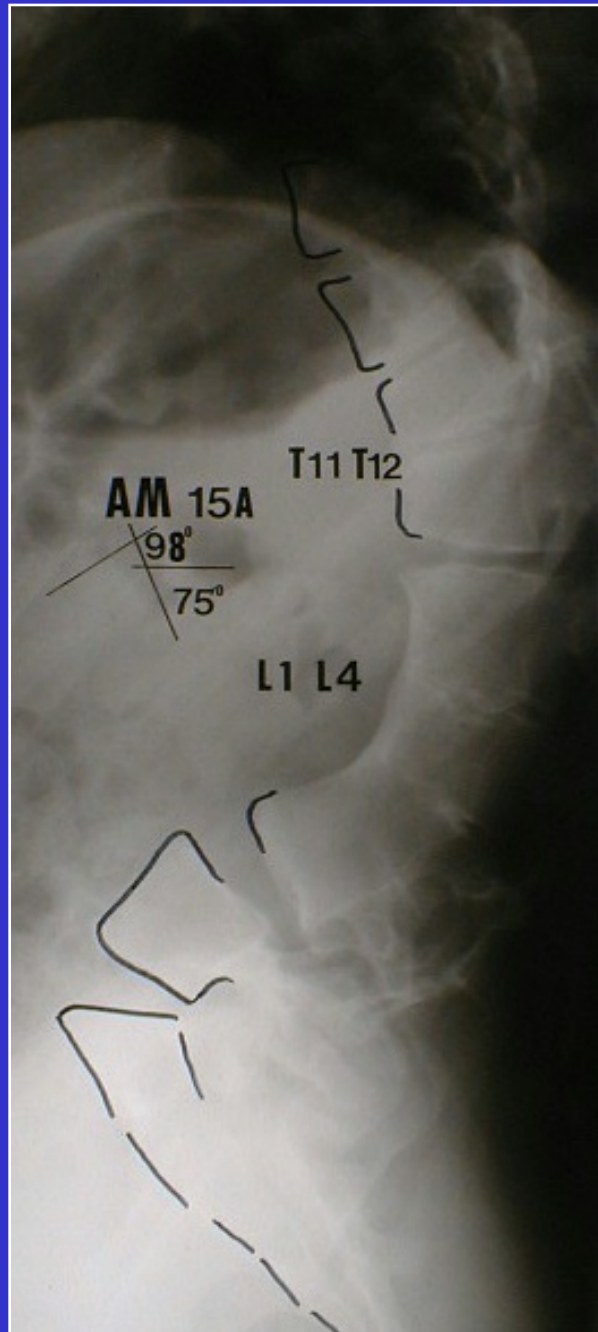


TRANSLOCATION INTRA THORACIQUE MEDULLAIRE









CLASSIFICATION DE WINTER

DEFAUT DE FORMATION

TYPE I

DEFECT ANTERO-LATERAL

DEFECT ANTERO-CENTRAL

DEFAUT DE SEGMENTATION

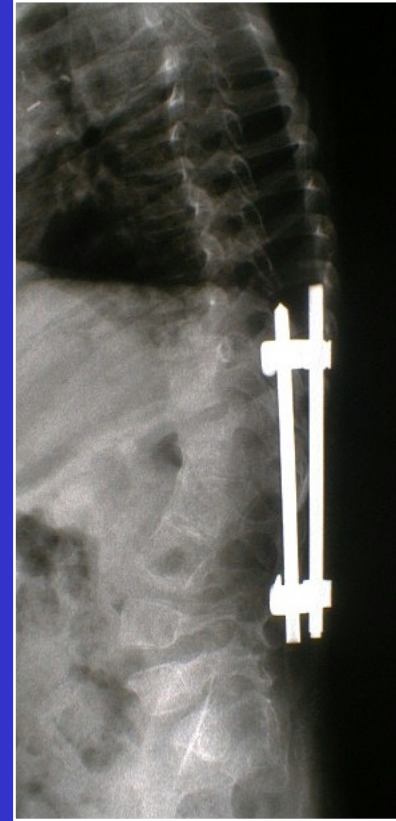
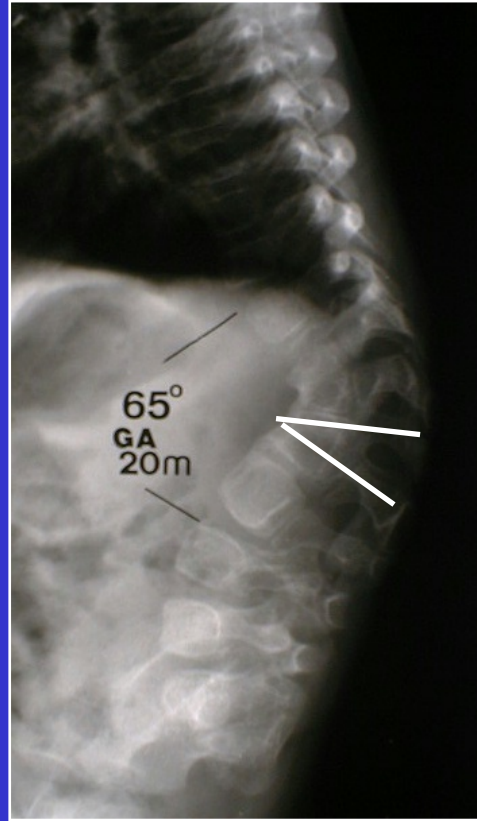
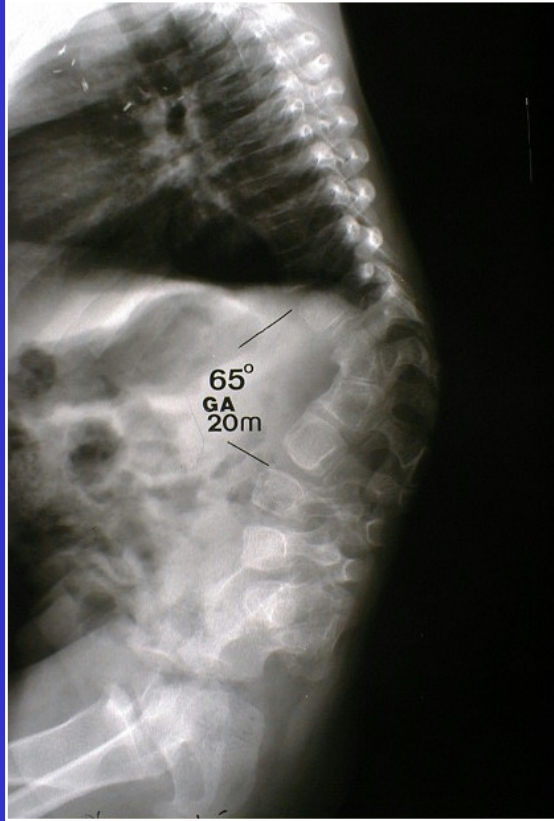
TYPE II

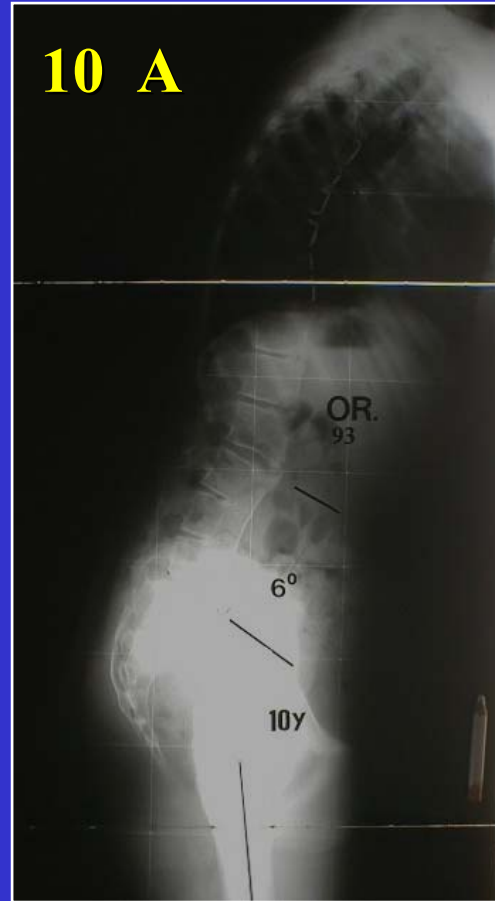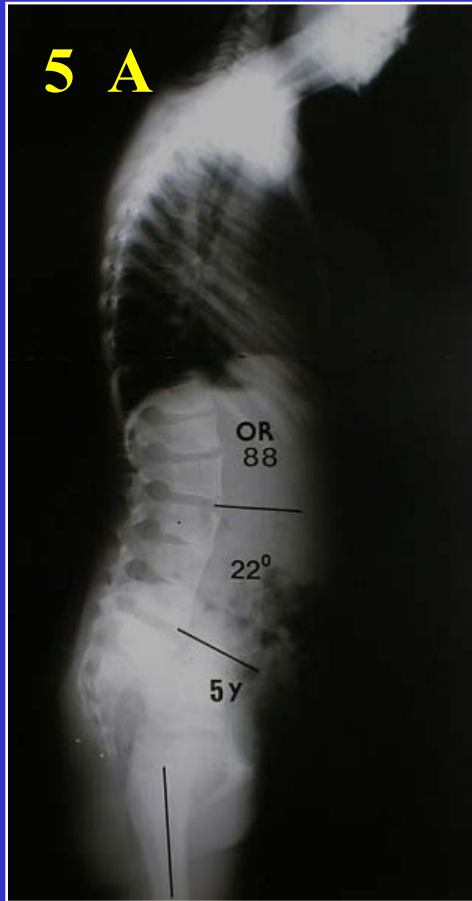FUSION ANTERIEURE TOTALE


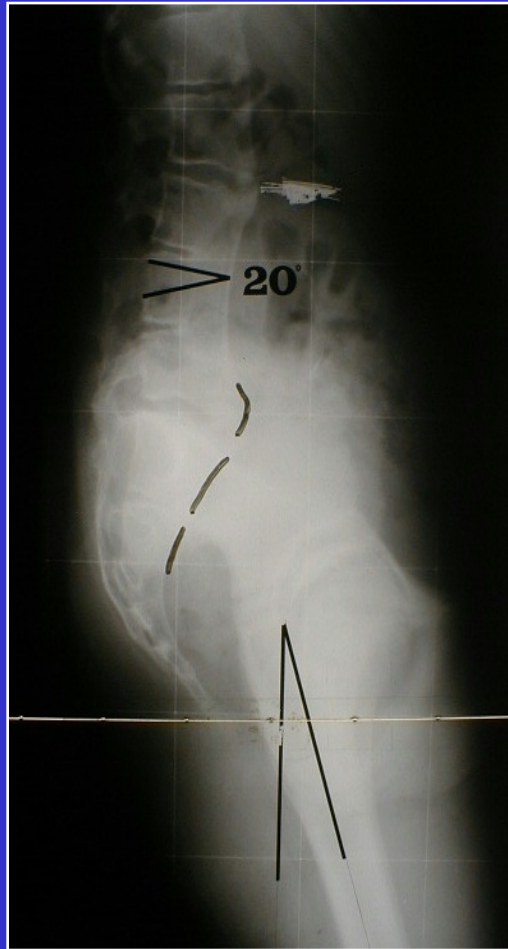
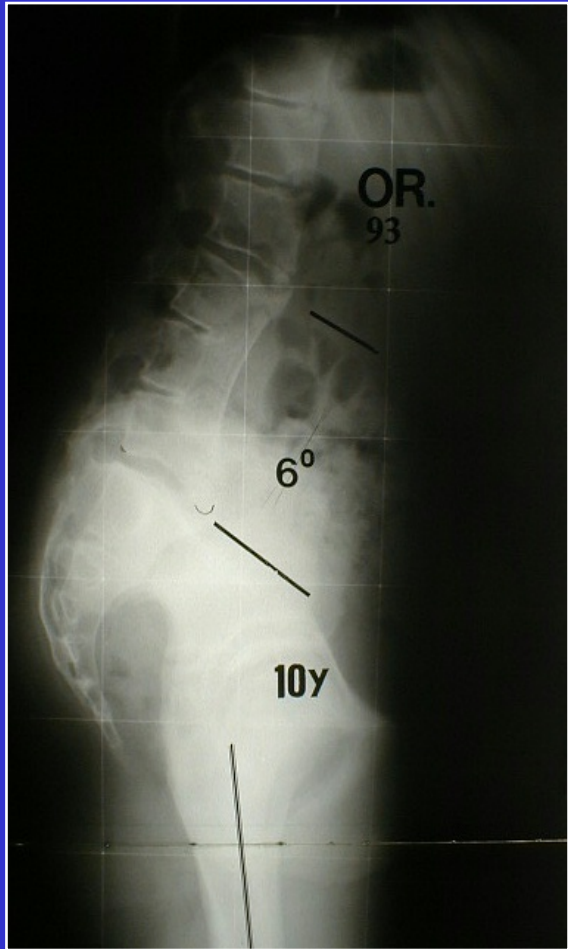
FUSION ANTERIEURE PROGRESSIVE

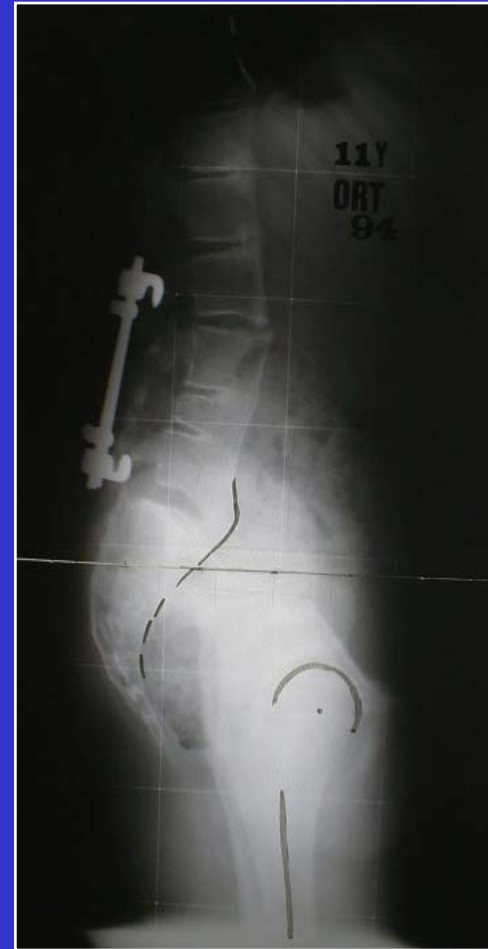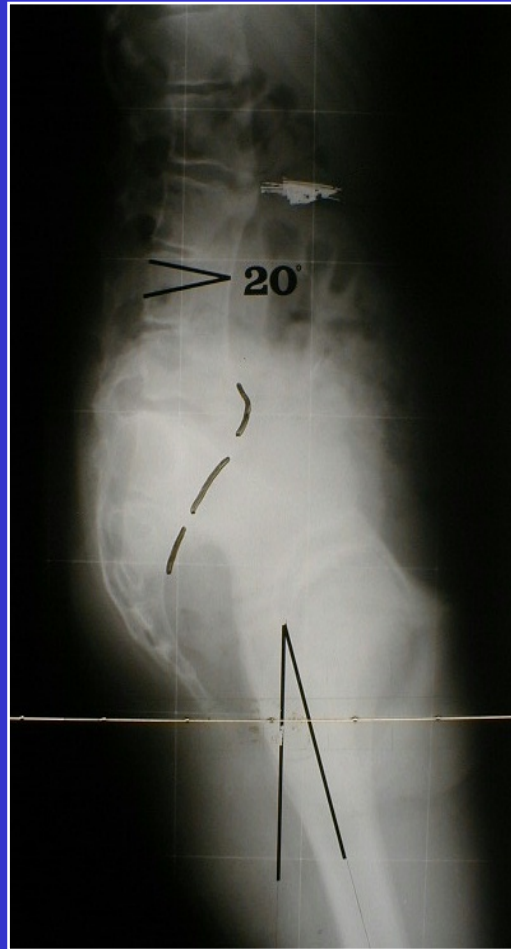
MALFORMATION COMPLEXE

TYPE III

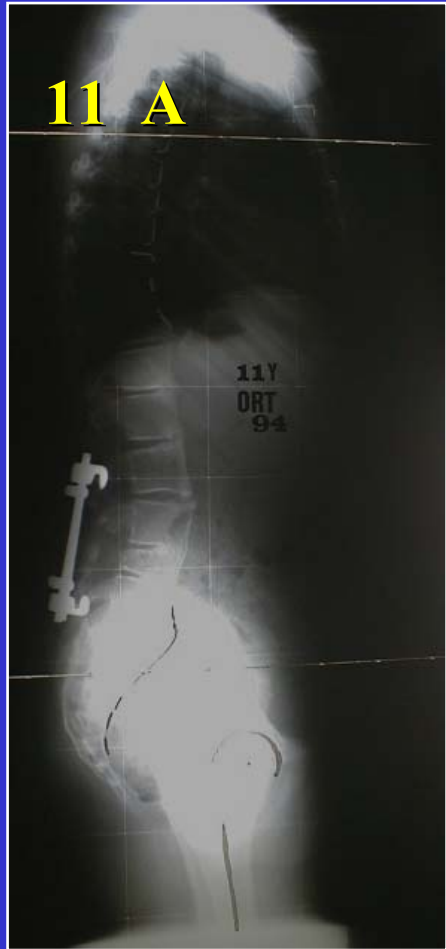




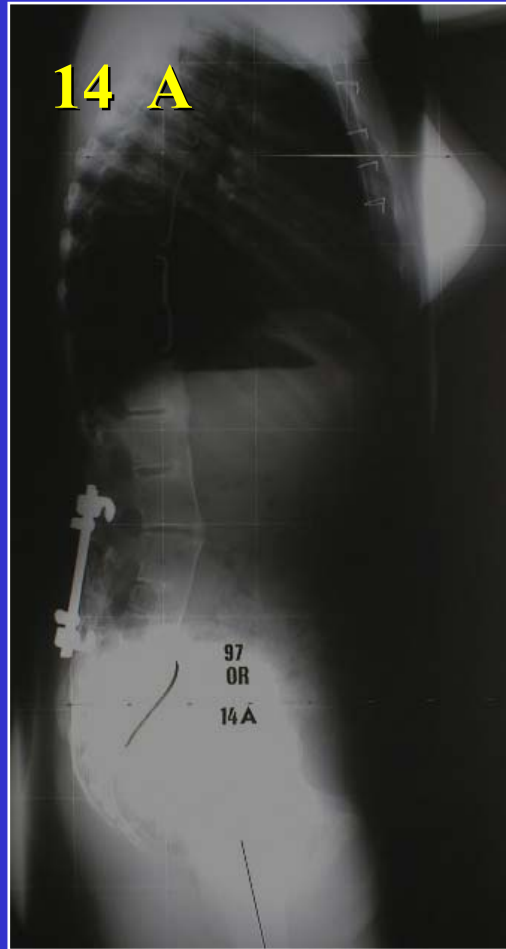
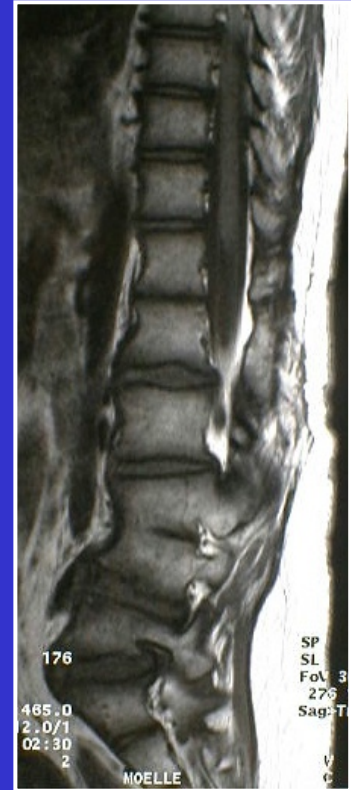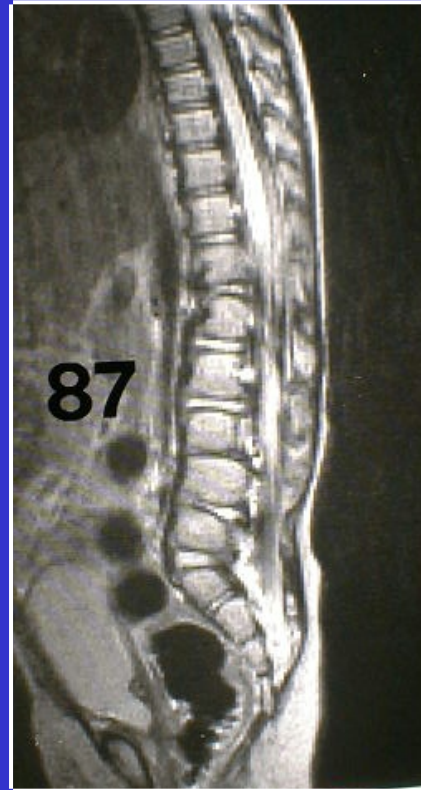
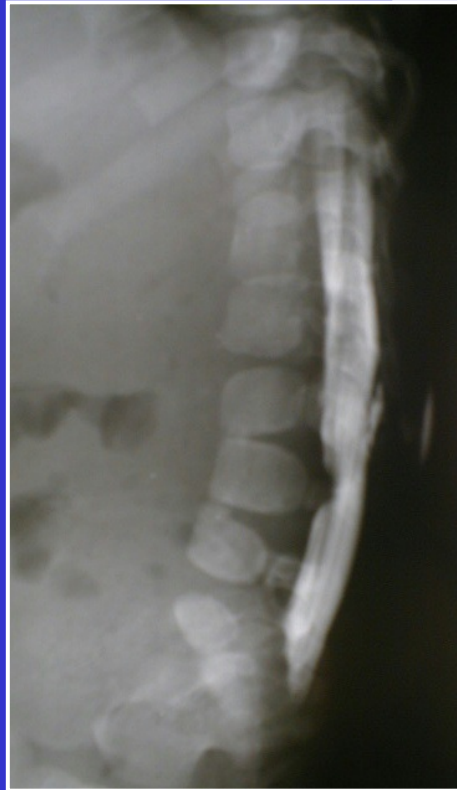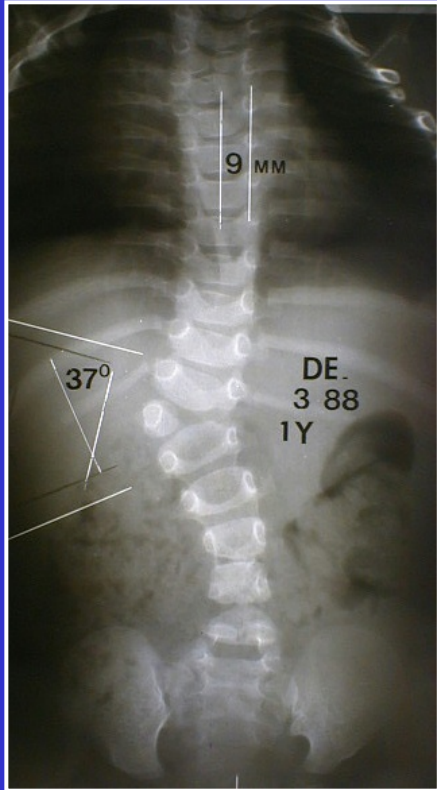


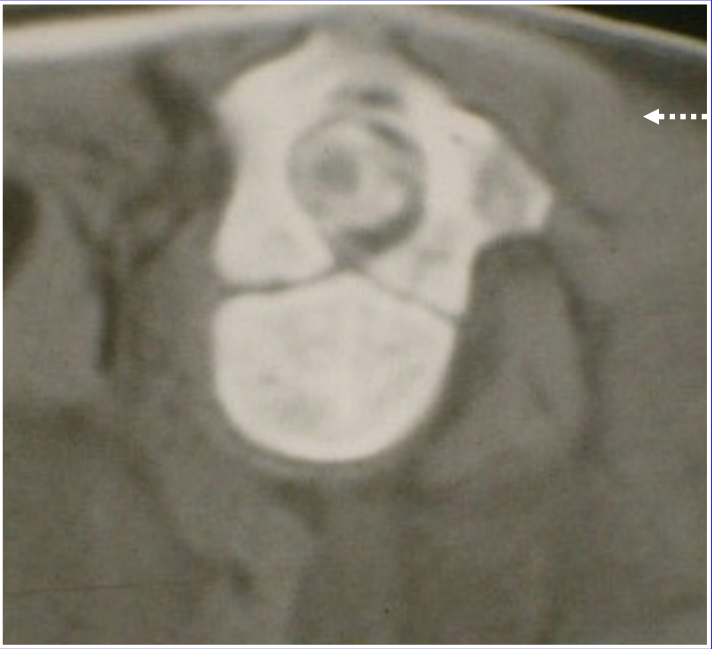
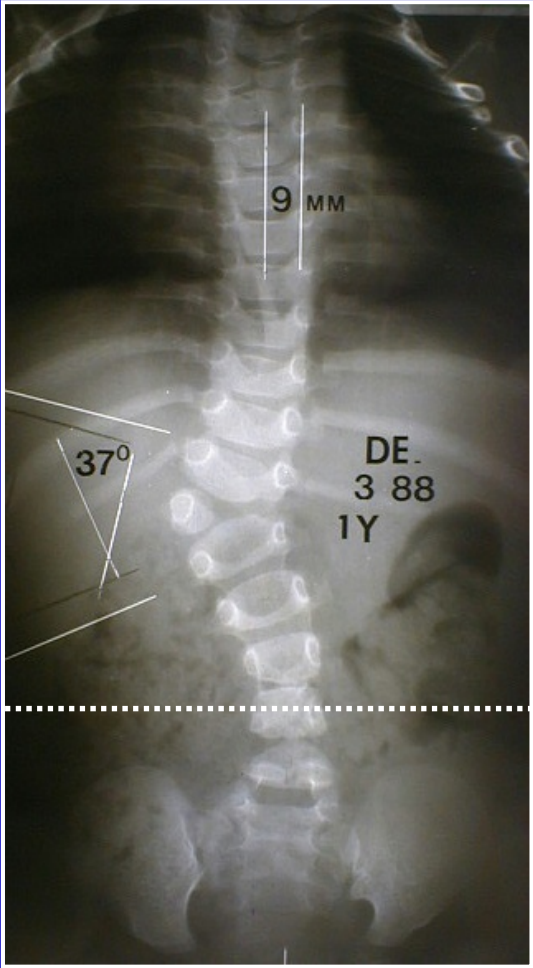
11 A

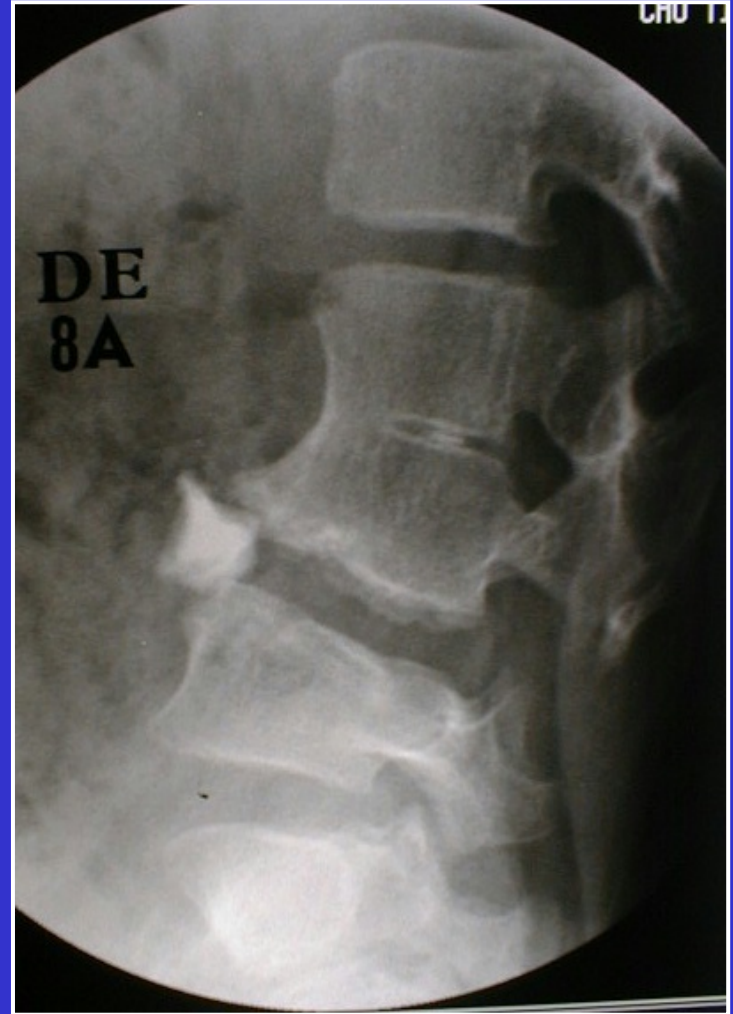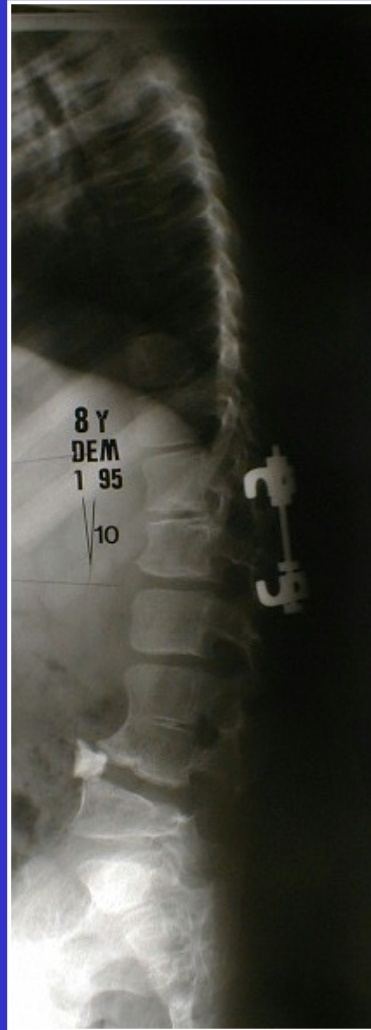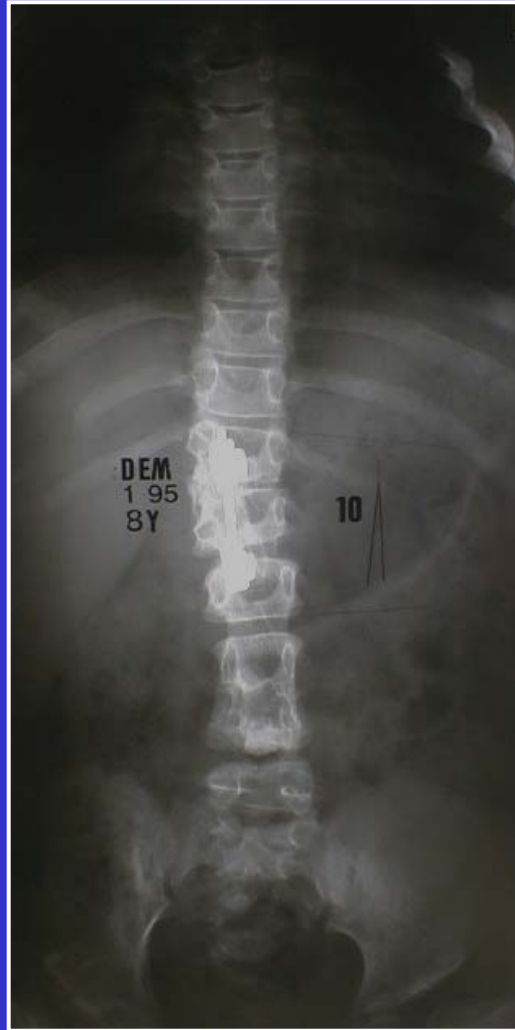


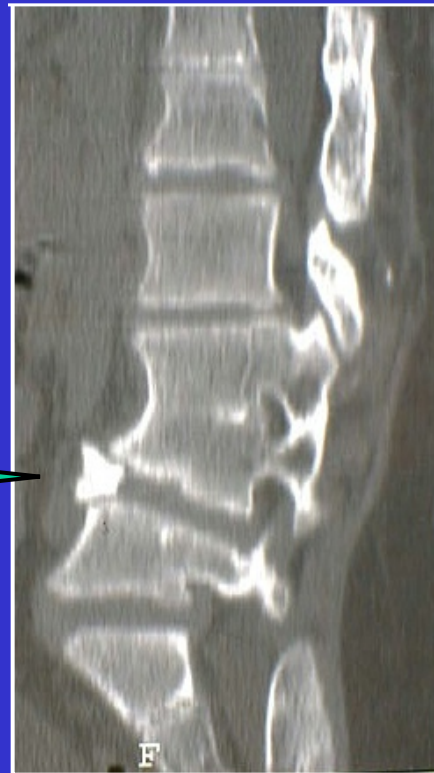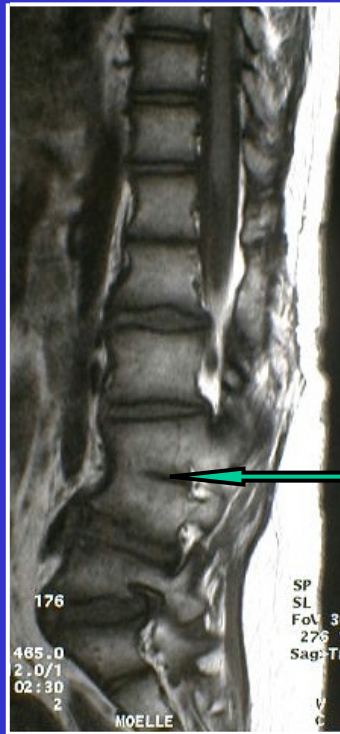
14 A



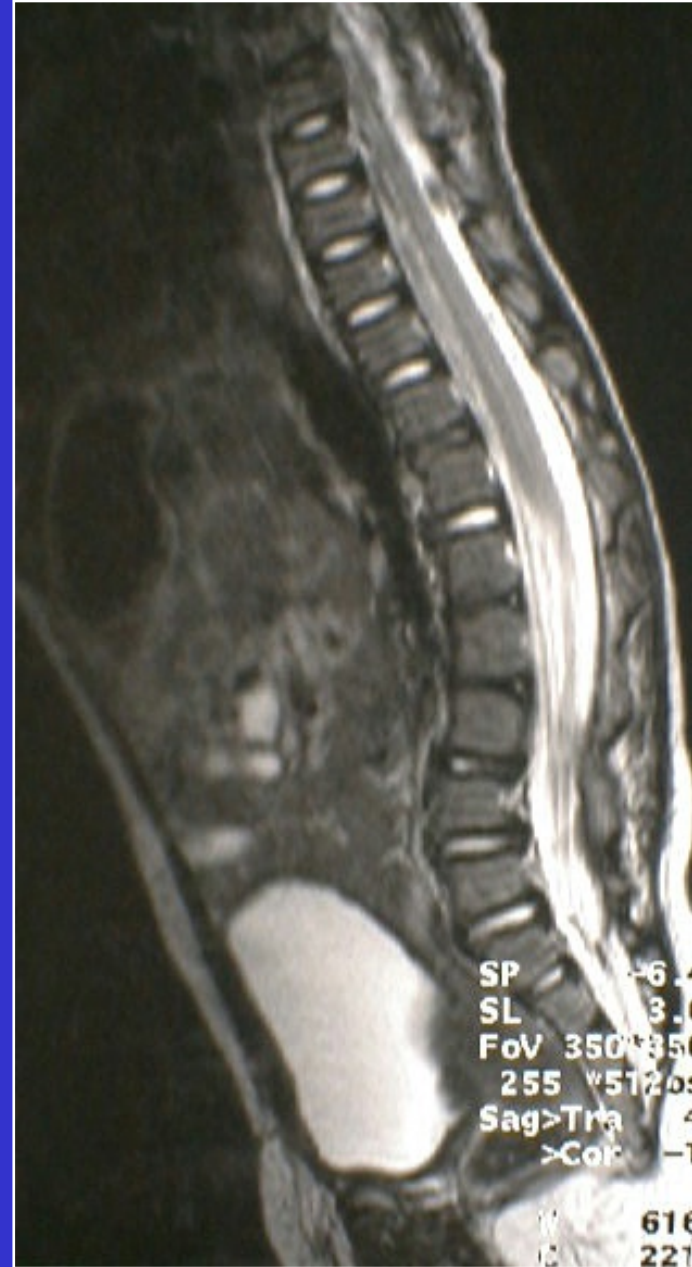
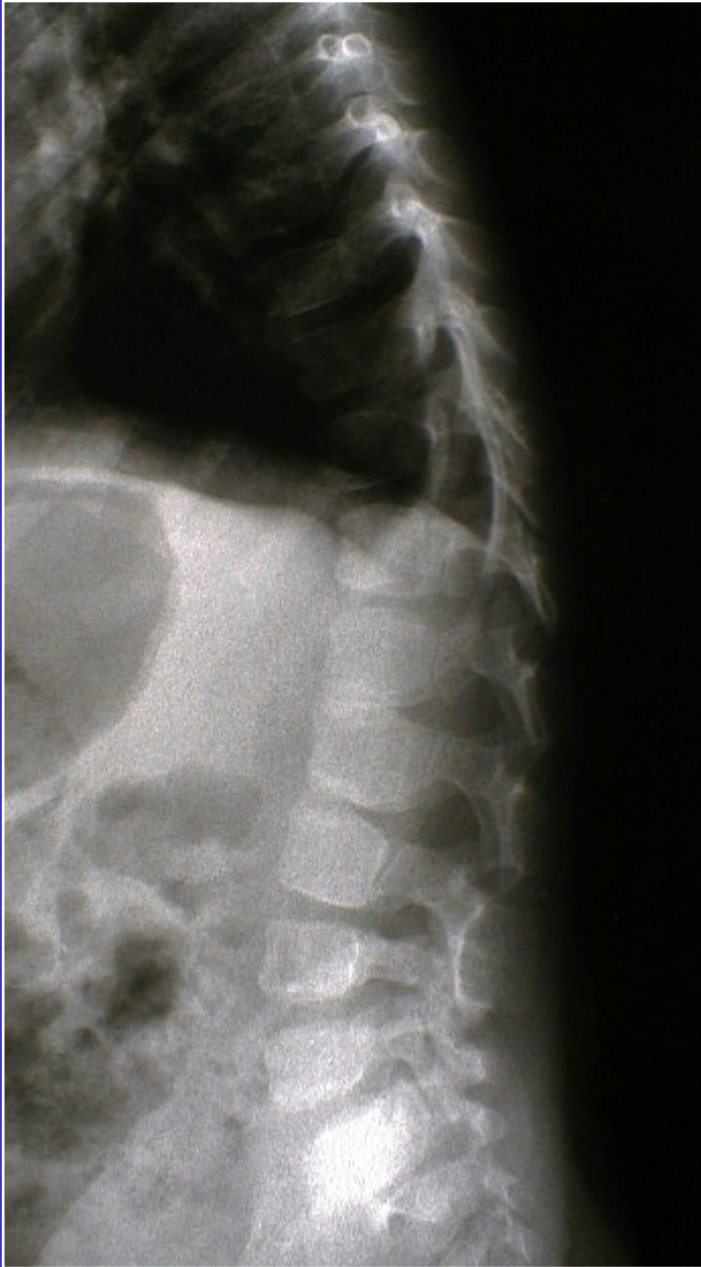

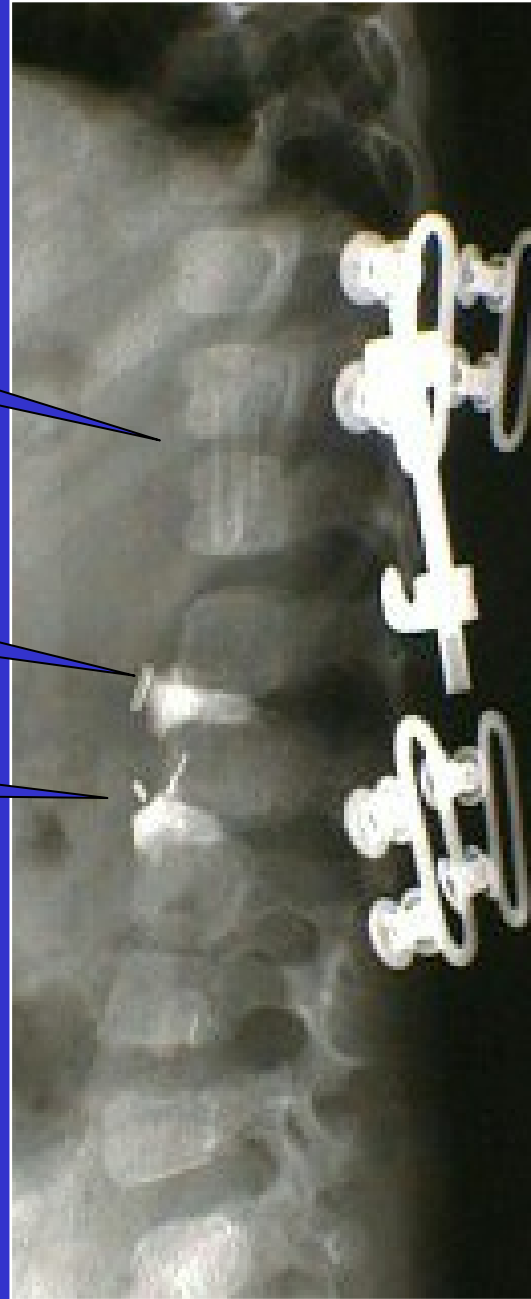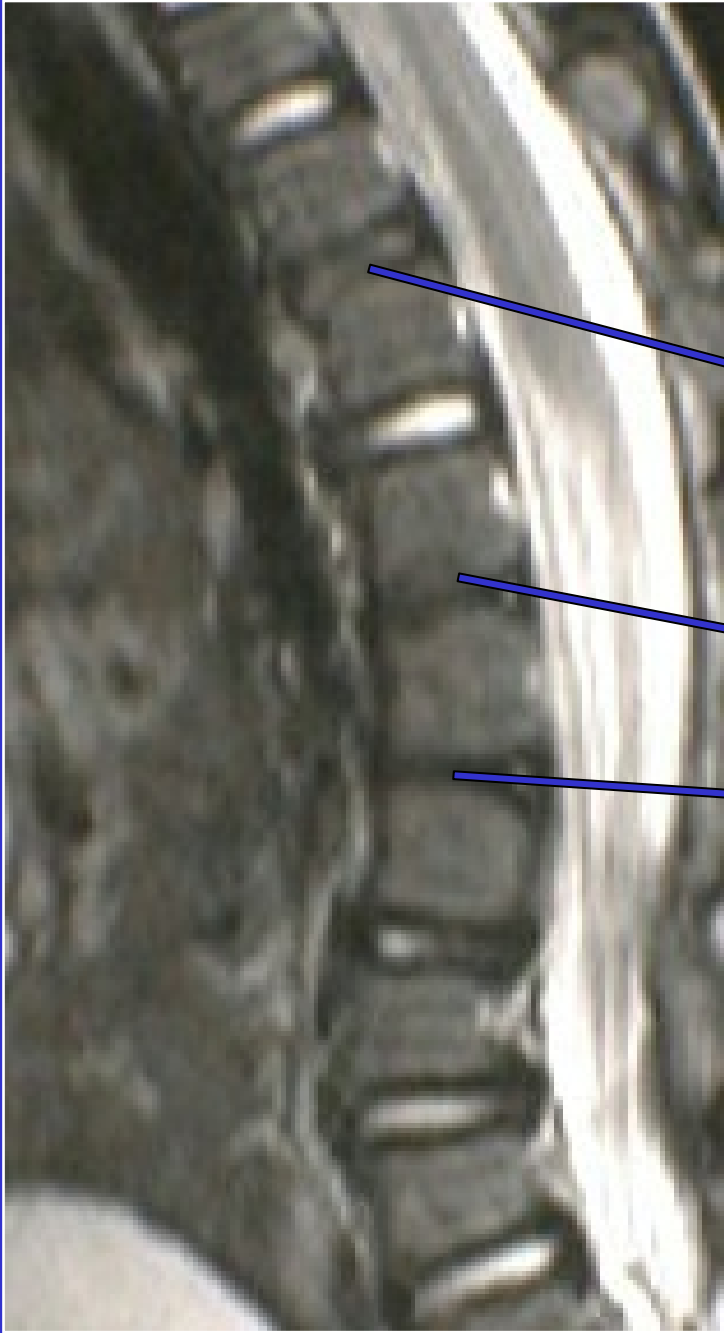




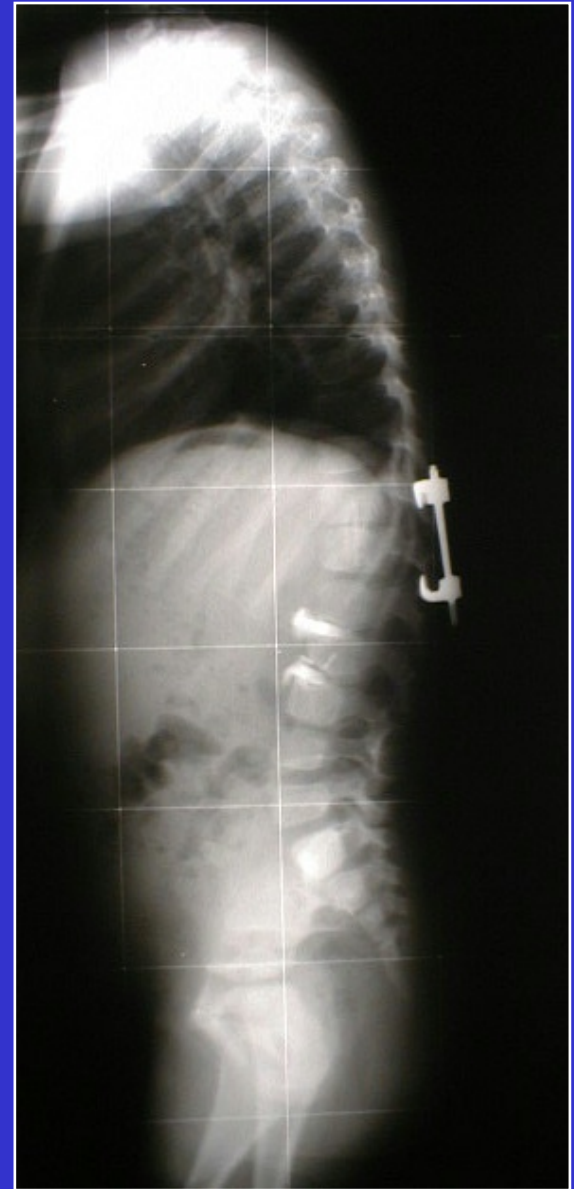
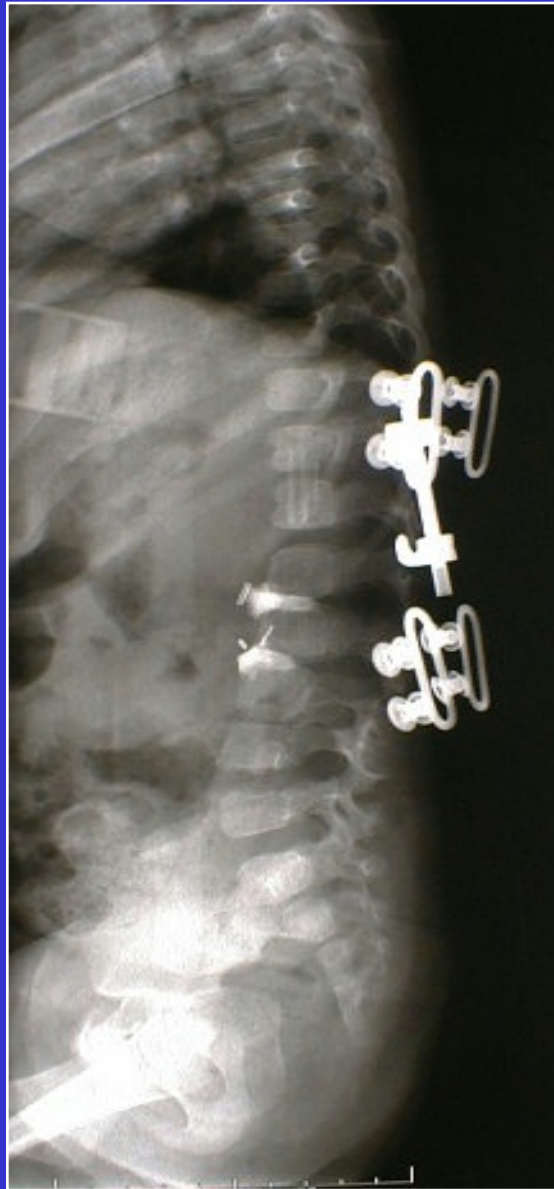
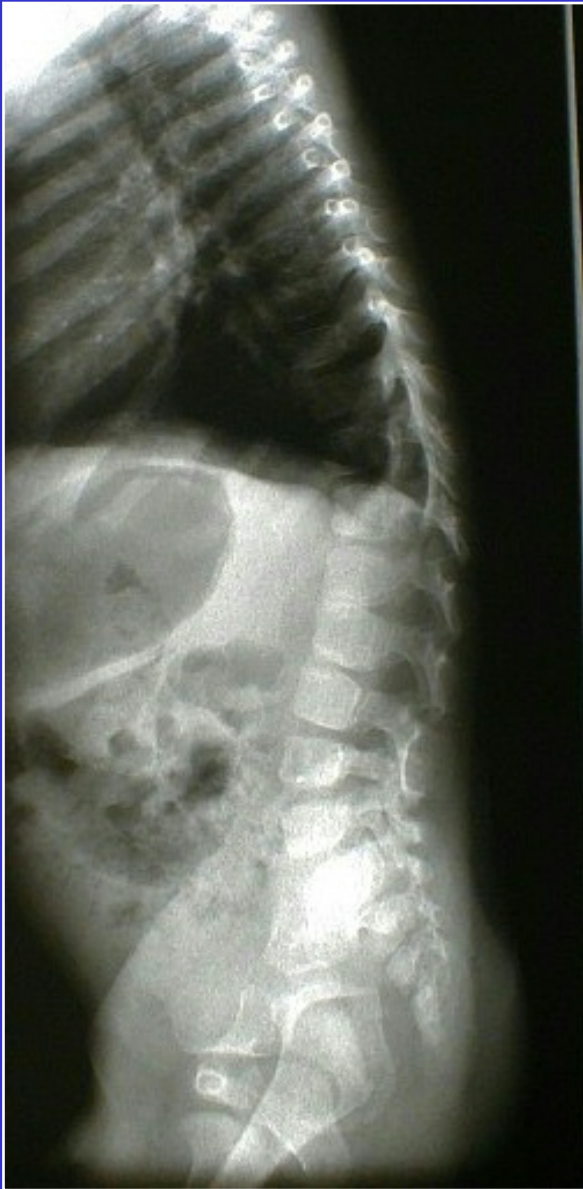

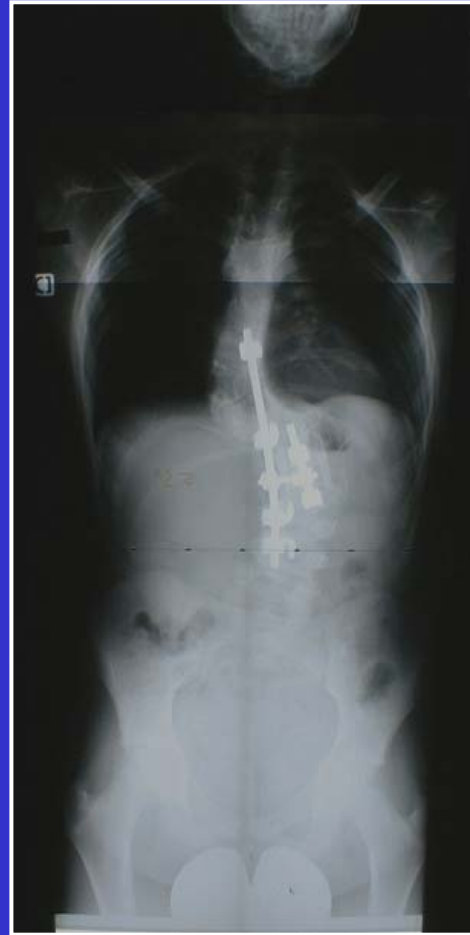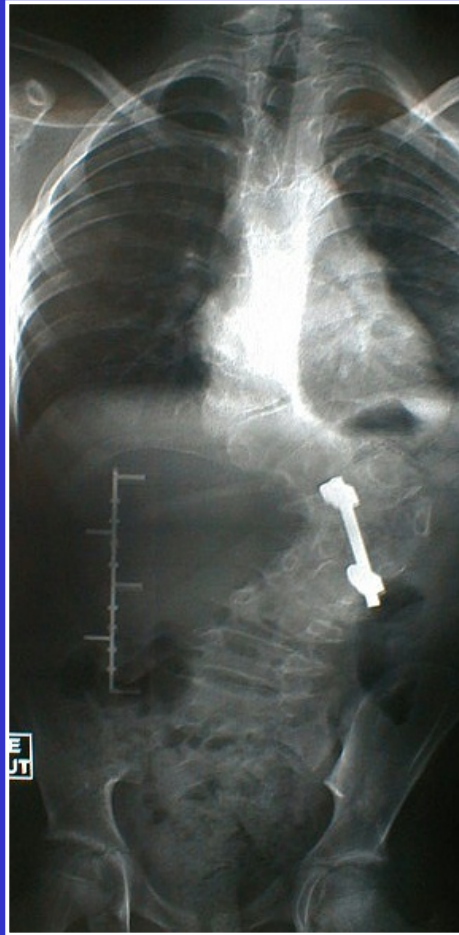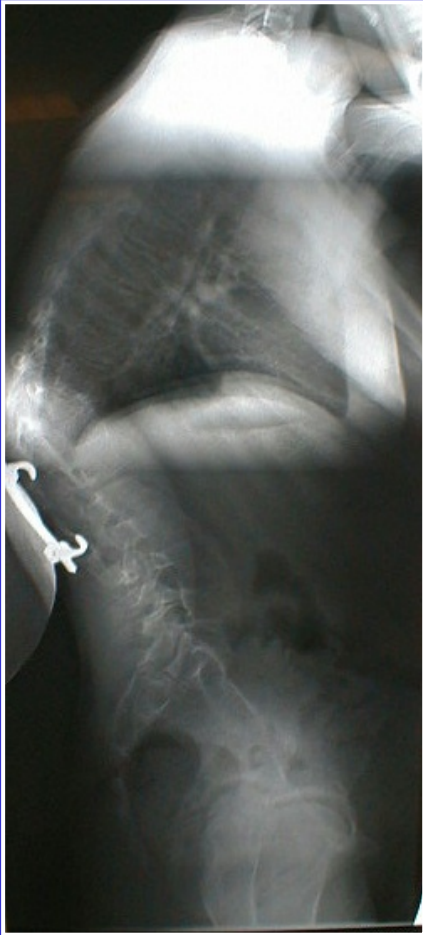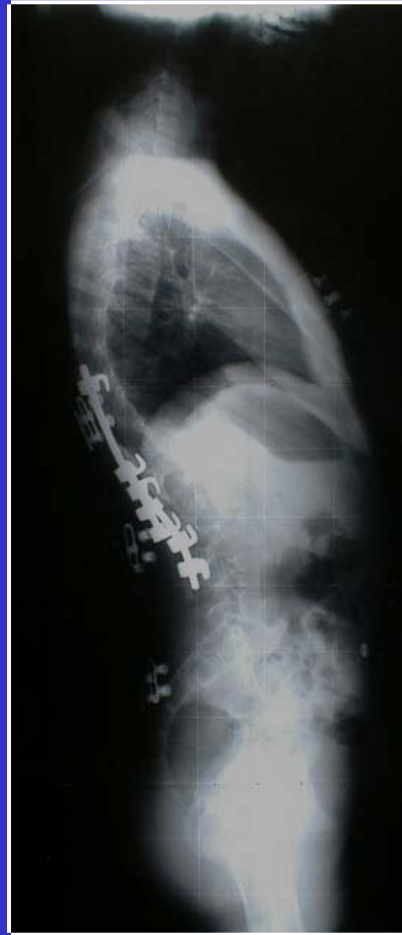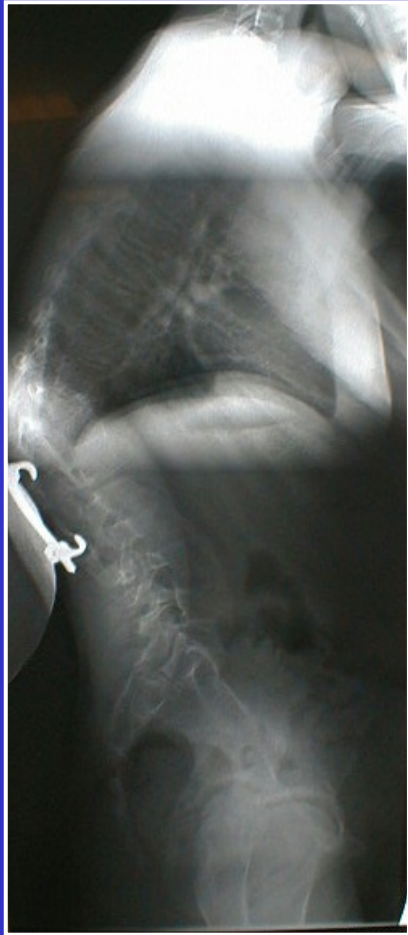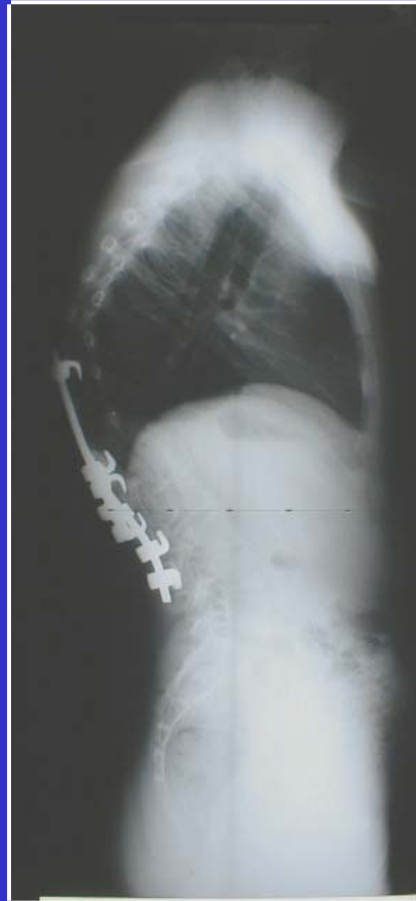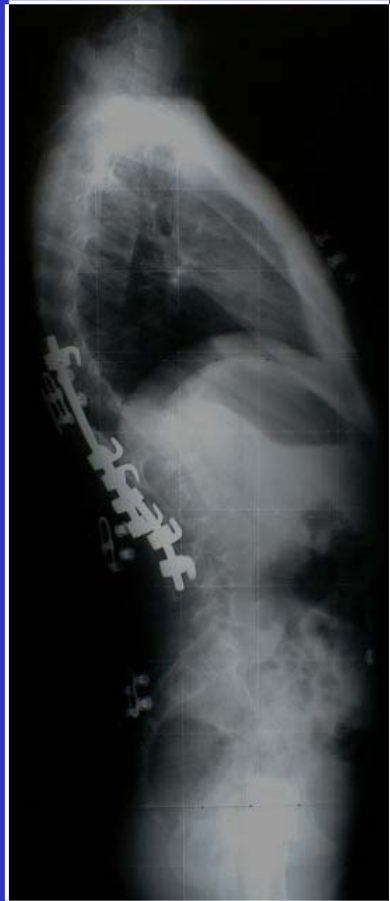








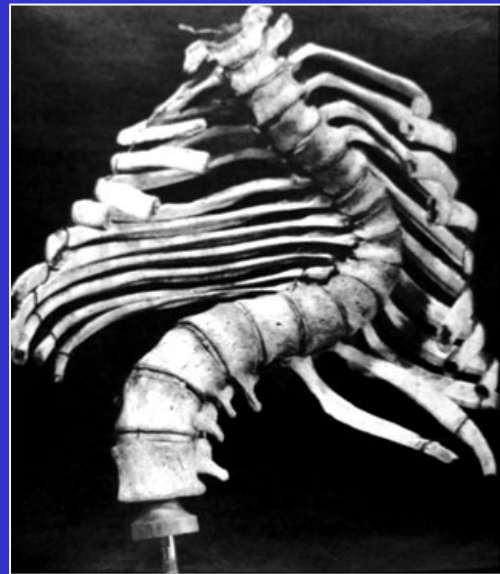
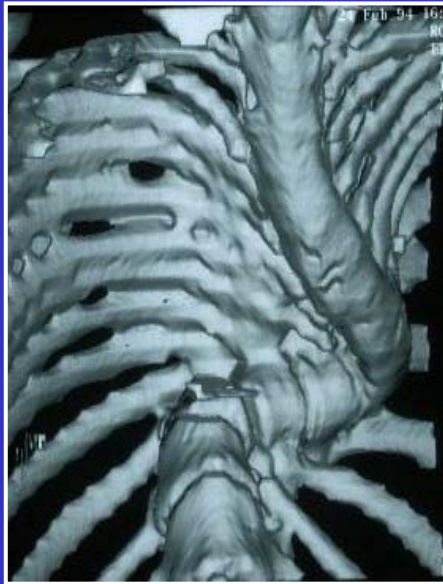




CLASSIFICATION DE WINTER

TYPE III

MALFORMATION COMPLEXE

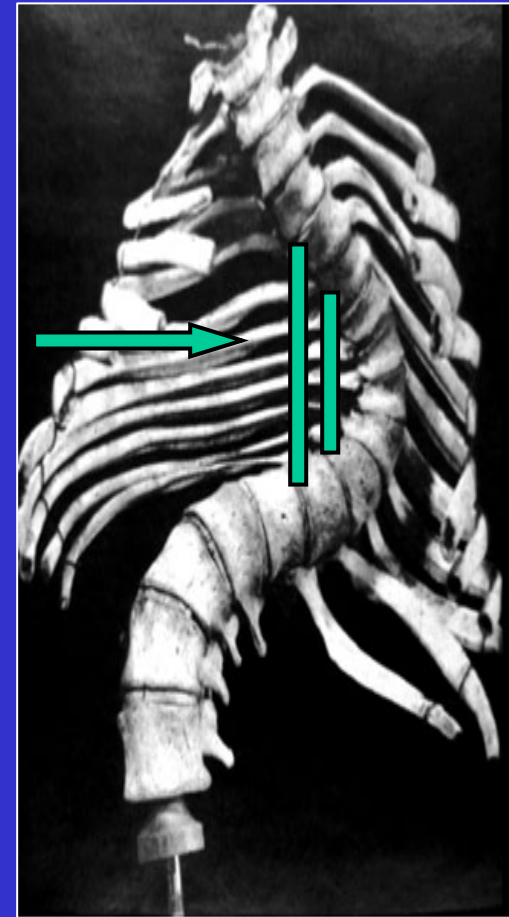
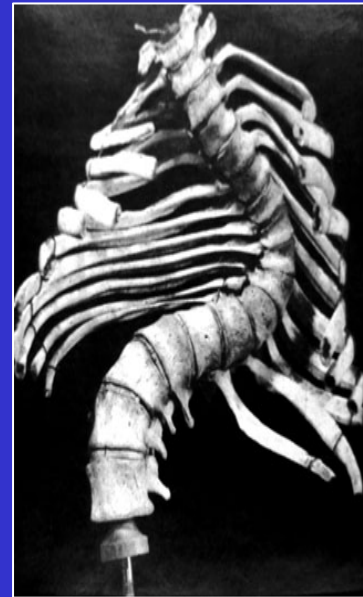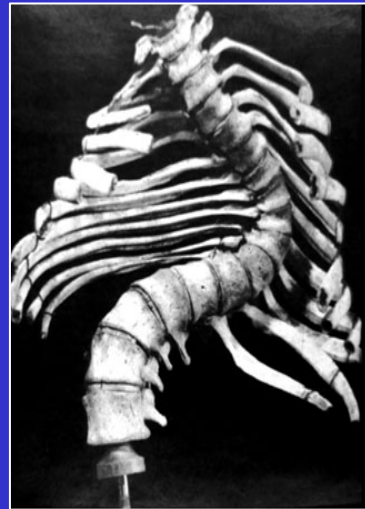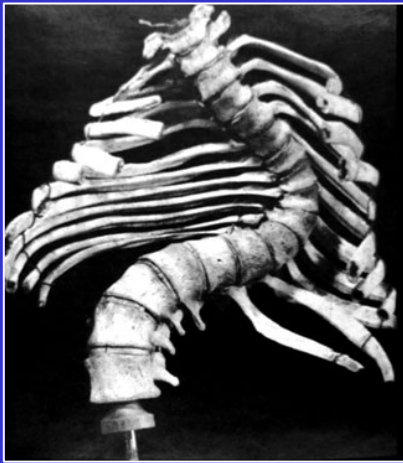


DISLOCATION ROTATOIRE

J. DUBOUSSET

1

TRACTION PAR HALO-FAUTEUIL OU HALO-VESTE SI APEX REDUCTIBLE

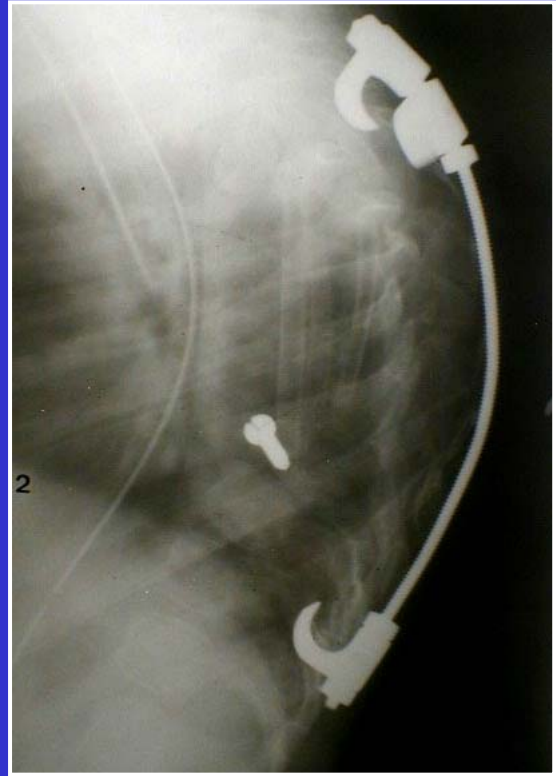
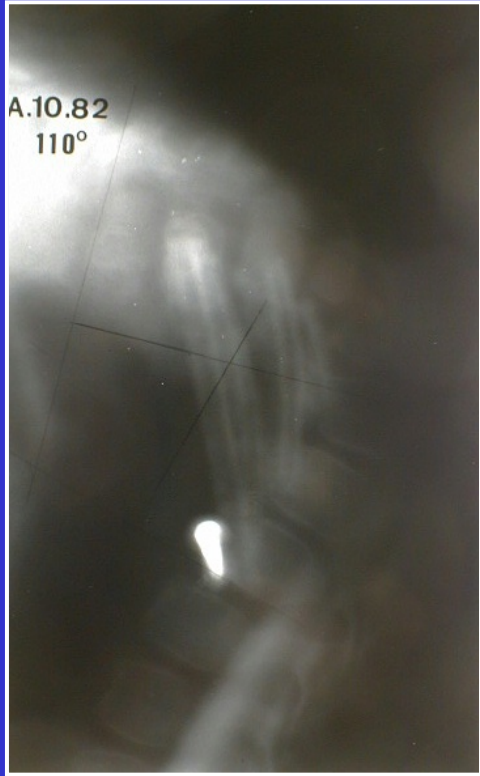
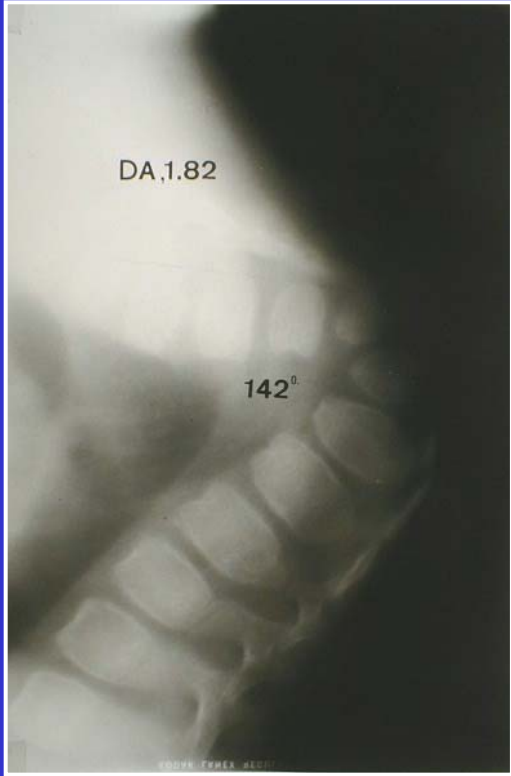
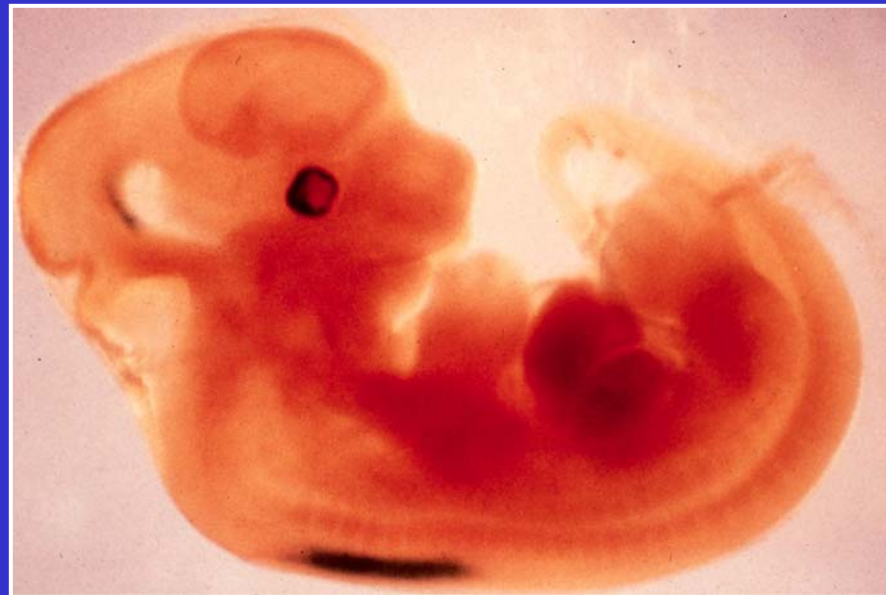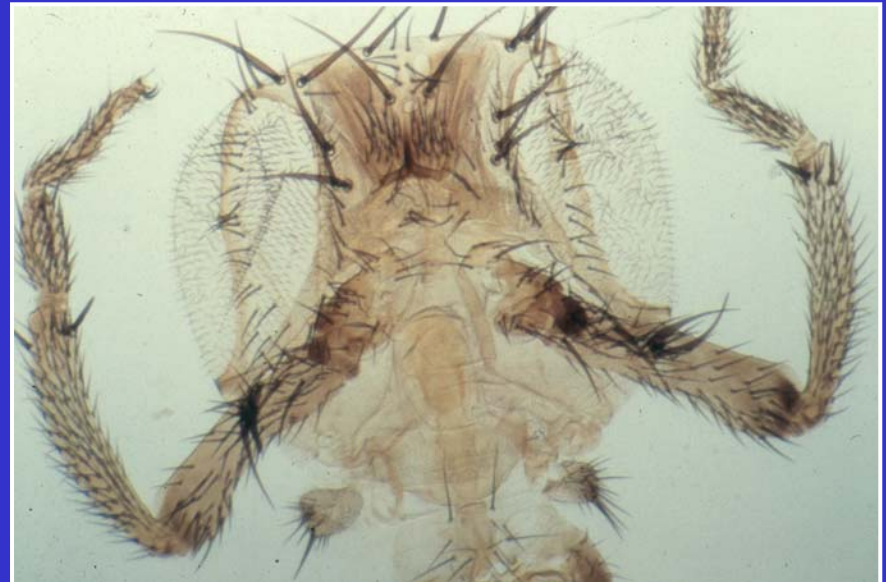3

PUIS GREFFE ET INSTRUMENTATION POSTERIEURE

2

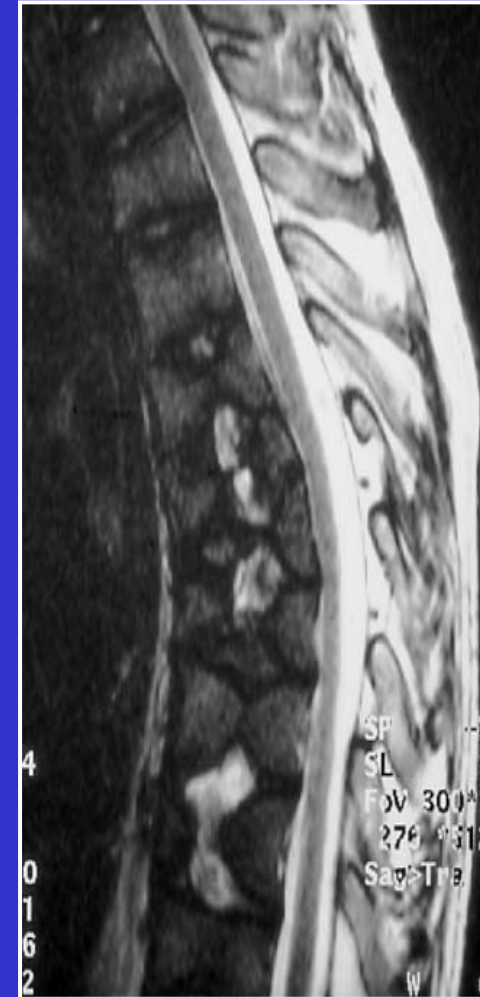
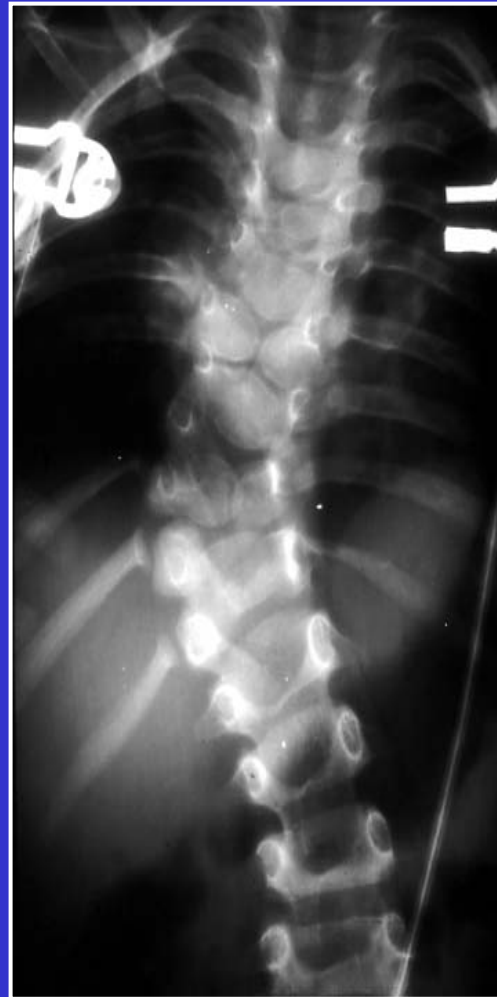PUIS GREFFE ANTERIEURE PAR LA CONCAVITE





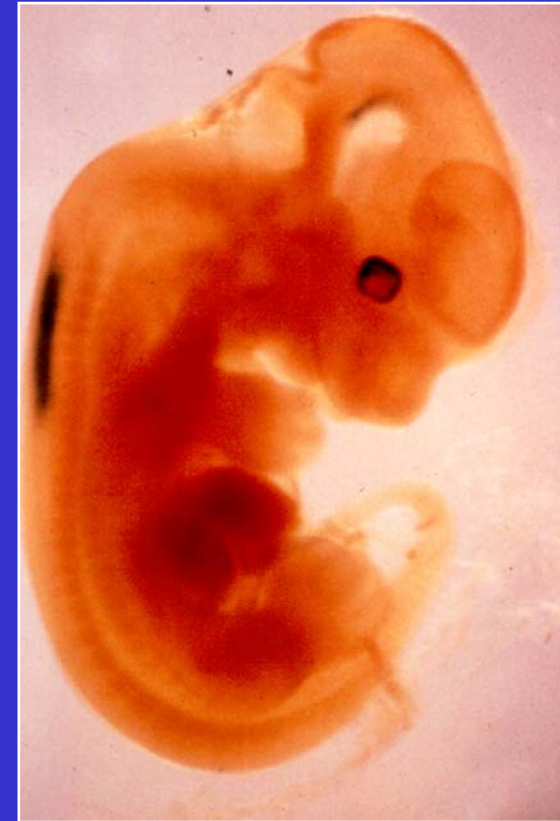DEFAUT DE FORMATION

L'organisation métamerique des corps vertébraux se fait autour de la notochorde qui normalement disparaît à la fin de la période fœtale ne laissant comme stigmate que le nucléus pulposus



Recent evidence from work performed in fish, chick and mouse embryos indicates that **segmentation of the embryonic body relies on a molecular oscillator called the segmentation clock**, which requires Notch signaling for its proper functioning.

In humans, mutations in genes required for oscillation, such as Delta-like 3 (DLL3), result in abnormal segmentation of the vertebral column, as found in spondylocostal dysostosis syndrome, suggesting that the segmentation clock also acts during human embryonic development.



Pourquie, O 1; Kusumi, K 2

**Clinical Genetics. 60(6):409-416,
December 2001.**

Merçi

