

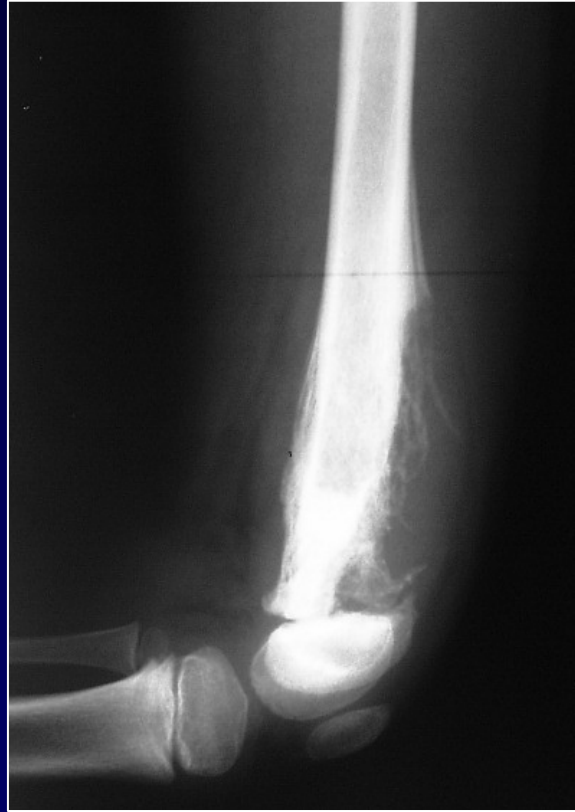

Collège Hospitalier et Universitaire
de Chirurgie Pédiatrique

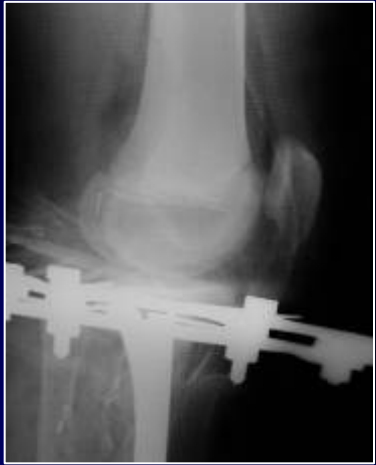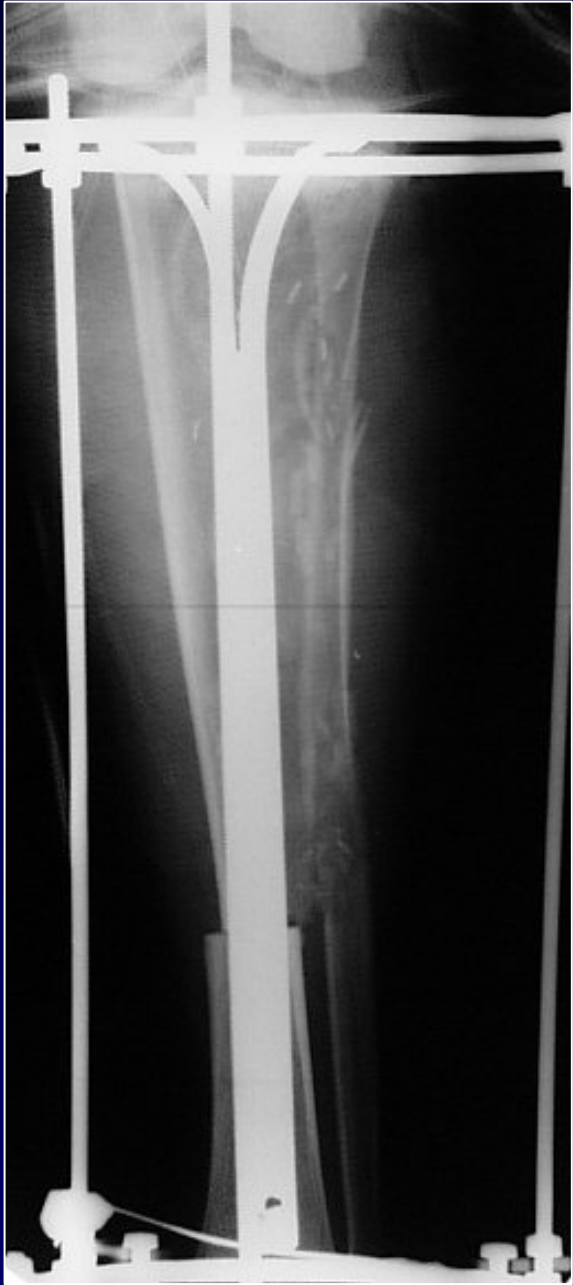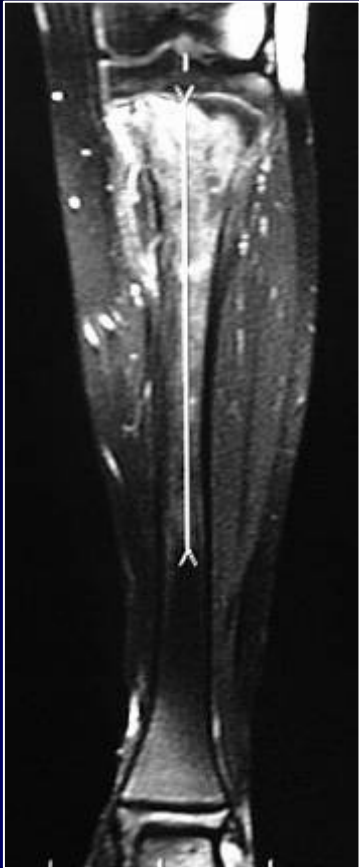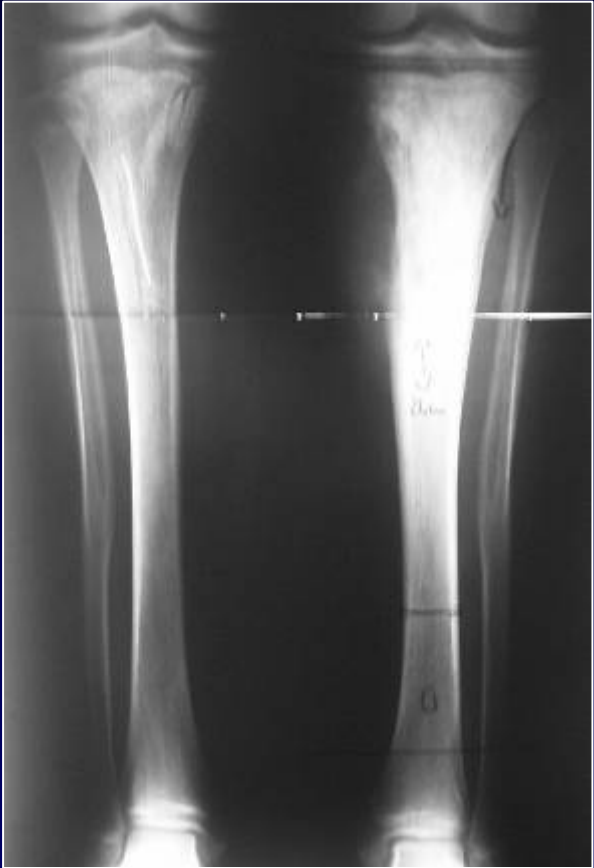DESC de Chirurgie Pédiatrique
Session de Mars 2008 - PARIS

Méthodes de reconstruction osseuses dans les tumeurs malignes de l'enfant

Ch. GLORION



Ewing, 13 ans



Chirurgie : objectifs

- Exérèse large
- Evaluation chimio.
- Reconstruction

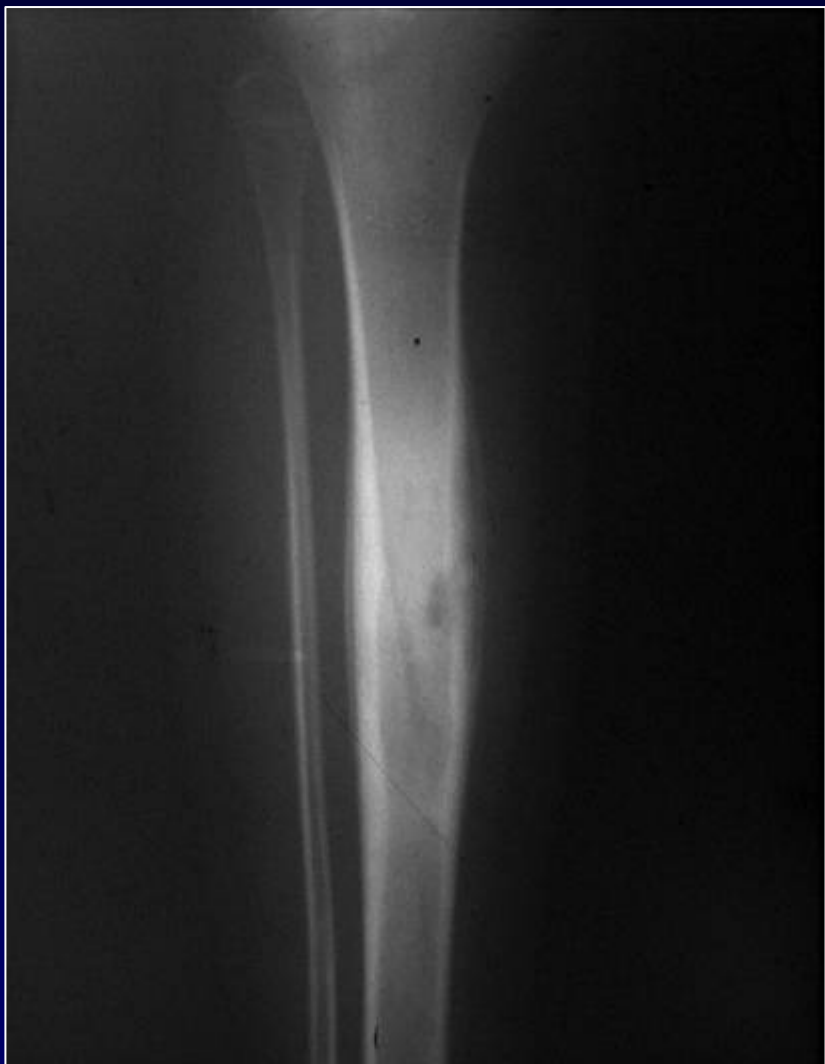Reconstruction

- **Diaphysaire**
- **Articulaire**

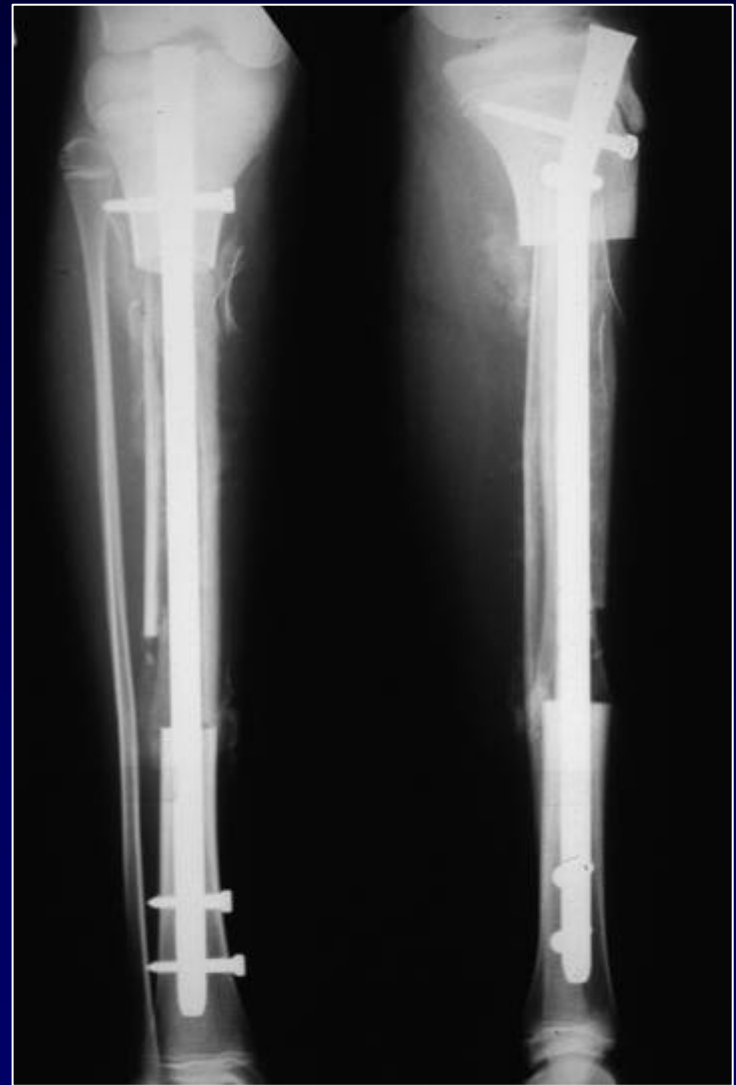Reconstruction diaphysaire

- **Ostéosynthèse : clou, plaques**
- **Greffes corticales et spongieuses**
- **Greffes vascularisées**
- **Membrane induite**
- **Allogreffes**

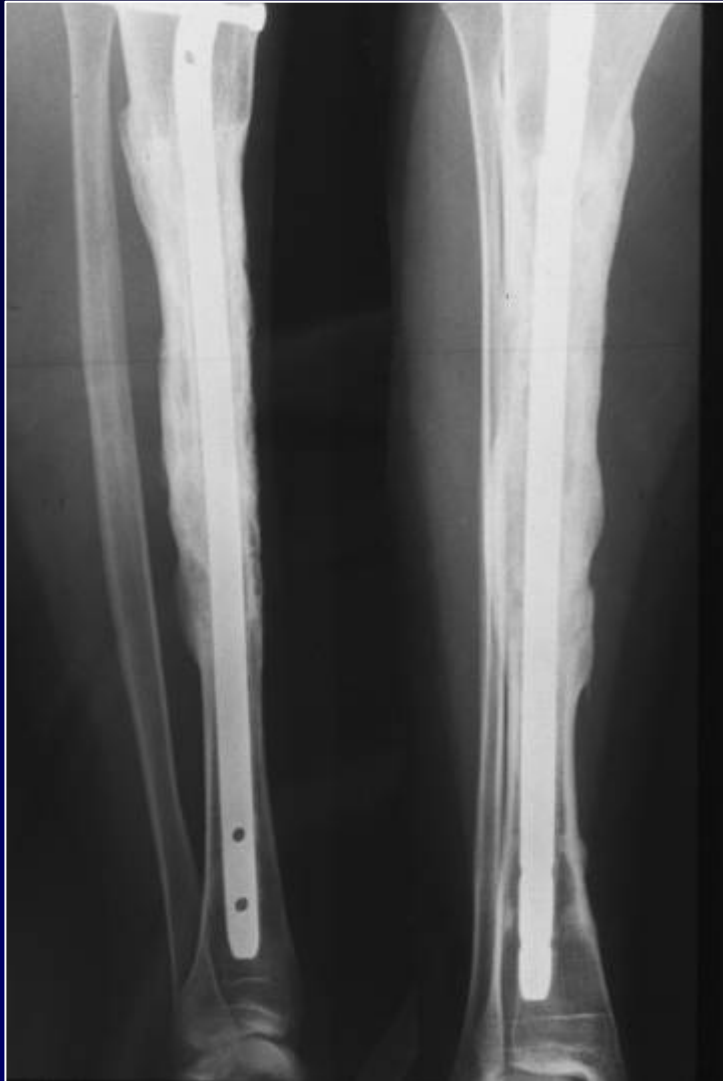S. d 'Ewing, 14 ans



**Greffe corticale
et spongieuse**

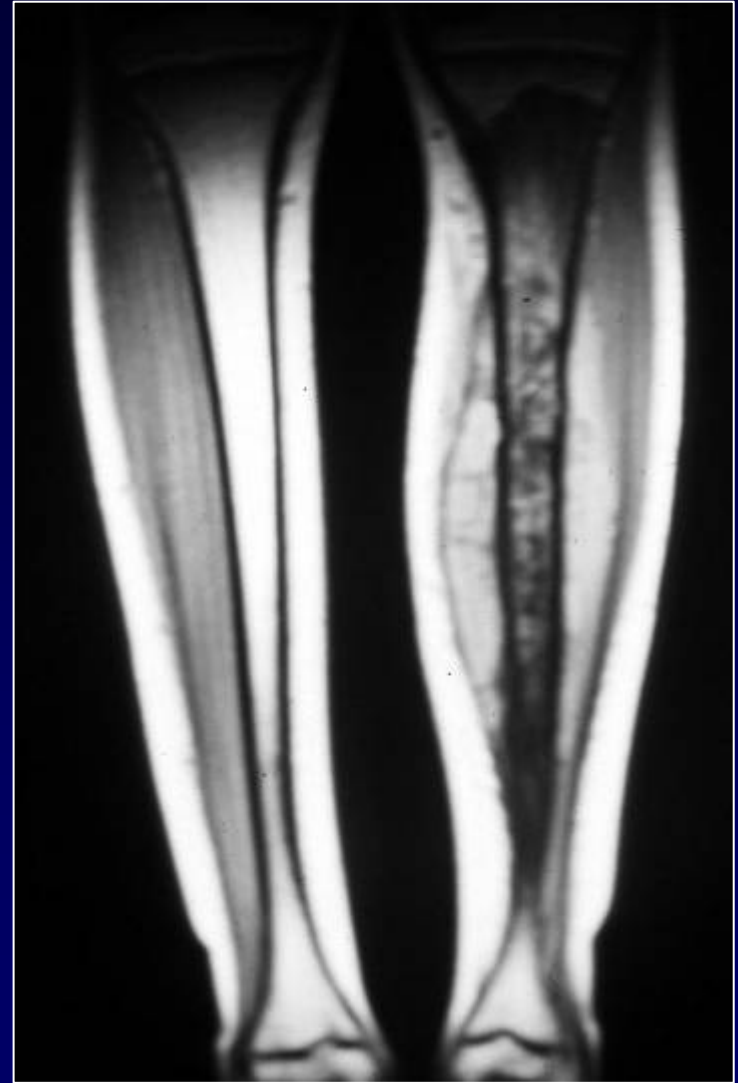
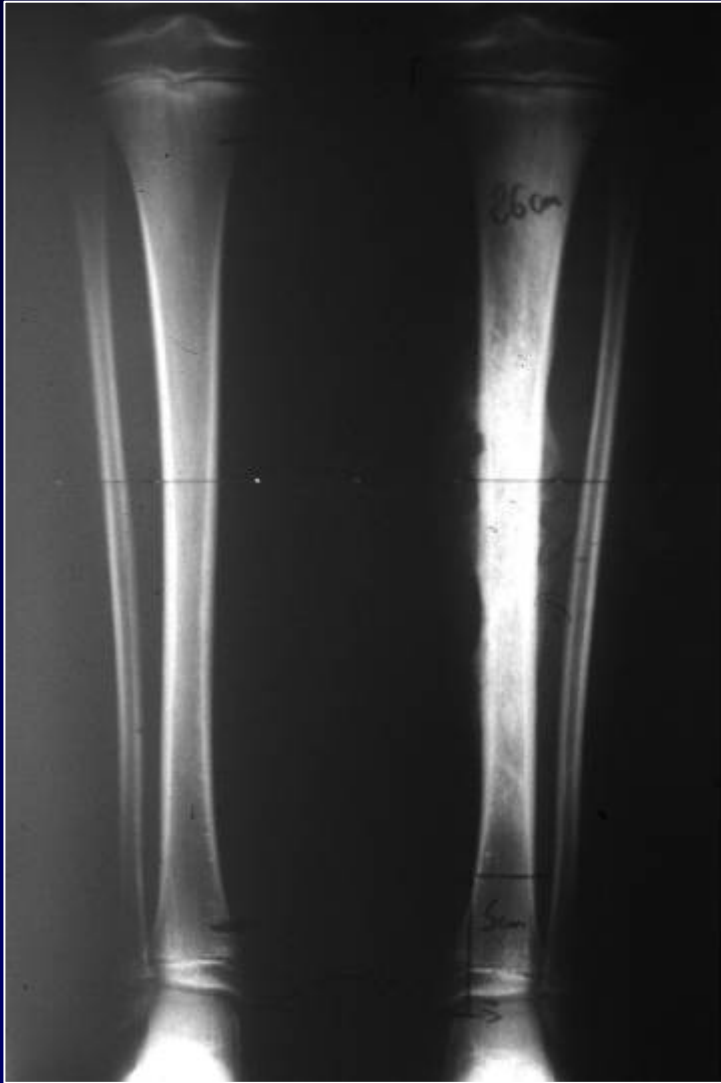
Recul = 13 ans

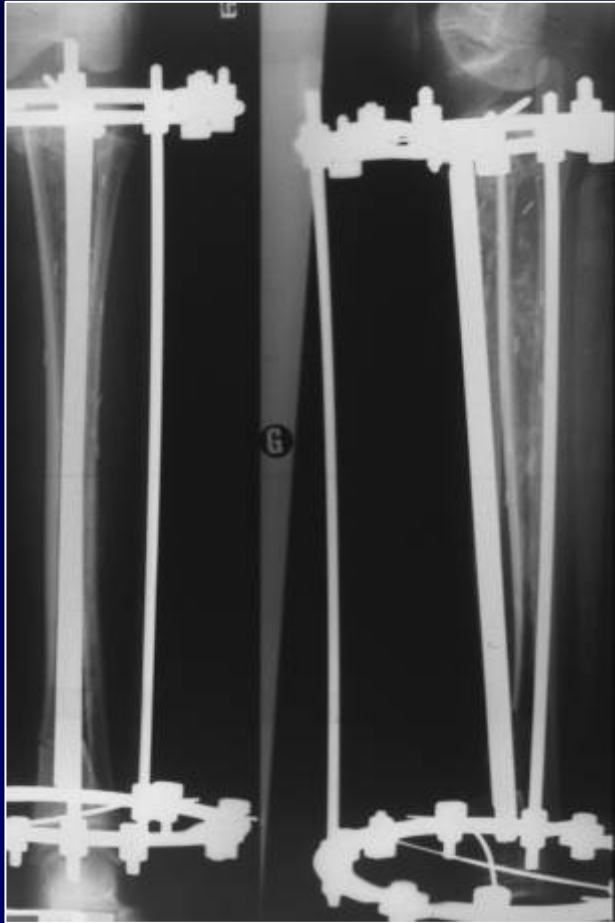


Ostéosarcome du tibia

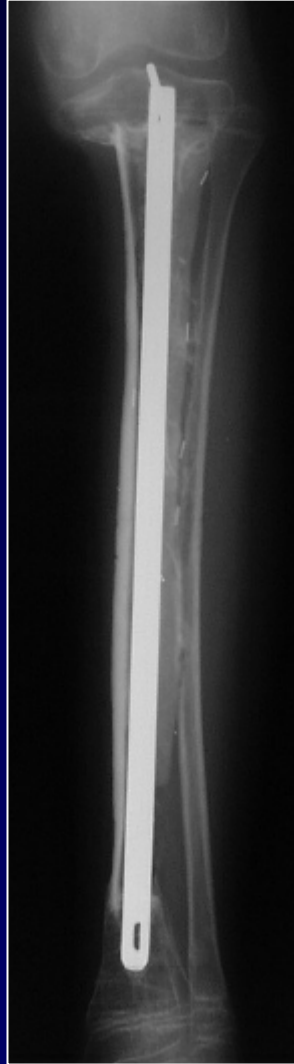
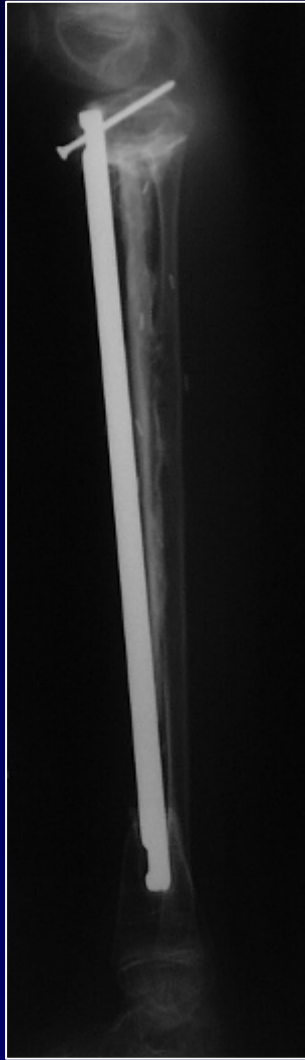
Garçon, 10 ans



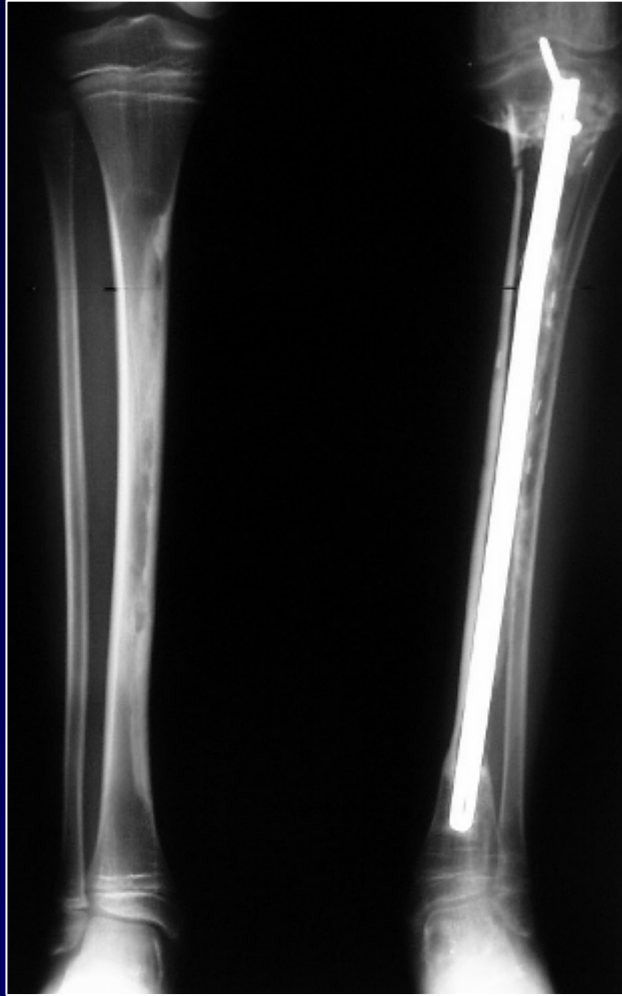
- Résection
- Clou + fixateur
- Greffe corticale et spongieuse

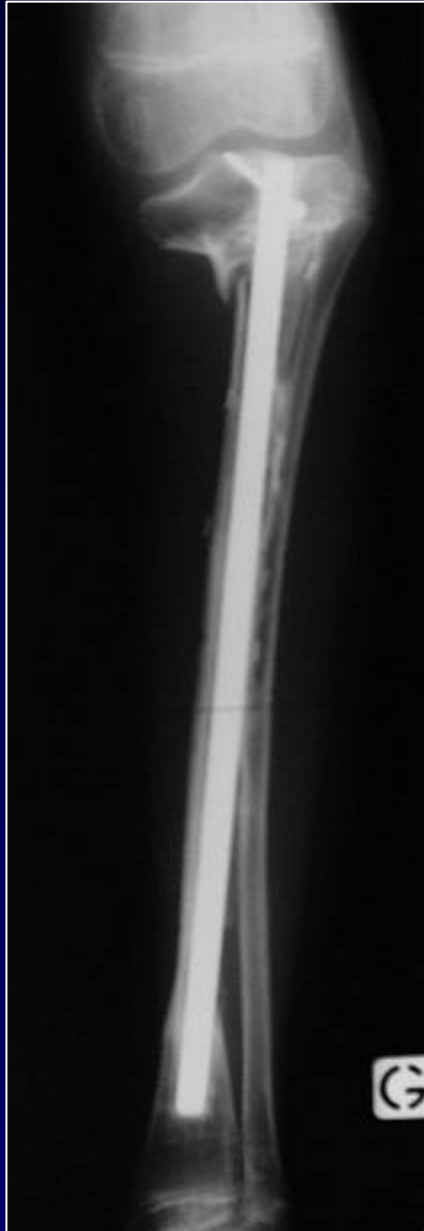

Recul = 1 an



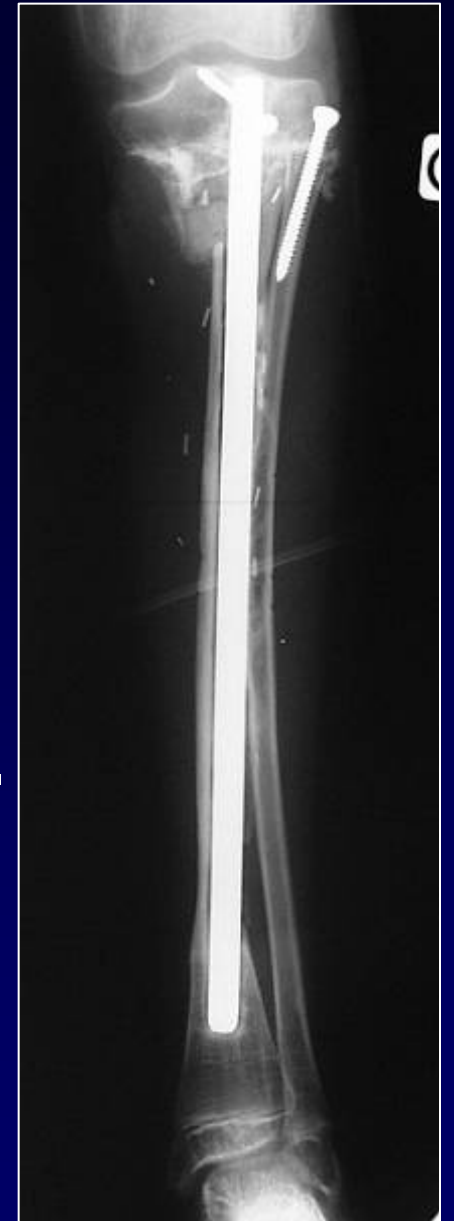Recul = 18 mois



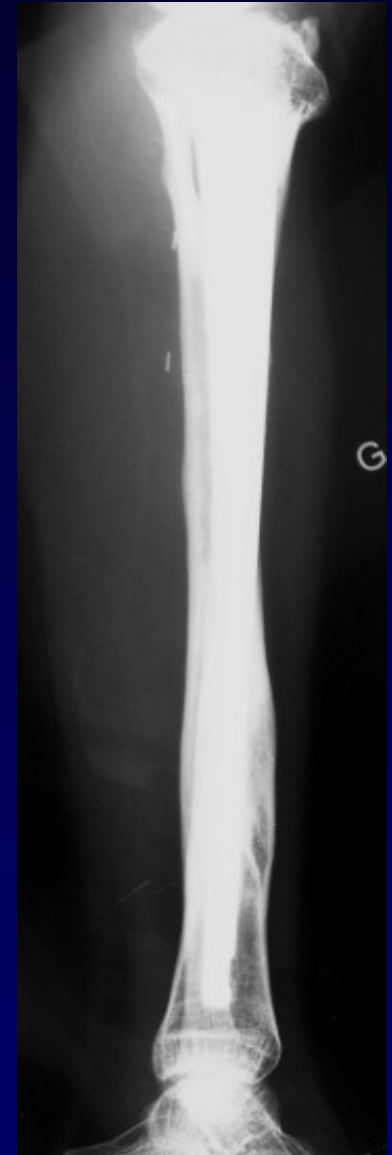
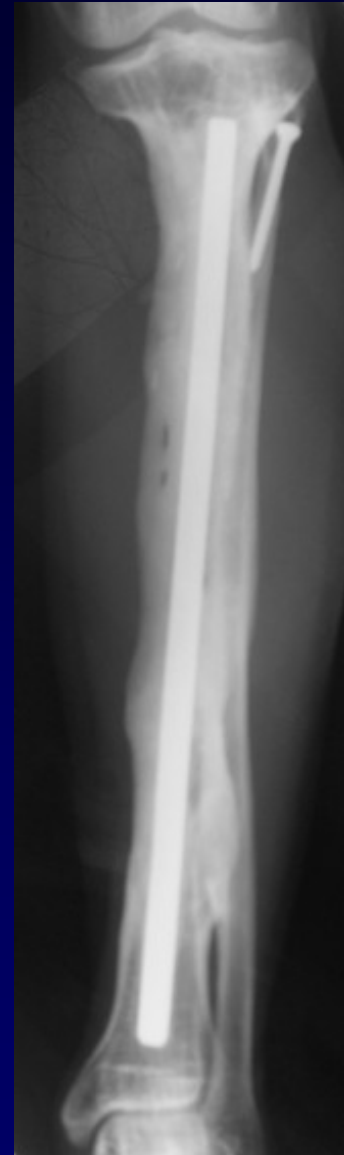
3 interventions

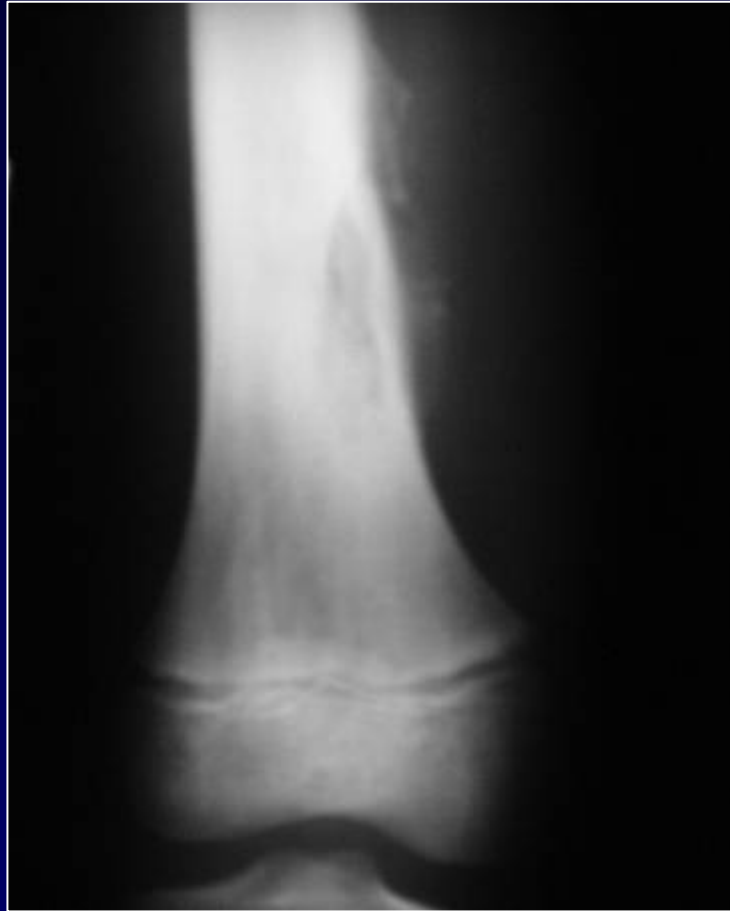- épiphysiodèse controlat.**
- Réaxation, greffe**



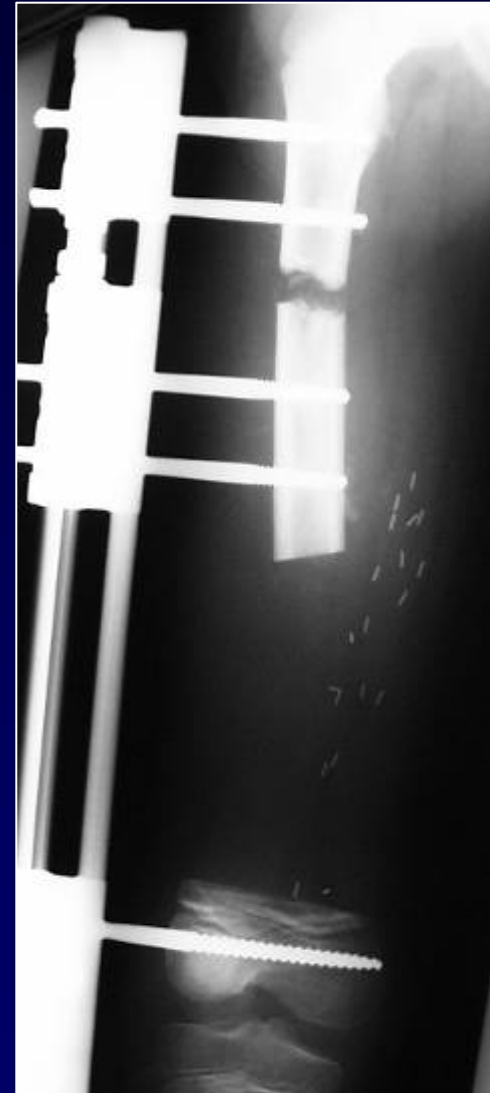
J + 11 ans



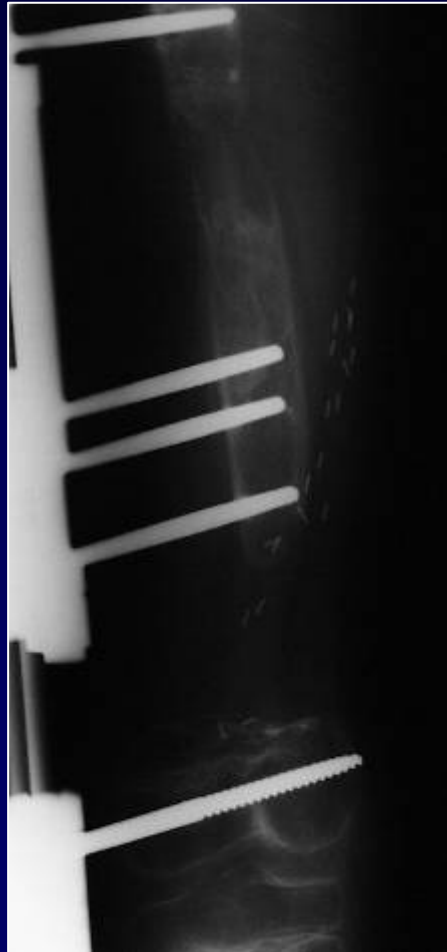
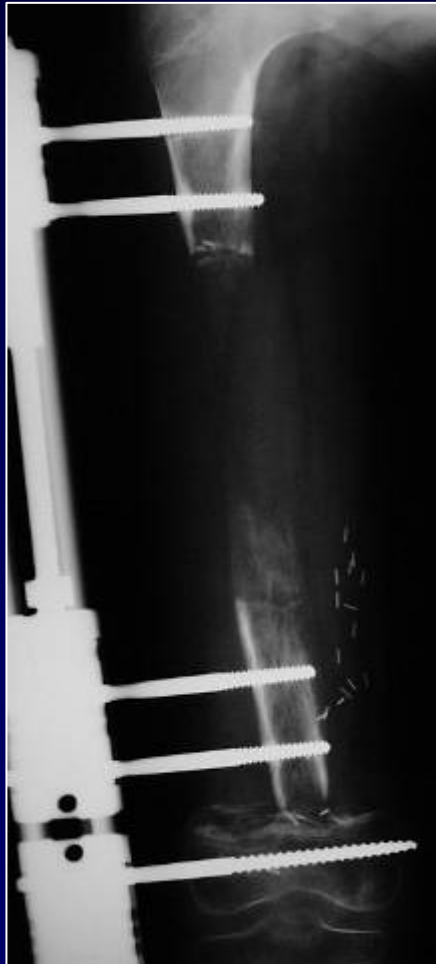**Garçon, 10 ans
Ostéosarcome**



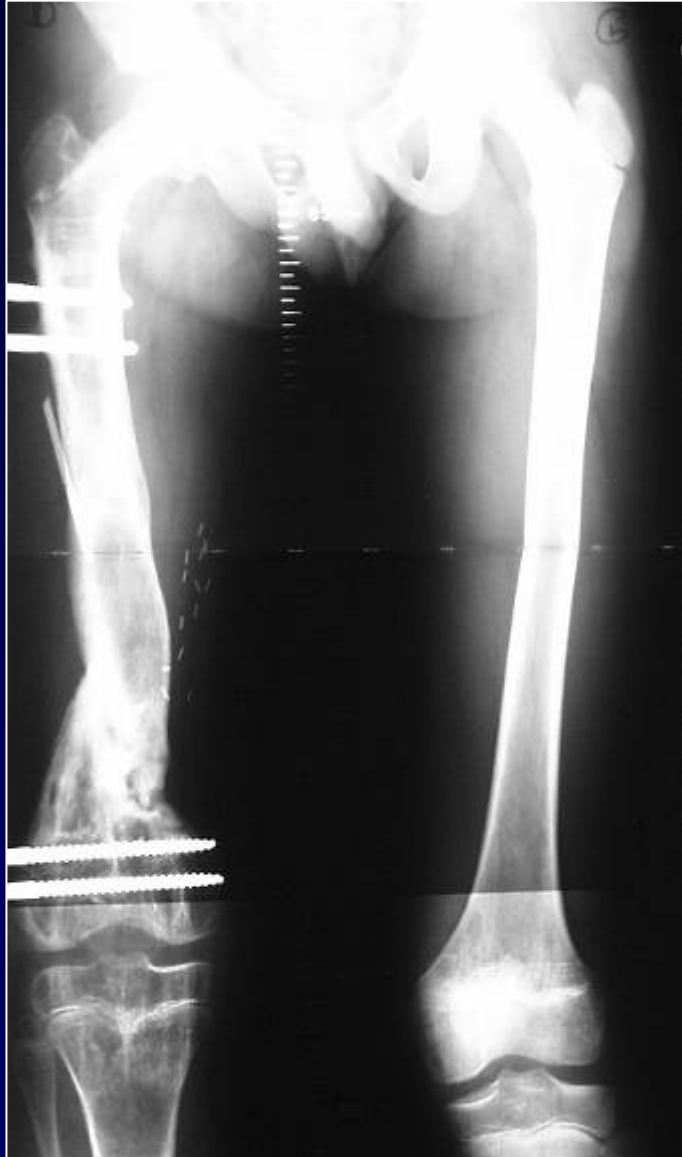Résection, Transfert



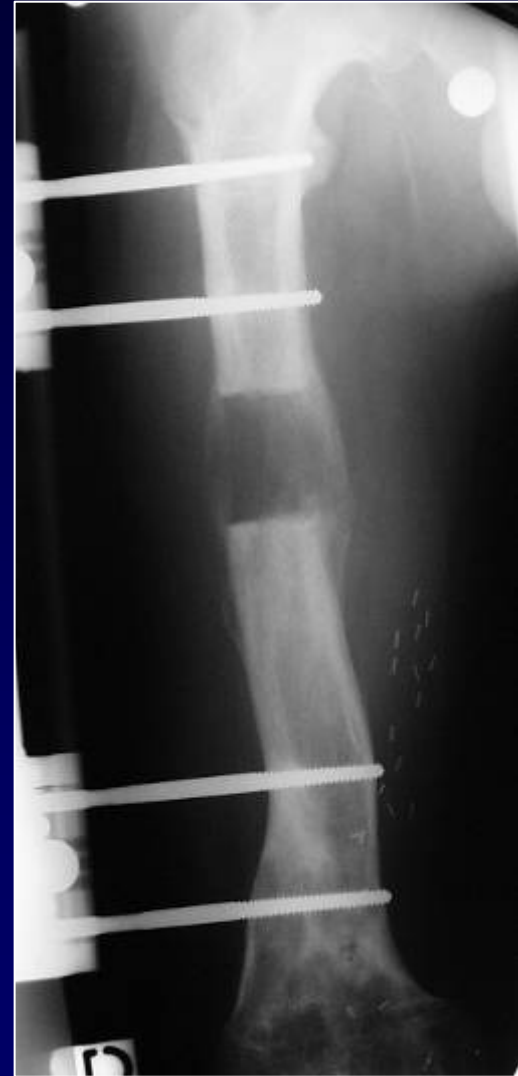- Transfert osseux (Pendant la chimio !!!)
- Greffe spongieuse X 2

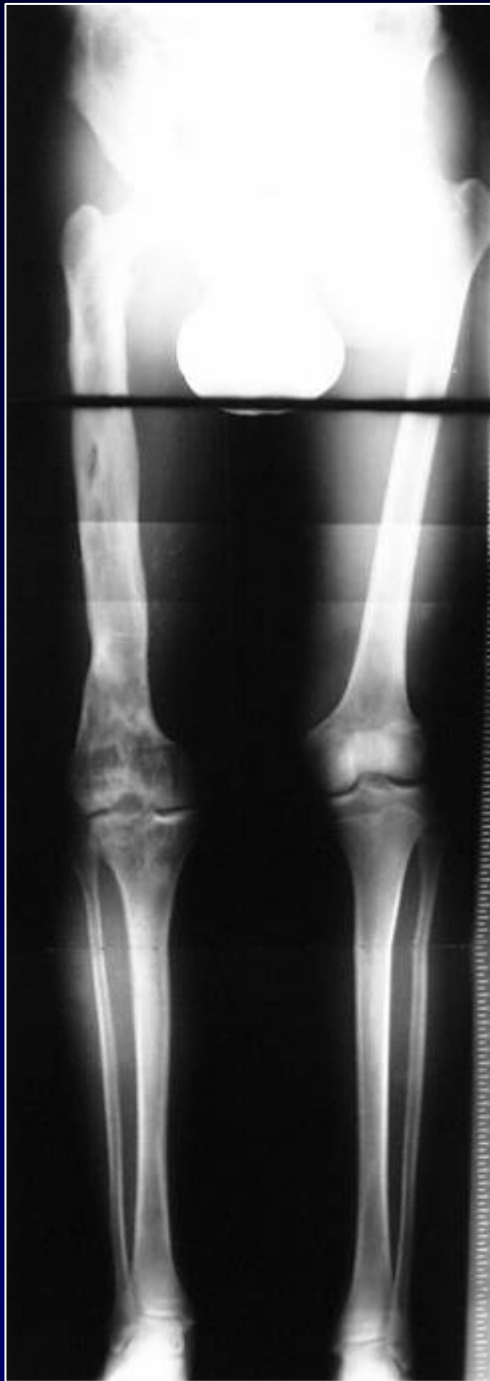

+ Une fracture



**Allongement fémoral
= 9 cm**



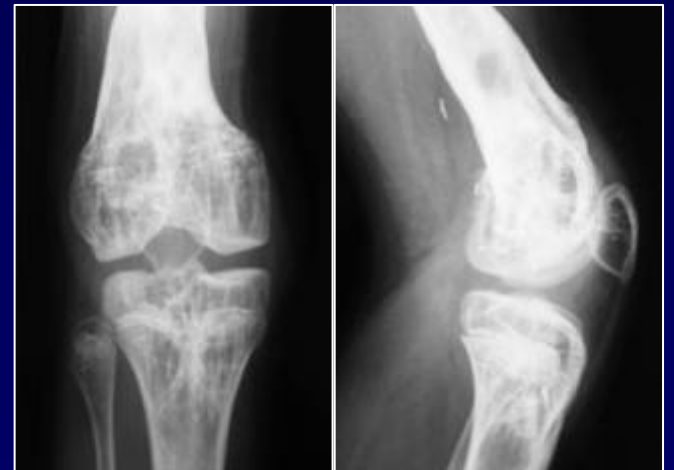


Recul = 14 ans

- 4 cm

- Genou 0/45

- Quadriceps -

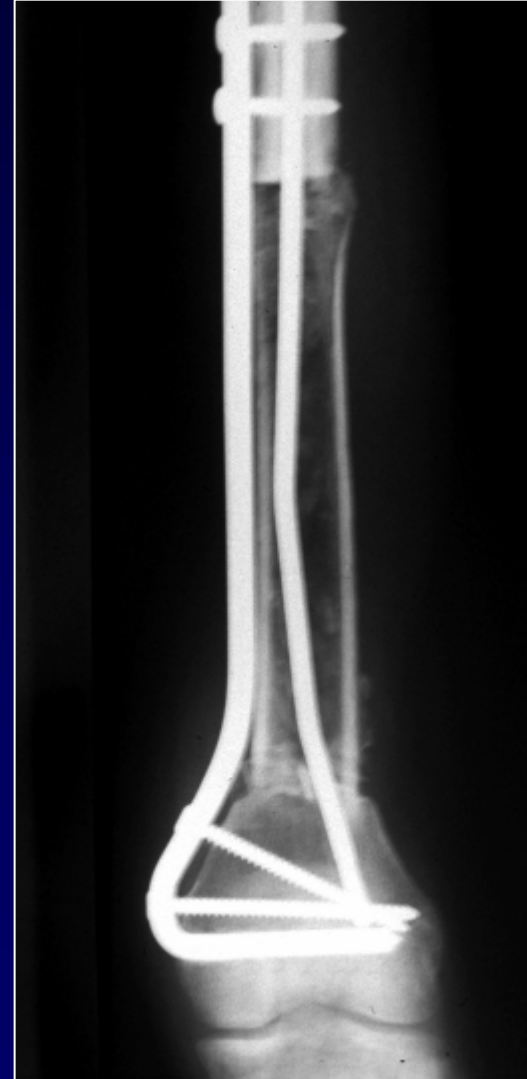
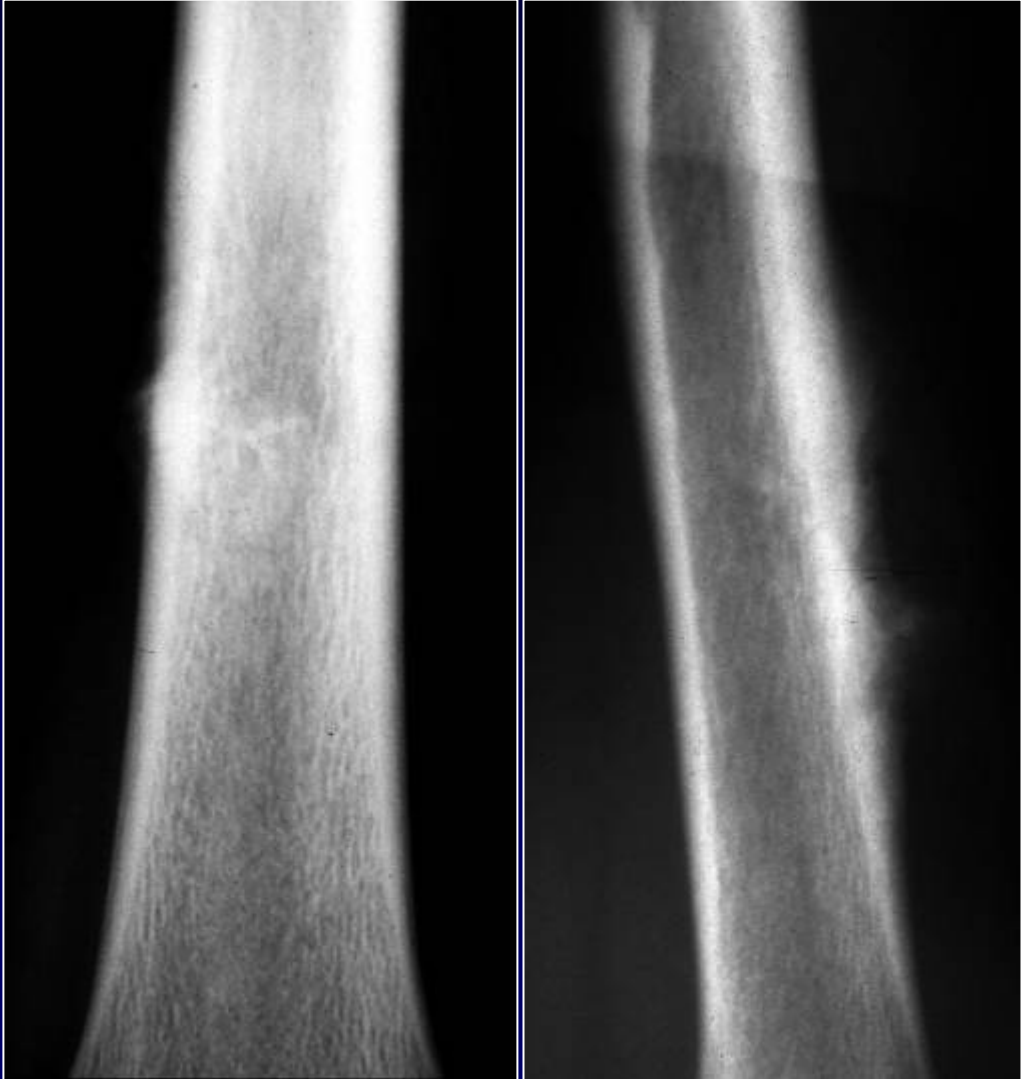
Fille, 14 ans

Sarcome radio-induit

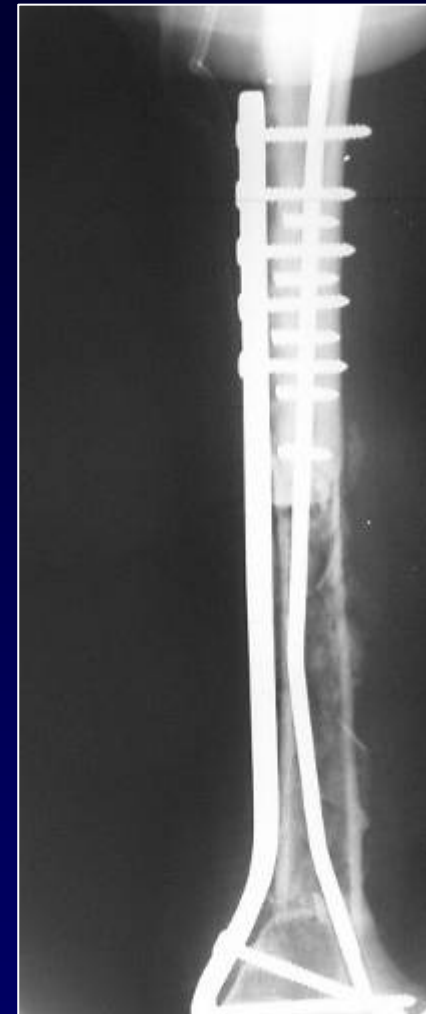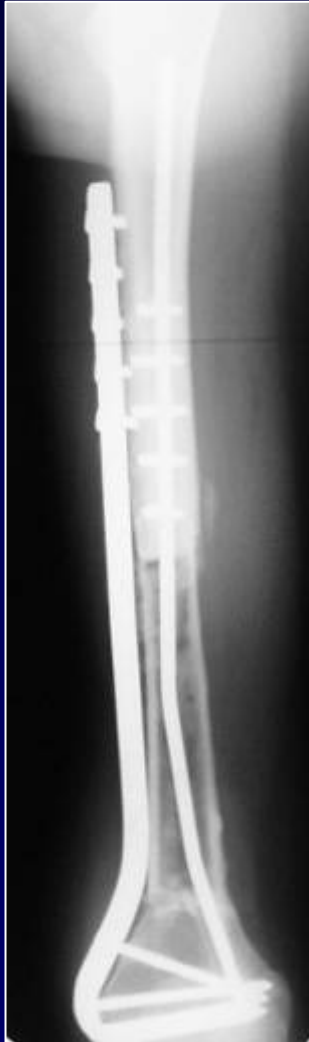J + 10 ans Rhabdomyosarcome

- Résection
- Lame-plaque + clou
- Greffe corticale et spongieuse



Recul = 1 an

**Fracture des vis
= retard de consolidation**

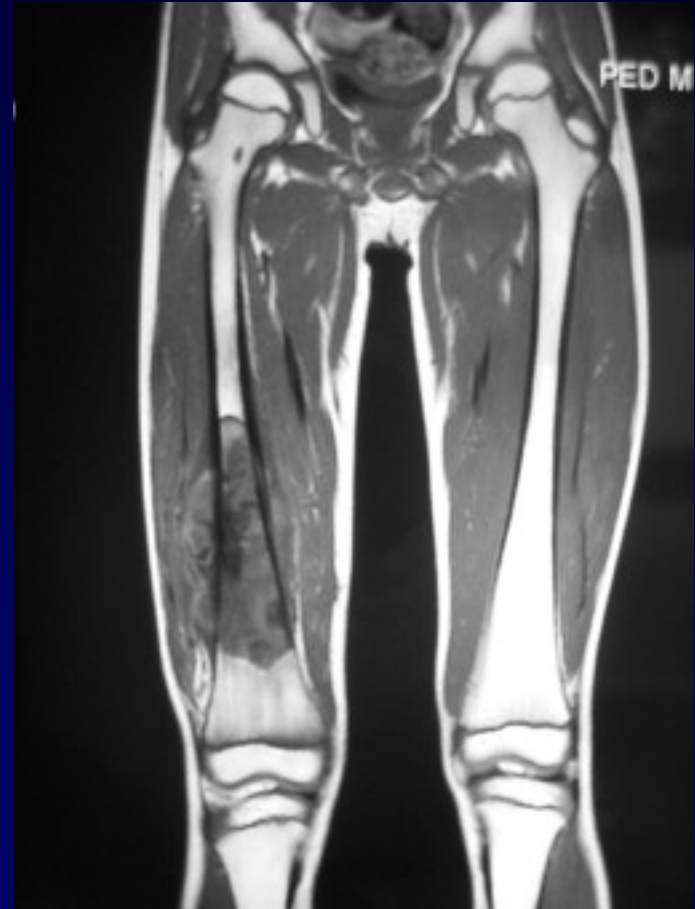
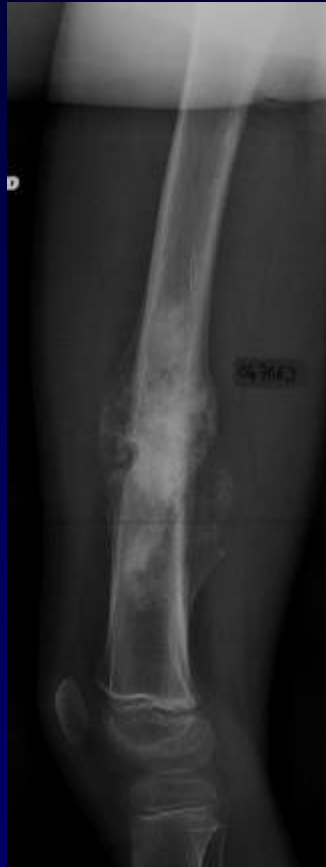
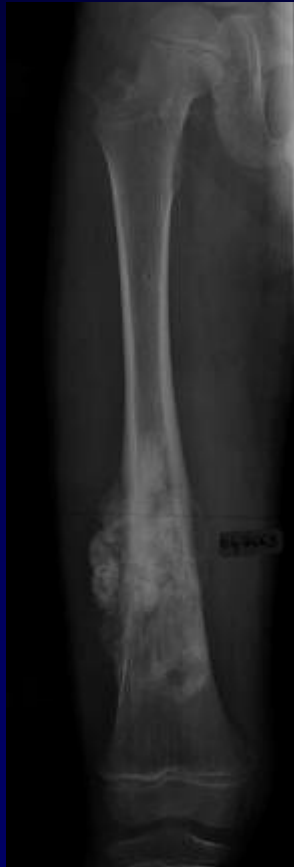Recul = 2 ans

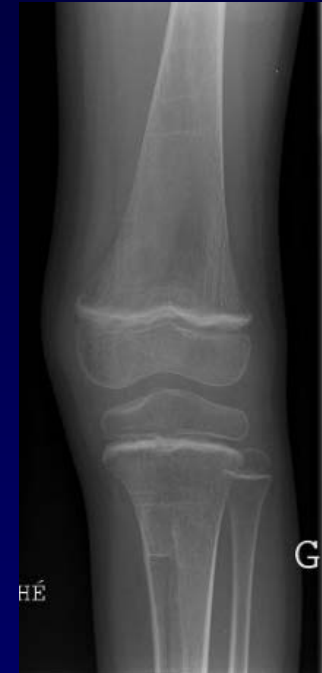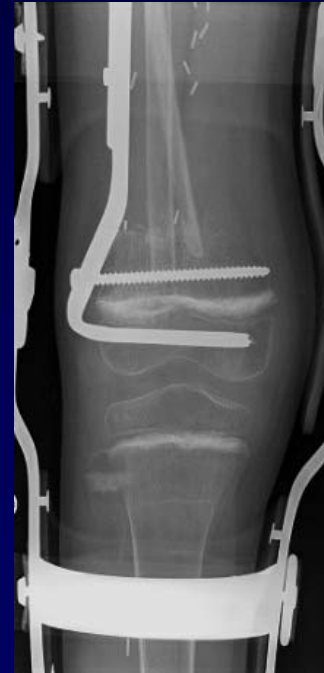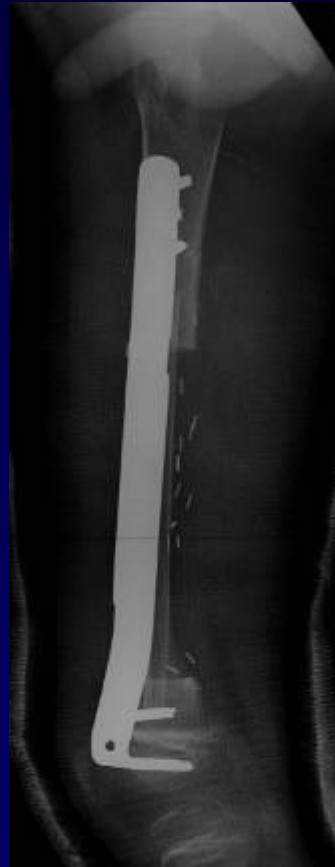
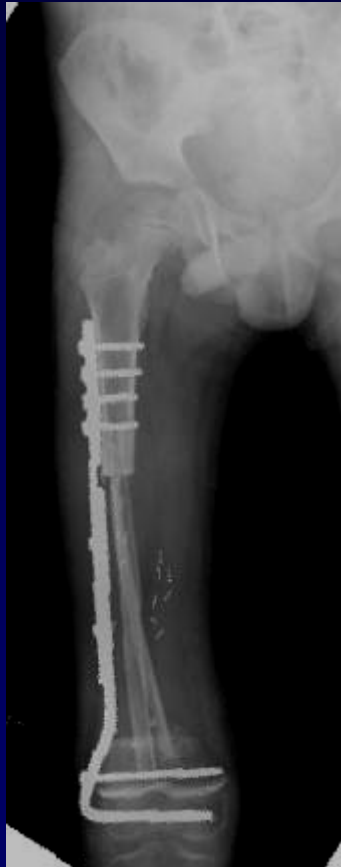Solide

Greffe Vascularisée

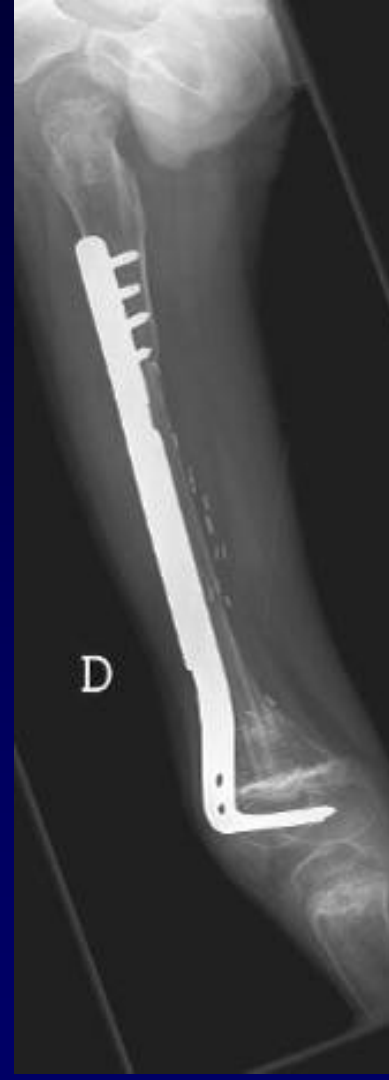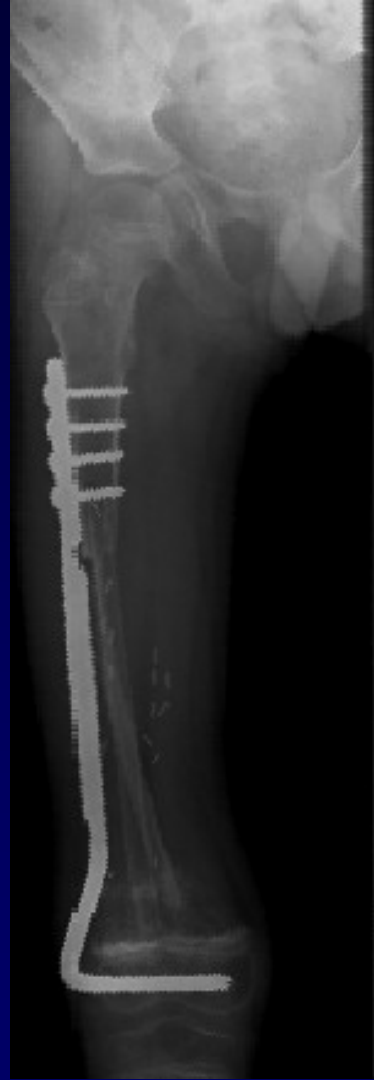Ostéosarcome, 6 ans



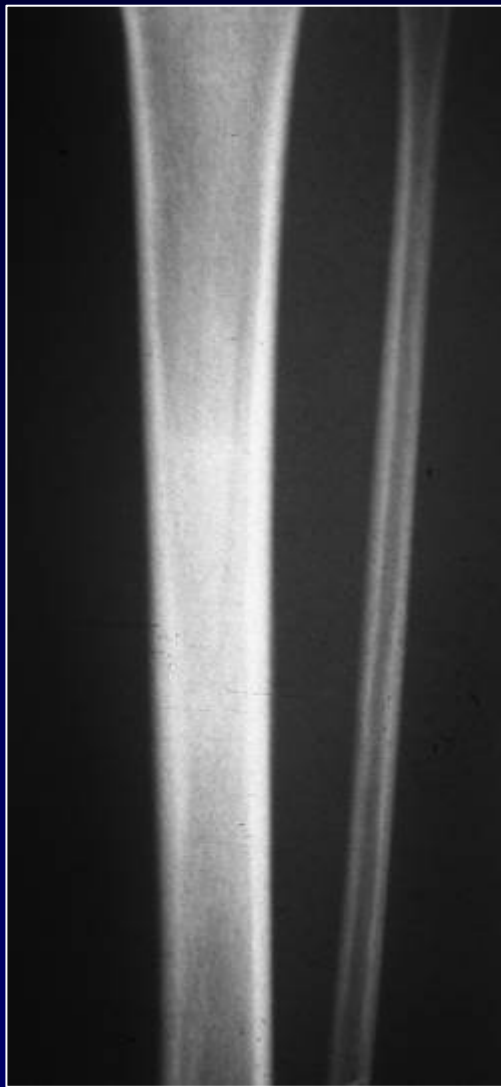
Plaque + Péroné vascularisé + Tibia



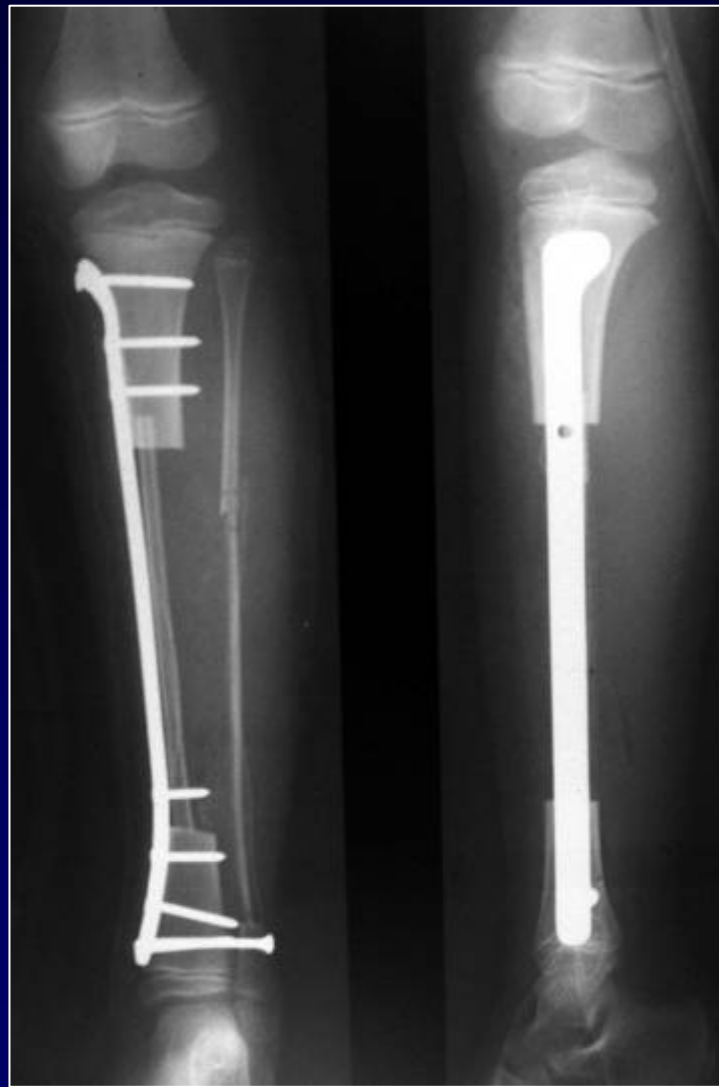J + 6 mois




Ostéosarcome 8 ans

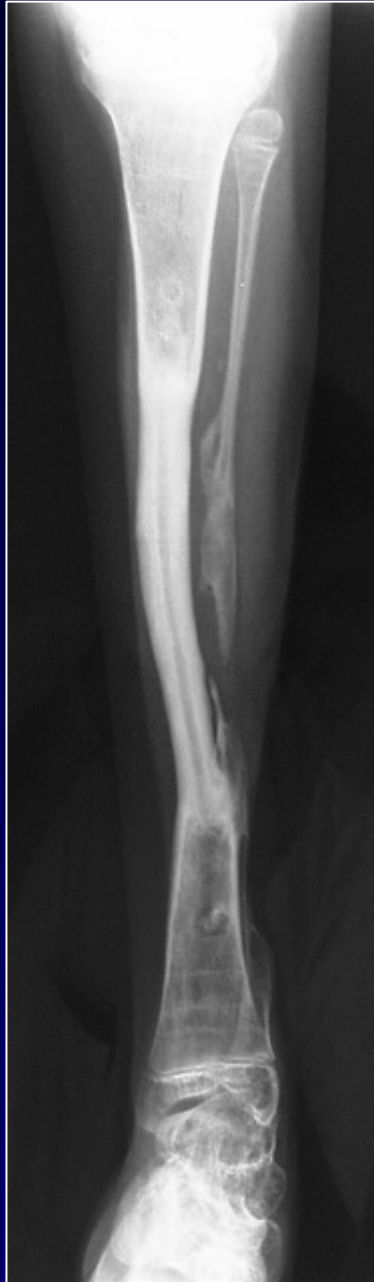

Péroné Vascularisée homolatérale



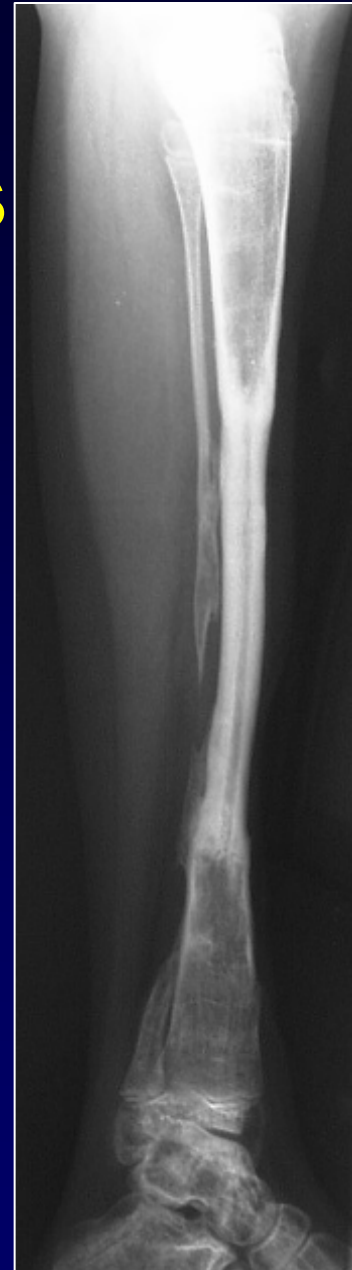Syndrôme de loge





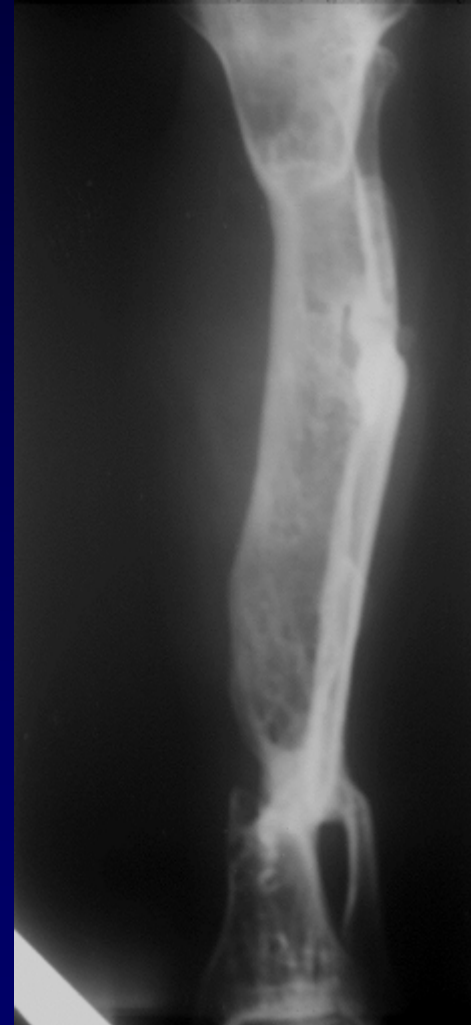
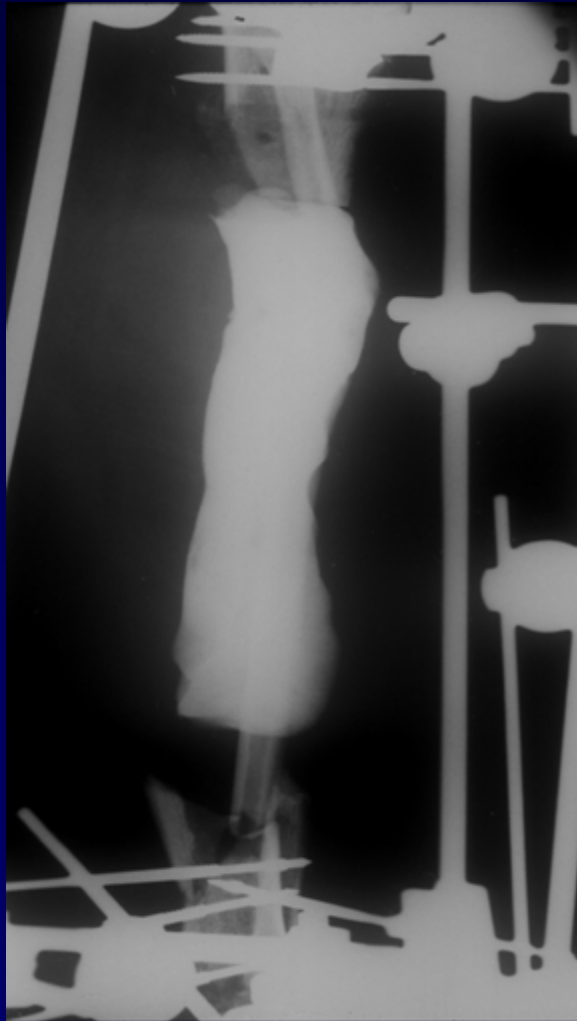
Recul = 10 ans

- **Protection**
- **Mauvais pied**



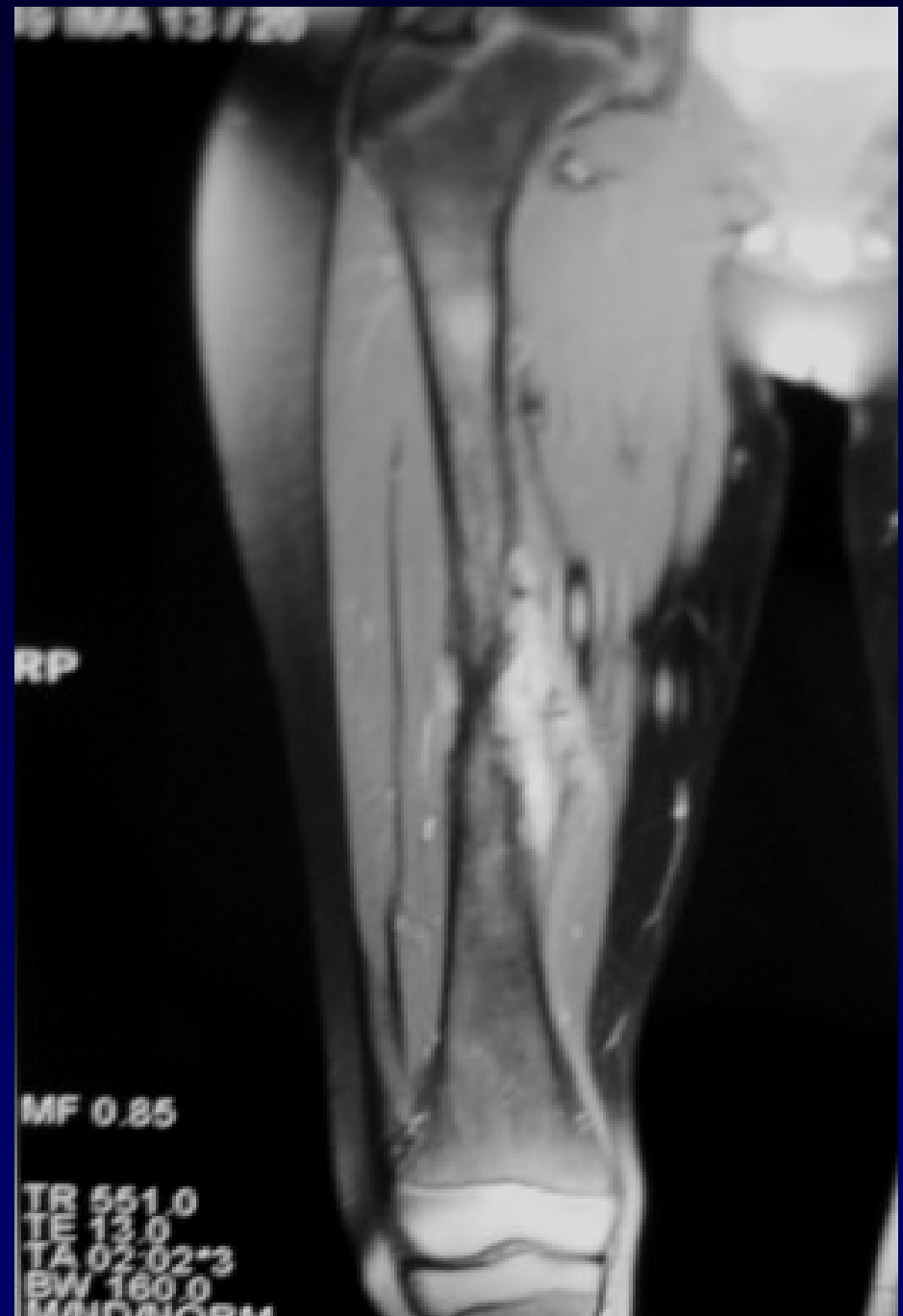
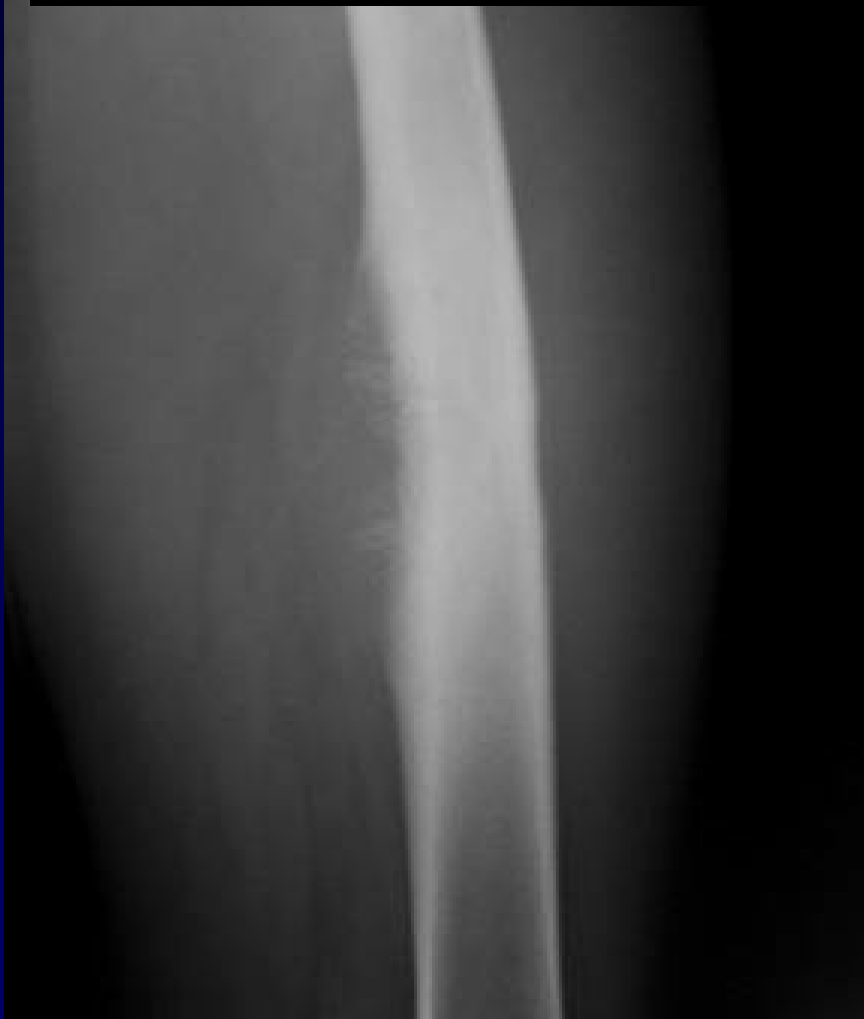Membrane induite

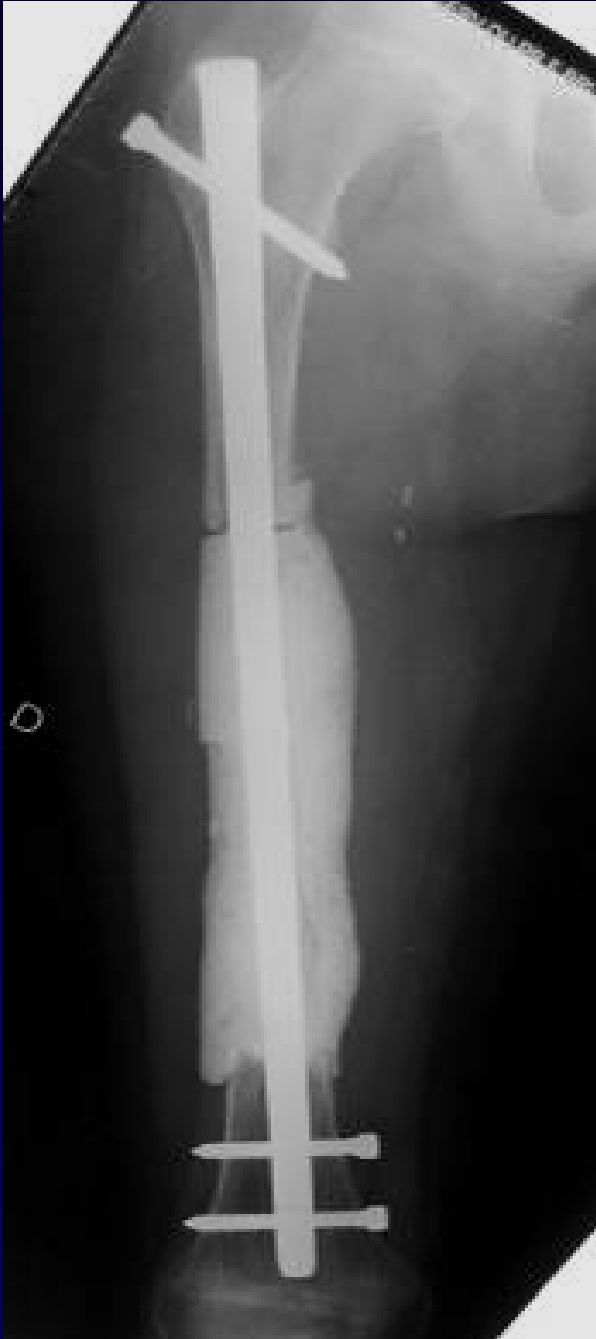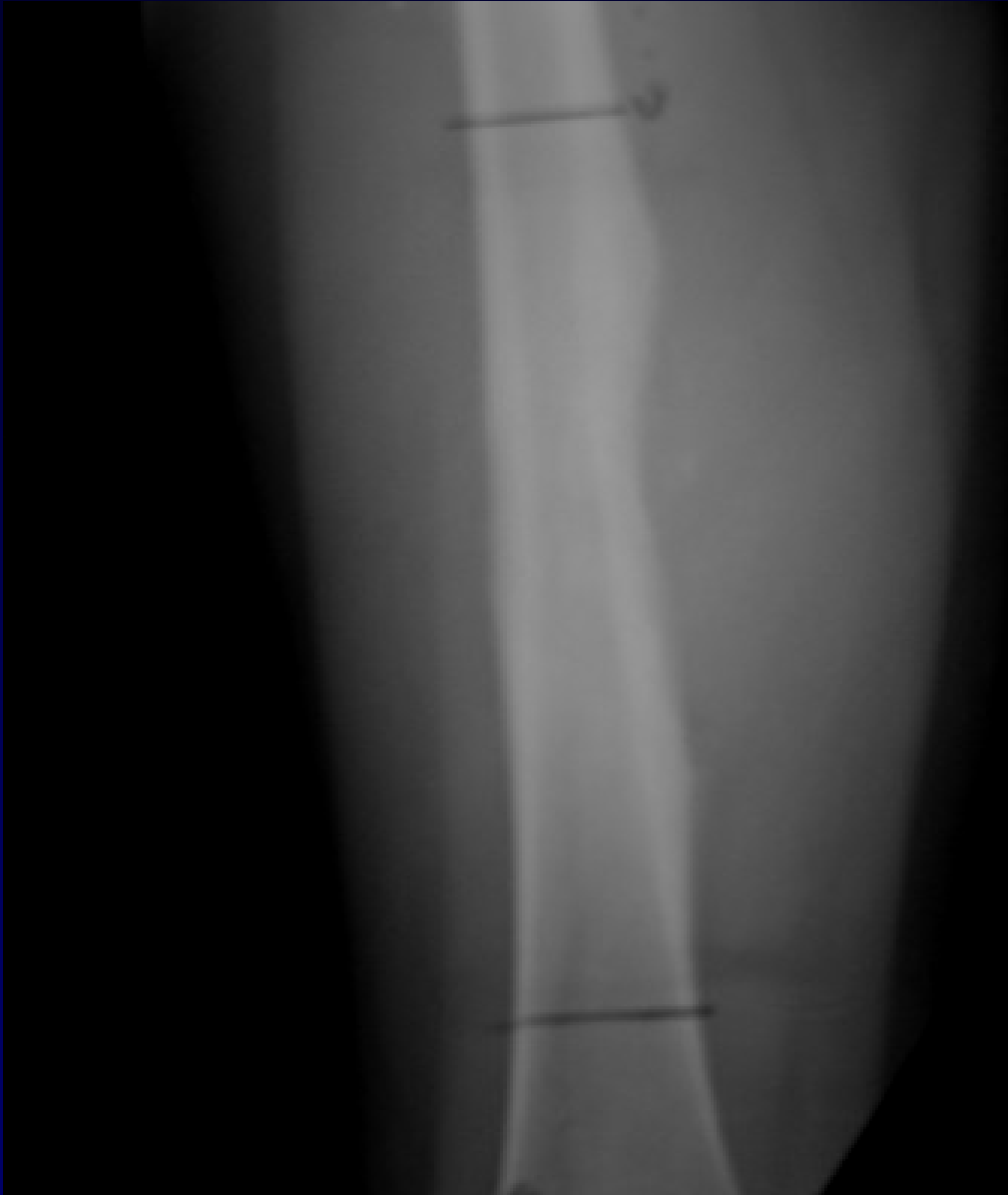Méthode finalisée par A. C. Masquelet



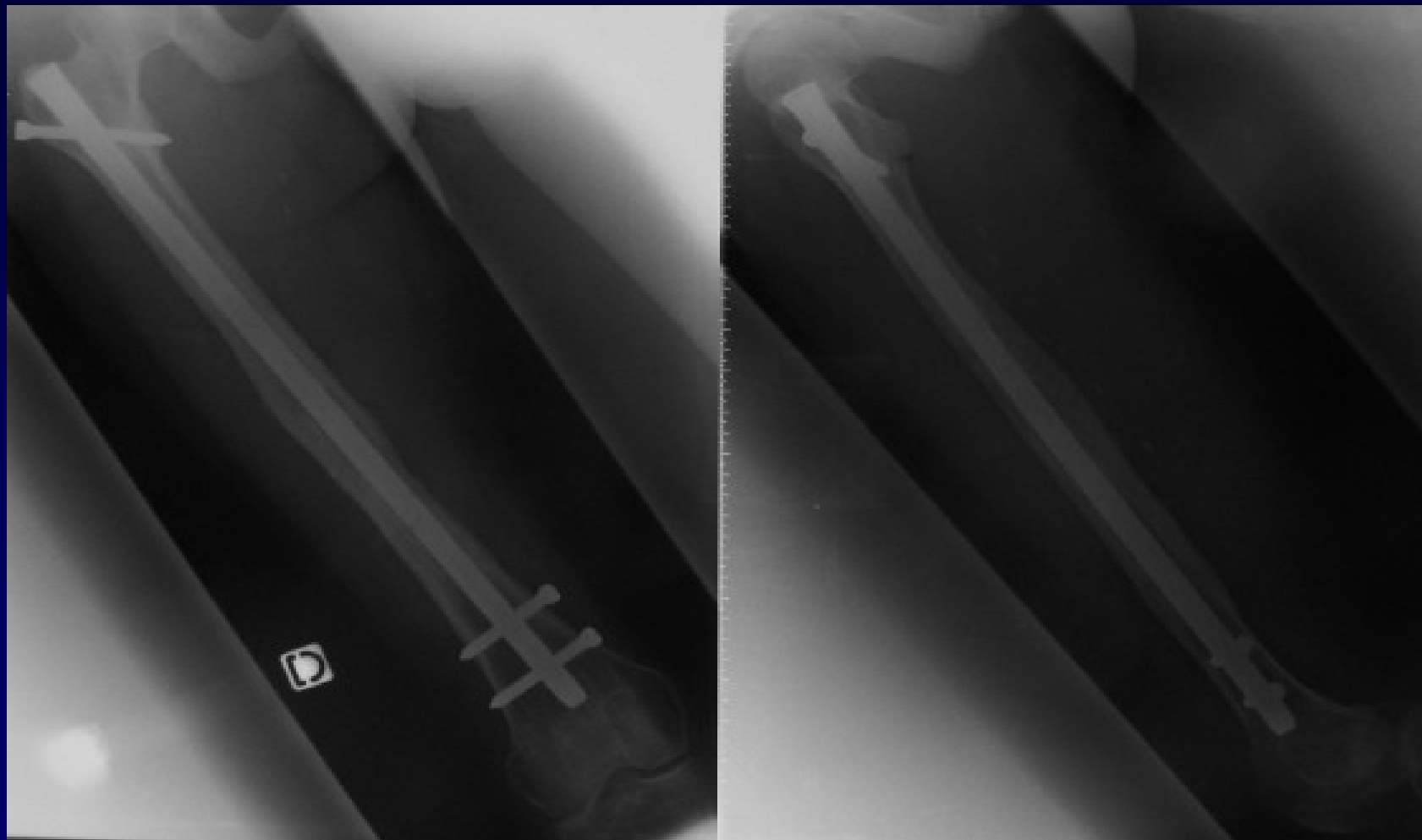
+ 8 mois !

Garçon, 11 ans
Ewing fémur droit

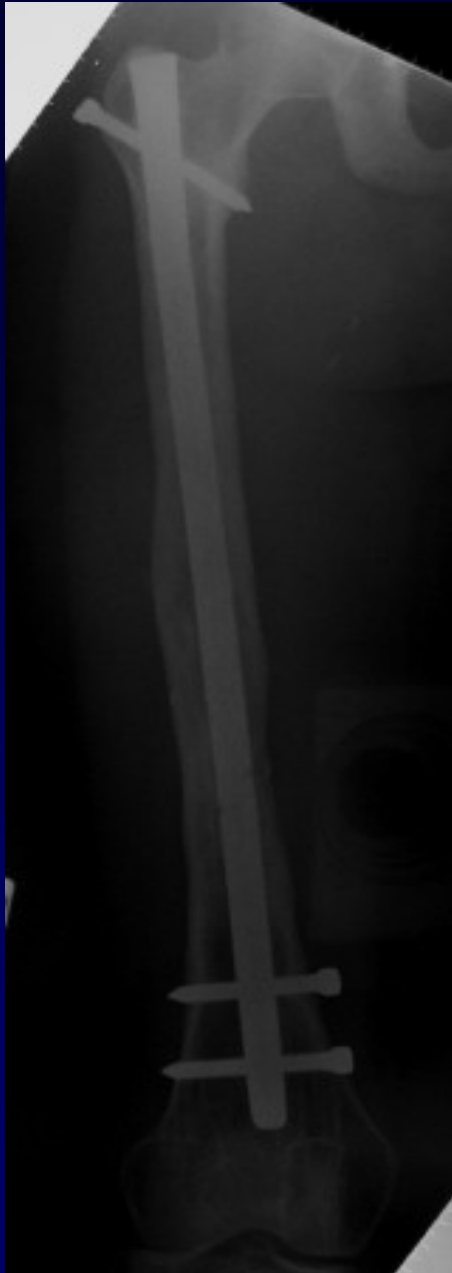



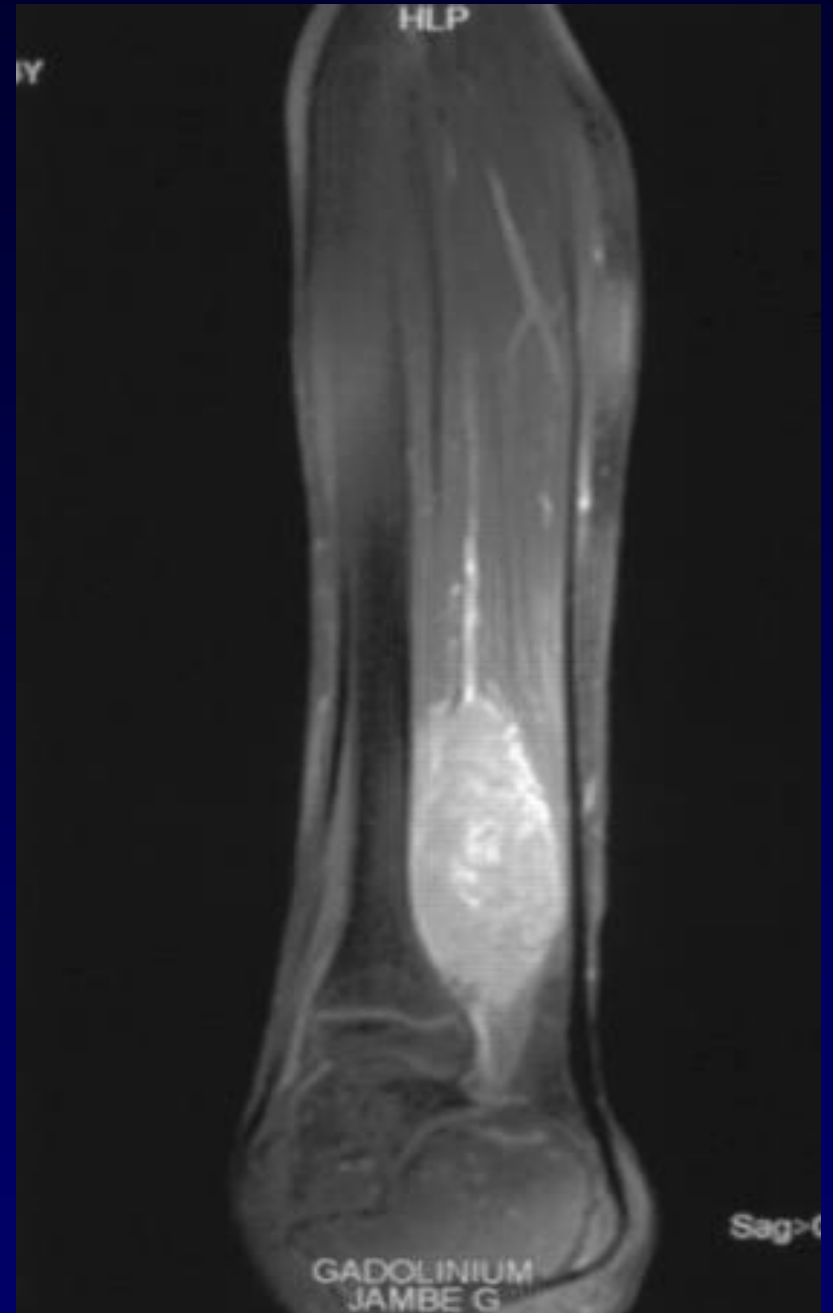
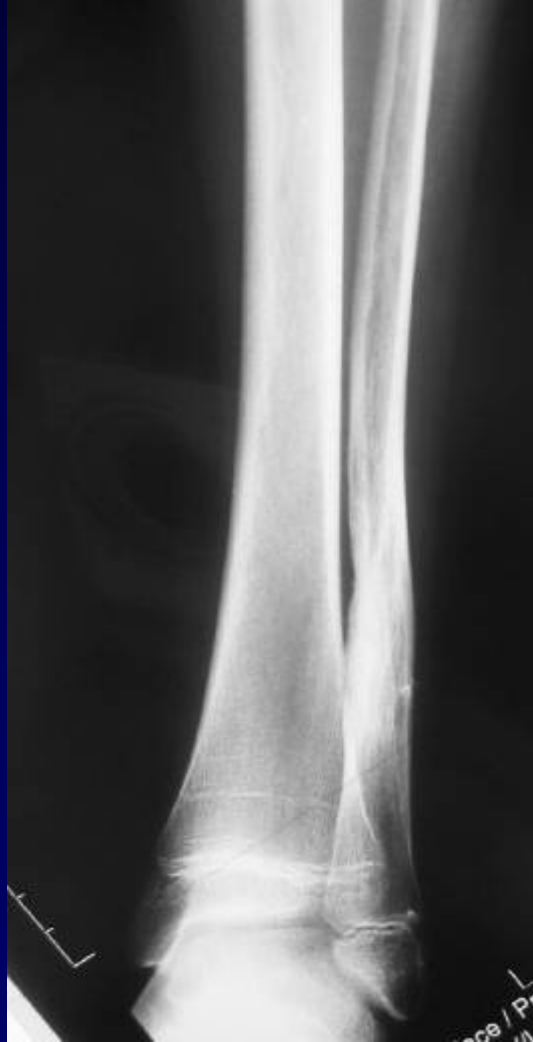
+ 1 an



+ 4 ans



Garçon, 11 ans
Ewing péroné gauche



MARTIN LEO
08
6/11/92, M, 13Y

STUDY 1
20/03/06
17:14:17
IMA 10 / 16

HPR

DR LEJEUNE
Harmony
MR 2004A
FFS
+LPH

F 1.27
130.0
R 5000.0
E 68.0
A 02:55
W 180.0
IND
MIR
D1.2;SP3-6
241.11 / 180

JAMBE G

MARTIN LEO
2108
06/11/92, M, 13Y
STUDY 1
20/03/06
17:20:14
4 IMA 9 / 19

A

DR LEJEUNE
Harmony
MR 2004A
FFS
+LPH

RH

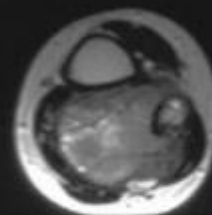
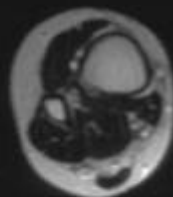
10ci

MF 1.37

TR 5080.0
TE 145.0
TA 03:43
BW 195.0
MIND
SP P53
SL 4 A2
FOV 377*441
tse2d1_23 / 180

Cor>Tra(2.3)>Sag(1.9)

W 394
C 38



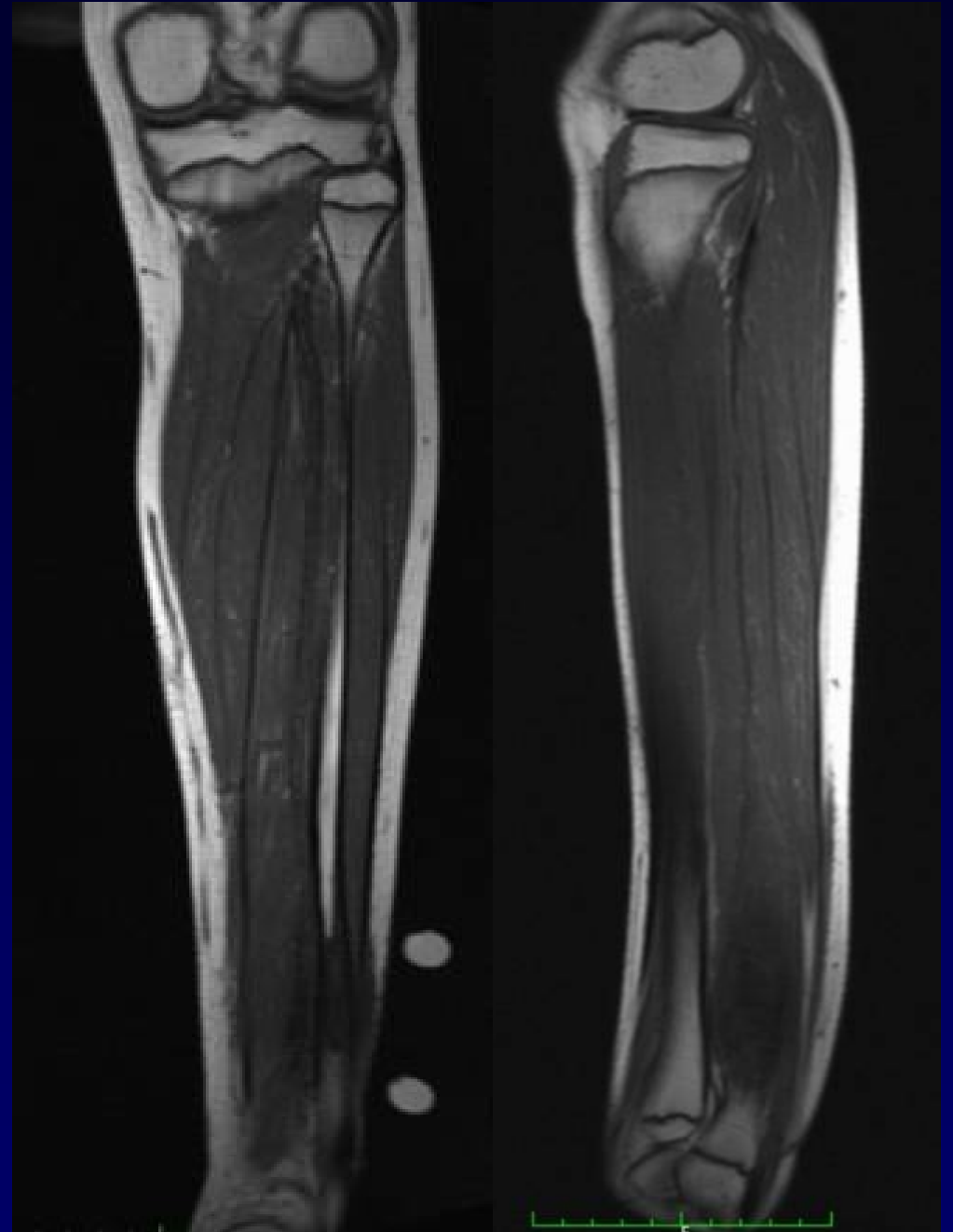
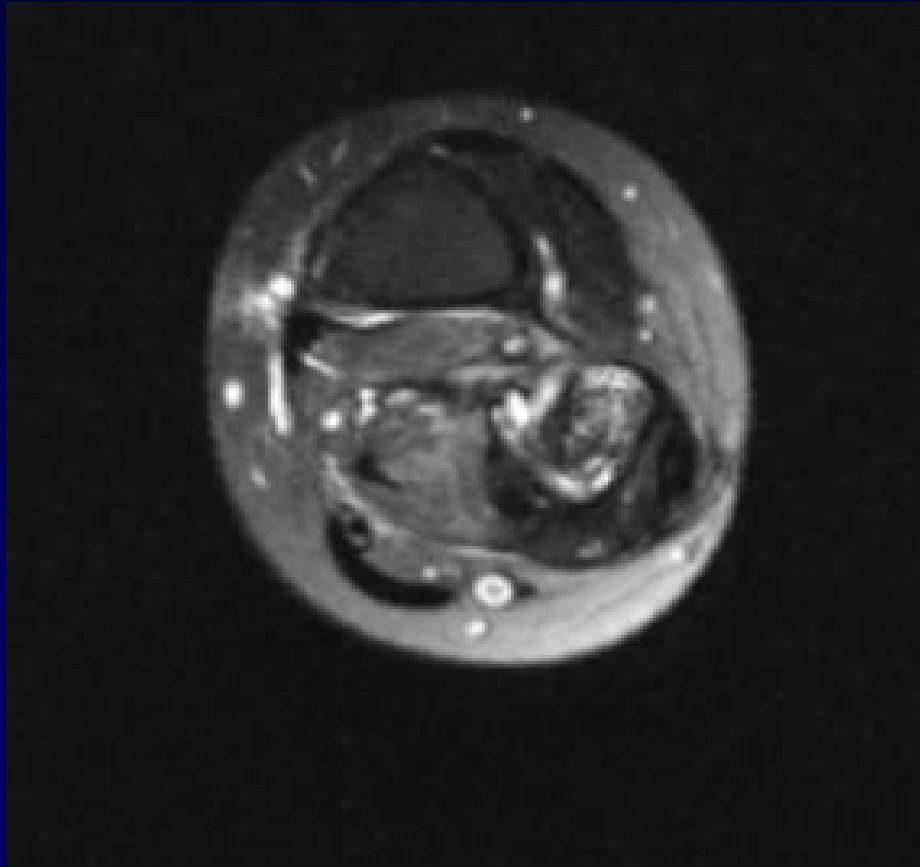
10ci

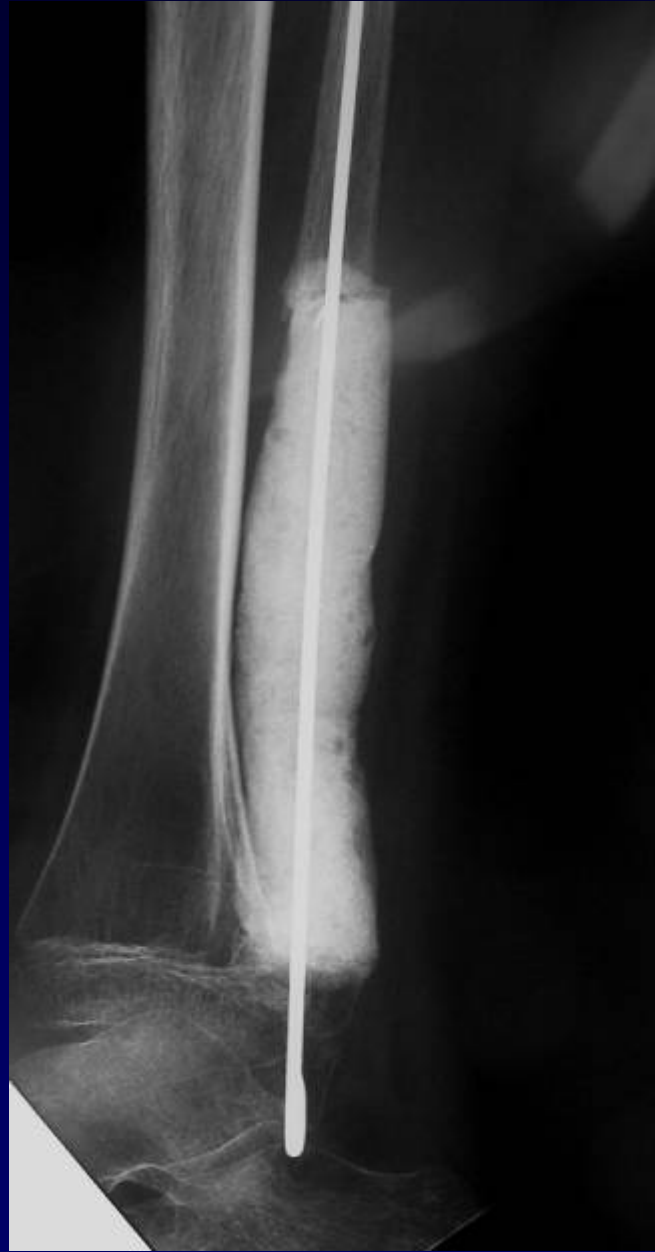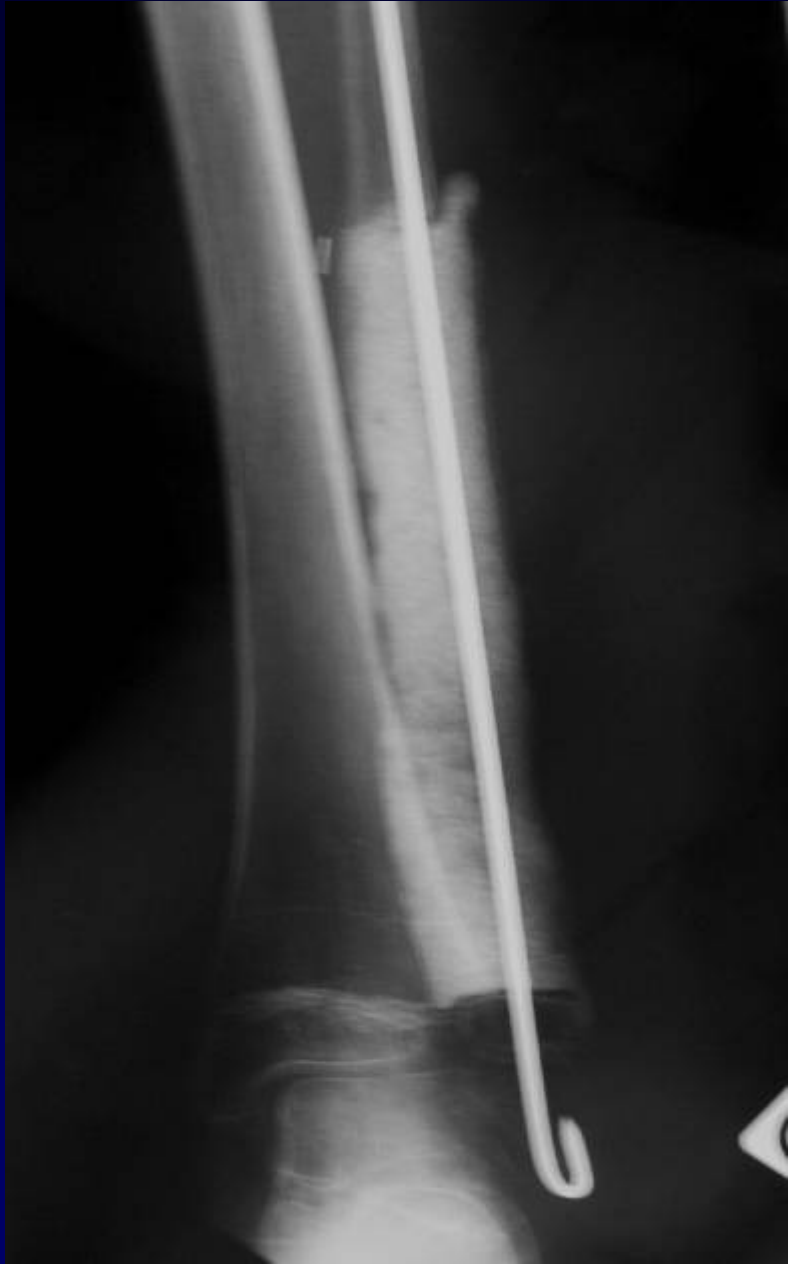JAMBE G

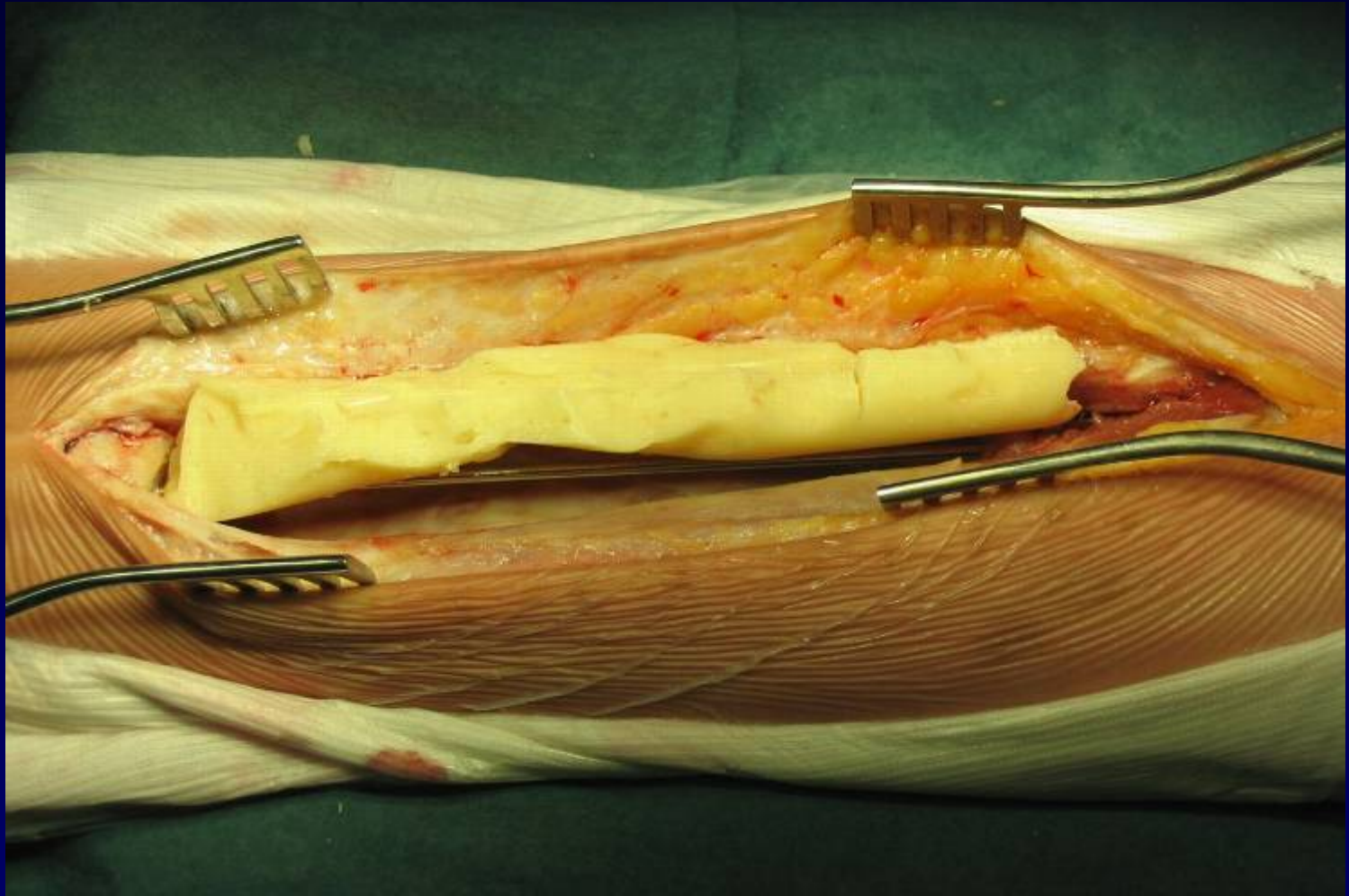
SP F19
SL 6
FoV 327*361
264*512
Tra>Sag(-0.1)

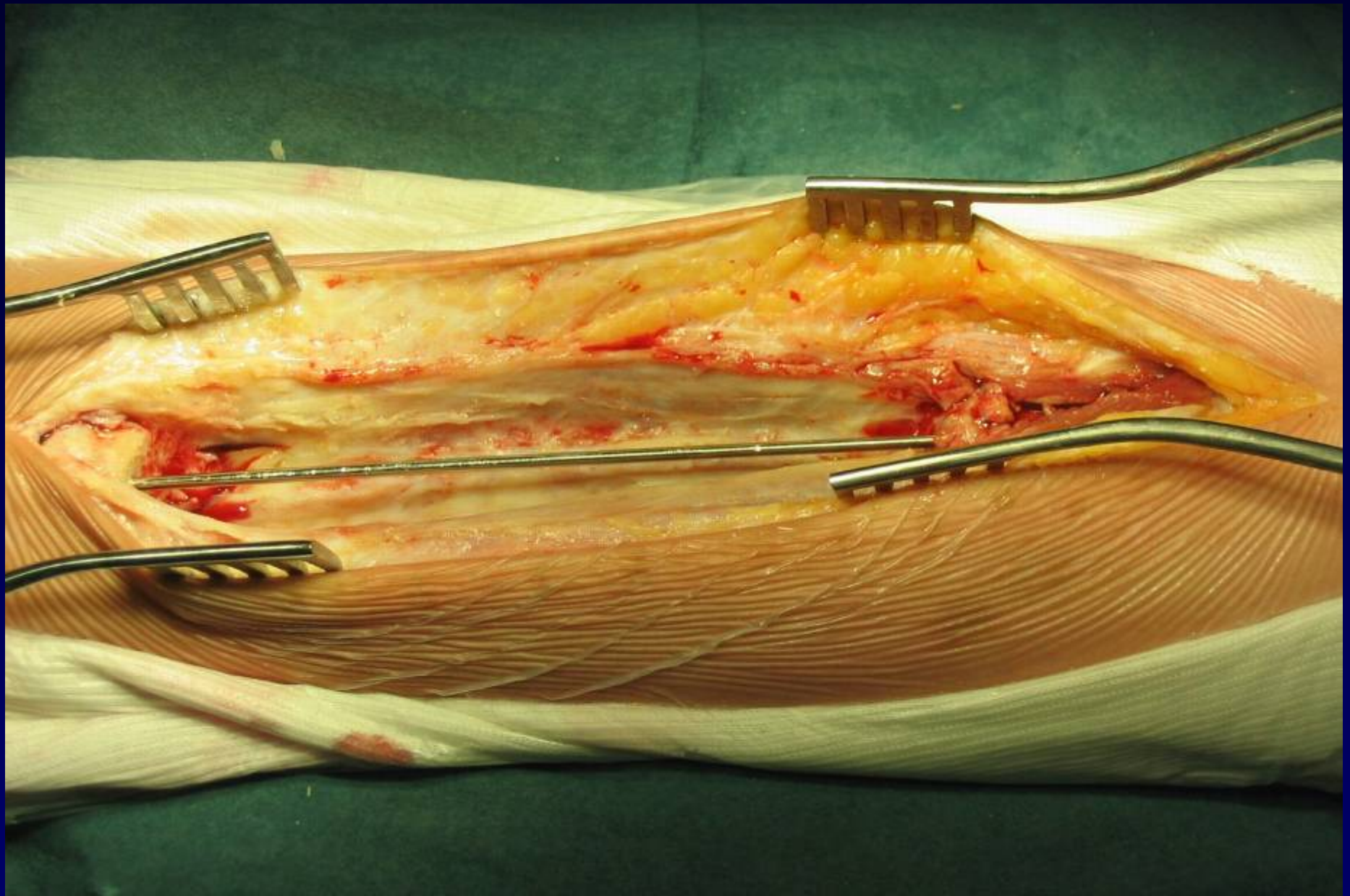
W 89
C 46

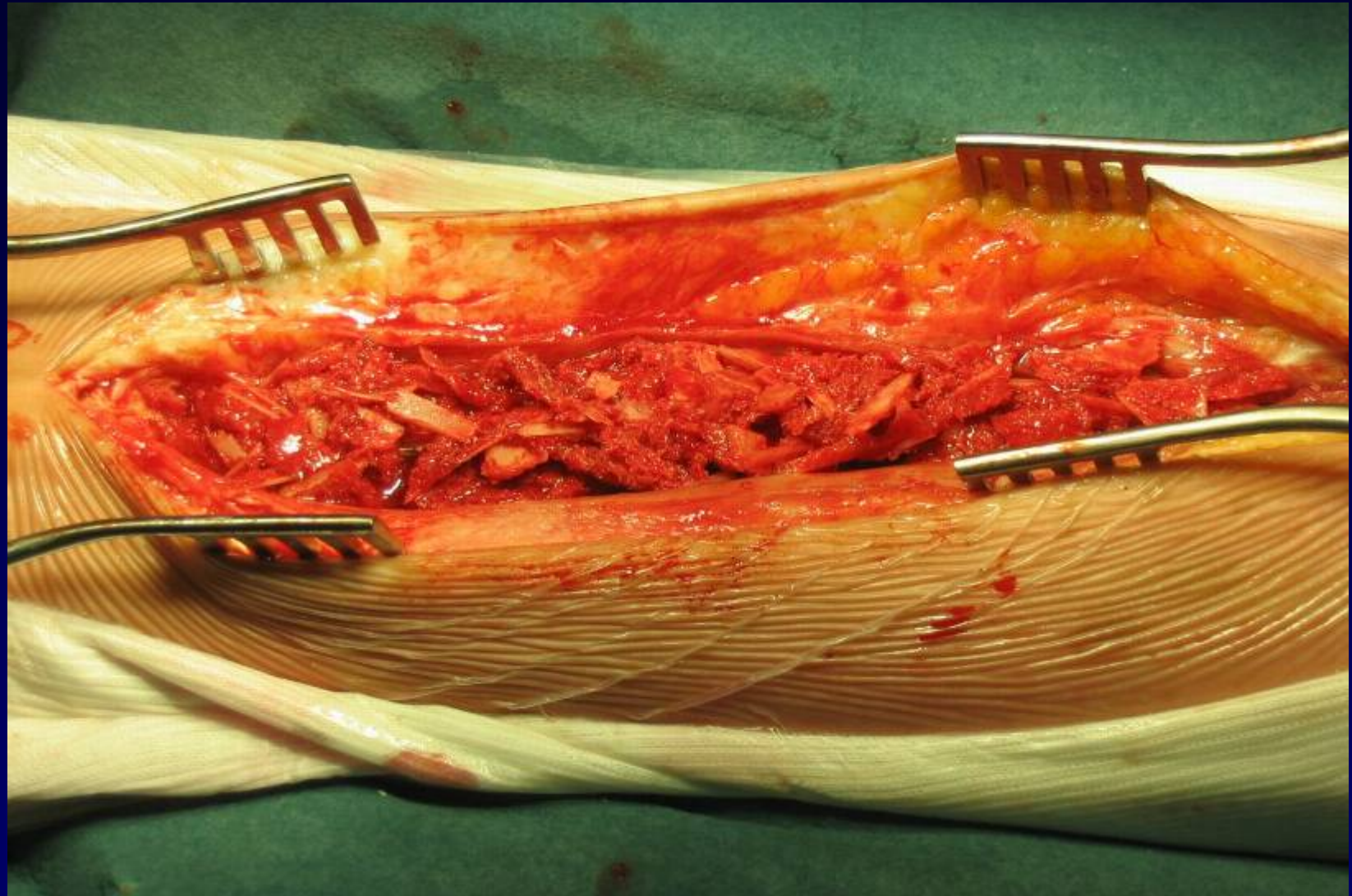
Après chimiothérapie

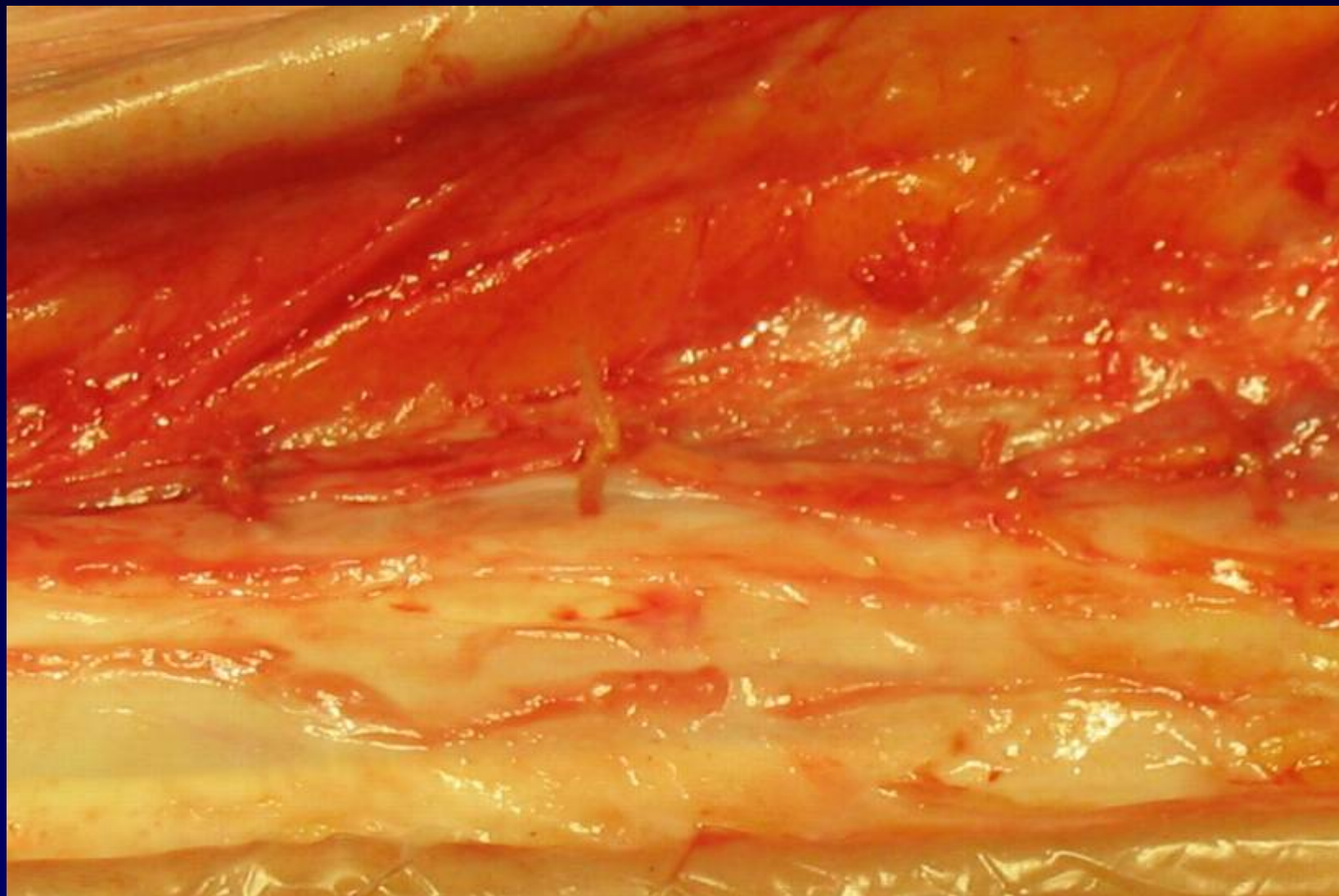


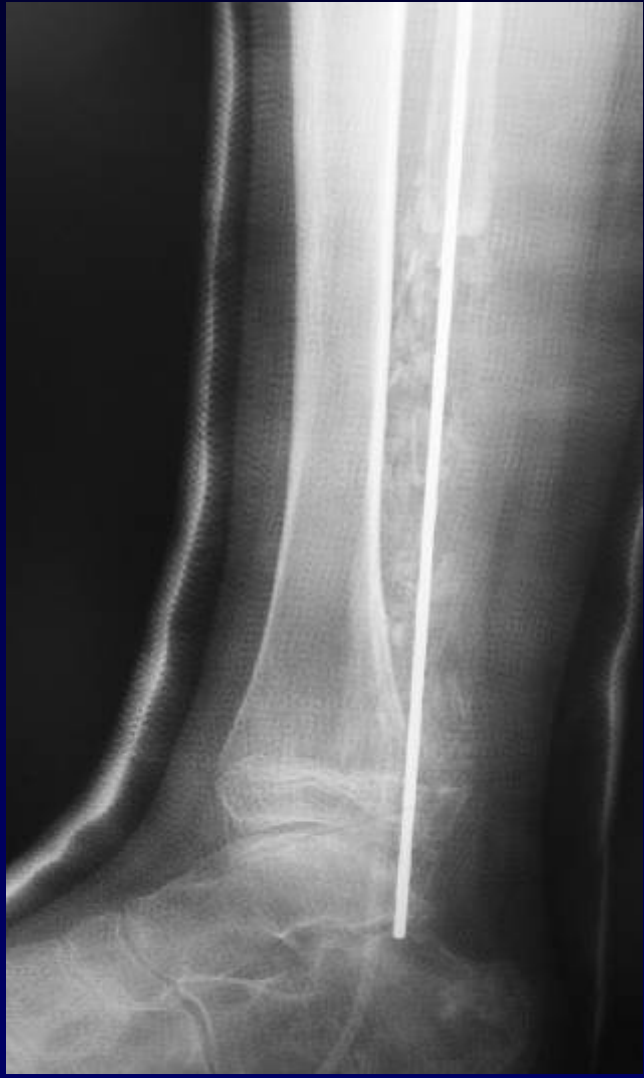
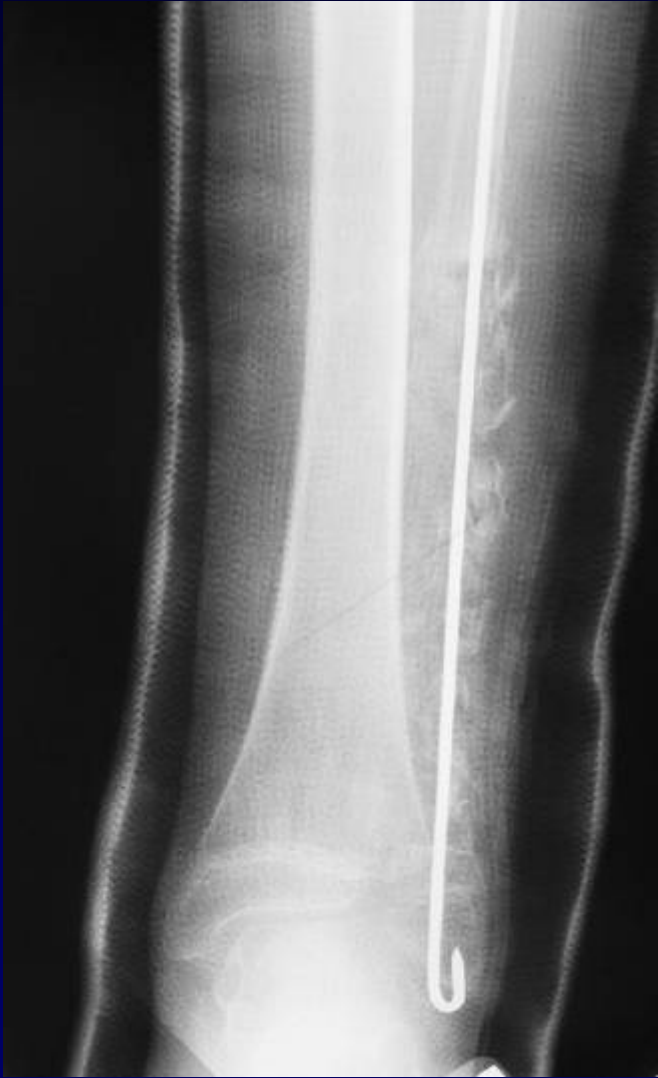




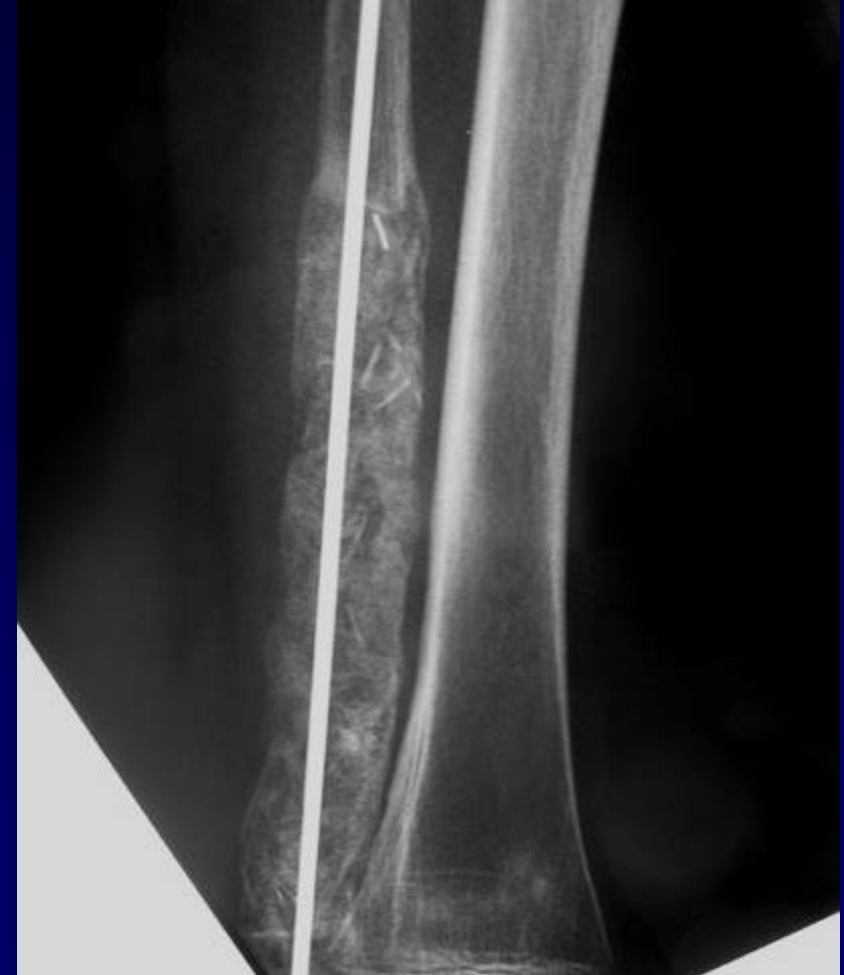
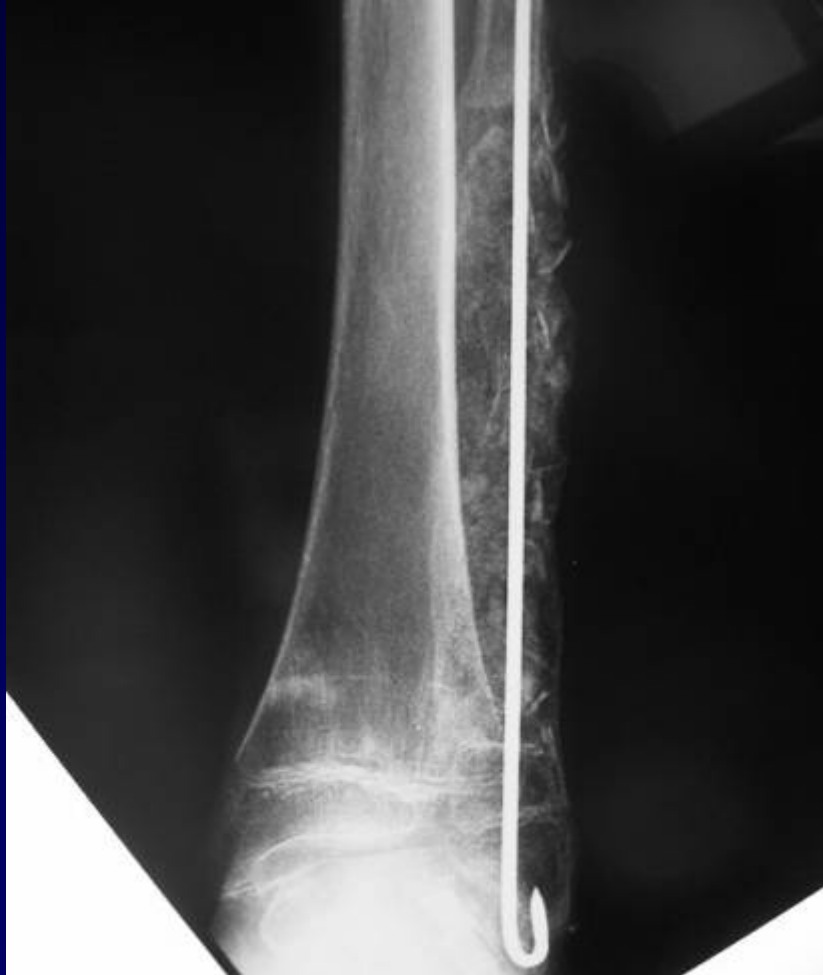
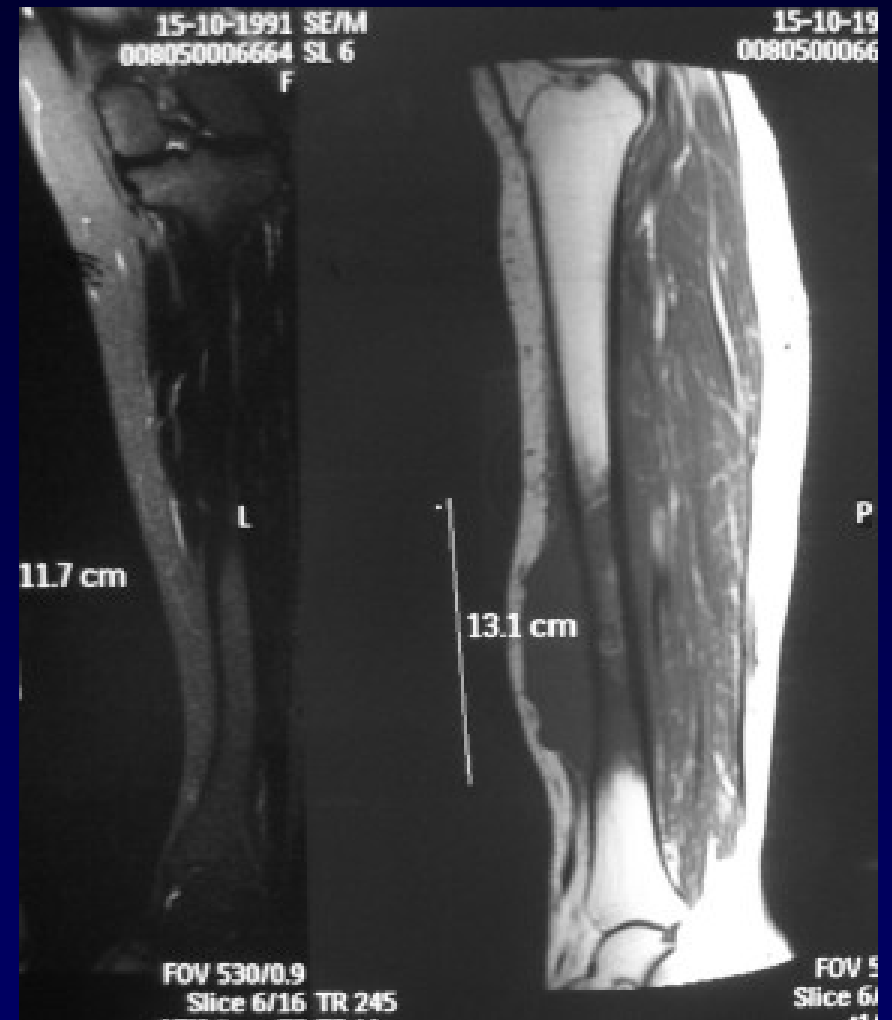
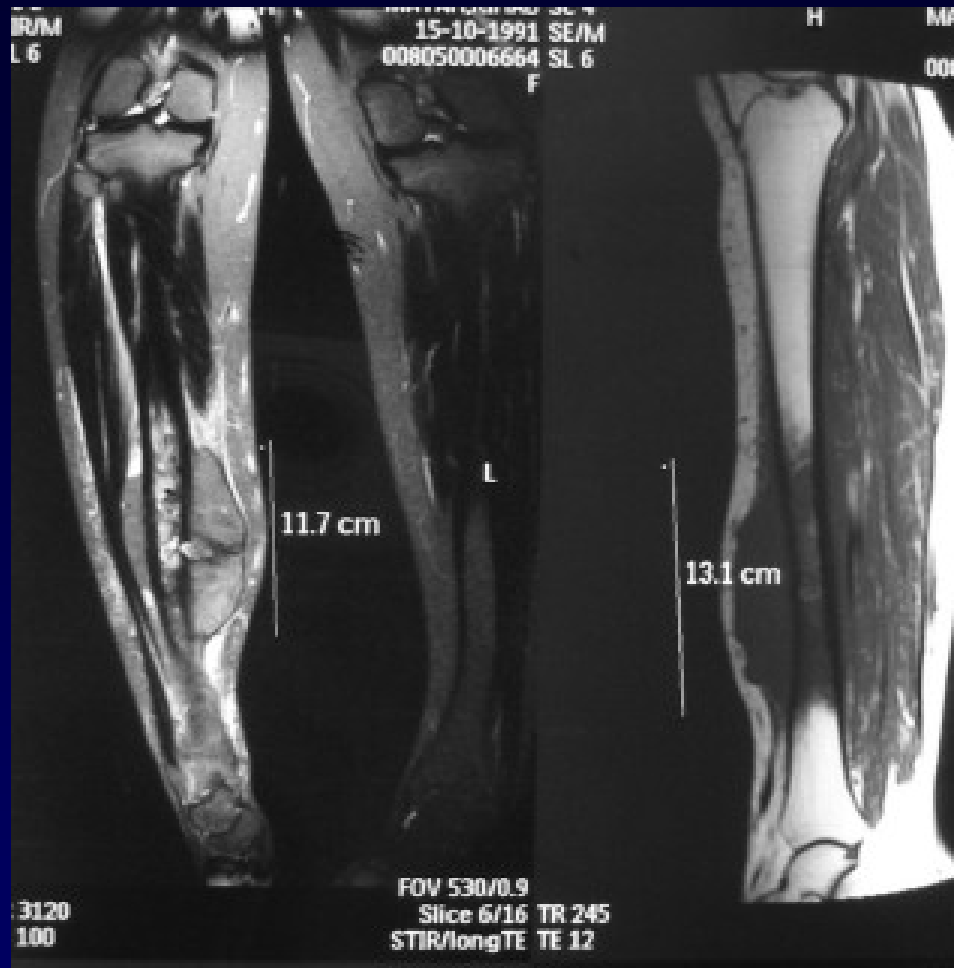




+ 6 mois



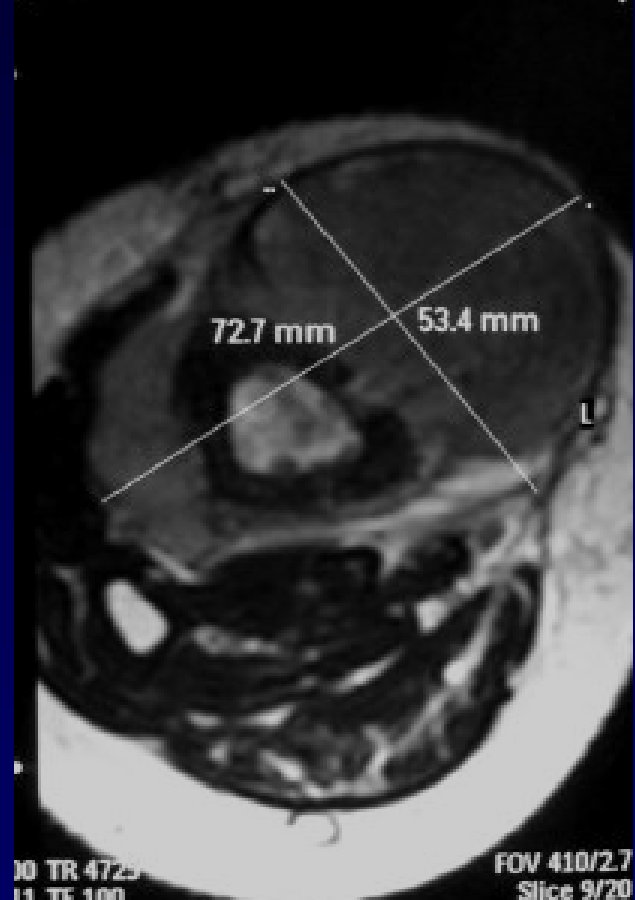




B Sc 3
1 TSE/M
4 SL 9
F

A

MATAHURHAB
15-10-1991
008050006664
F



10 TR 4725
11 TE 100
se TSE Factor 21

FOV 410/2.7
Slice 9/20
T2W/TSE

MB Sc 6
91 SE/M
64 SL 7

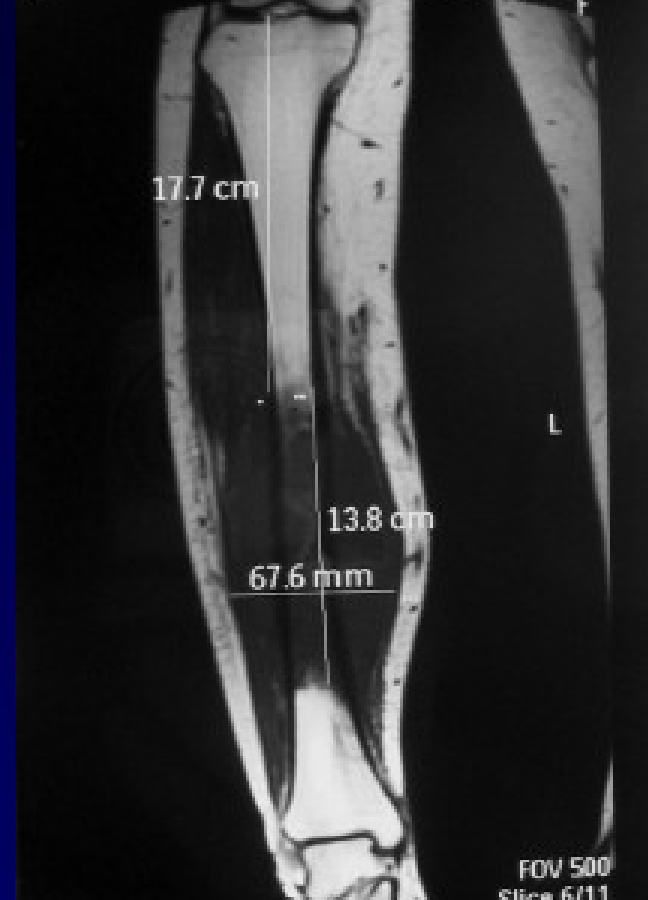
H

MATAHURHAB
15-10-1991
008050006664
F

C 3
E/M
L 6

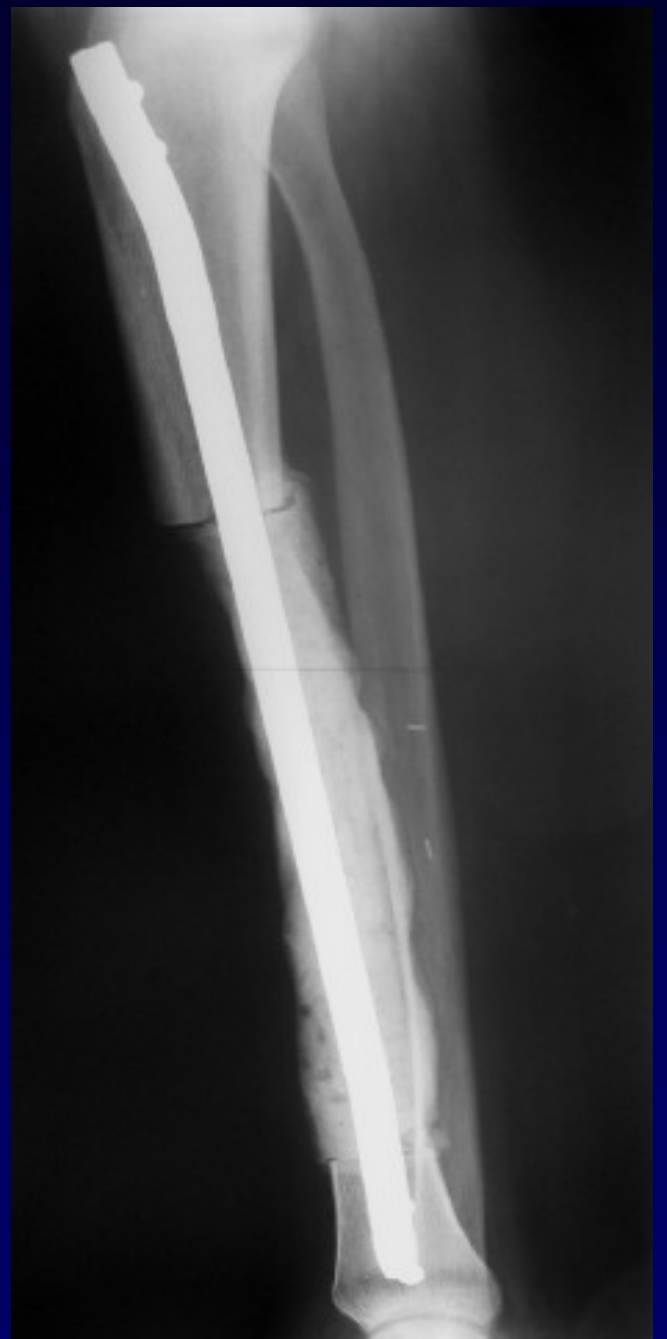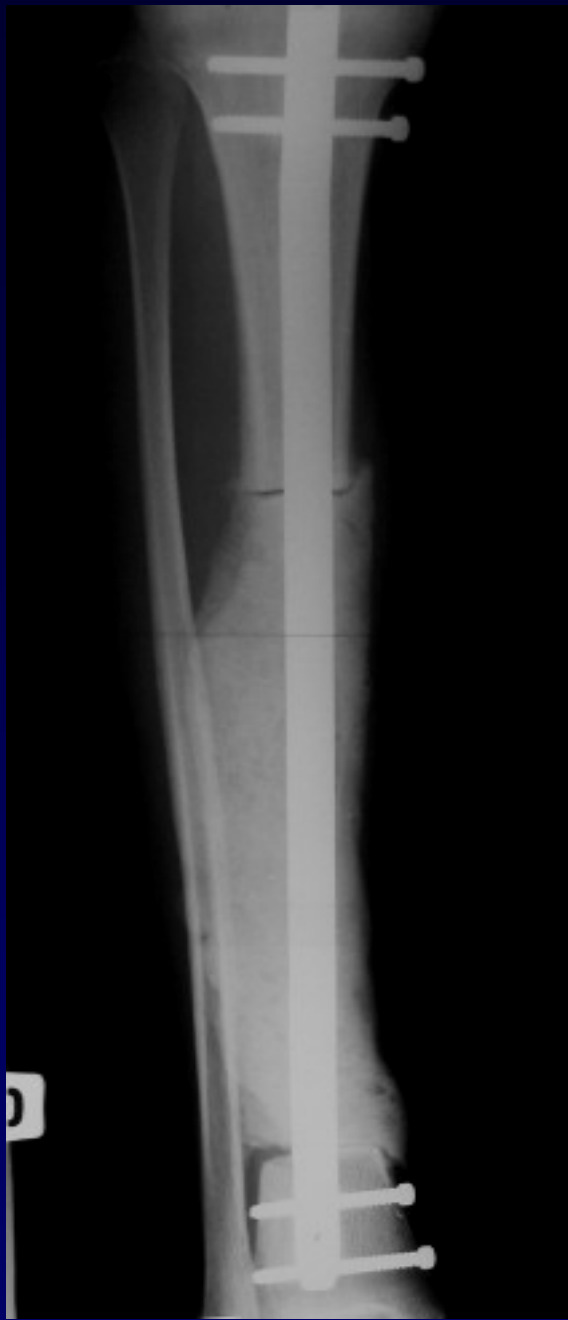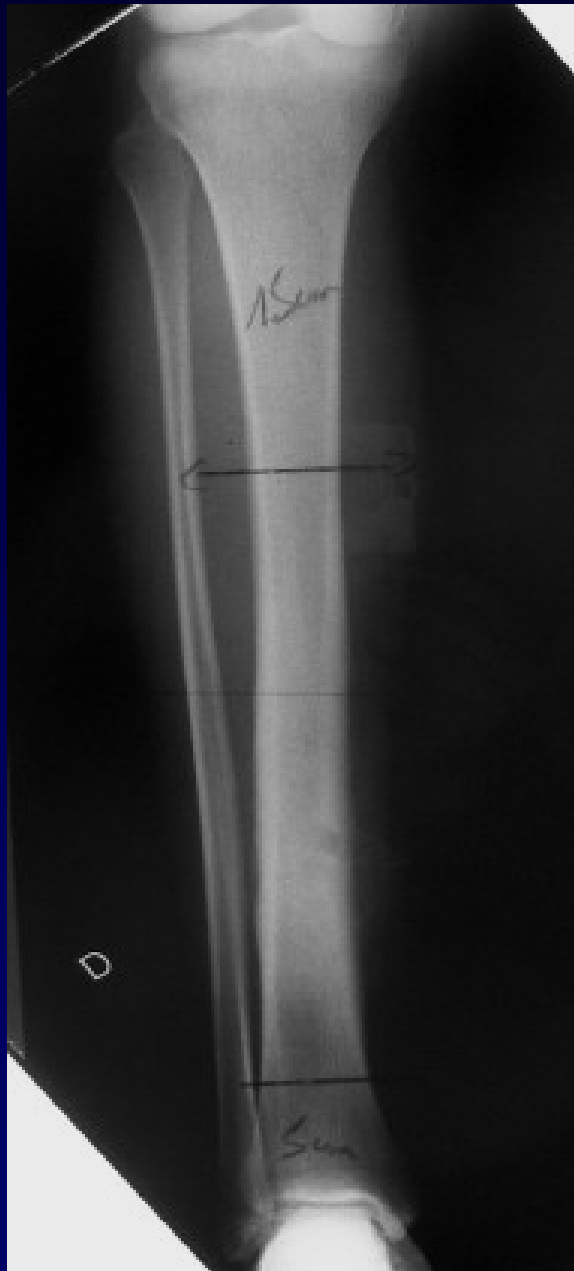H

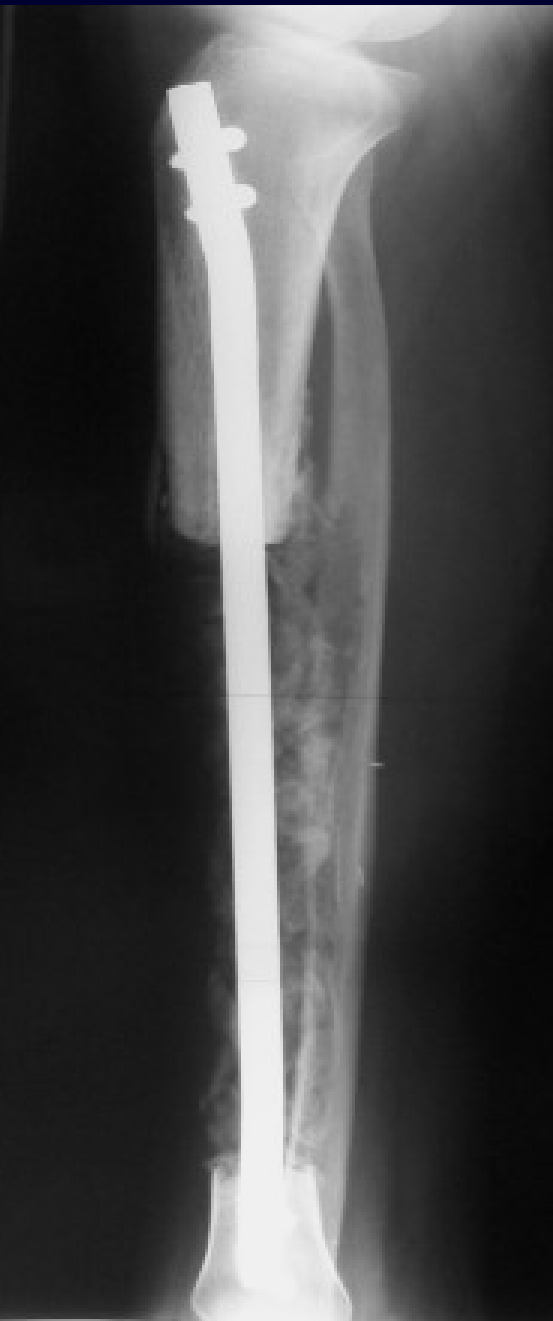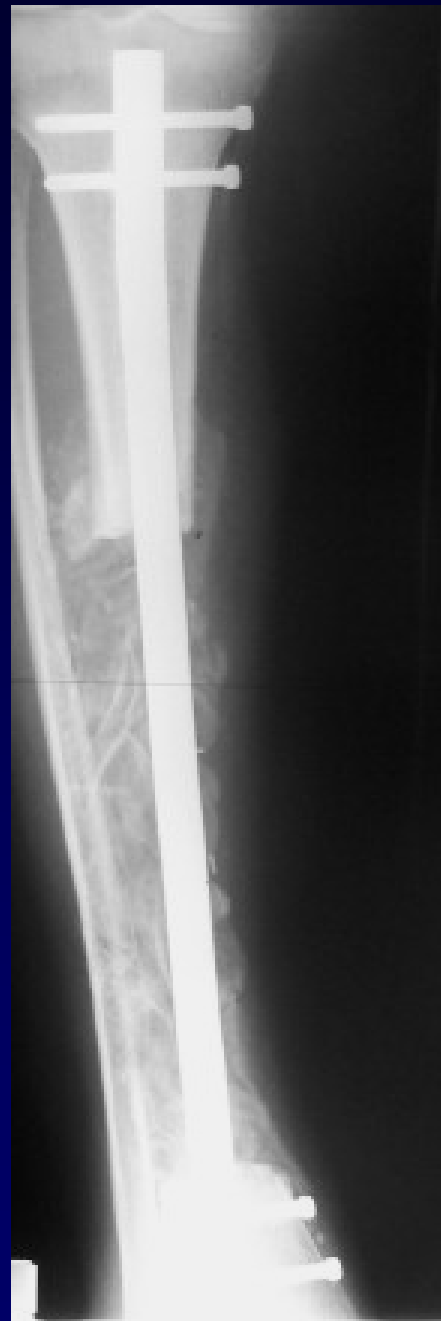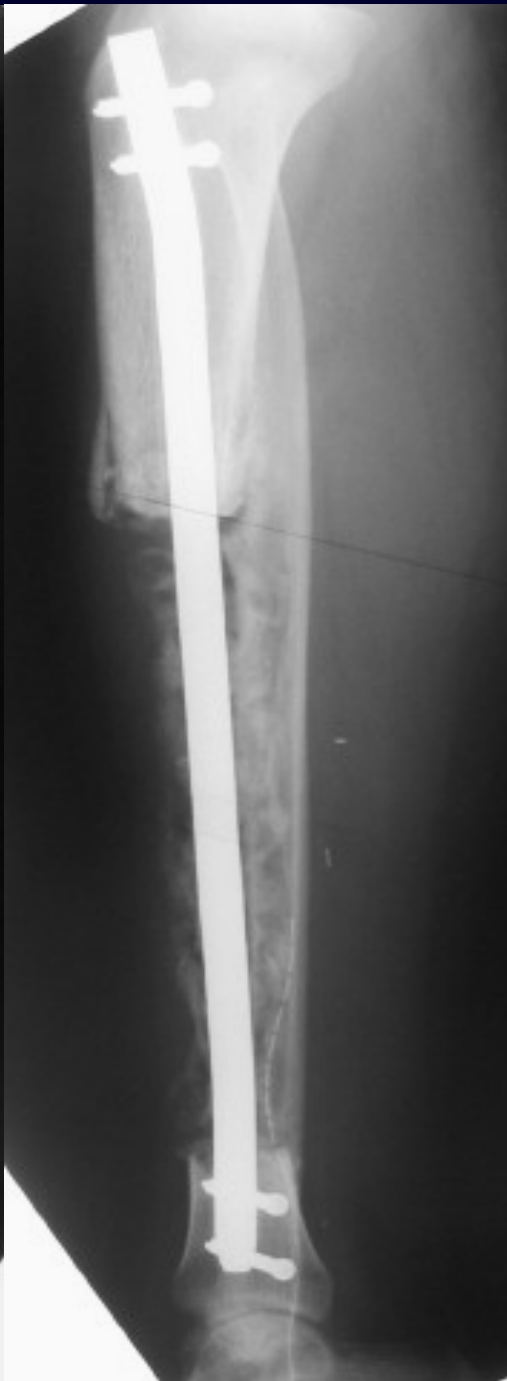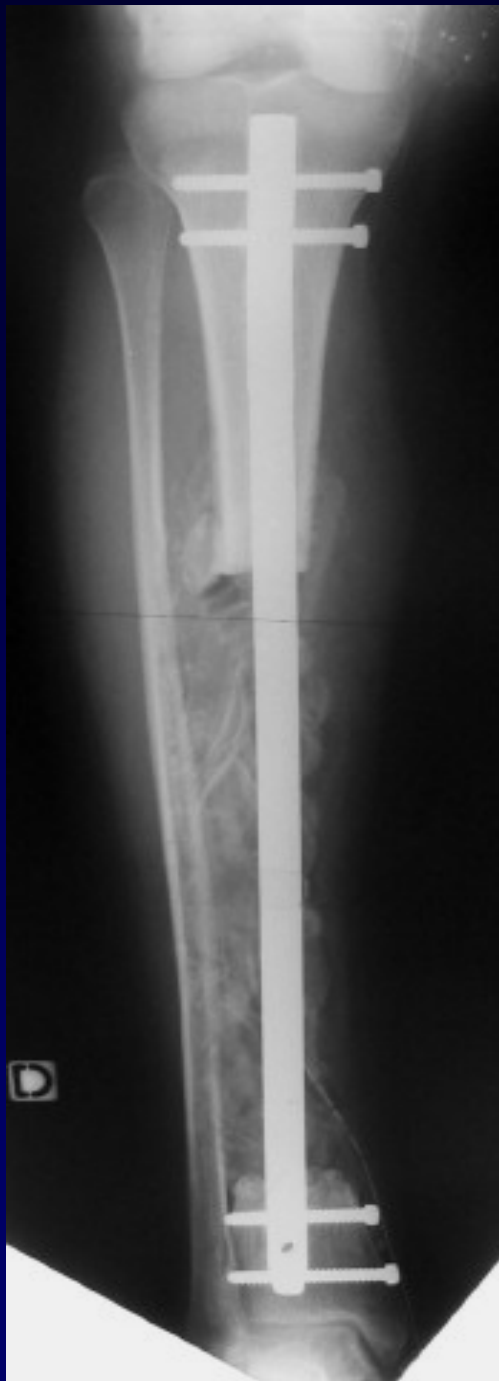MATAHURHAB
15-10-1991
008050006664
F



TR 245
TE 12

FOV 500
Slice 6/11
t1/se

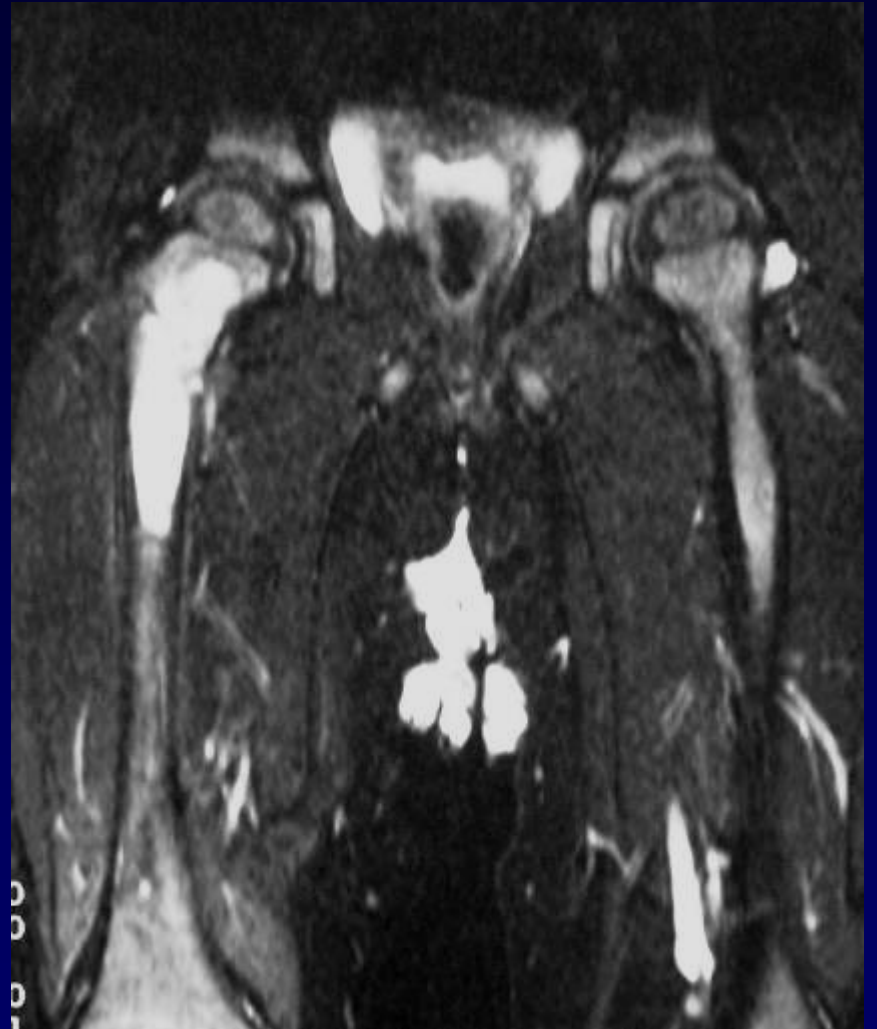
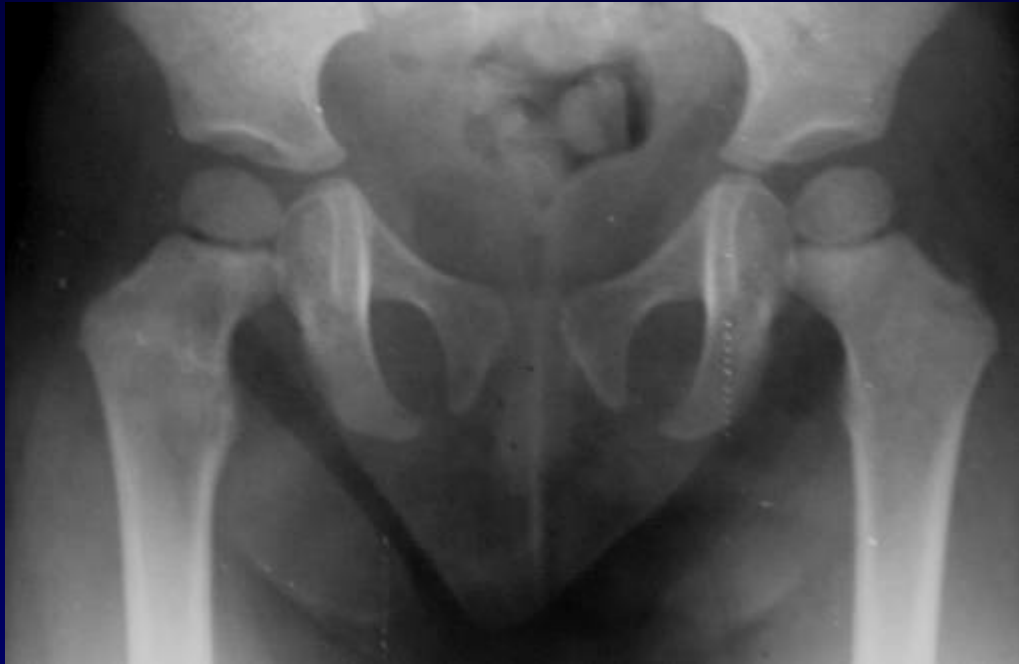


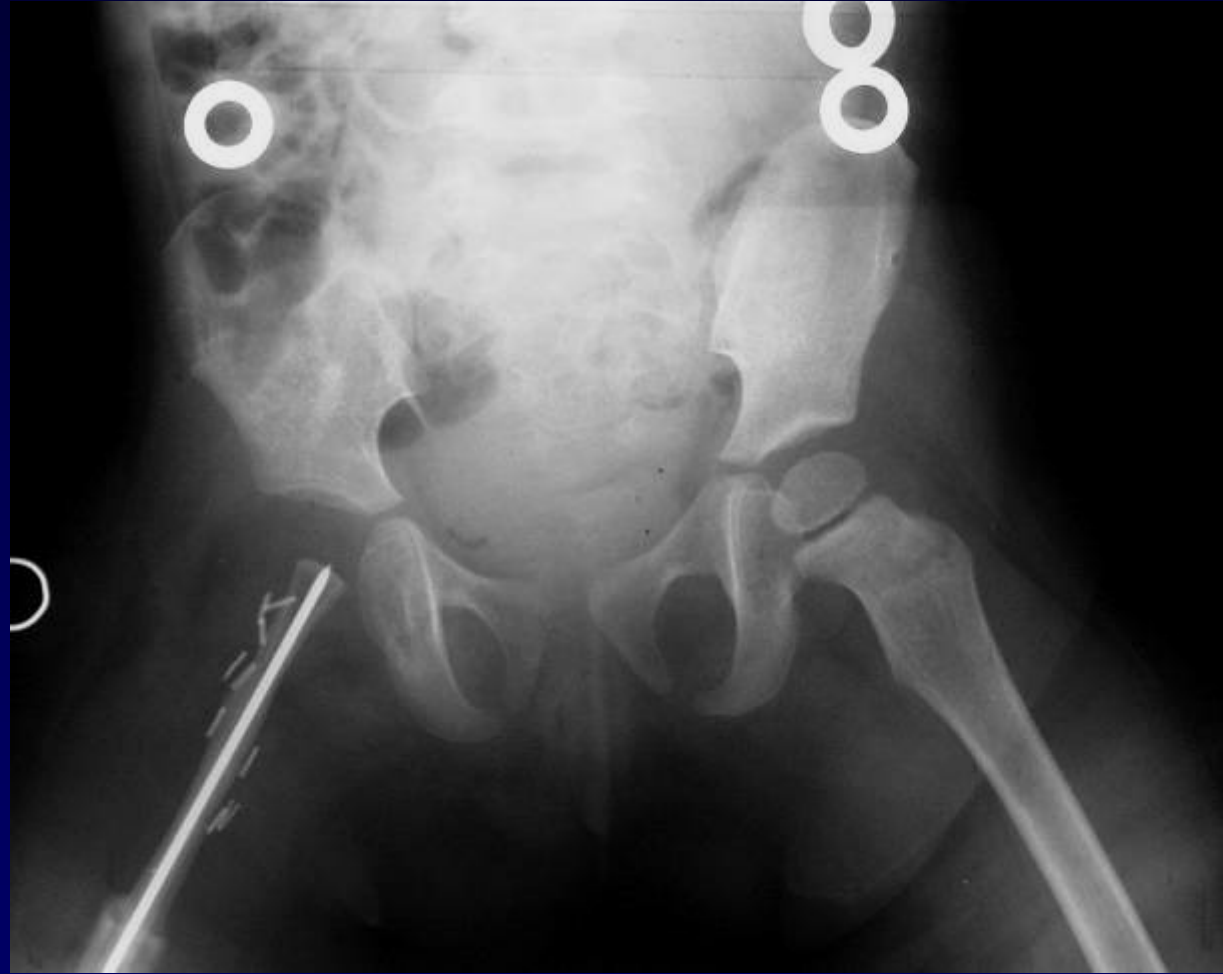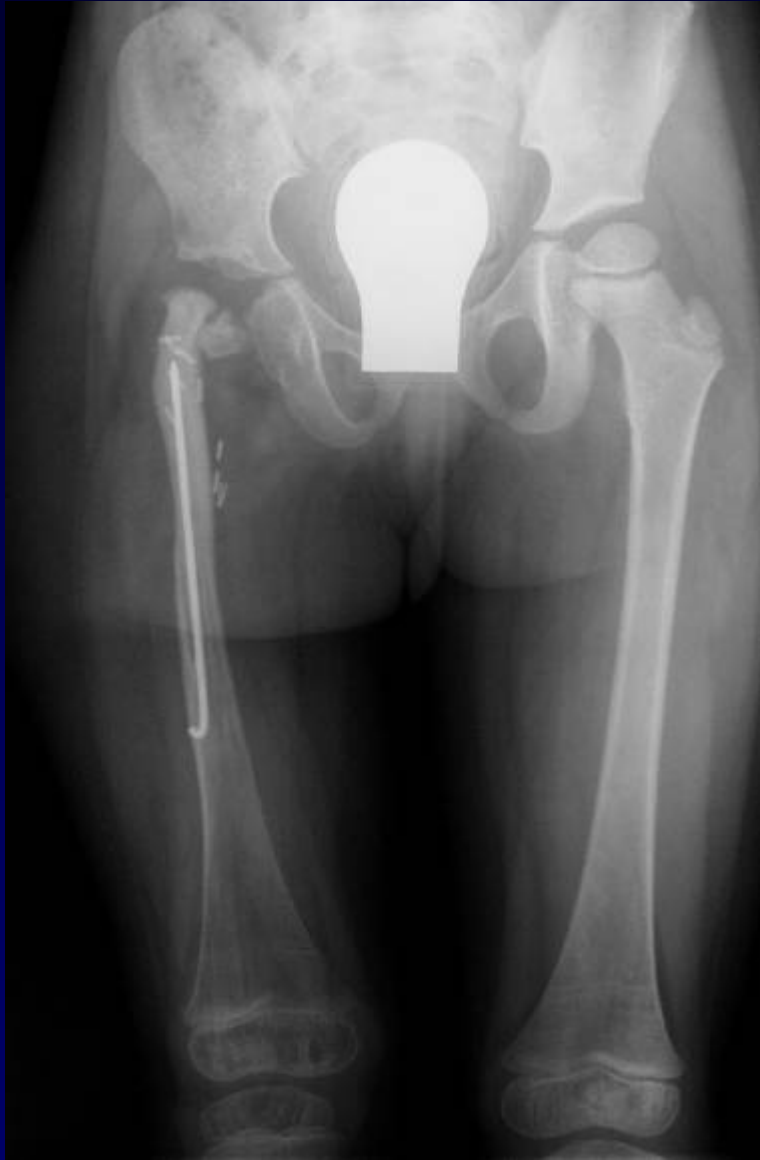Reconstruction Articulaires

- Transfert épiphysaire
- Arthrodeèse

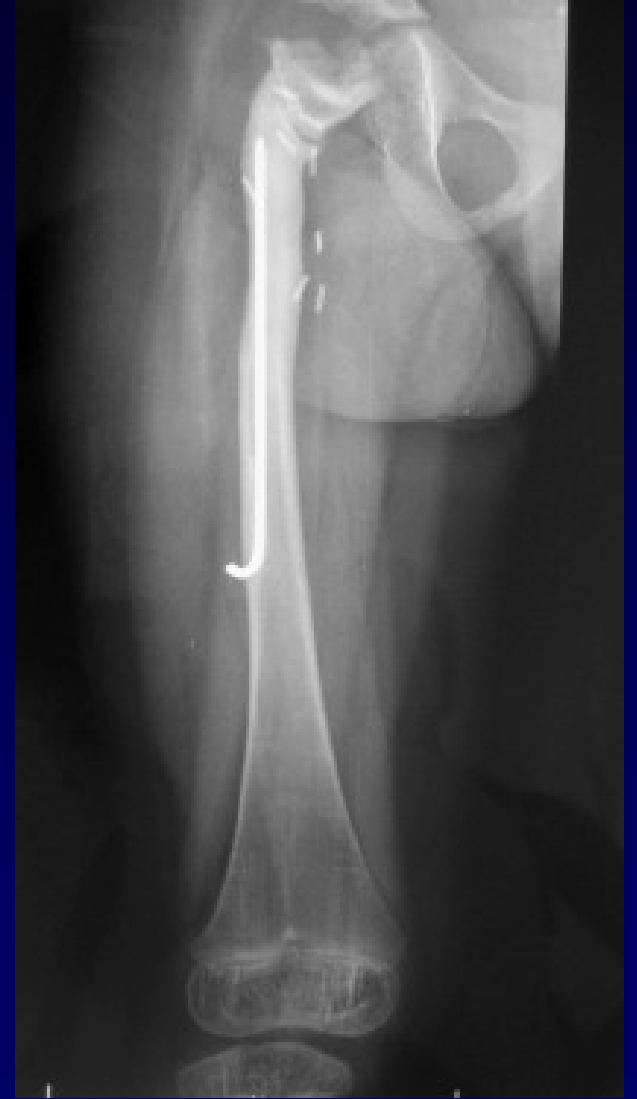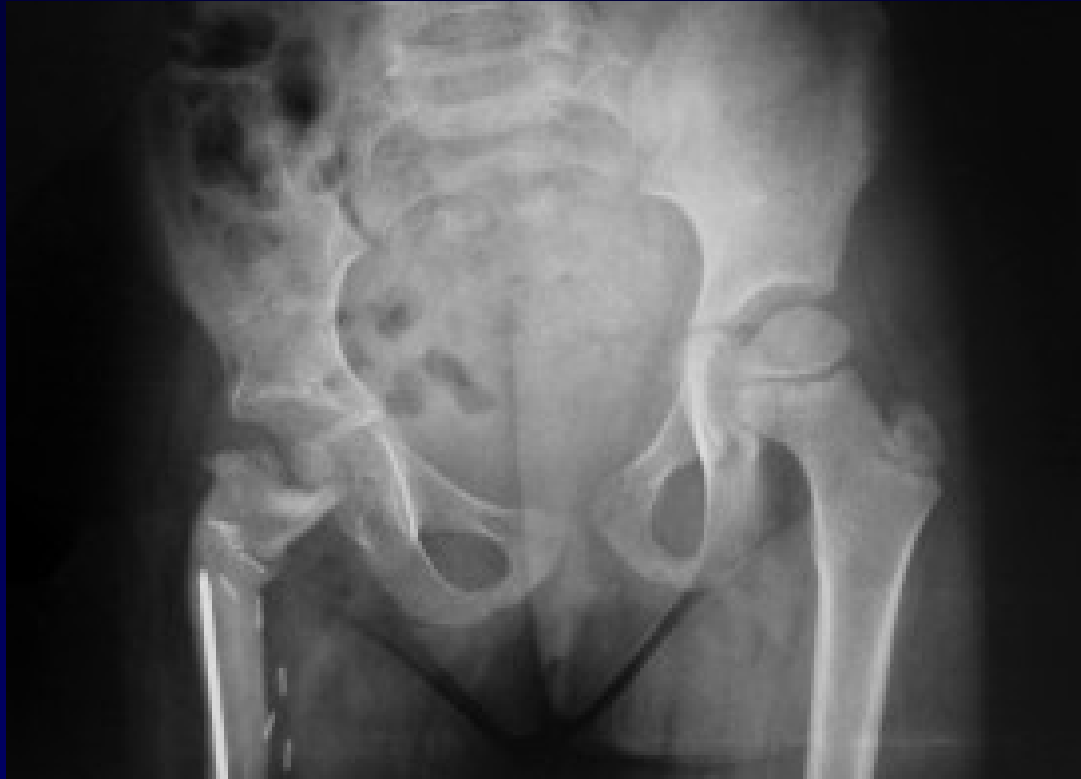Fille 2 ans
Sarcome d'Ewing



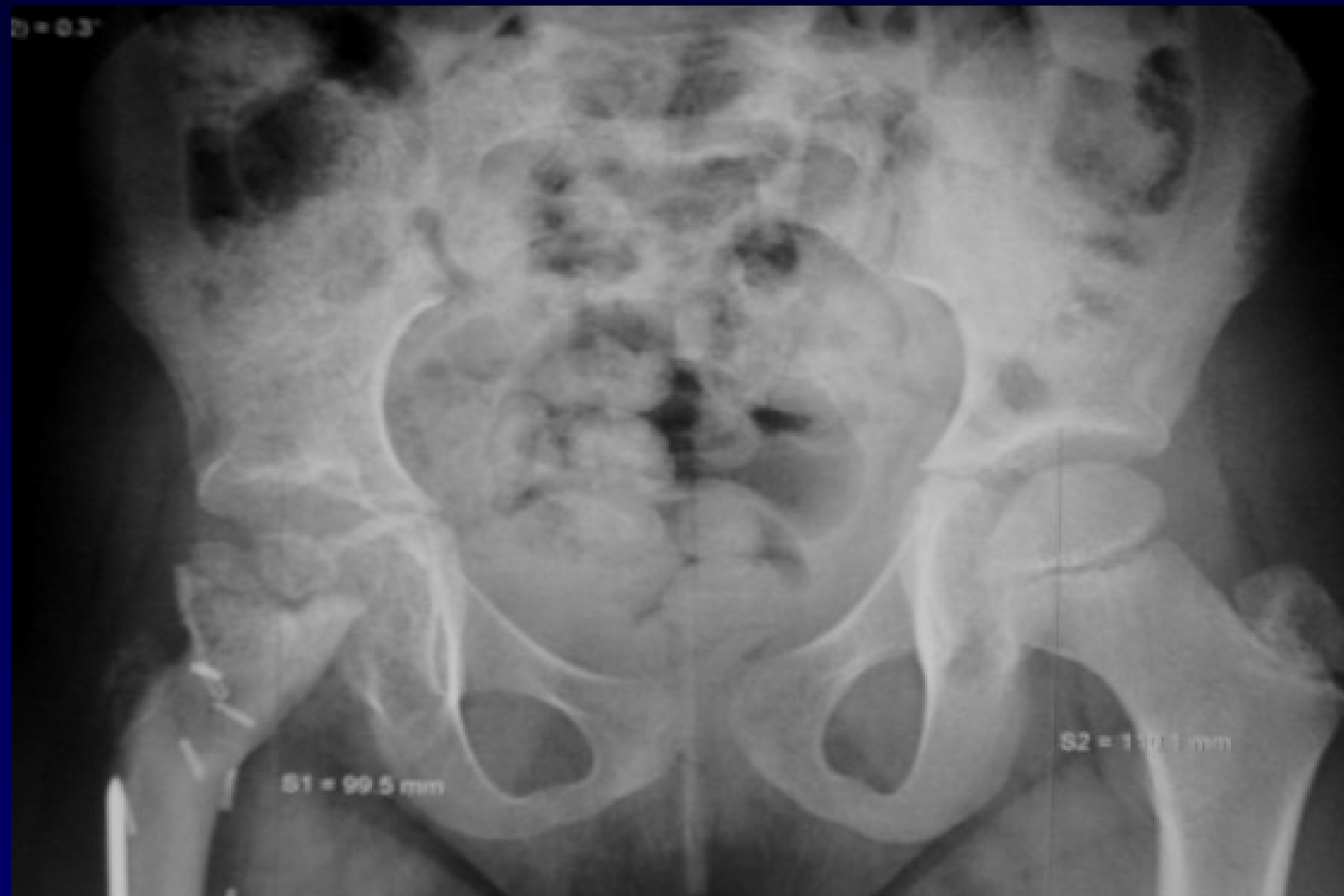






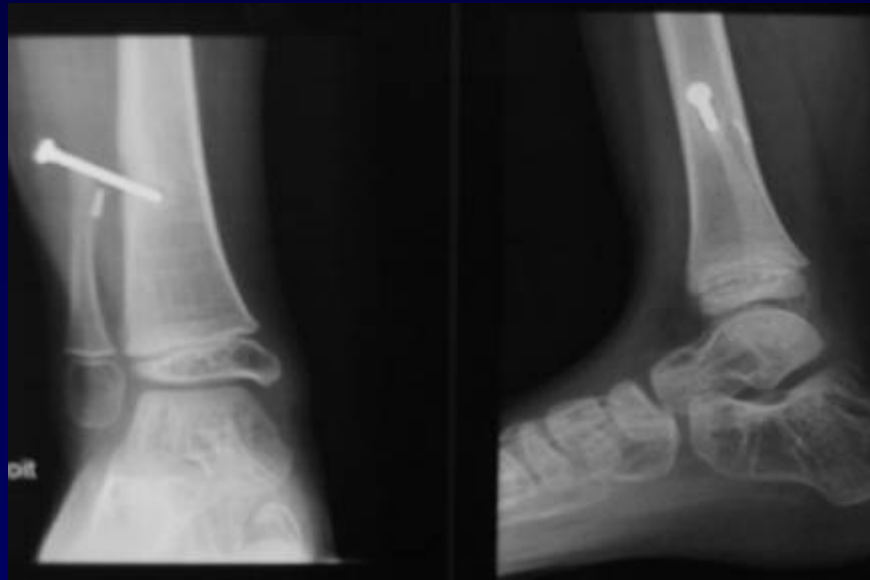
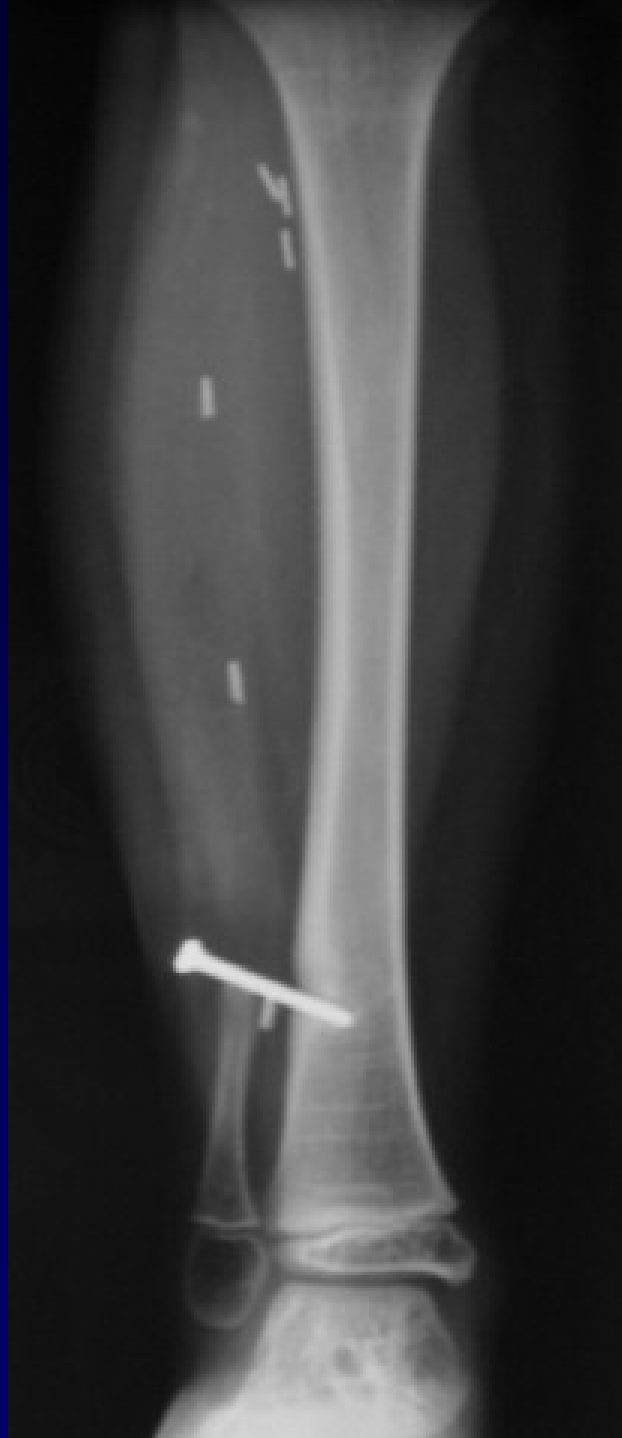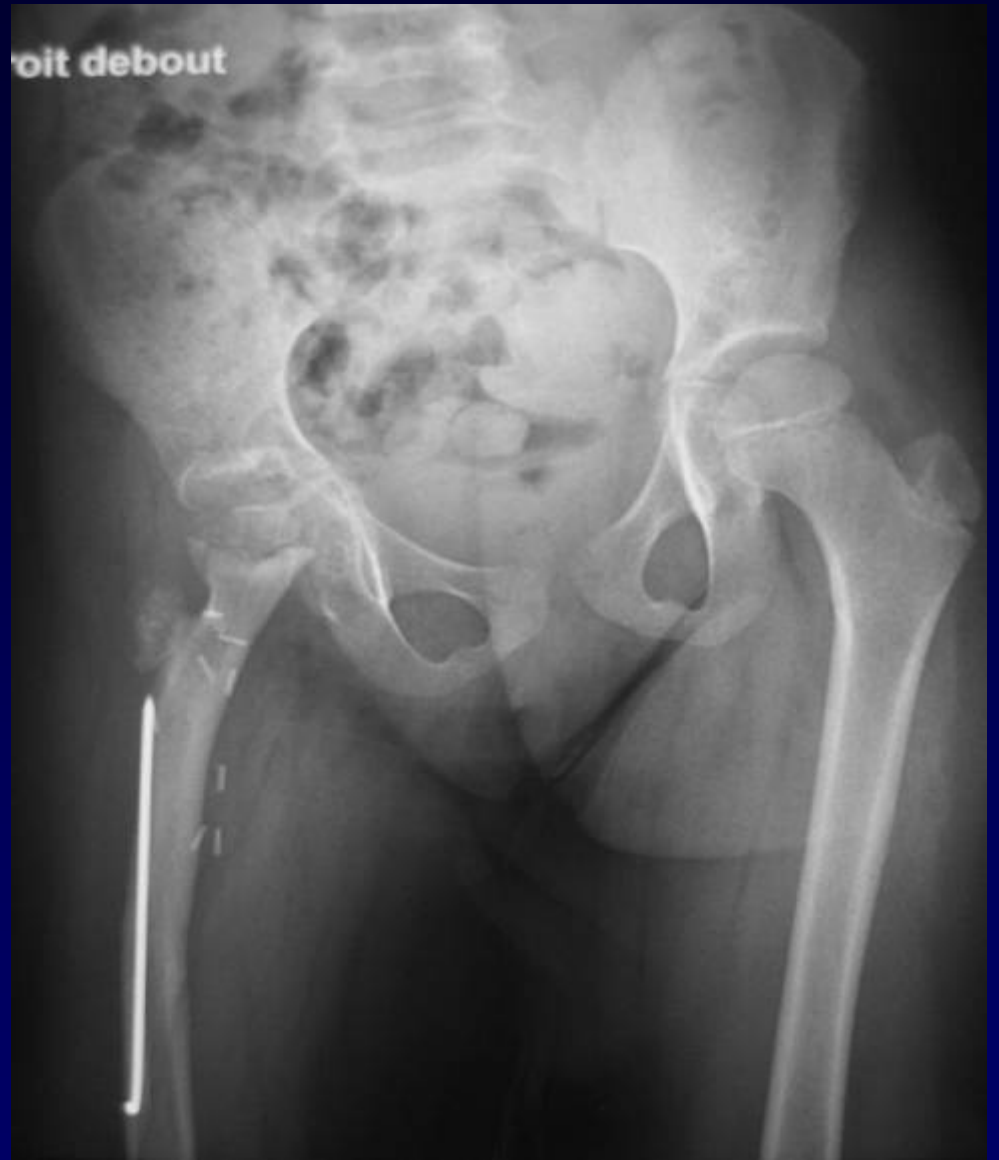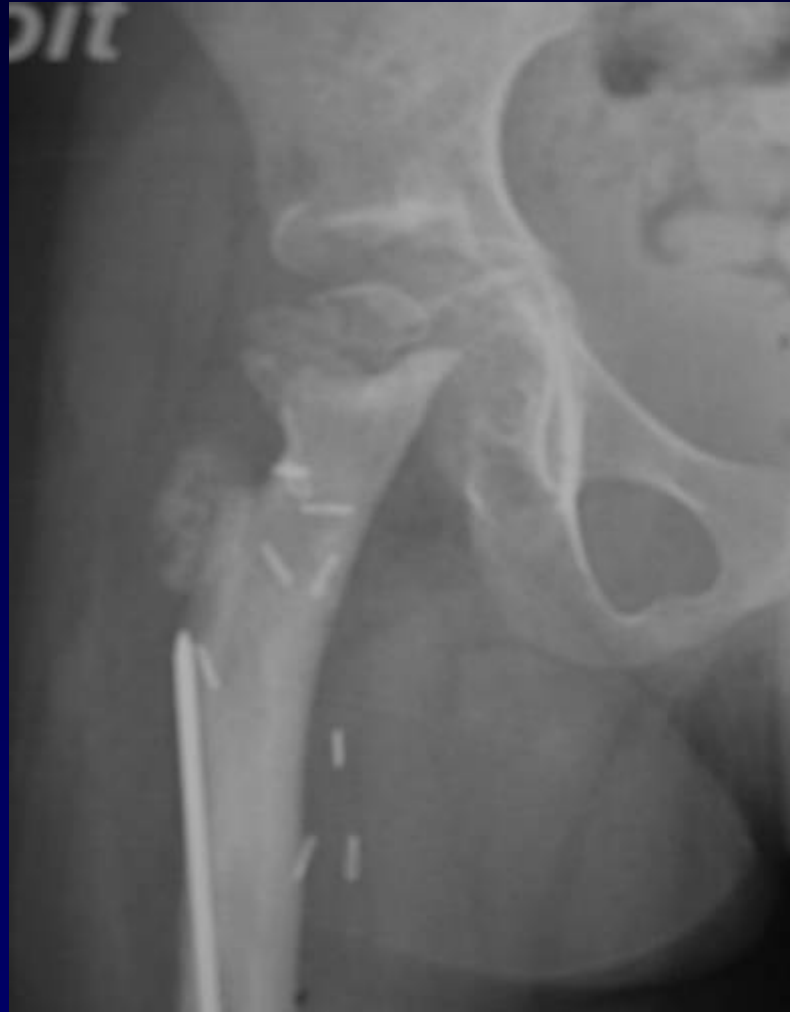$\theta = 0.3^\circ$

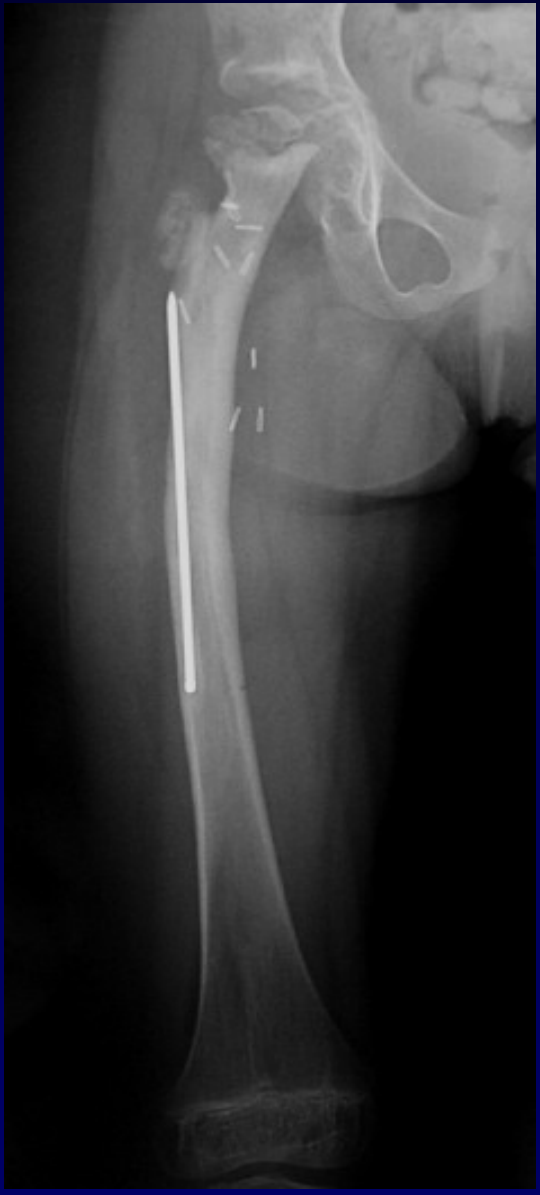

S1 = 99.5 mm

S2 = 110.1 mm










Allogreftes masivos

Reconstrucciones biológicas

- ✓ Autoinjerto
- ✓ Aloprotesis
- ✓ Aloinjerto



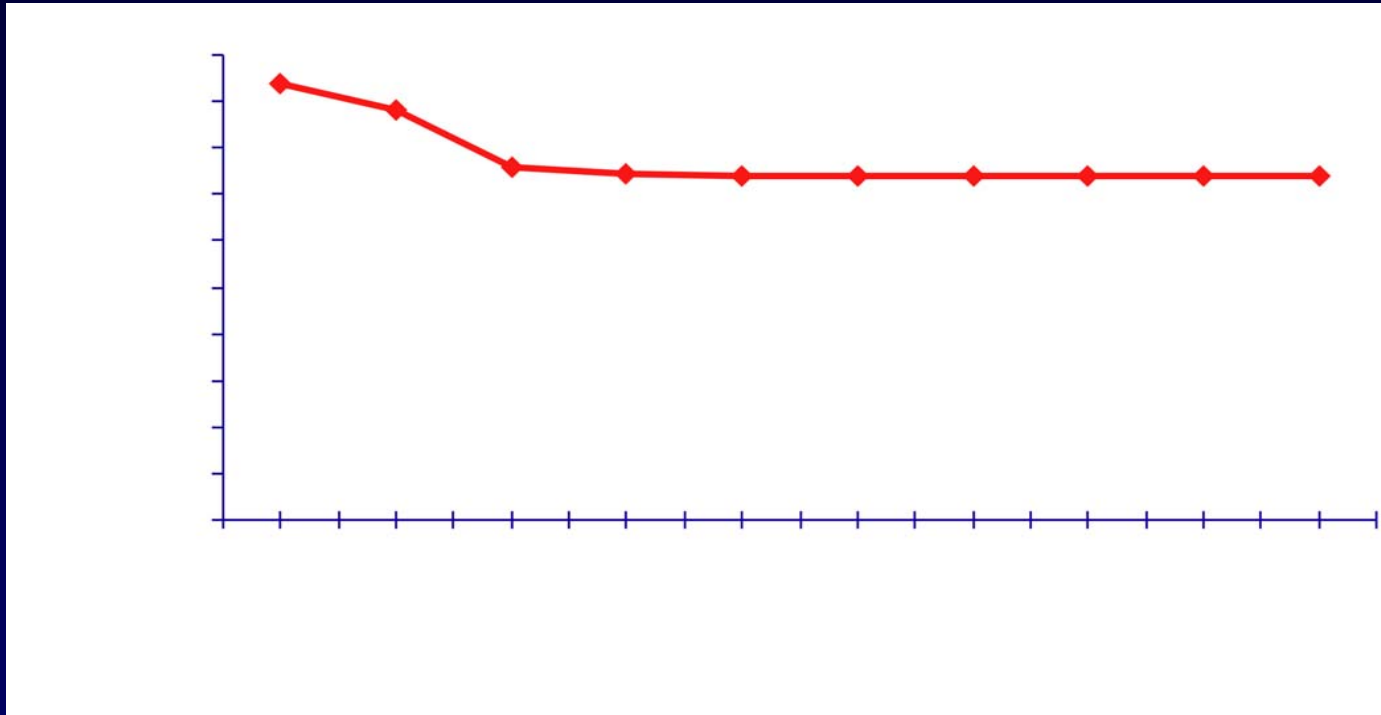
Aloinjerto osteoarticular

- **265 transplantes osteoarticulares realizados en el Hospital Italiano de Buenos Aires**
 - **134 Femur distal**
 - 97 bicondileos
 - 37 hemicondileos
 - **69 Tibia proximal**
 - 58 bicondileos
 - 11 hemicondileos
 - **62 Otras localizaciones**



Sobrevida (Kaplan-Meier)

74% a los 5 años (IC 95% 63 - 81)

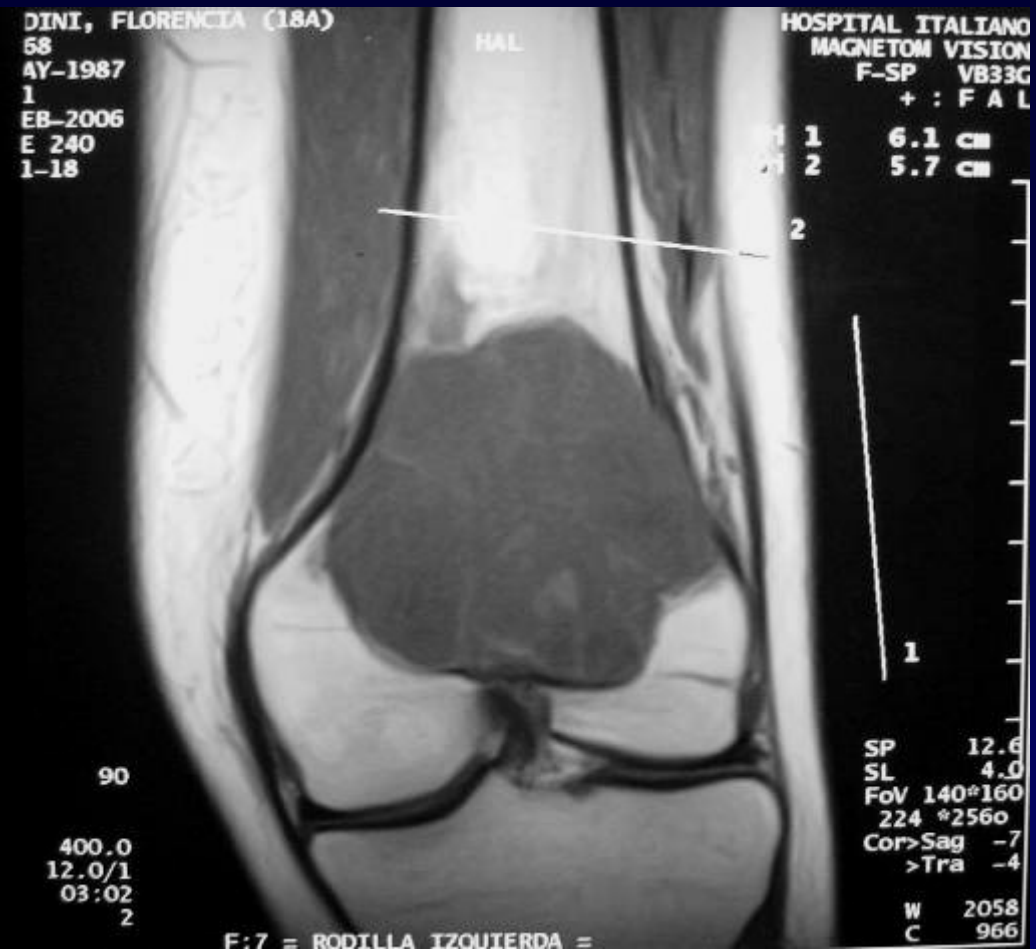
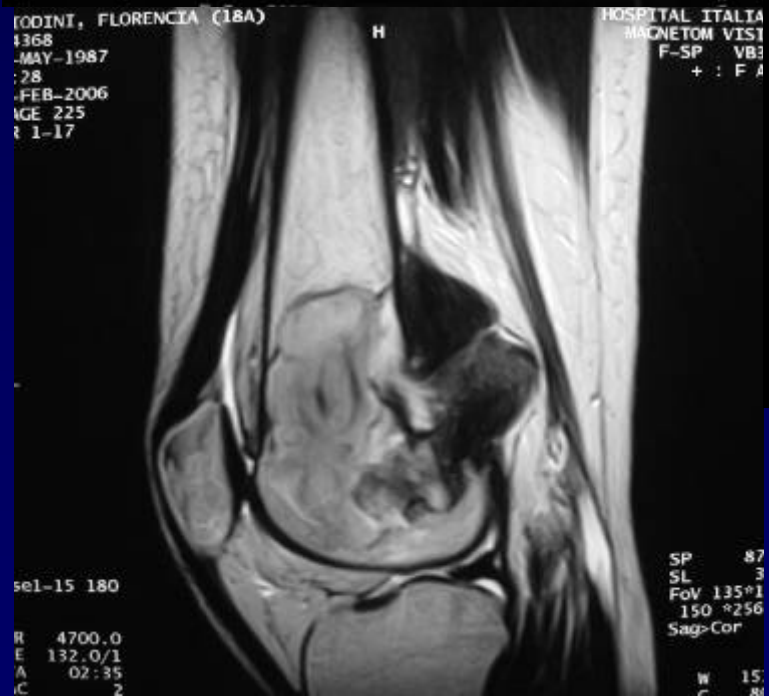
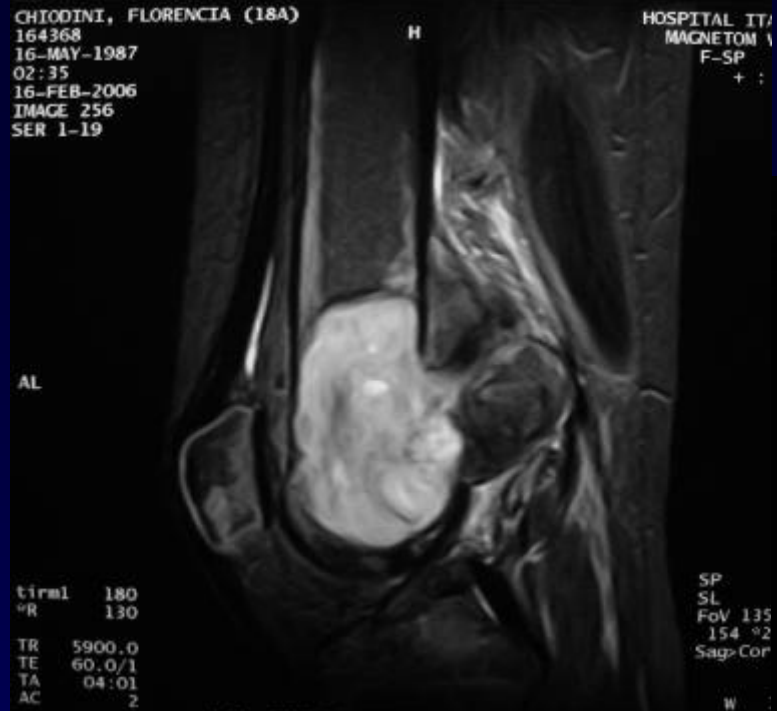Survivorship and radiographic analysis of knee osteoarticular allografts. Muscolo DL, Ayerza M y Aponte-Tinao L.

Clin Orthop 373:73-79, 2000.



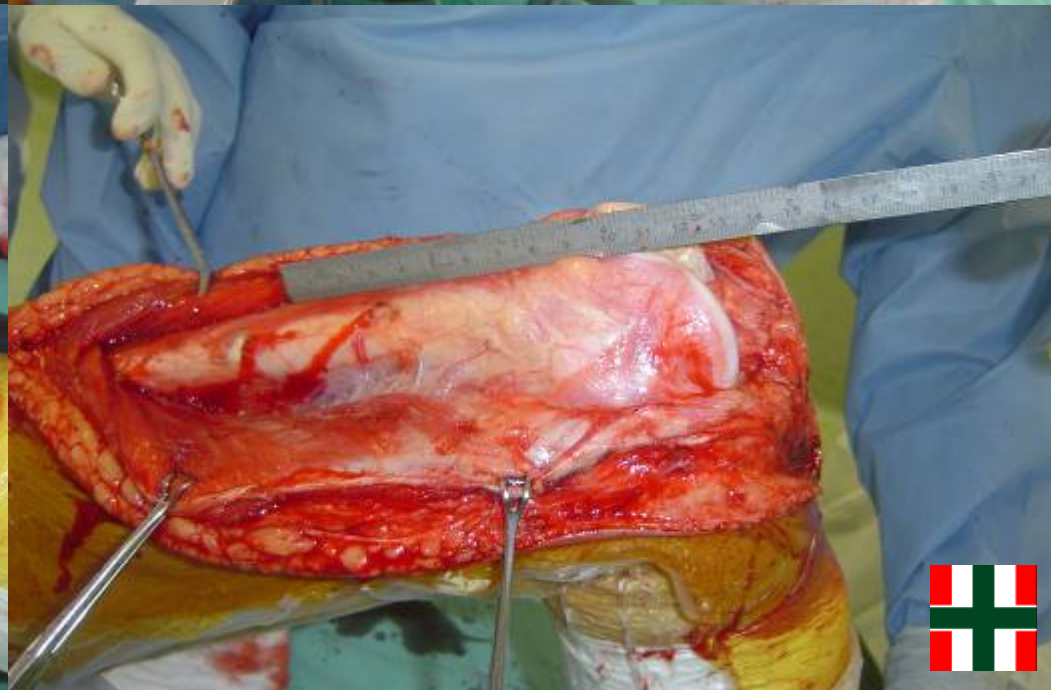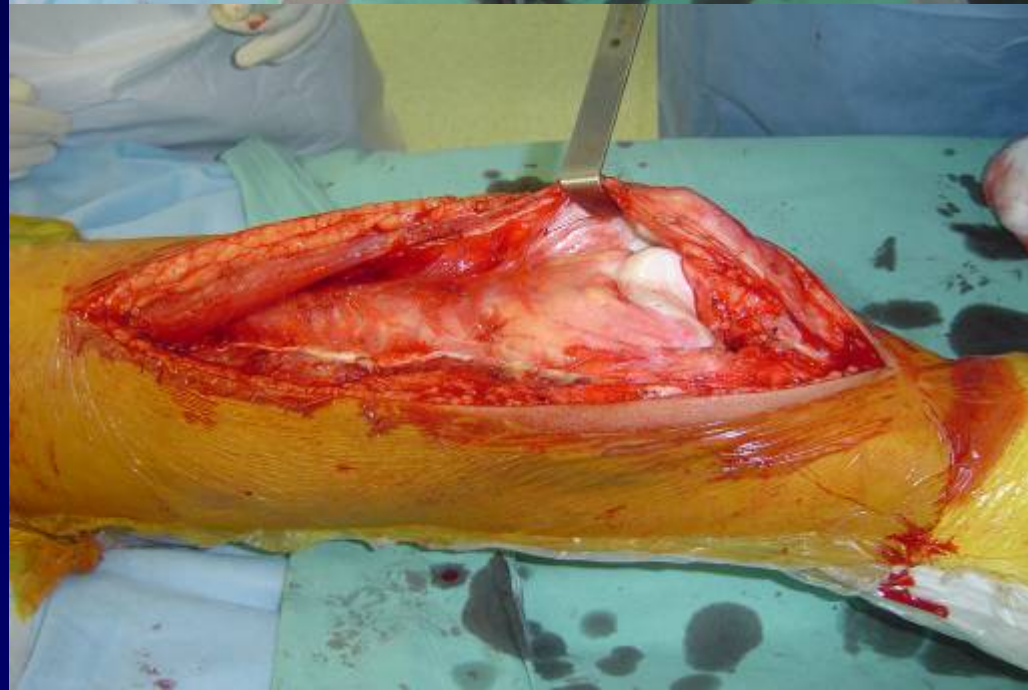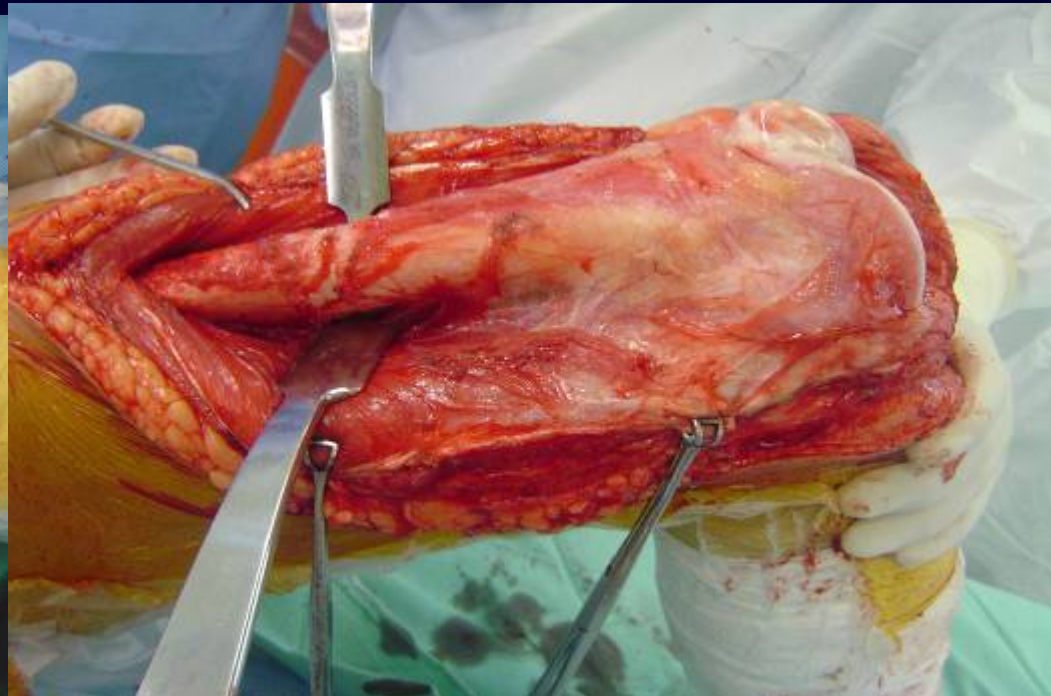
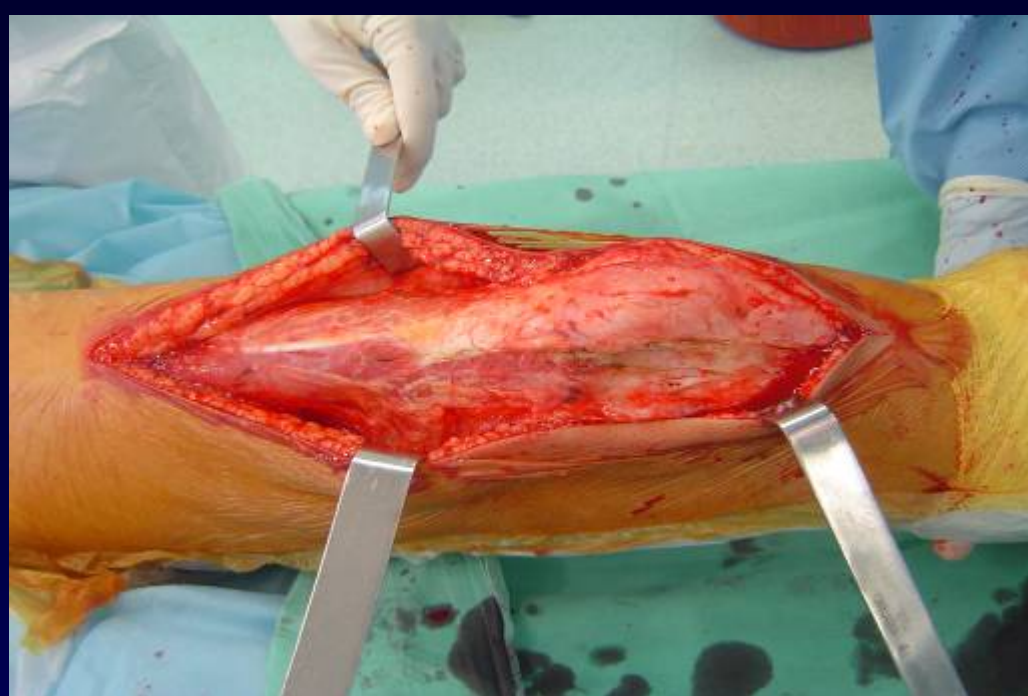Femur distal

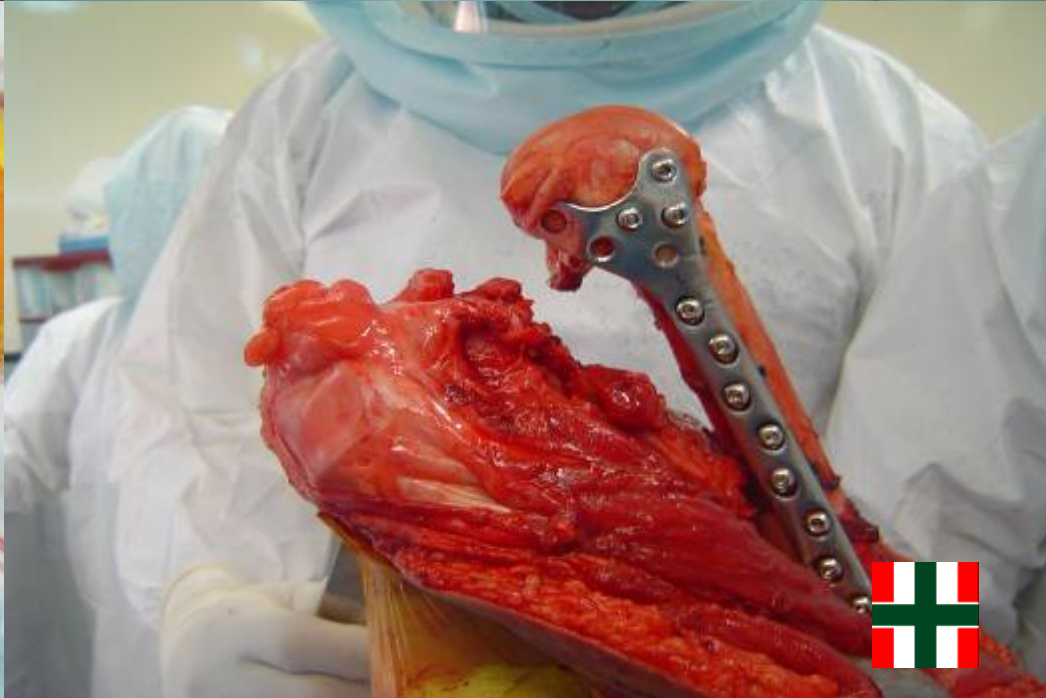
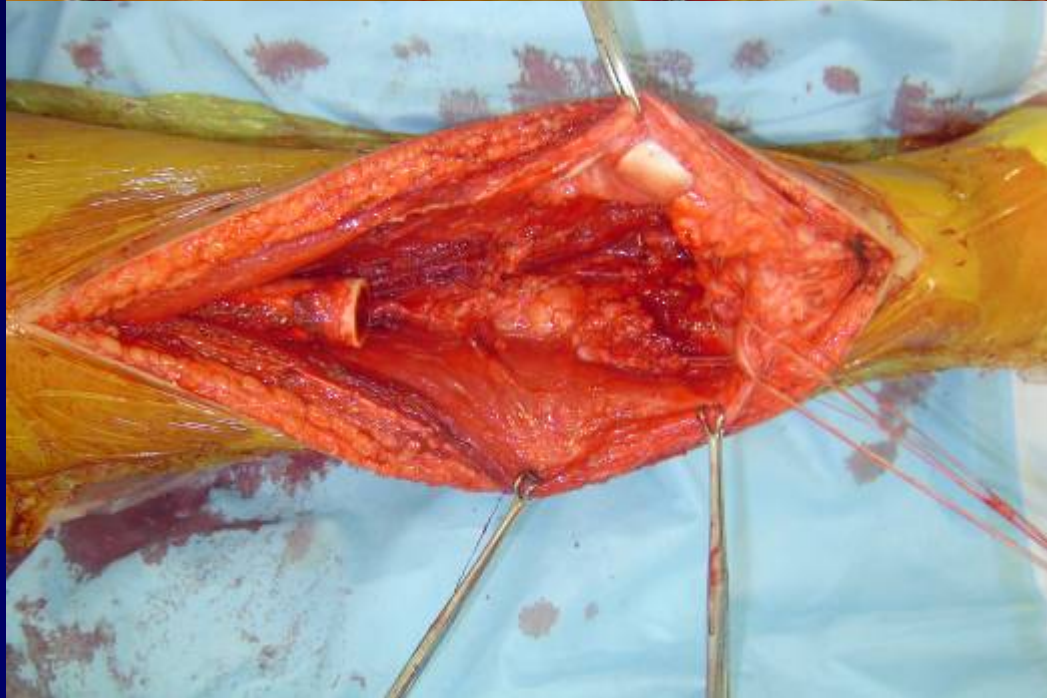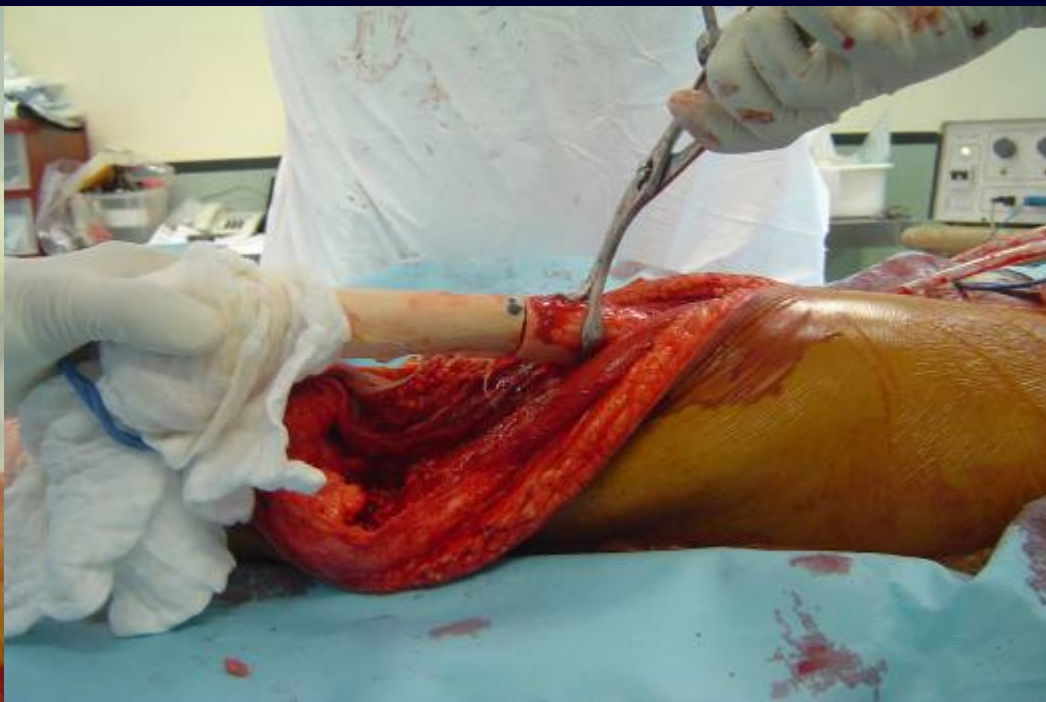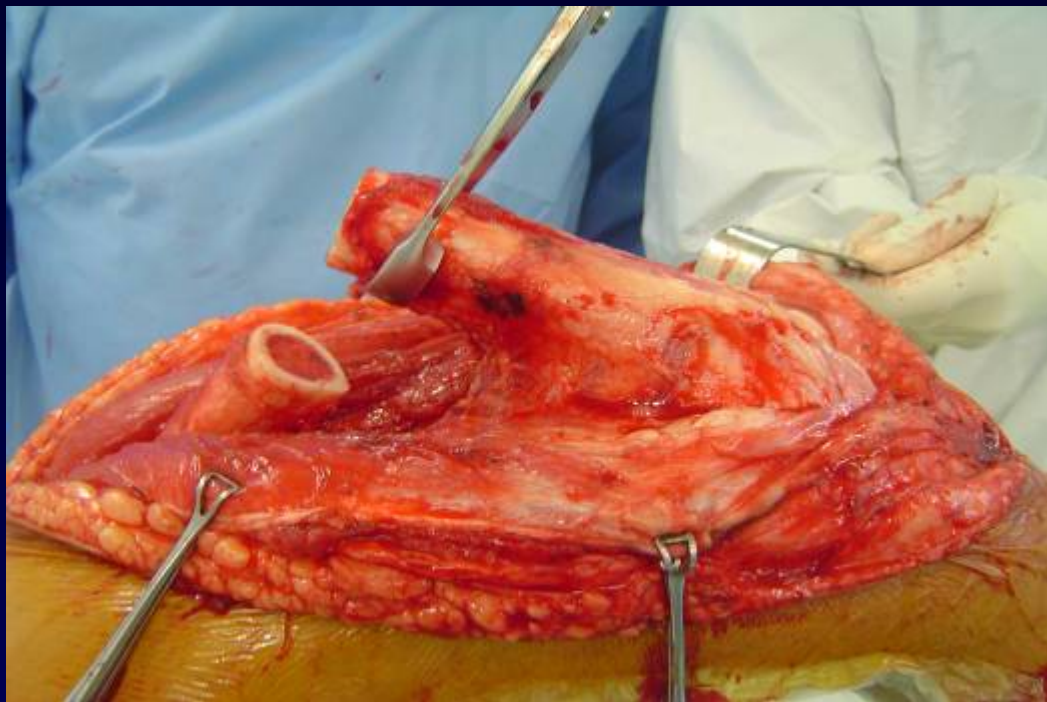


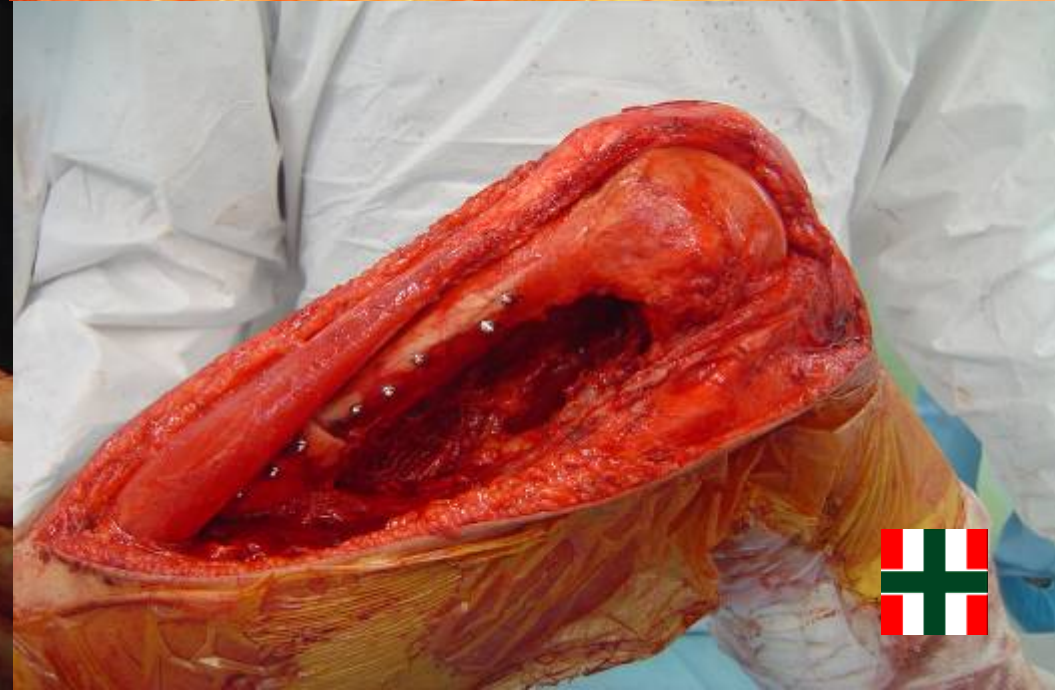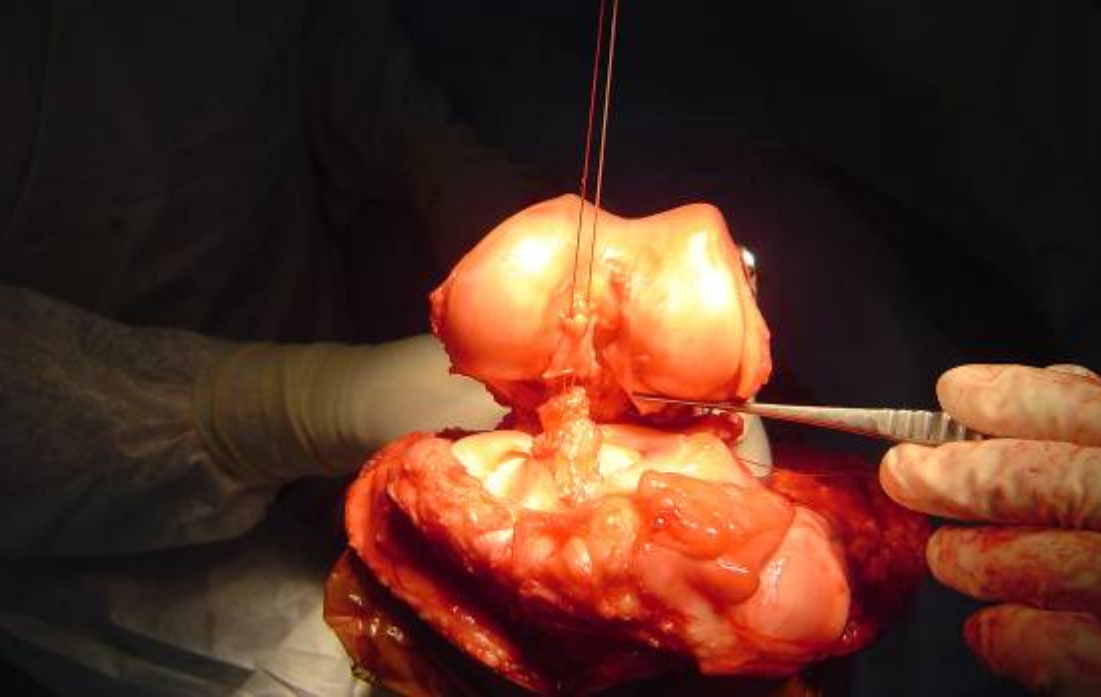
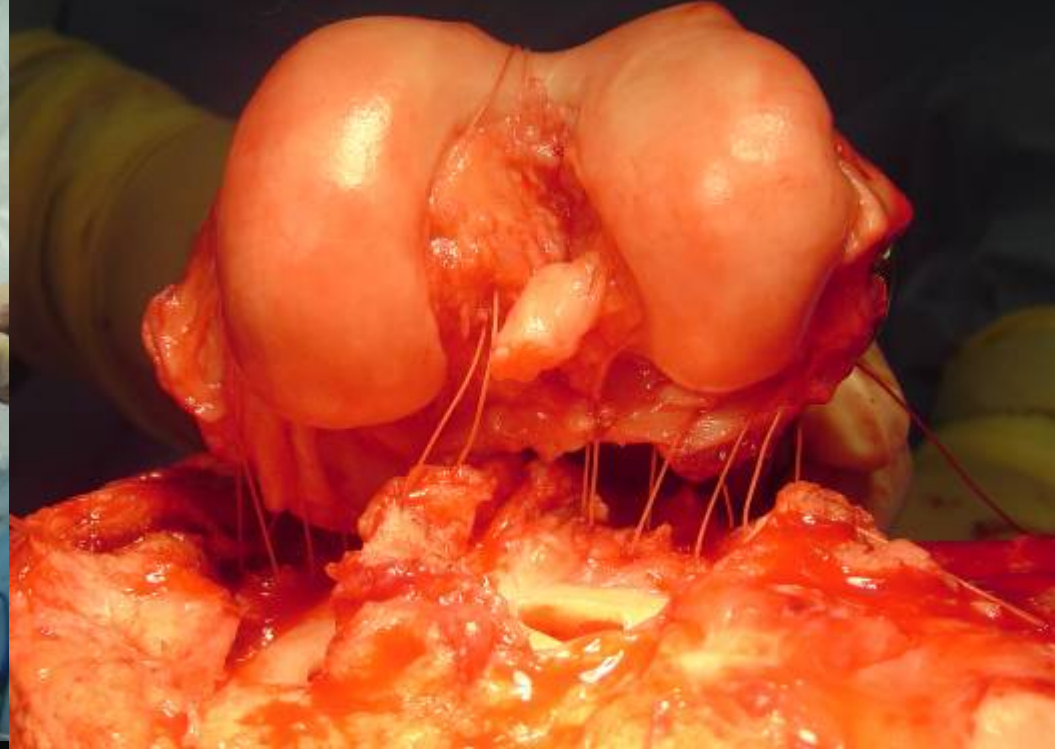
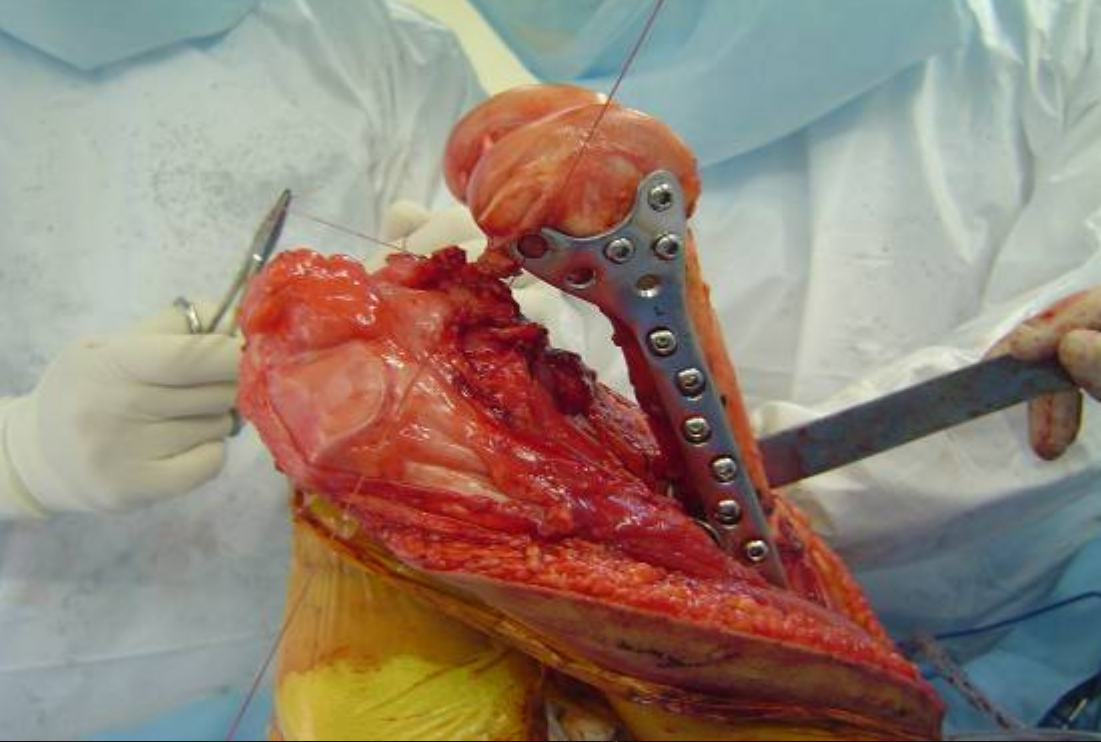
Surgical Technique. Muscolo DL, Ayerza M, Aponte-Tinao L y col.

Journal of Bone and Joint Surgery Am, Sept 2006.

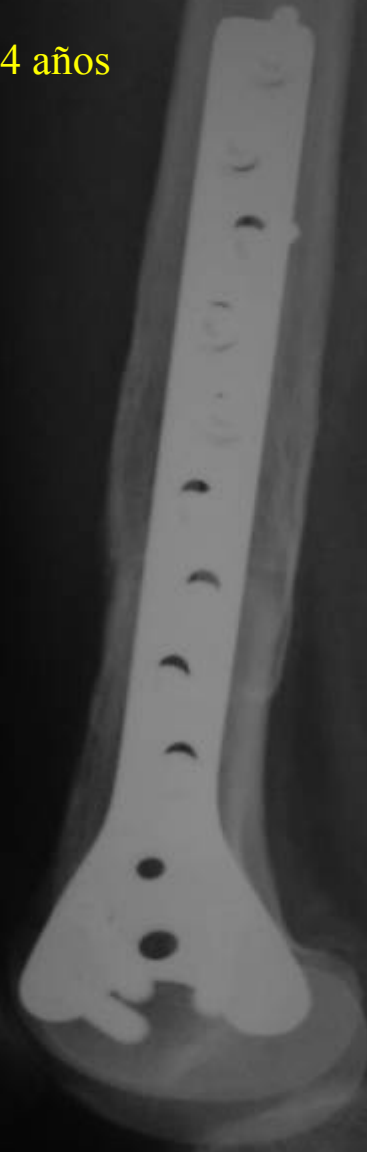








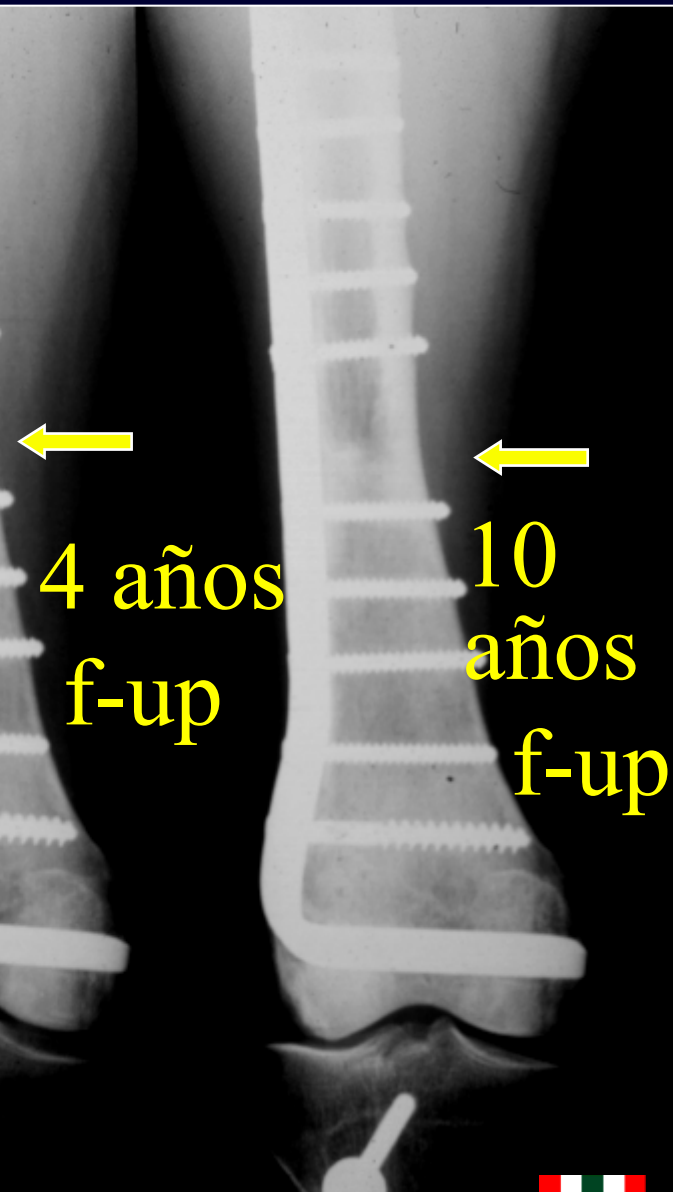
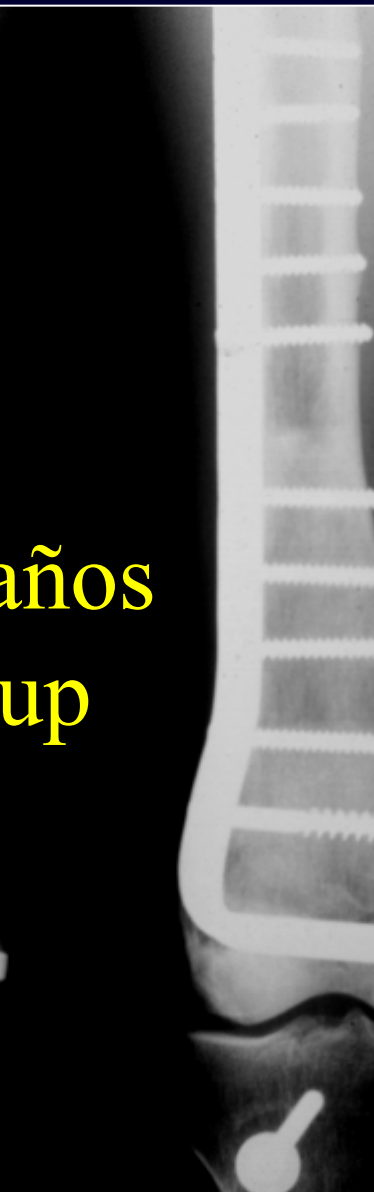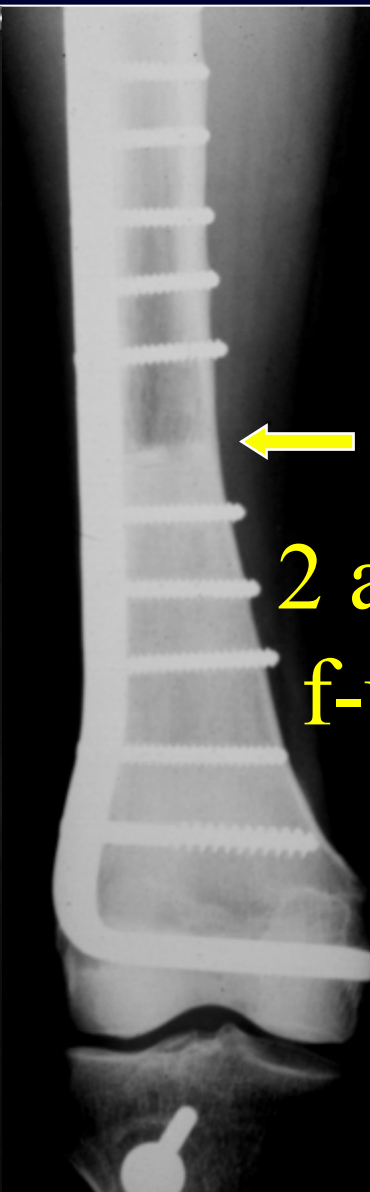
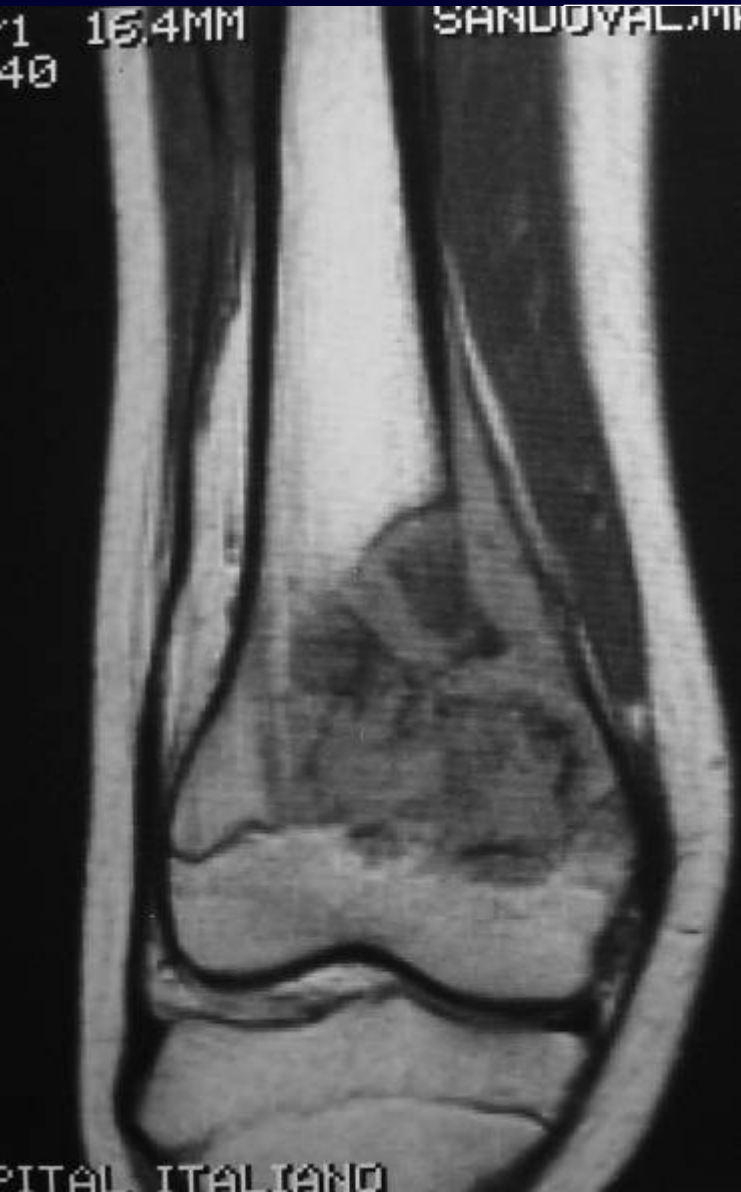Osteosarcoma multicentrico 14 años



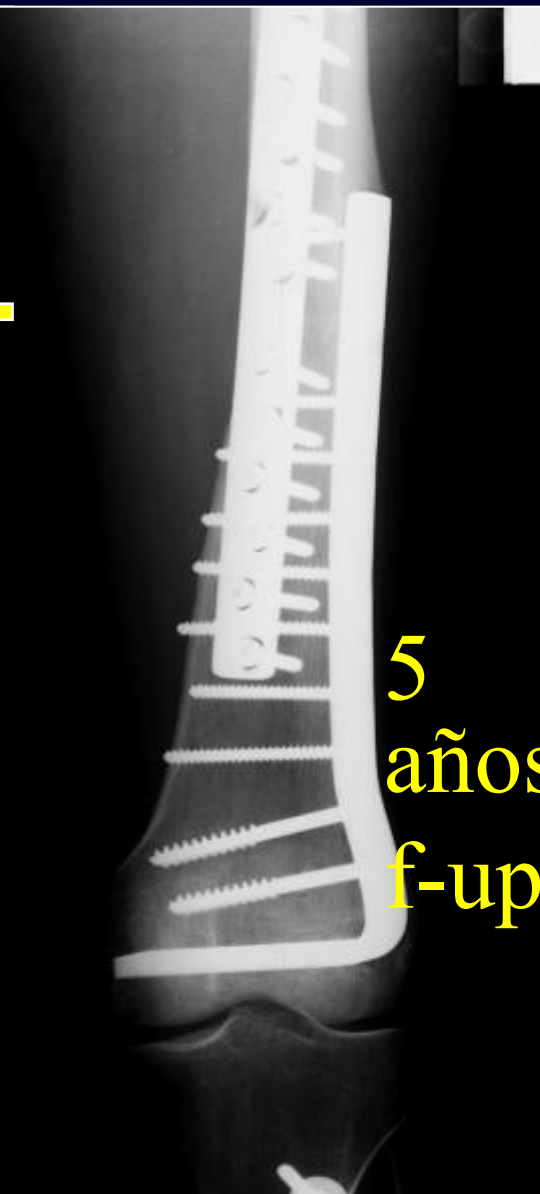
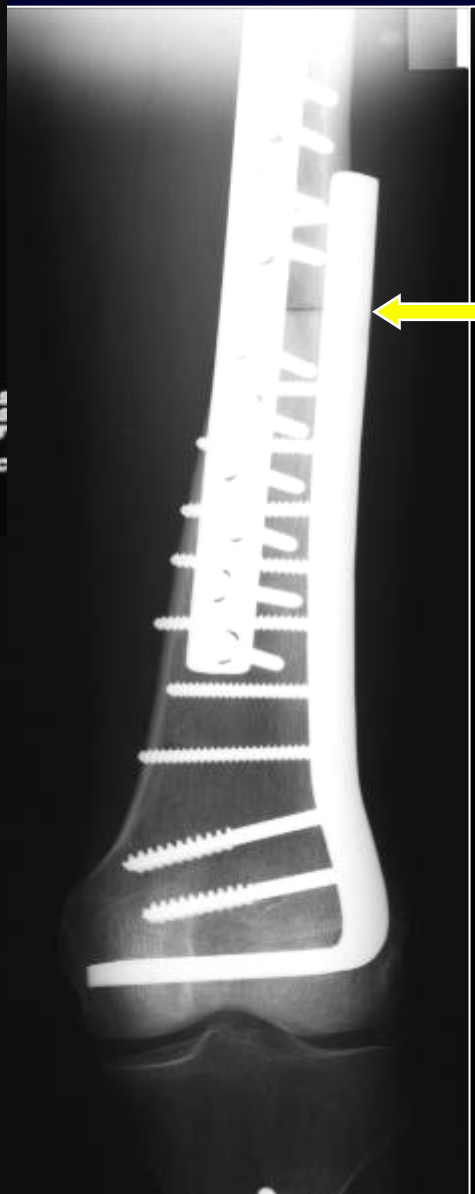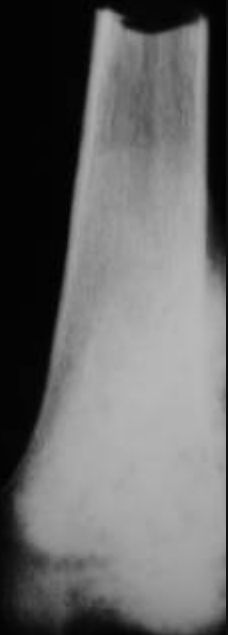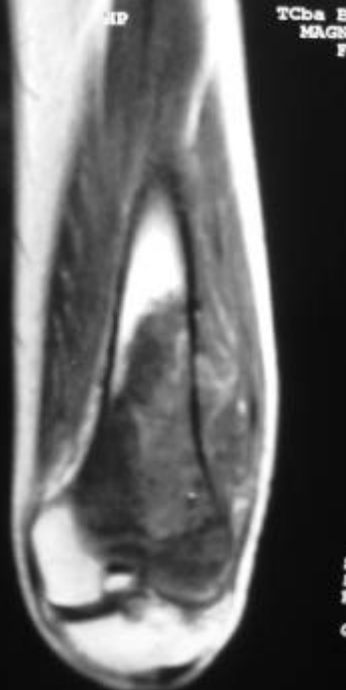4 años
Pop



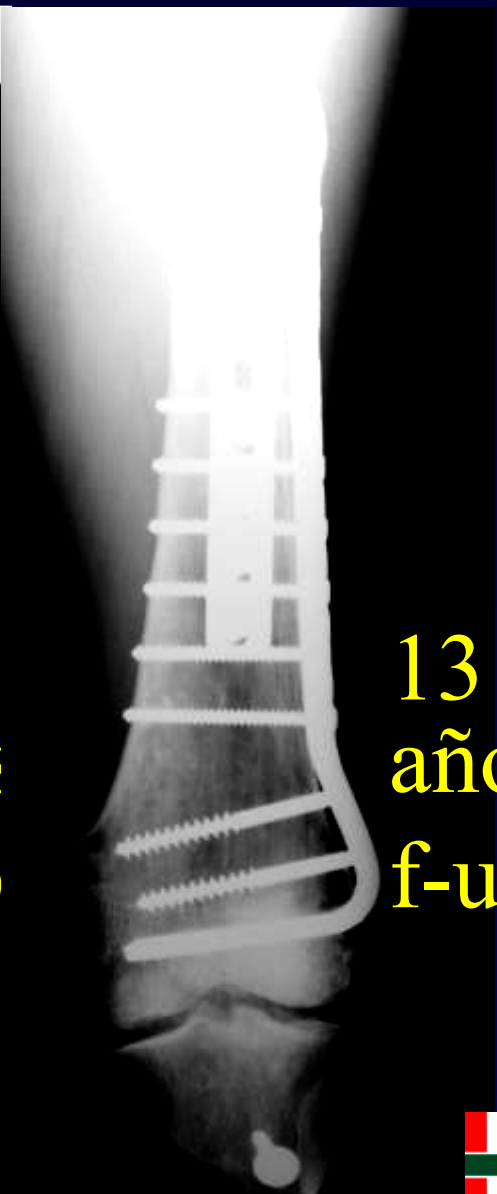
Osteosarcoma 12 años



Osteosarcoma 17 años

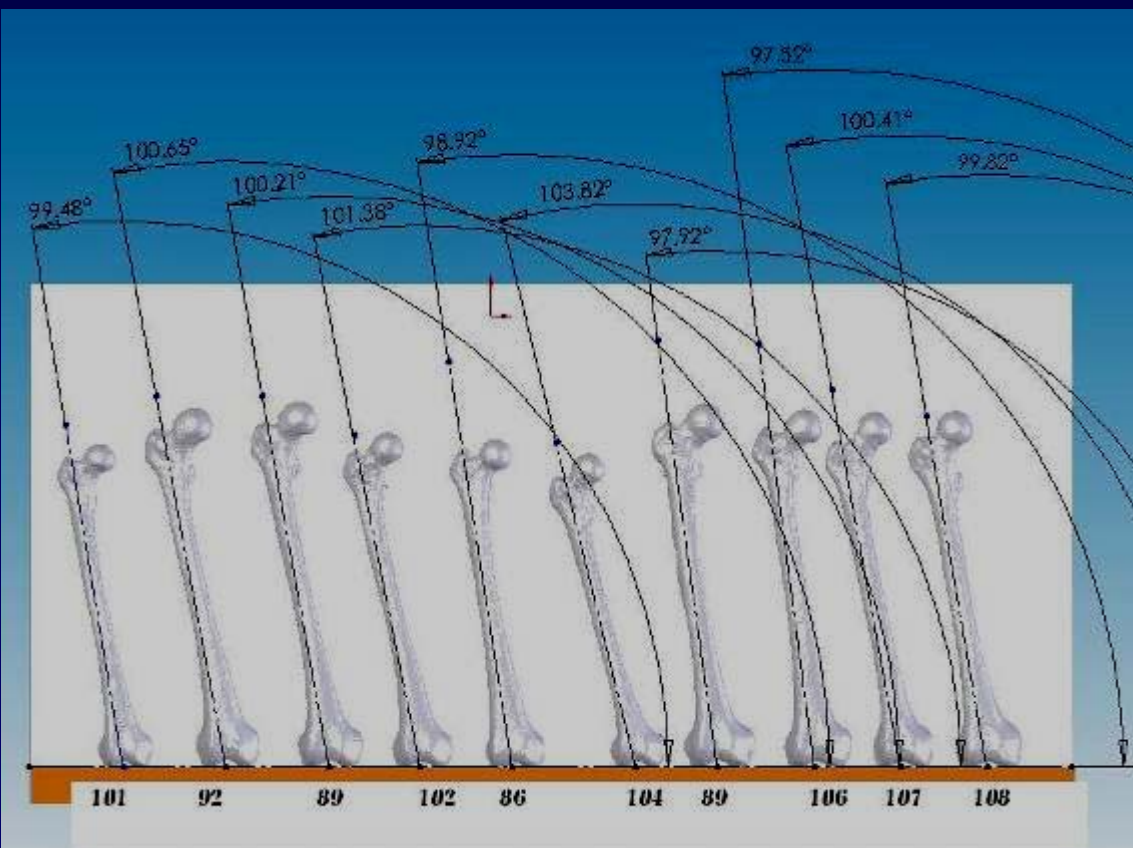
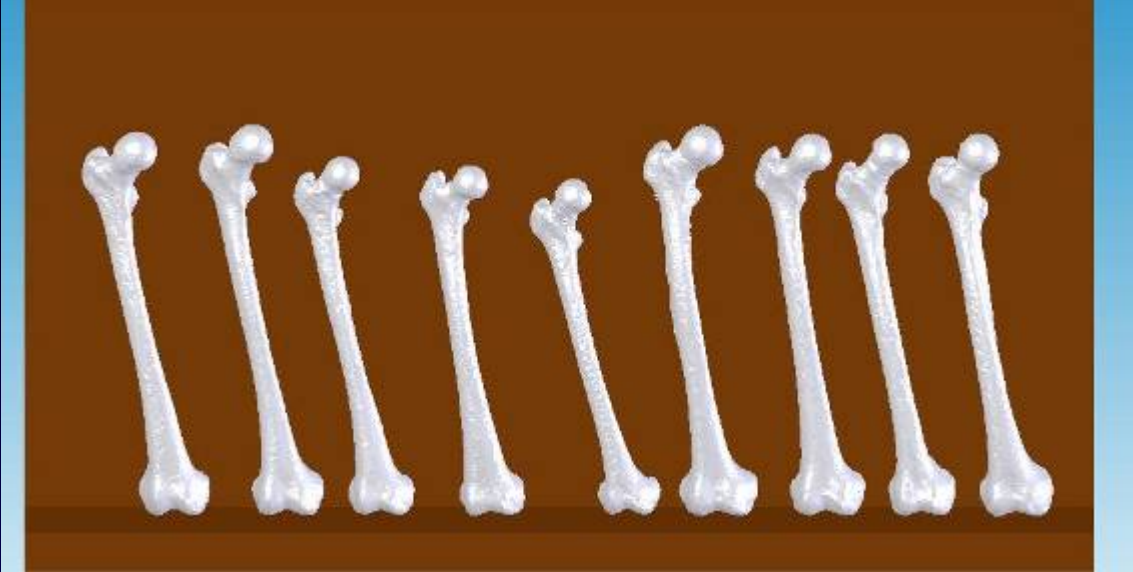


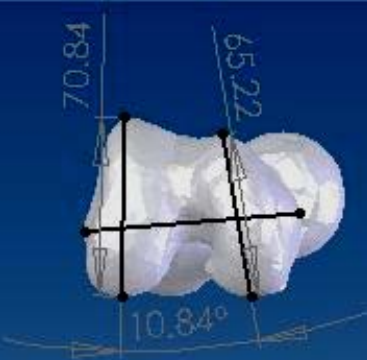
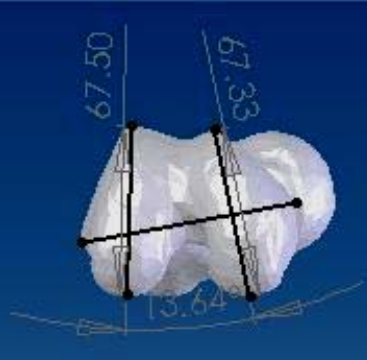

5 años
f-up

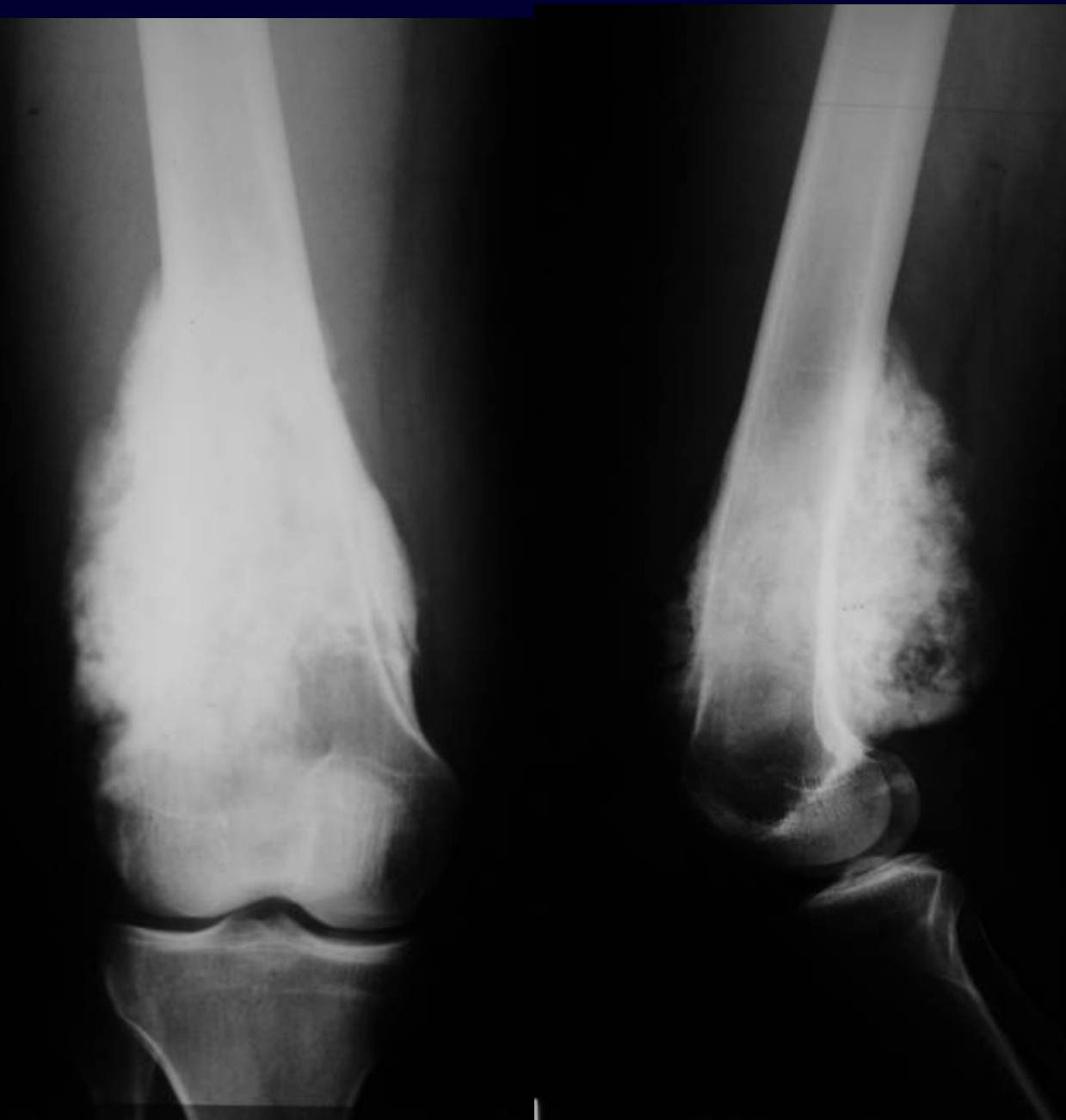

13 años
f-up







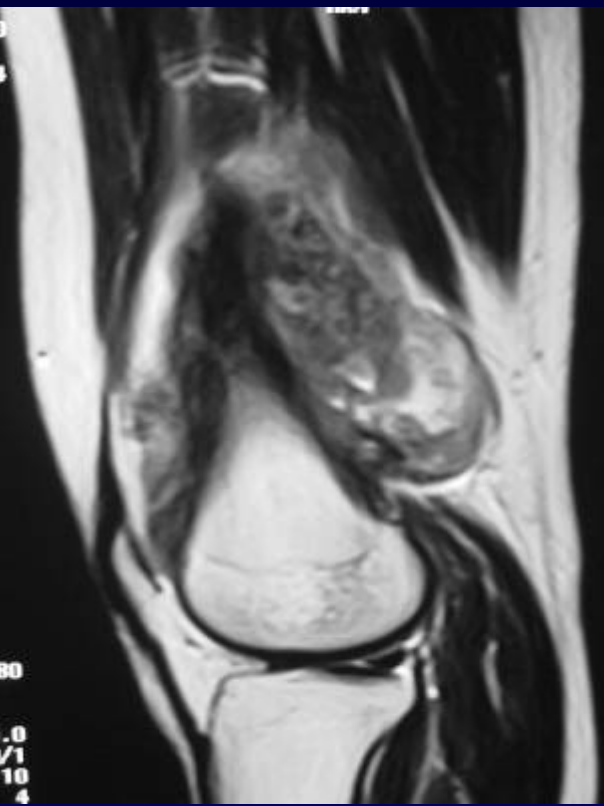

37330
3-FEB-1980
5:17
5-AUG-2004
MAGE 279
ER 1-23

F 1.33

AL

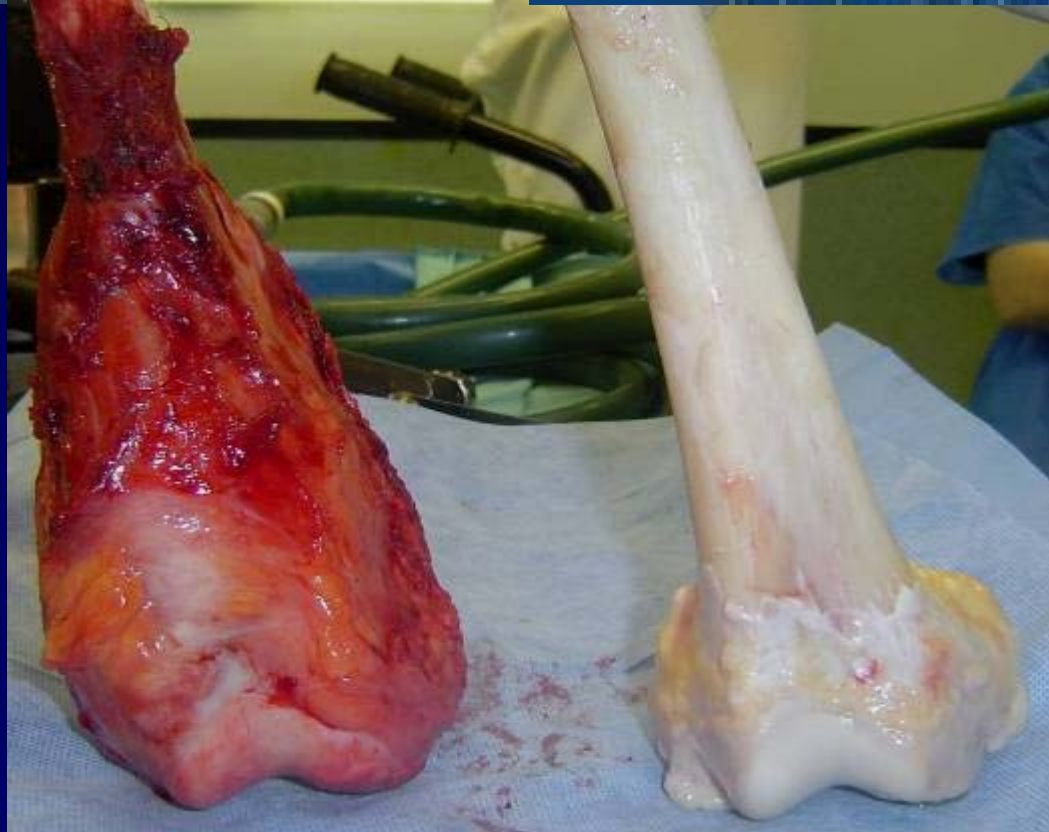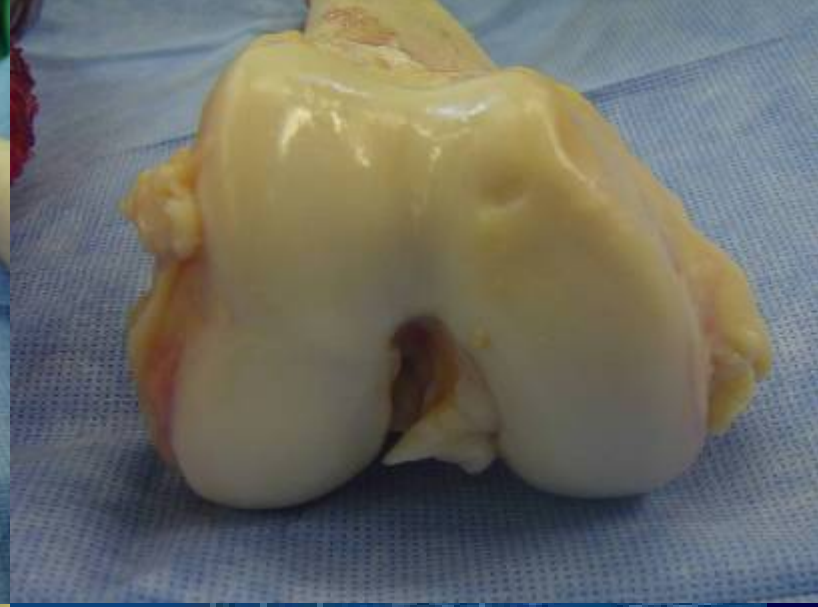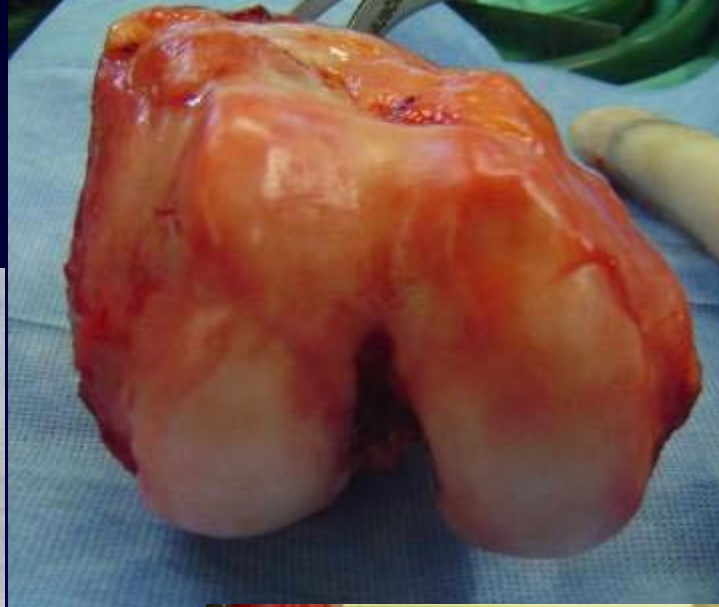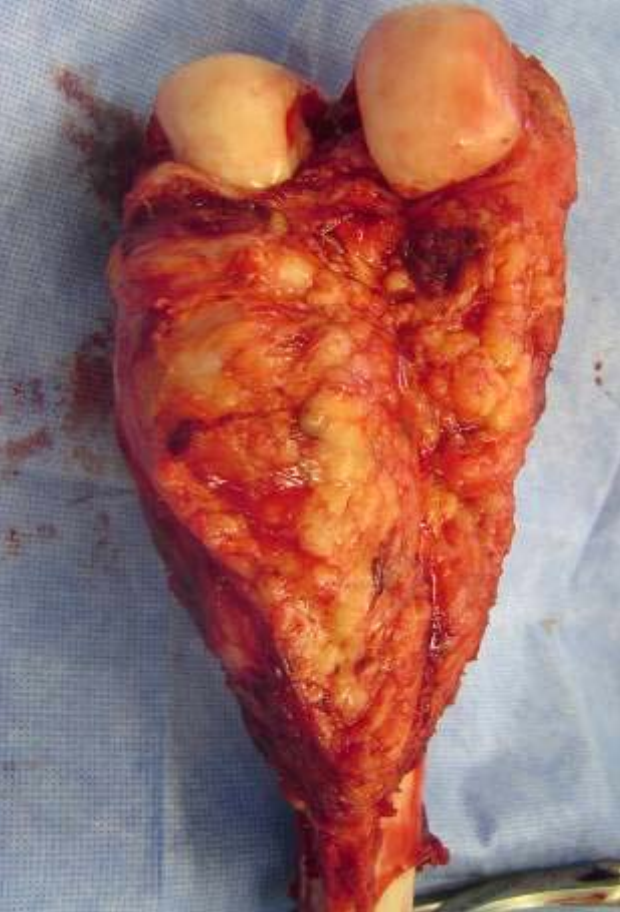tse2-9 180
* I D
TR 4400.0
TE 83.0/1
TA 04:10
AC 4

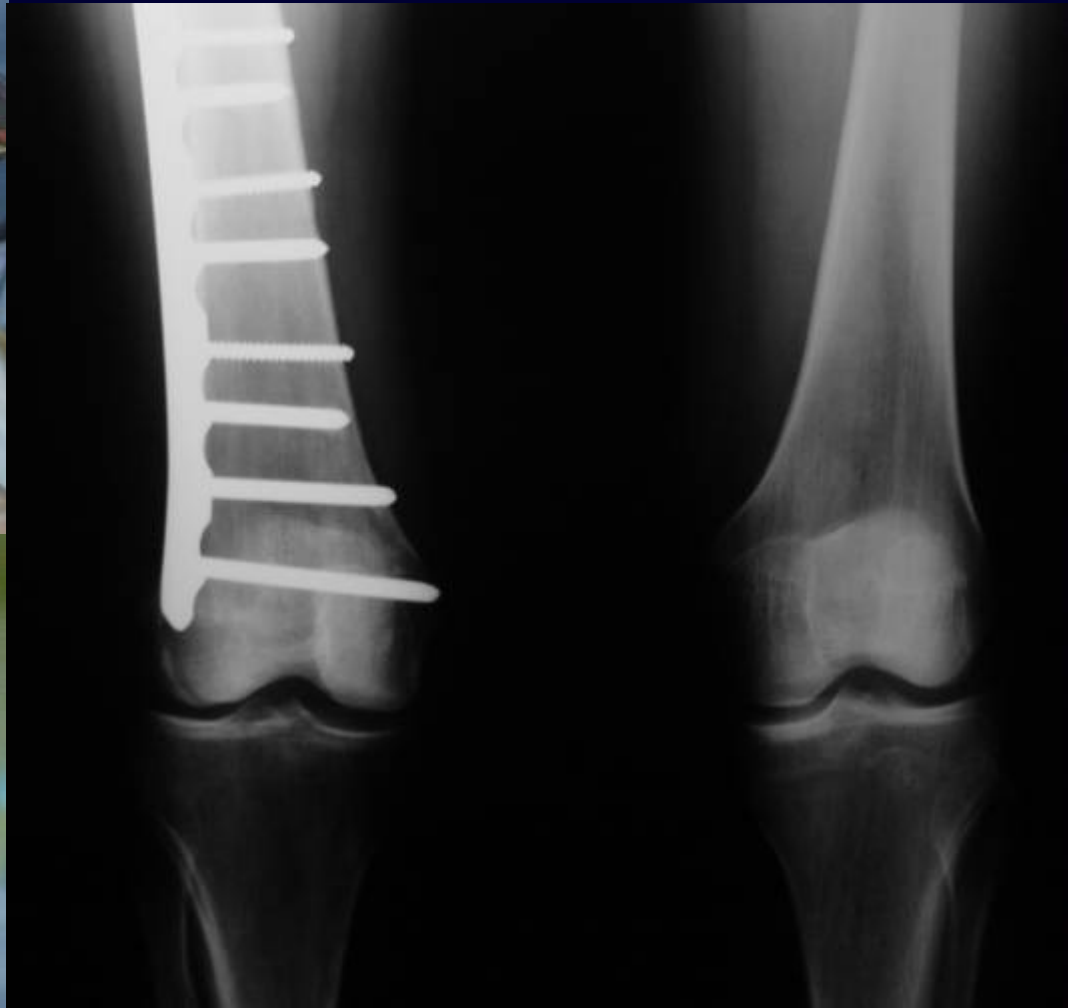
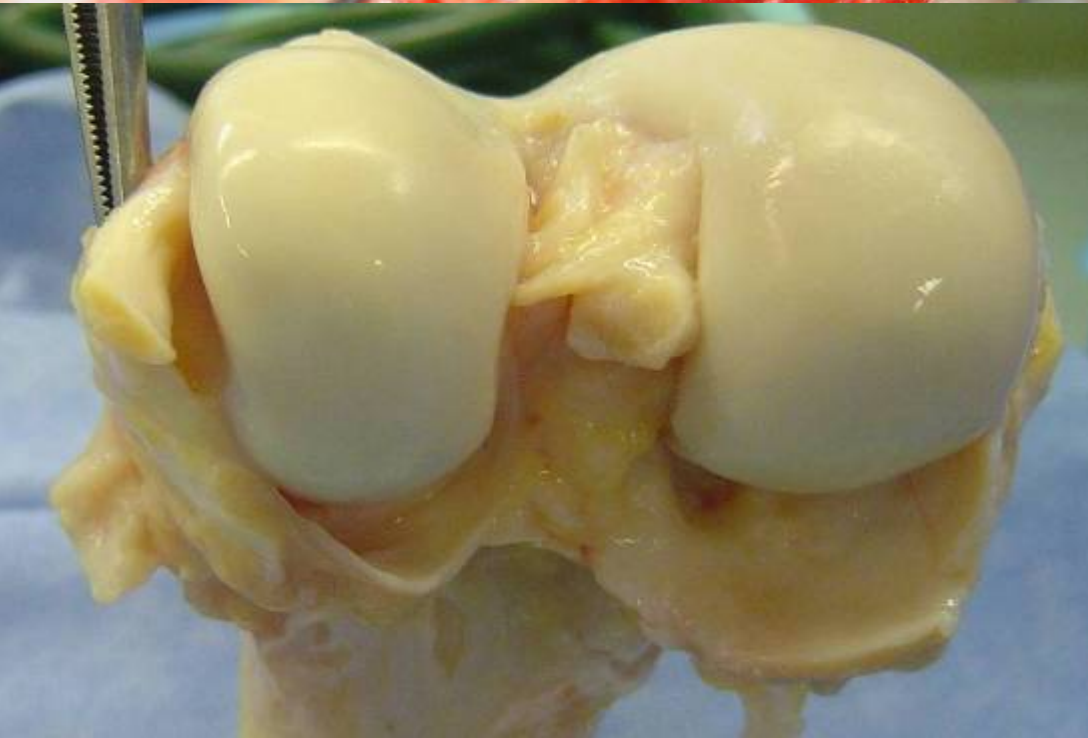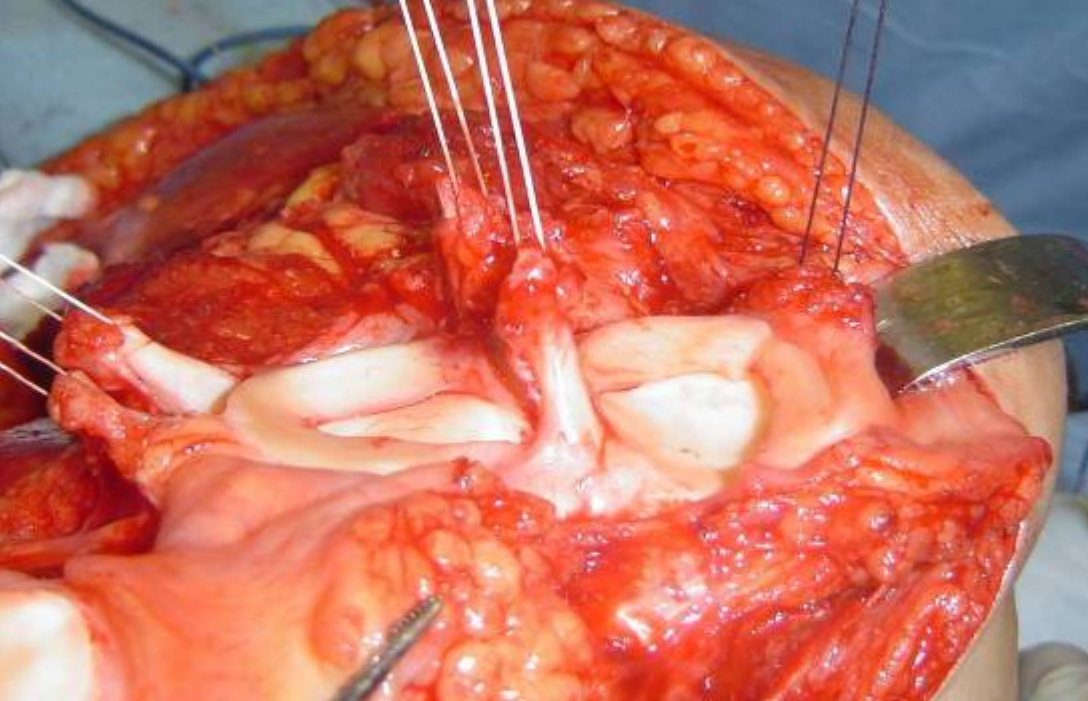


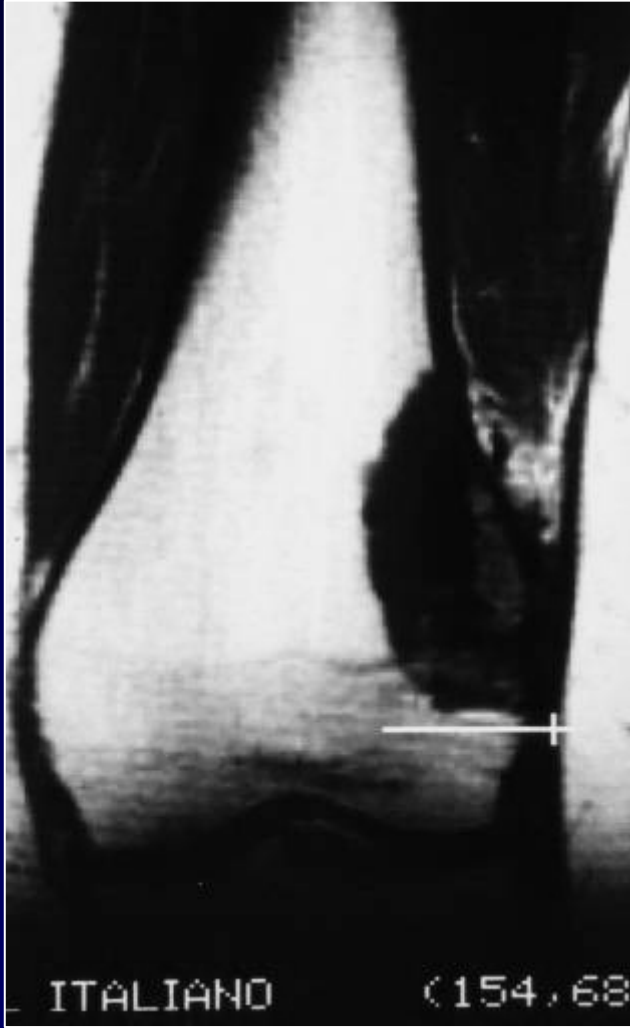MAGNETOM VISION
F-SP VE3
+ : F A

SP -70
SL 5
FoV 206*3
126 *256
SagCor
>Tra
W 11
C 6

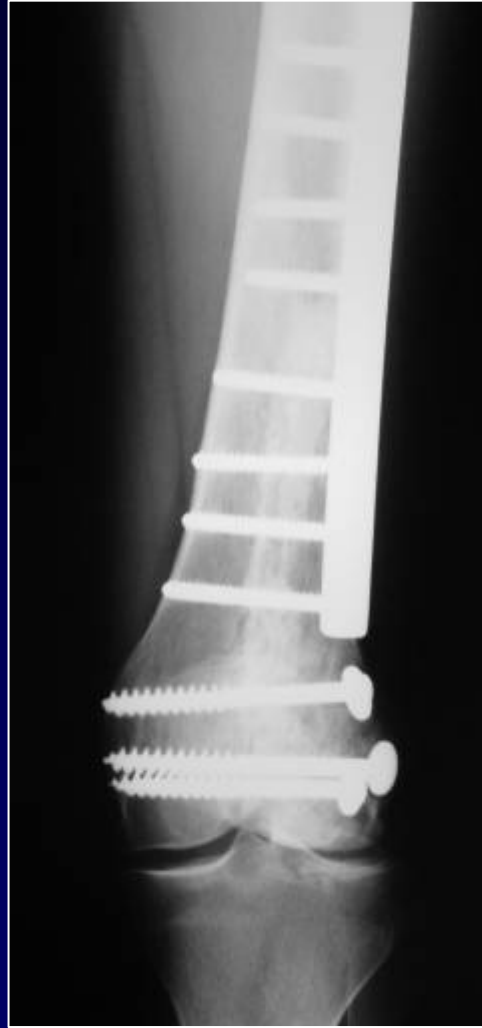






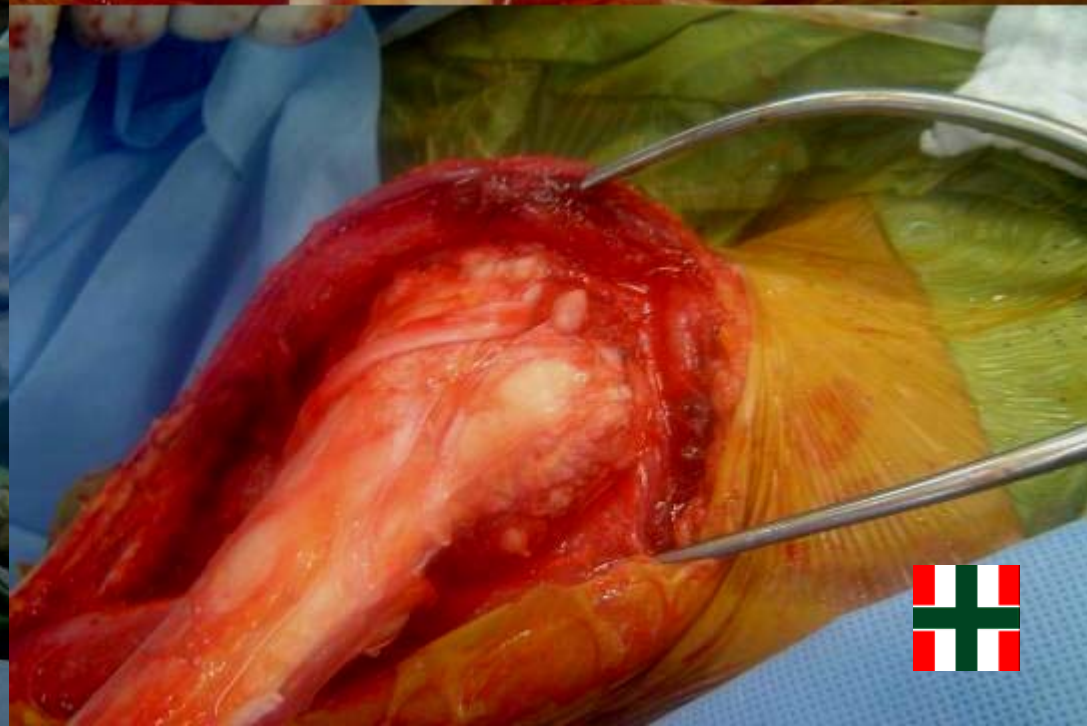
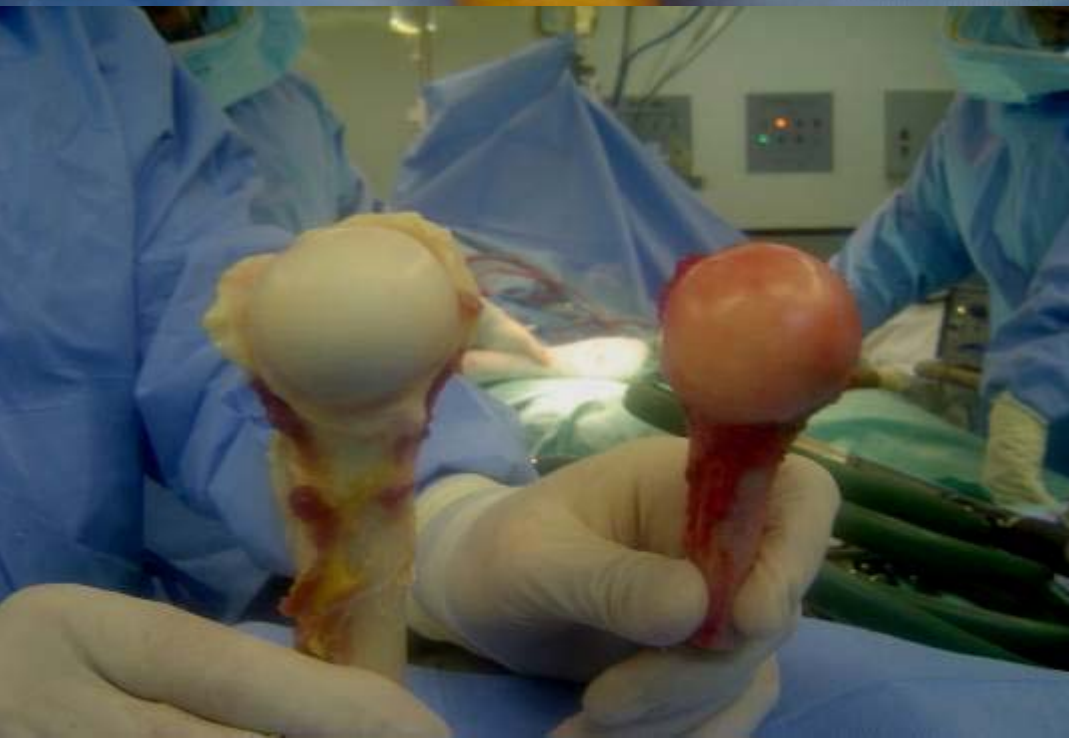
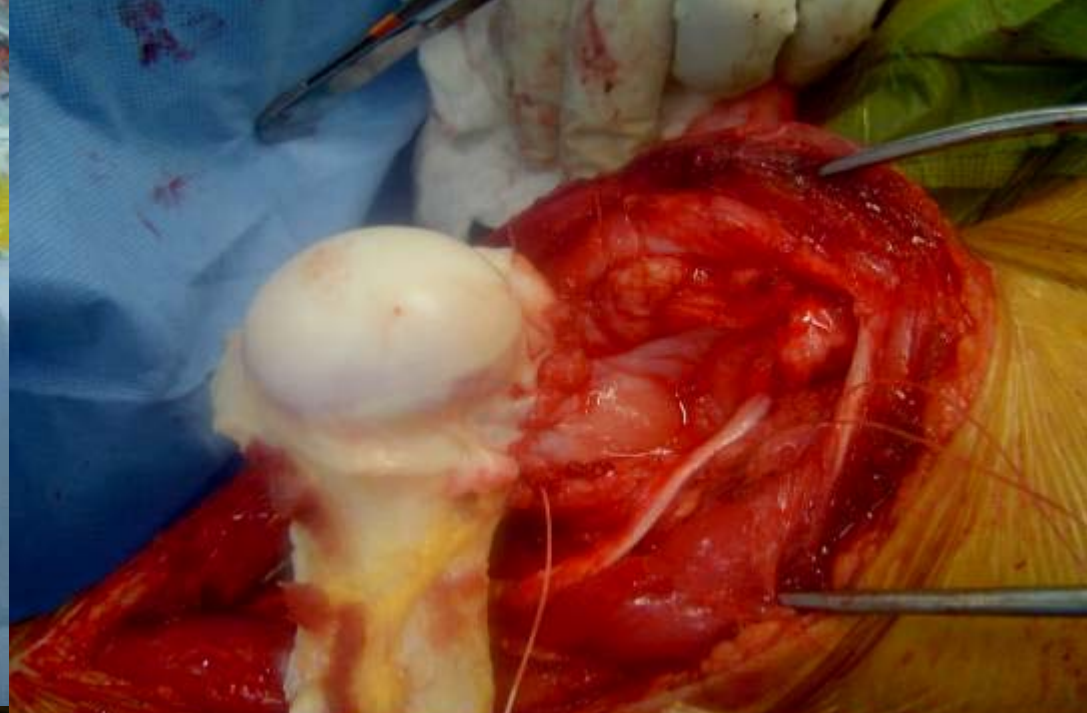
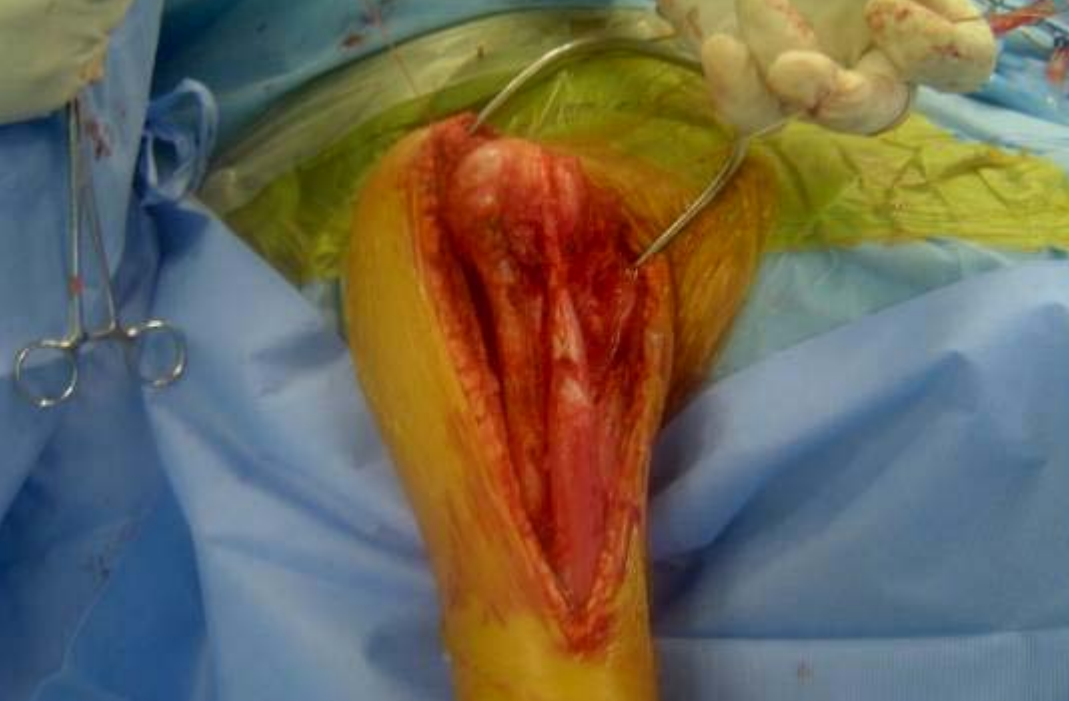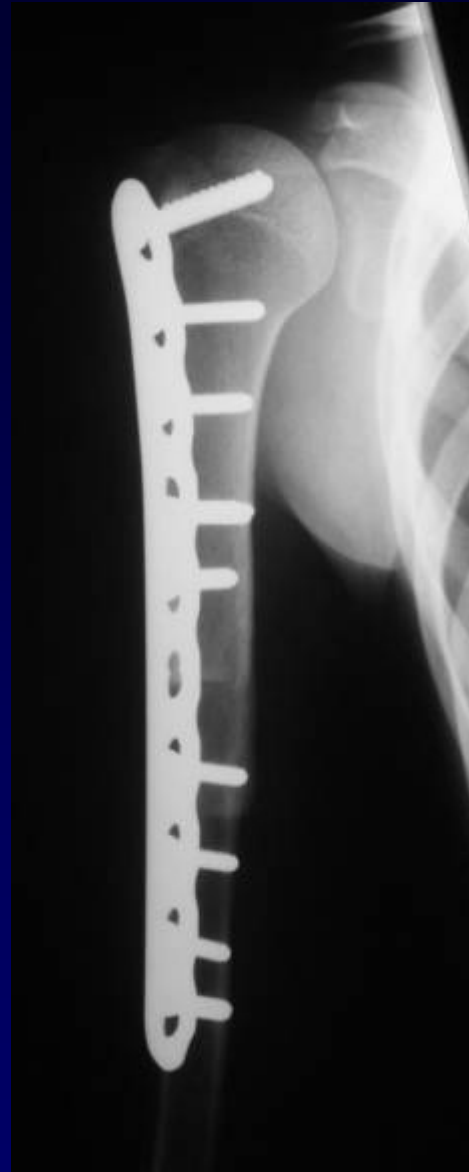
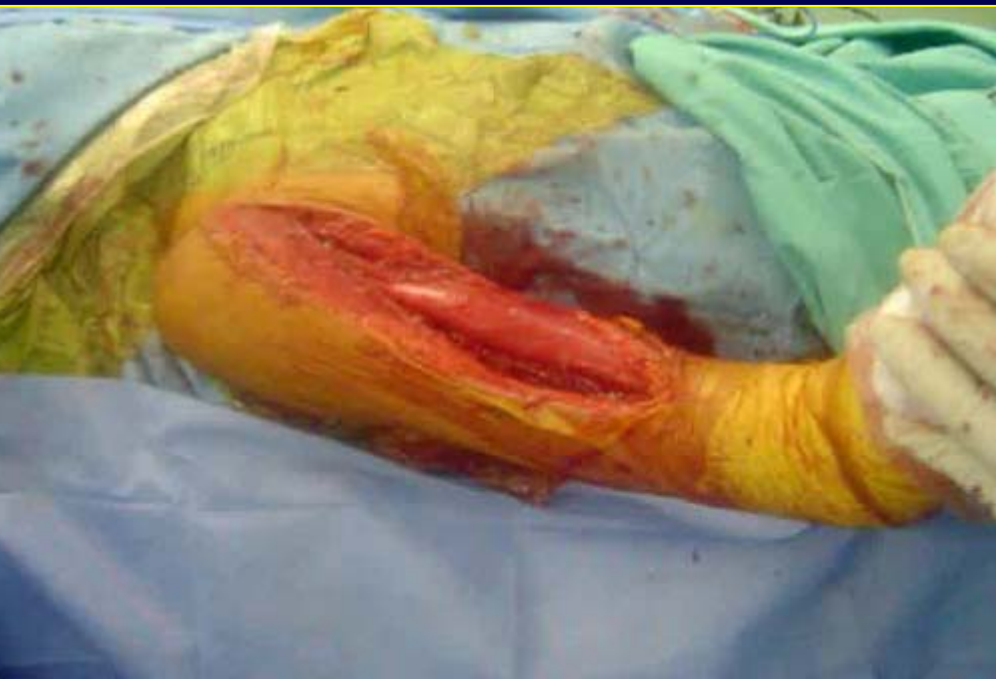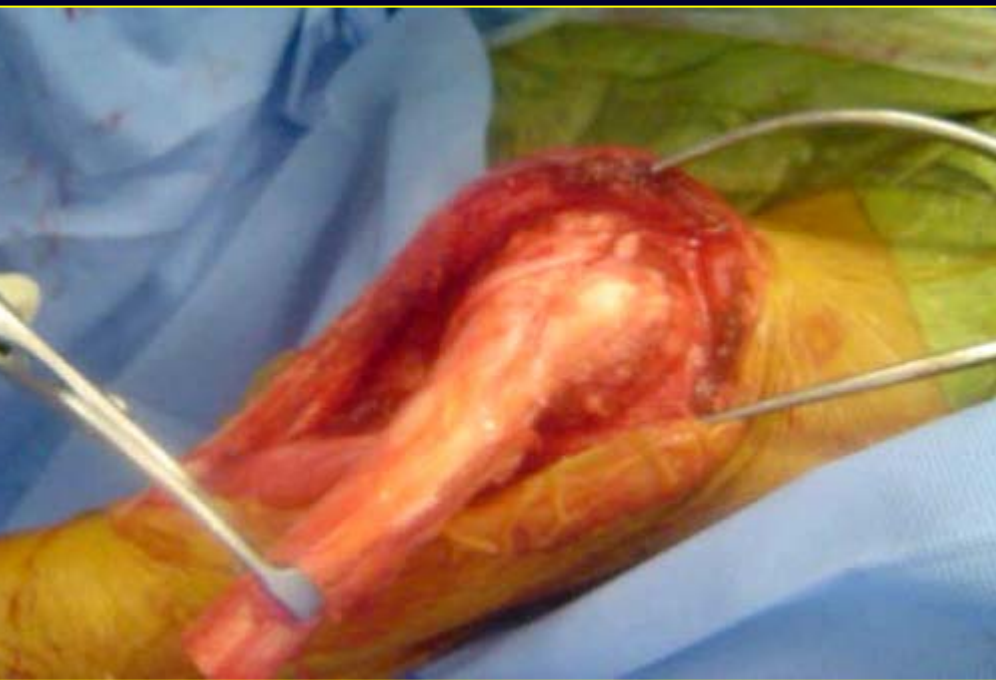Osteosarcoma
15 años



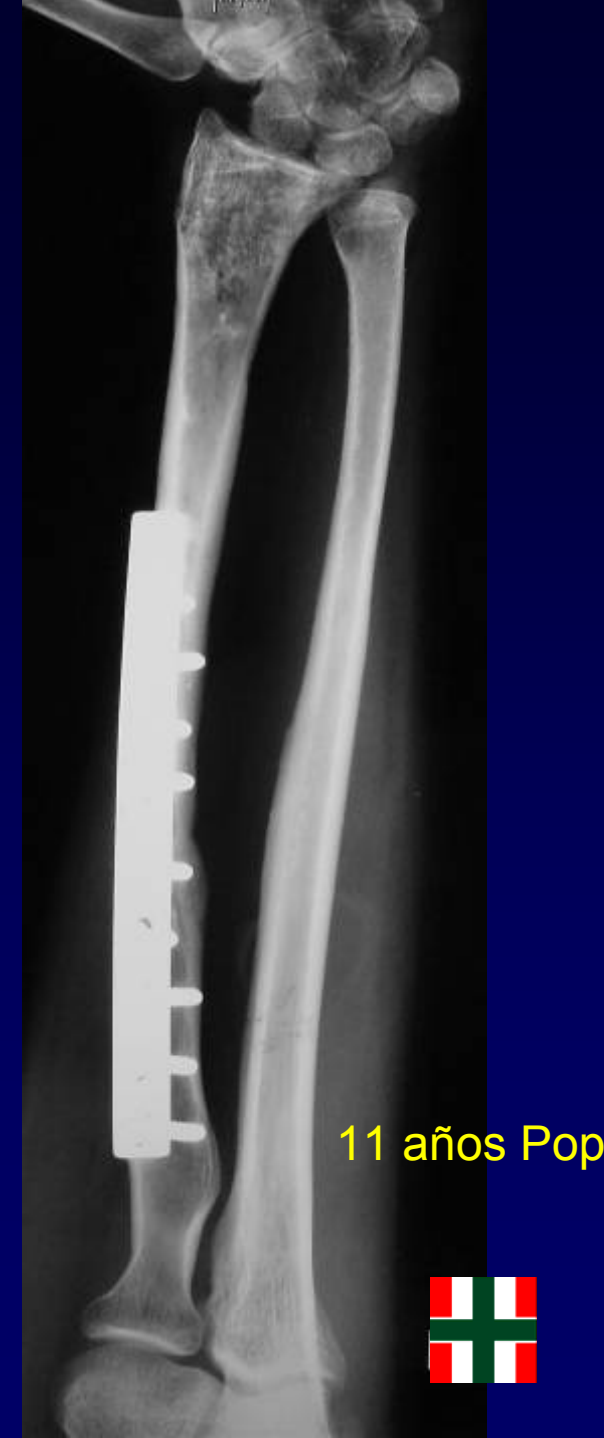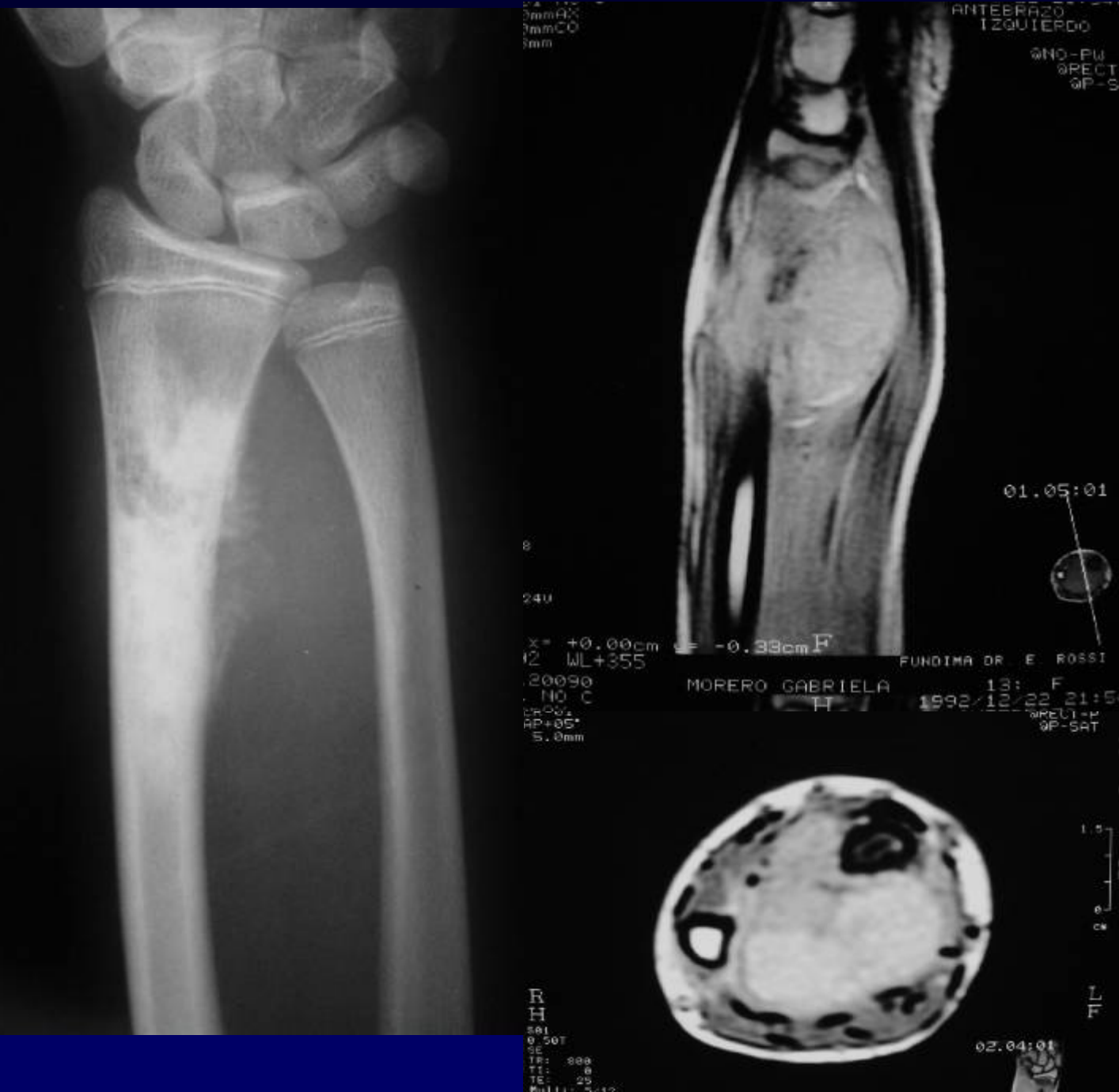16 años
Pop





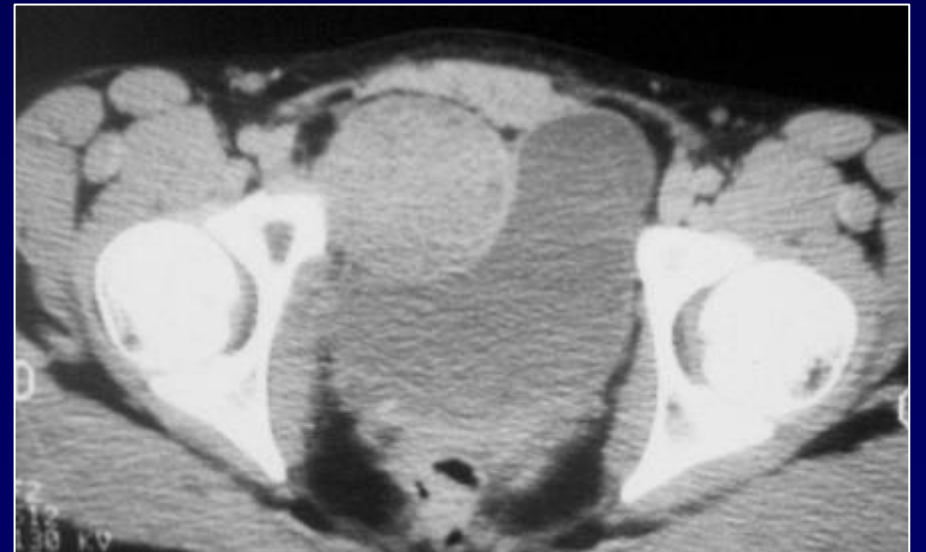
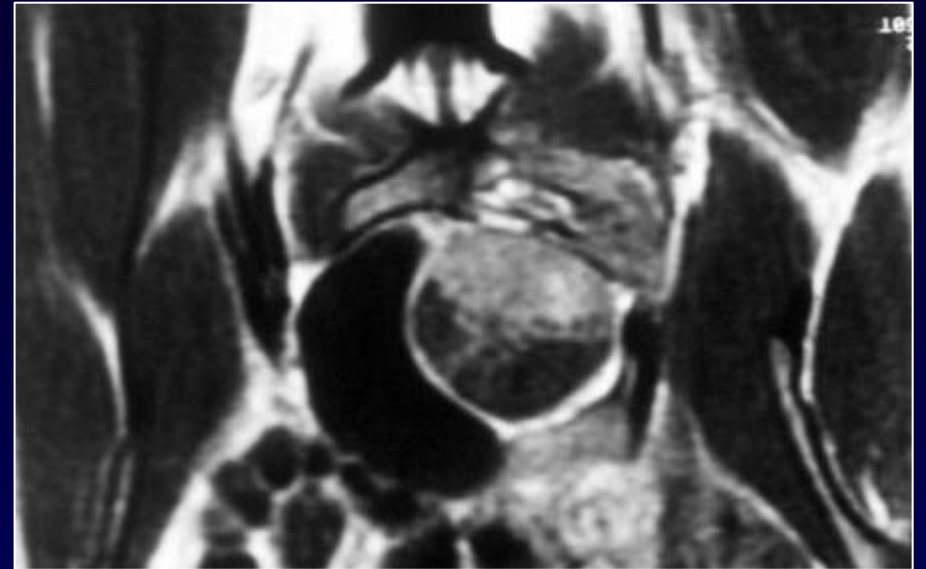
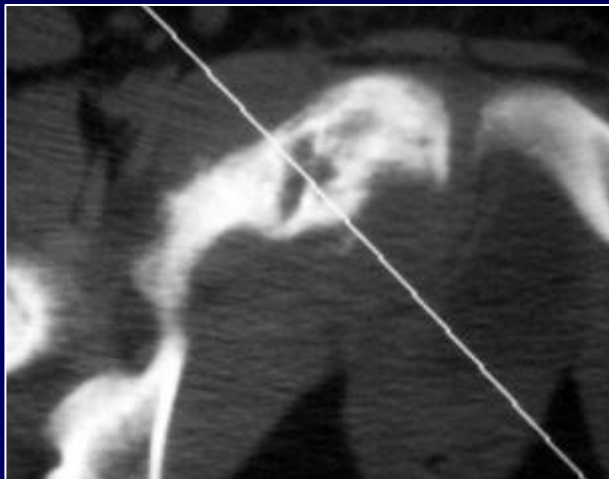
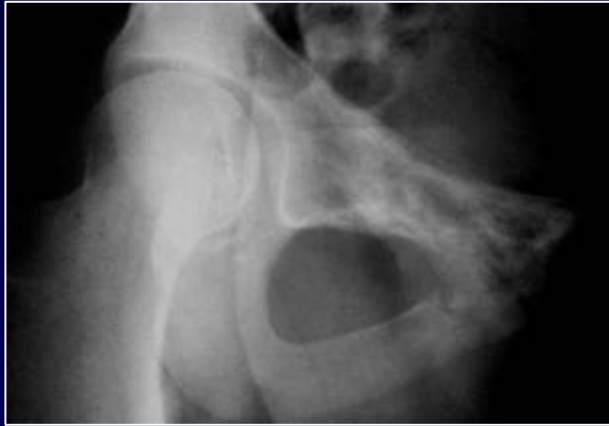

Osteosarcoma 13 años

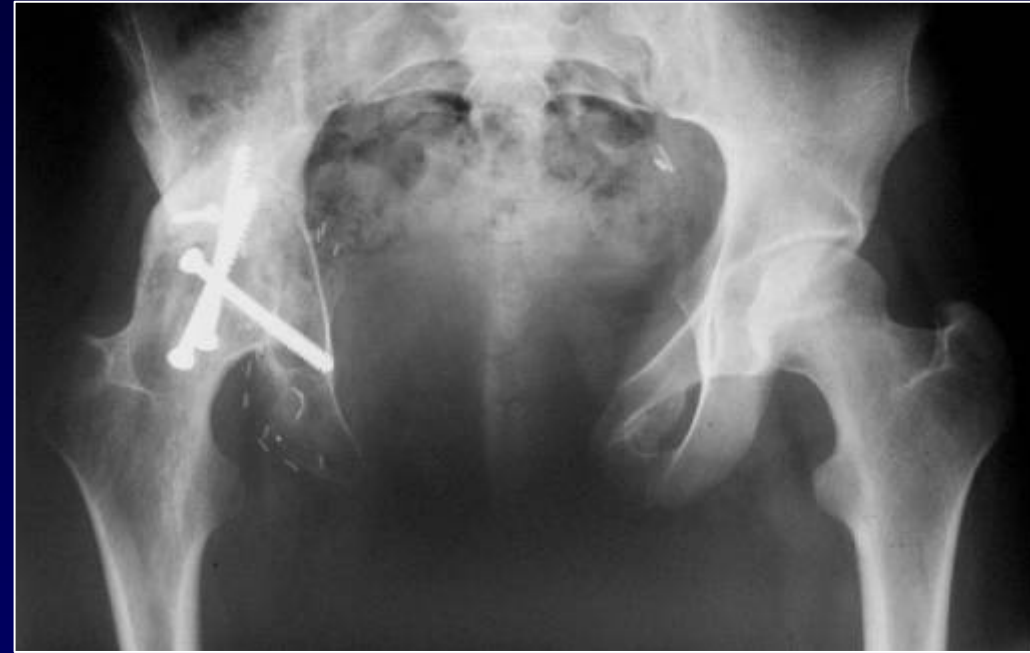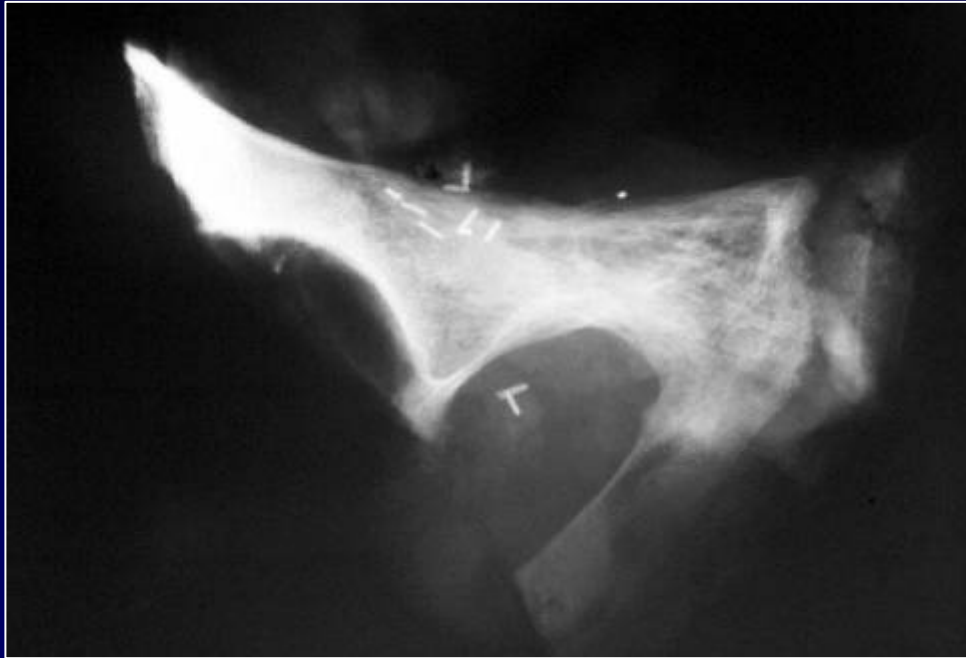


Arthrodèses

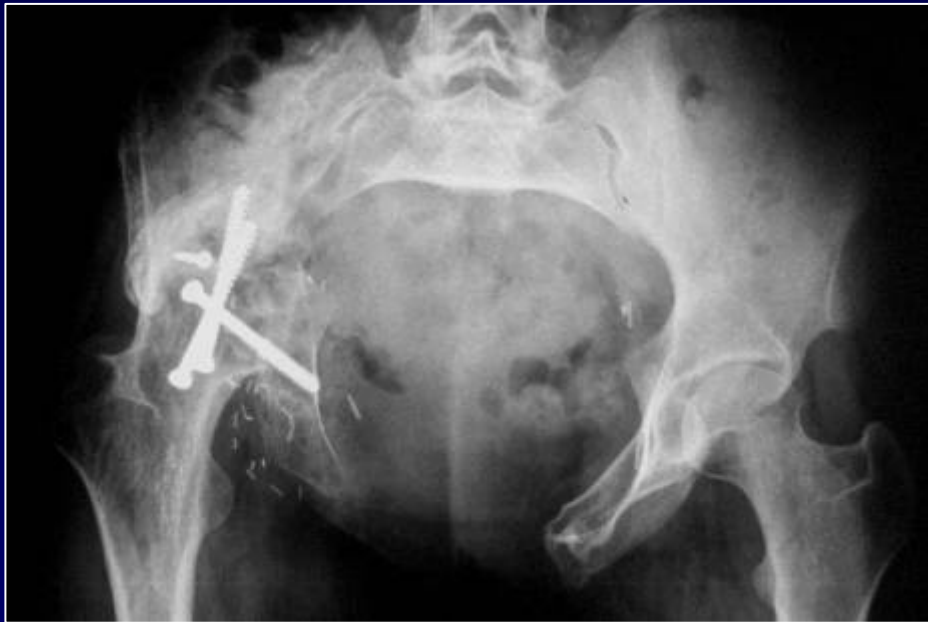S. d'Ewing
Branche ilio-pubienne Dte
14 ans



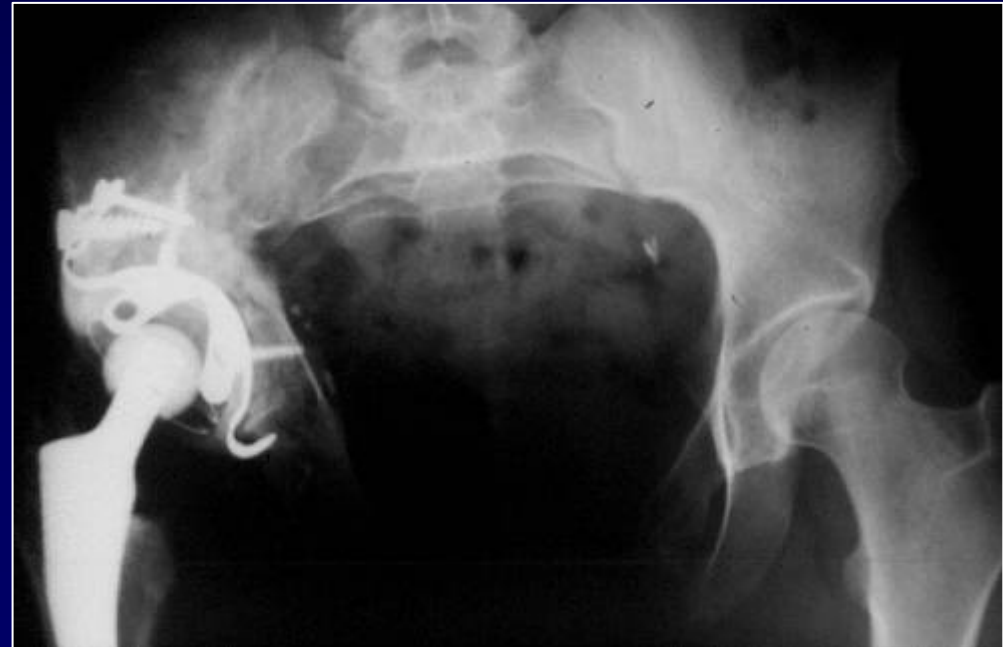Résection Arthrodèse Radiothérapie !



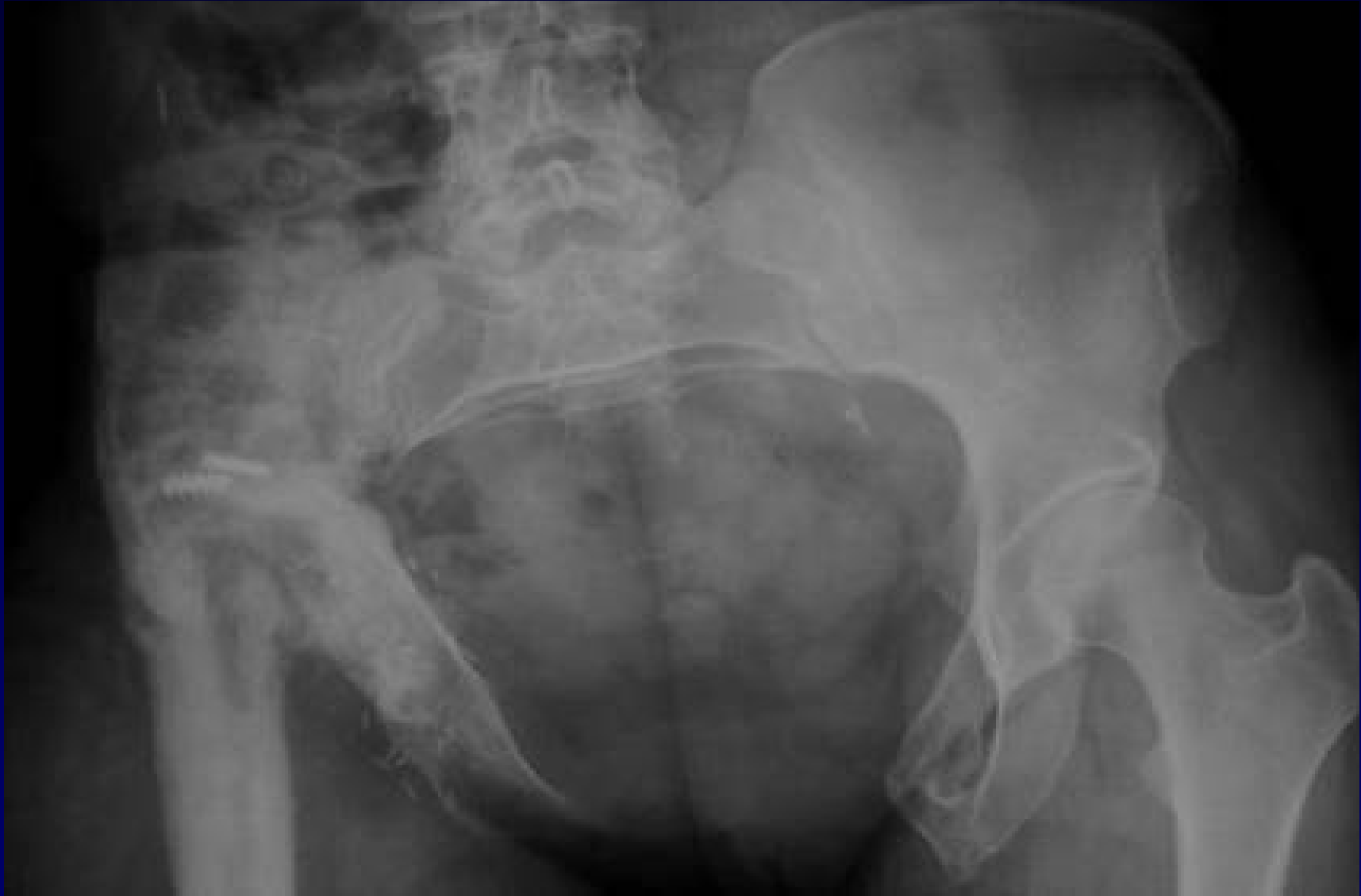- Chute
- Fracture isthmique
- Douleurs
- Attitude vicieuse
- Pseudarthrose



- Prothèse ..
- Infection ..
- Reprises x 4
- Implantation



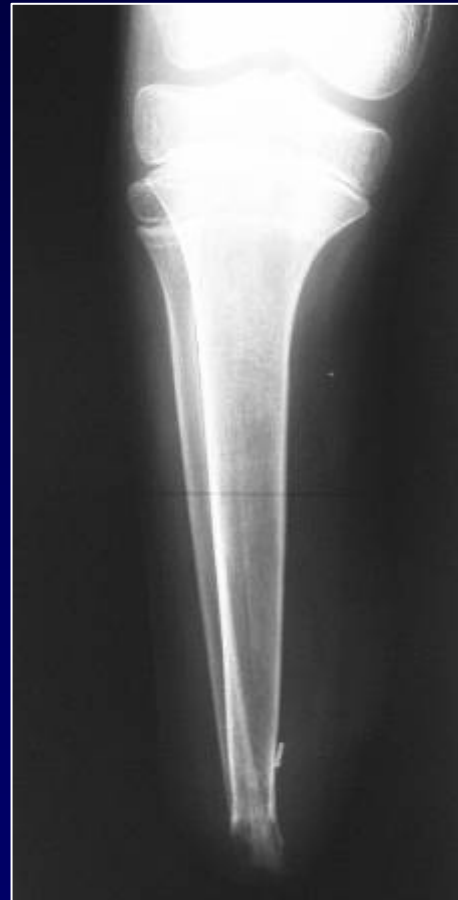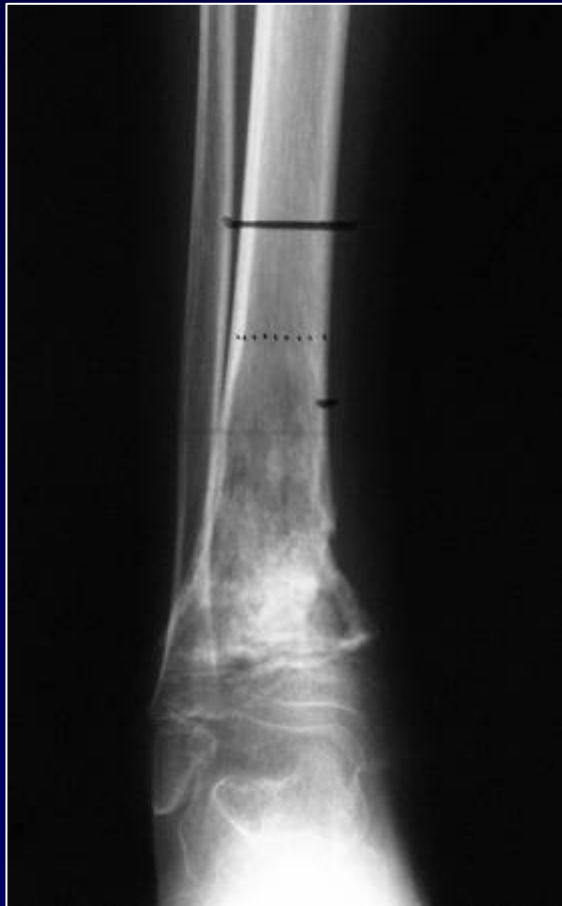Plus de 10 opérations !



Amputation

« de première intention »

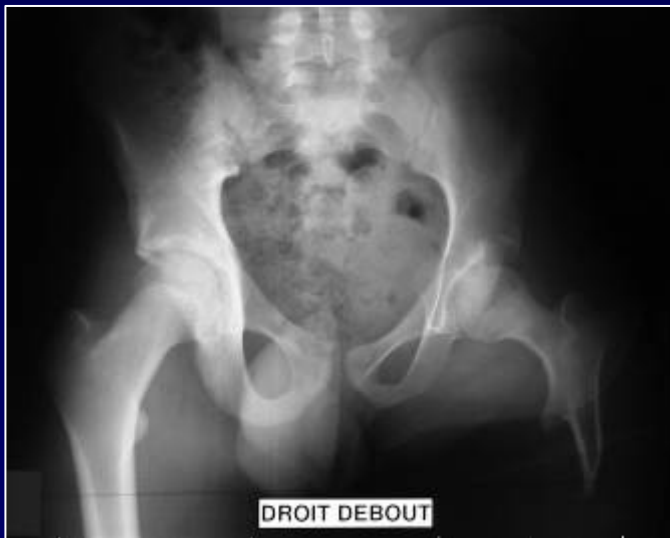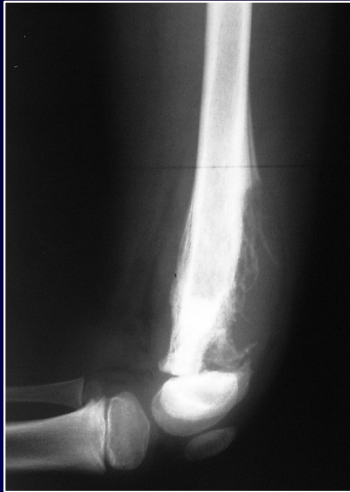Garçon, 12 ans, Ostéosarcome



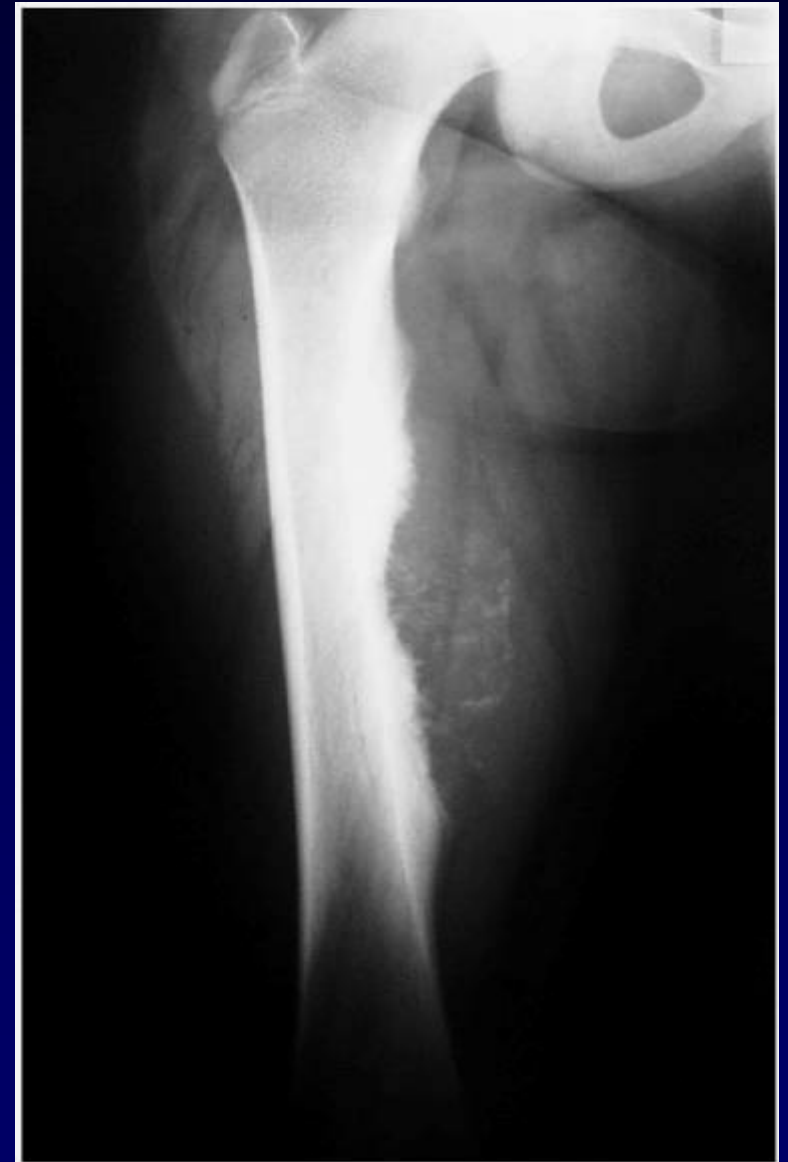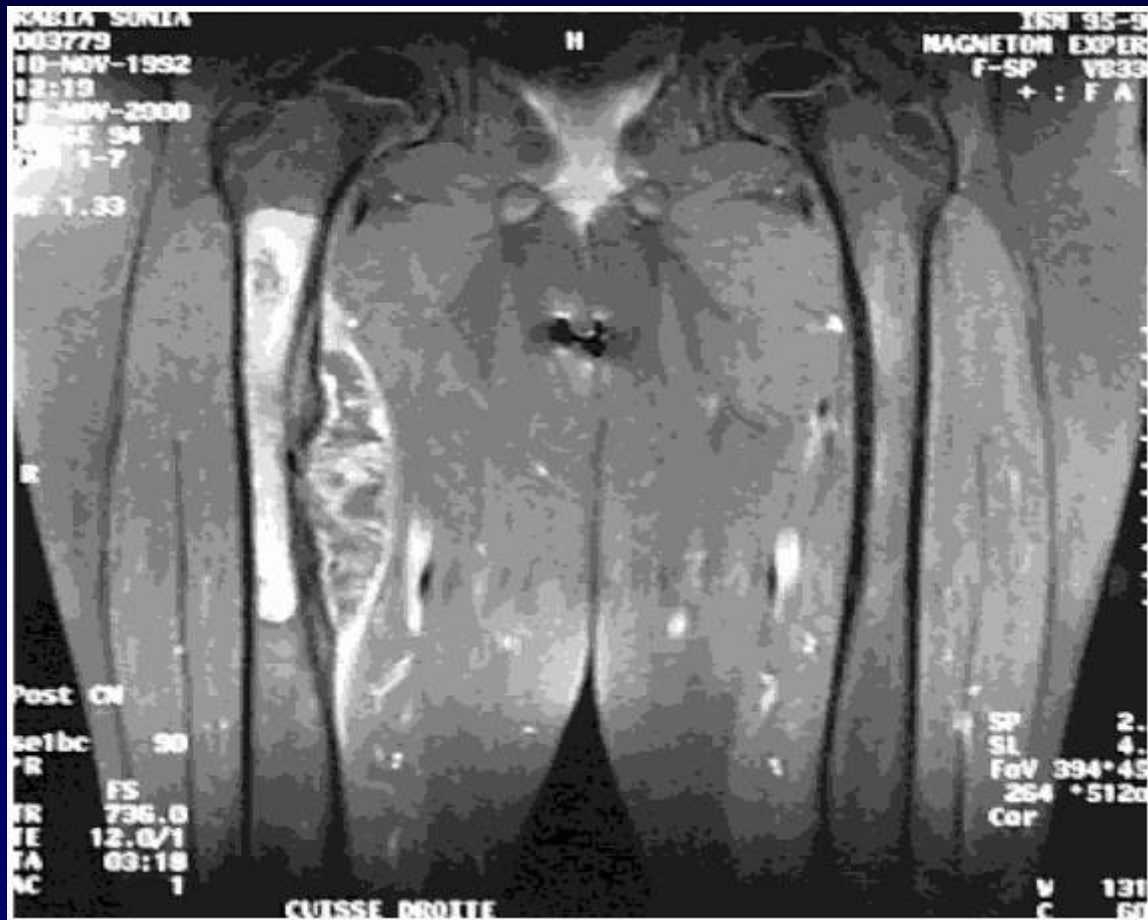Amputation « de deuxième intention »

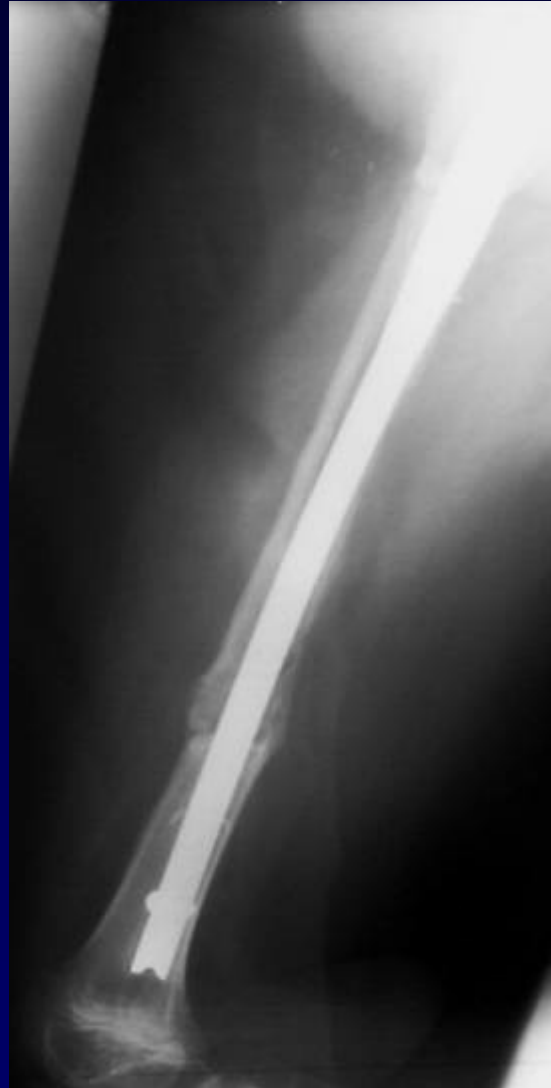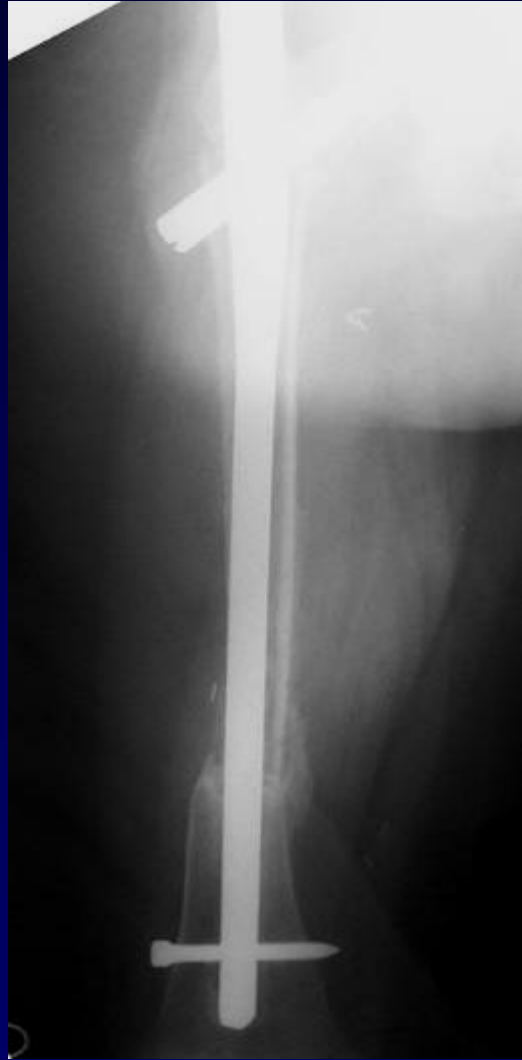Garçon, 6 ans, osteo.

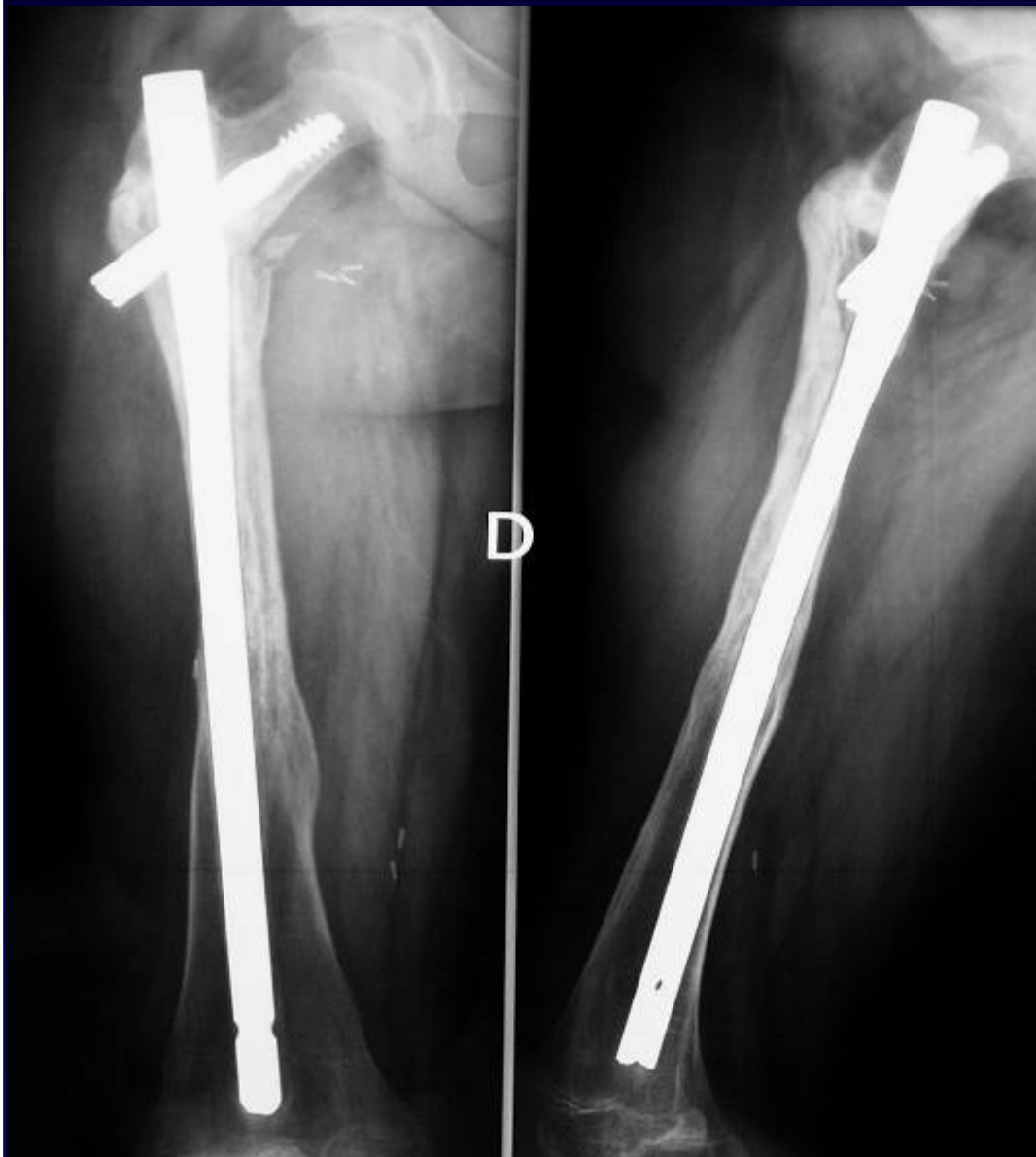Echec de Borgraeve



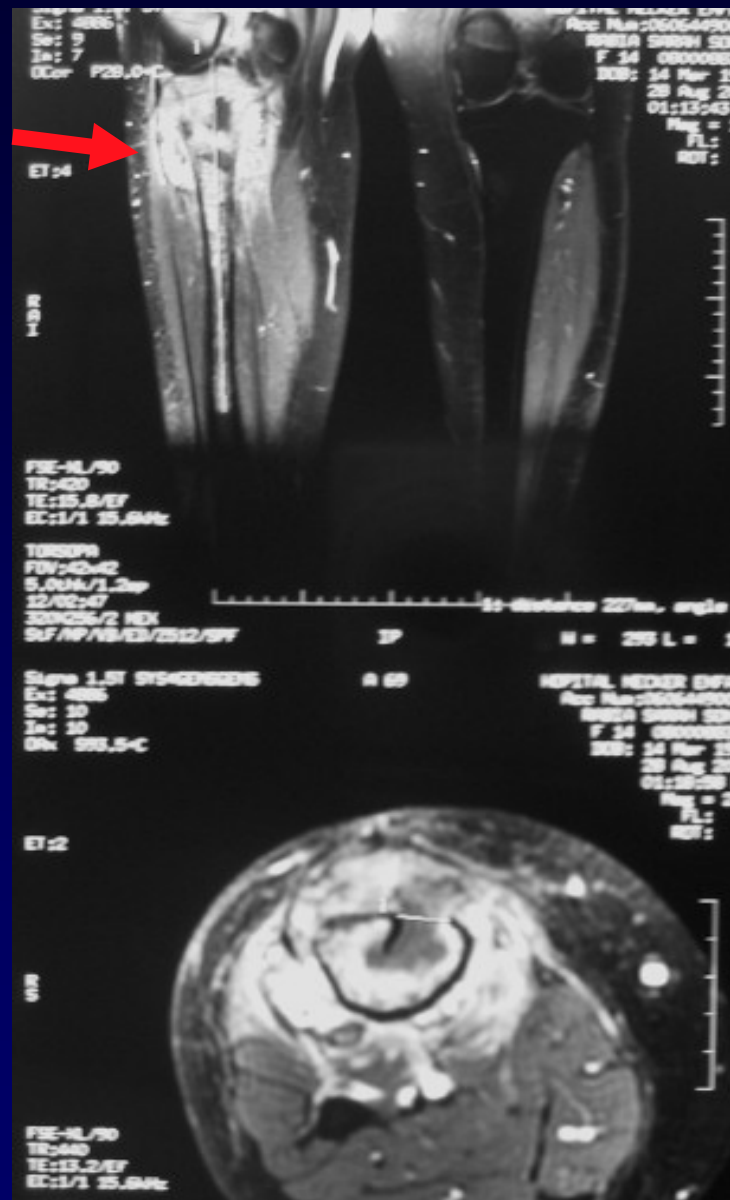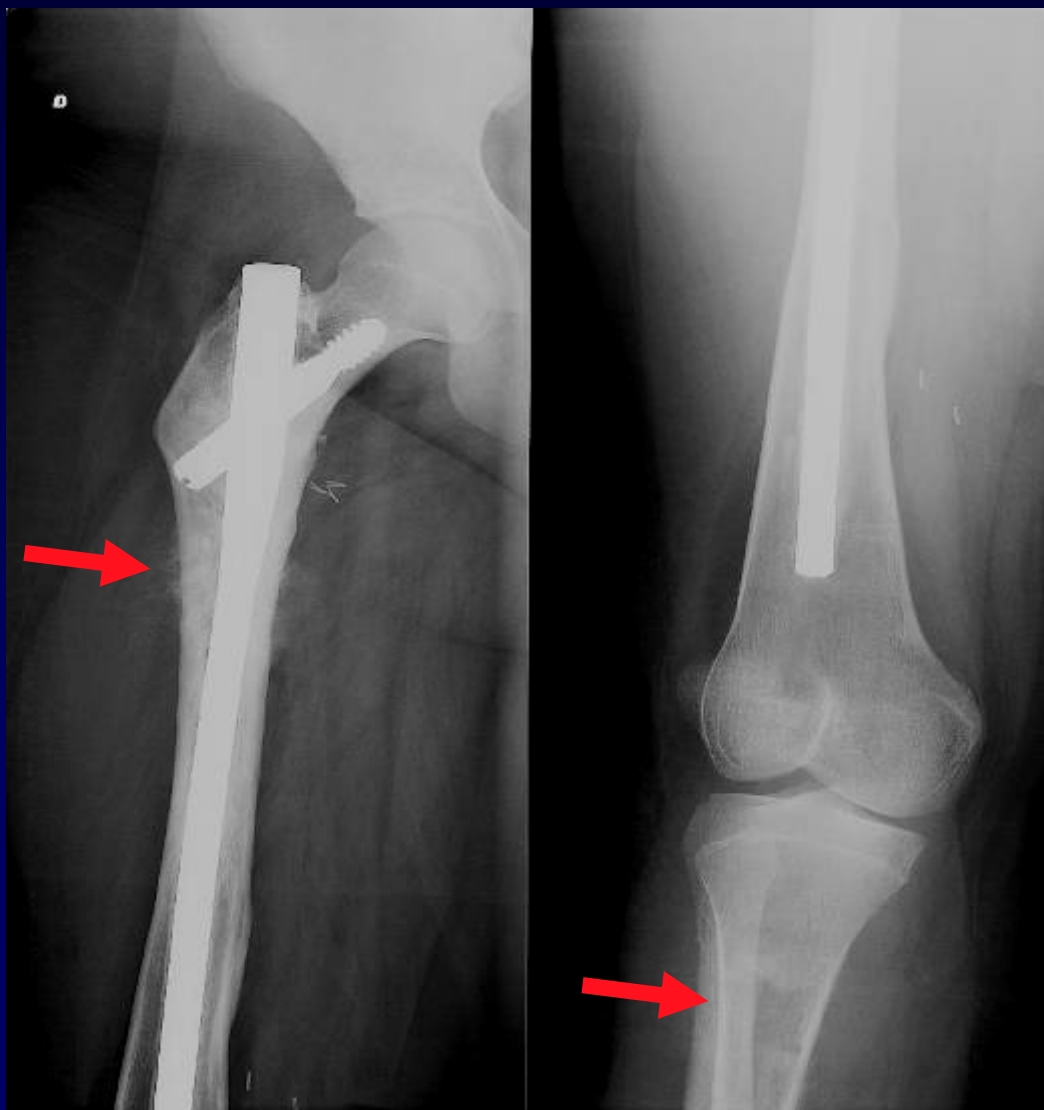
Récidive locale







J + 6 ans



Signa 1.5T B1546296096
Ex: 4886
Se: 3
Is: 9
DCor: F20

HOSPITAL MEDICAL CENTER
Acc Num: 0506449000
RASHIA SARAH SONIA
F 14 0800088389
DOB: 14 Mar 1992
28 Aug 2006
12:46:32 PM
Mag = 1.0
FL:
ROT:

ET:18

DR

FSE-MC/90
TR:4000
TE:79.6/CF
EC:1/1 20.8kHz

TORSOPA
FOV:42x42
5.0cm/1.2cm
13/03:08
384K256/3 HEX
FCI/HP/VS/ED/Z512/3PF

I 196

M = 531 L = 239

Signa 1.5T B1546296096
Ex: 4886
Se: 3
Is: 9
DCor: F20

HOSPITAL MEDICAL CENTER
Acc Num: 0506449000
RASHIA SARAH SONIA
F 14 0800088389
DOB: 14 Mar 1992
28 Aug 2006
12:46:32 PM
Mag = 1.0
FL:
ROT:

ET:18

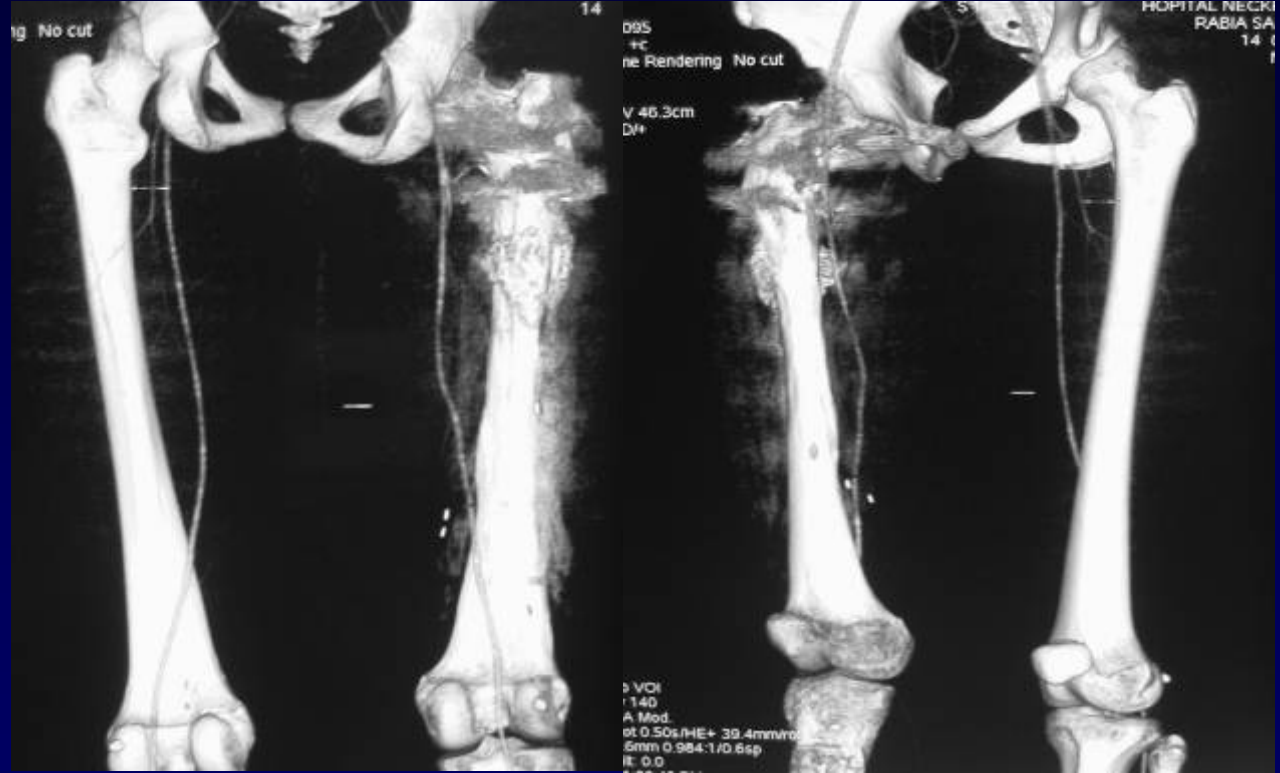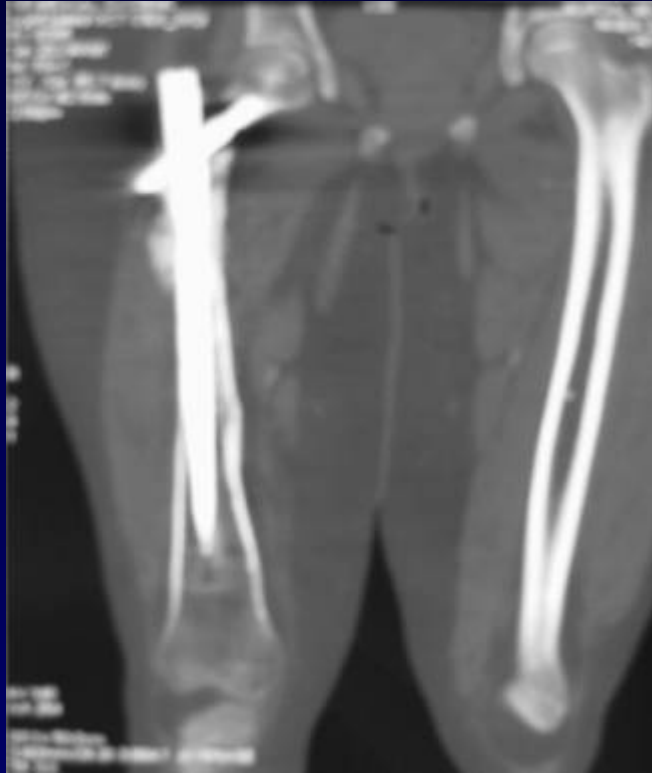DR


FSE-MC/90
TR:4000
TE:79.6/CF
EC:1/1 20.8kHz

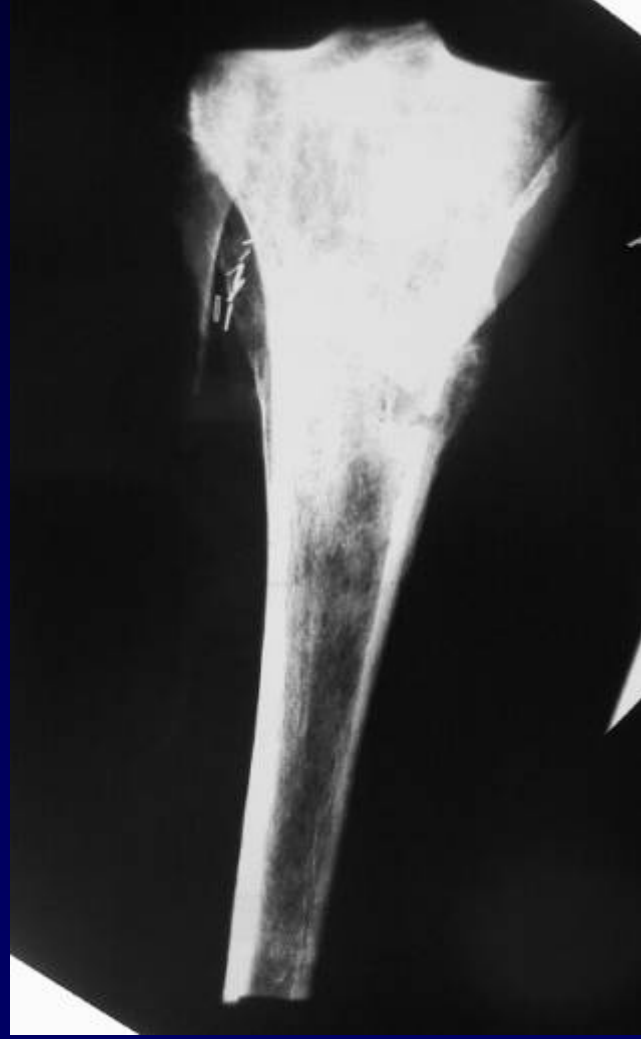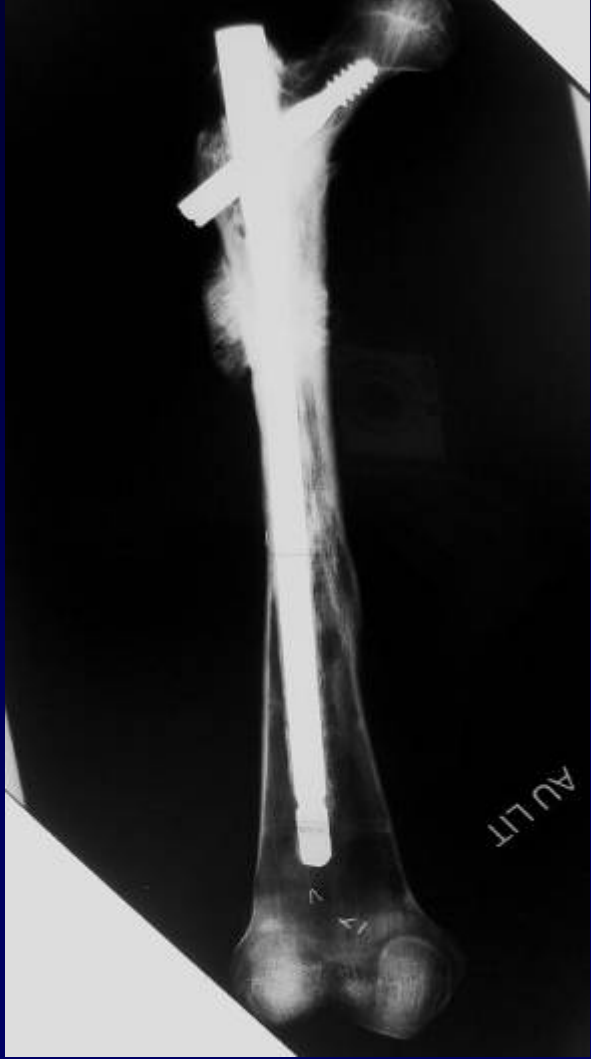TORSOPA
FOV:42x42
5.0cm/1.2cm
13/03:08
384K256/3 HEX
FCI/HP/VS/ED/Z512/3PF

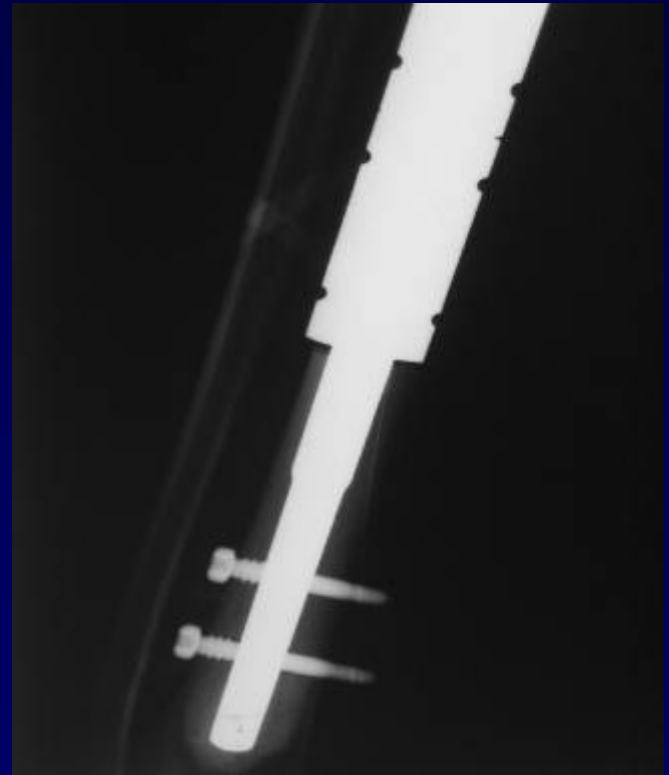
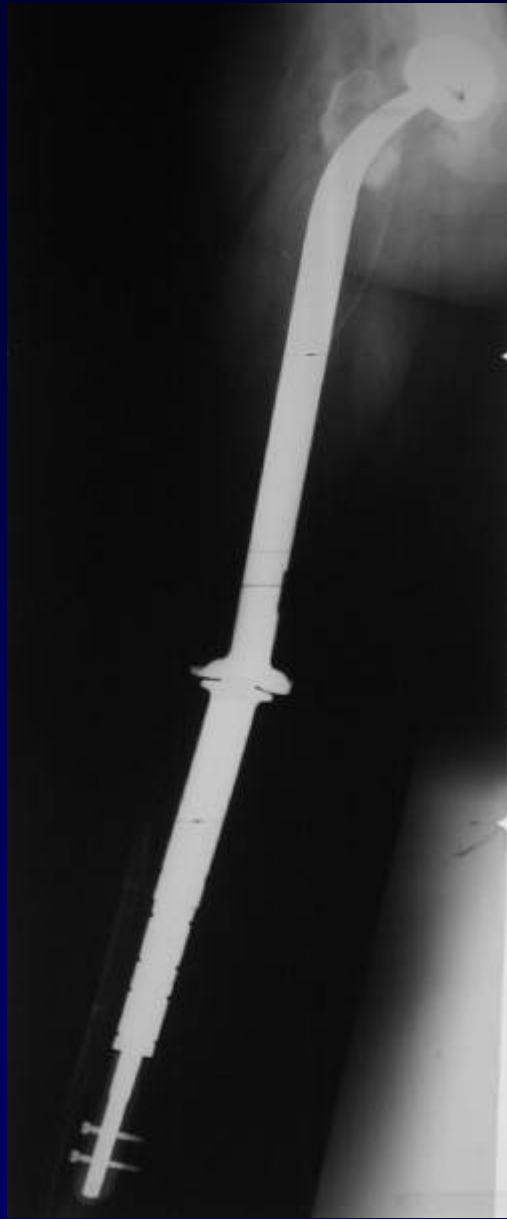
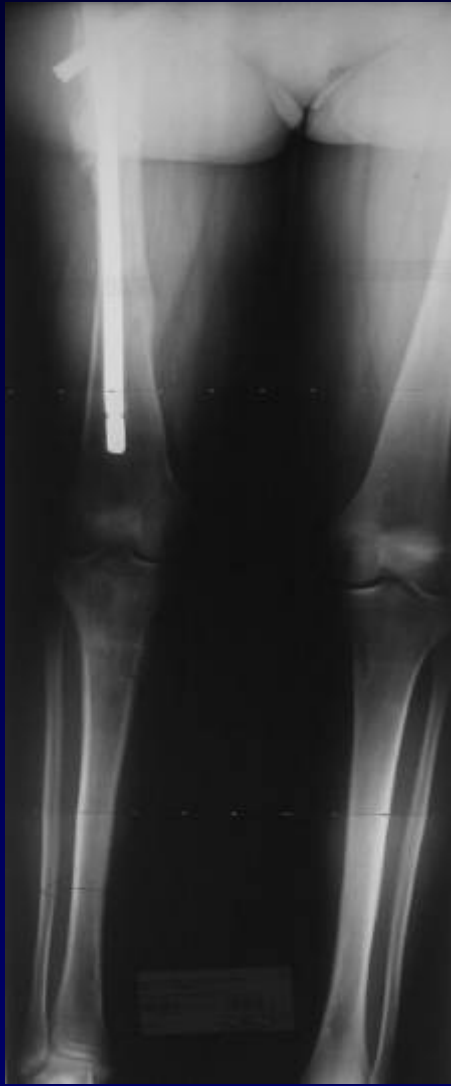
I 196

M = 531 L = 239









Conclusions

- **Attention à la biopsie**
- **Chirurgie difficile**
- **Priorité à la résection**
- **Indication de reconstruction difficile**
- **Grande diversité des possibilités**
- **Taux de complications importants**