



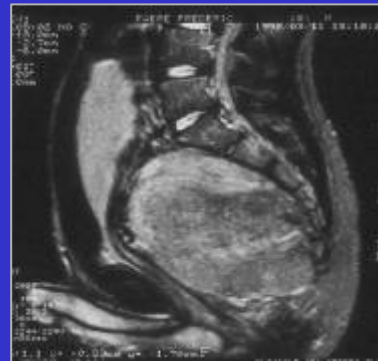
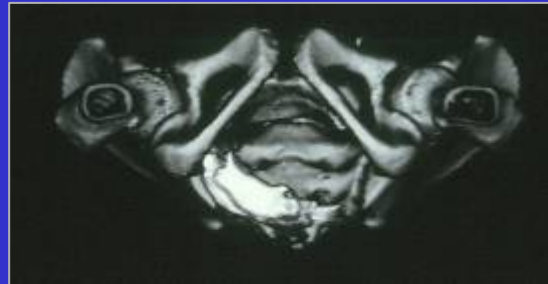
Collège Hospitalier et Universitaire
de Chirurgie Pédiatrique

DESC de Chirurgie Pédiatrique
Session de Mars 2008 - PARIS

Tumeurs Malignes du Rachis

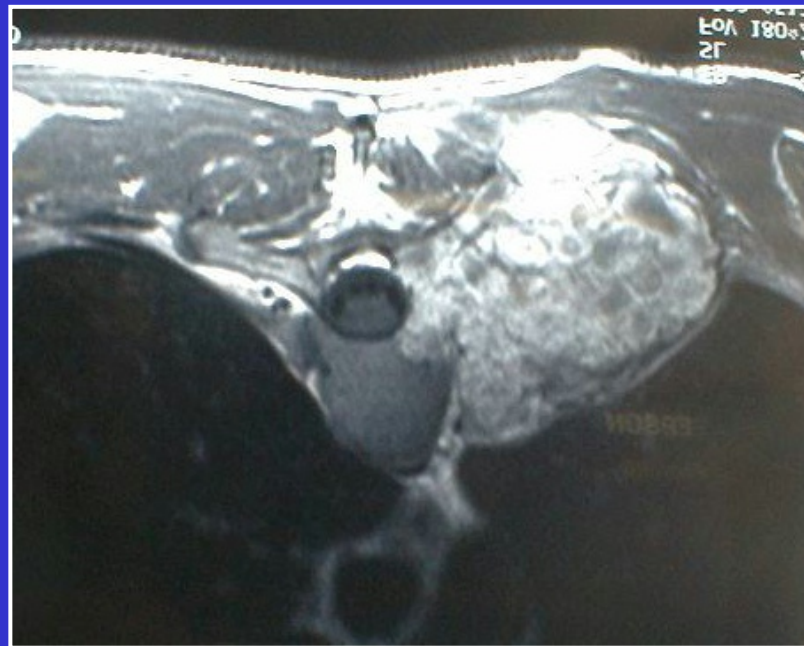G. BOLLINI

We will exclude from this presentation the tumor involving the sacrum which are particular entities more prone to be discussed in a chapter entitled sacral and pelvi-sacral malignant bone tumor.




It is often difficult to determine whether a malignant bone tumor in children involve a rib and then spread to the adjacent vertebra(e) or if it is a primary malignant spine tumor invading the adjacent rib(s).

That the reason why in such cases in thoracic area we will discuss of costo-vertebral bone neoplasm




Primary malignant sarcomas of the spine are extremely rare. It has been estimated that they account for 2% to 10% of all primary bone neoplasms

4767 patients in the Vienna Bone Tumor Registry



1715 primary malignant tumors



44 spine tumors = 2.5%

As this localization of malignant bone tumor is very rare most of the publication in the literature deal with both children and adult patients.....

And often with benign as well as malignant spinal bone tumours

5 Ewing Sarcomas, 1 Chondrosarcoma, 1 Malignant Fibrous Histiocytoma, 1 Epithelioid Sarcoma

Patient Number	Age/Gender	Tumor Location	Histologic Diagnosis	Tumor Removal	Resection Margins	Local Recurrence
1	37/M	L2	Chondrosarcoma	En bloc	Free of tumor	No
2	18/M	L4	Chondrosarcoma	En bloc	Free of tumor	No
3	15/M	L5	Ewing's sarcoma	Piecemeal	Macroscopic tumor	No
4	13/M	L2-L4	Ewing's sarcoma	Piecemeal	Free of tumor	No
5	22/M	C3-C7	Chondrosarcoma	Piecemeal	Free of tumor	Yes
6	67/M	L3	Chondrosarcoma	Piecemeal	Microscopic tumor	No
7	44/M	C3,C4	Chondrosarcoma	Piecemeal	Microscopic tumor	No
8	7/M	L2-L5	Ewing's sarcoma	Piecemeal	Microscopic tumor	No
9	27/M	T10-T12	Myxoid liposarcoma	En bloc	Free of tumor	No
10	44/F	T10	Hemangioendothelial sarcoma	Piecemeal	Macroscopic tumor	No
11	29/F	T10	Giant cell tumor	En bloc	Free of tumor	No
12	22/M	T2	Ewing's sarcoma	En bloc	Free of tumor	No
13	28/M	T10,T11	Chondrosarcoma	En bloc	Free of tumor	No
14	21/F	L4	Chondrosarcoma	Piecemeal	Free of tumor	No
15	32/M	C4	Chondrosarcoma	Piecemeal	Macroscopic tumor	Yes
16	19/M	L1	Ewing's sarcoma	Piecemeal	Macroscopic tumor	Yes
17	66/F	L3	Chondrosarcoma	En bloc	Macroscopic tumor	Yes
18	70/F	L3	Osteosarcoma	Piecemeal	Microscopic tumor	Yes
19	32/M	C4-T1	Osteosarcoma	Piecemeal	Macroscopic tumor	Yes
20	7/M	L1,L2	Ewing's sarcoma	En bloc	Macroscopic tumor	No
21	80/M	L3	Fibroblastic osteosarcoma	Piecemeal	Microscopic tumor	No
22	50/M	T7	Osteogenic sarcoma	En bloc	Free of tumor	No
23	62/F	L3	Fibroblastic osteosarcoma	Piecemeal	Microscopic tumor	Yes
24	16/F	C1,C2	Malignant fibrous histiocytoma	Piecemeal	Macroscopic tumor	Yes
25	72/M	T11	Malignant fibrous histiocytoma	En bloc	Free of tumor	No
26	4/F	C1,C2	Epithelioid sarcoma	Piecemeal	Microscopic tumor	Yes
27	34/F	L4,L5	Osteosarcoma	En bloc	Microscopic tumor	Yes
28	13/M	T7-T9	Ewing's sarcoma	Piecemeal	Macroscopic tumor	No
29	30/F	T7-T9	Giant cell rich osteosarcoma	Piecemeal	Microscopic tumor	Yes
30	72/M	T2,T3	Myofibroblastic sarcoma	En bloc	Free of tumor	Yes

Relationship Between Surgical Margins and Local Recurrence in Sarcomas of the Spine

Talac, Robert MD, PhD; Yaszemski, Michael J. MD, PhD; Currier, Bradford L. MD; Fuchs, Bruno MD; Dekutoski, Mark B. MD; Kim, Choll W. MD, PhD; Sim, Franklin H. MD, Clin Orthop Rel Res Volume 397, April 2002, pp 127-132

Charles G. Fisher 26 patients

Table 1. Patient Diagnosis and Preoperative Staging

Case	Age	Symptom Duration (Months)	Diagnosis	F. U	Level	Enneking	WBB Sector	WBB Level
1	56	15	Chordoma		S4-S5	1b	N/A	N/A
2	56	78	MFH		S1-S3	2b	N/A	N/A
3	29	37	Osteosarcoma		T5-T7	1b	8-12	A-D
4	53	79	Osteoblastoma (recurrent)		T12-L2	S3	11-8	A-D
5	51	13	Osteoblastoma (recurrent)		L5	S3	1-4	A-C
6	38	6	Pancoast tumor		T3-T4	2b	2-5	A-C
7	31	17	Osteosarcoma		T9-T11	2b	2-5	A-D
8	36	5	MPNST		C5-T1	2b	2-6	A-E
9	20	9	Osteosarcoma		L1-L3	2b	1-6	A-D
10	53	13	Chordoma		S1-S3	1b	N/A	N/A
11	64	6	Chordoma		L5-Cx	1b	N/A	N/A
12	41	4	Hemangioendothelioma		L1	S2	4-9	A-D
13	20	12	Mesenchymal hamartoma		C6-T1	S2	3-4	A-B
14	45	9	Giant cell tumor		C7-T2	S3	7-12	A-D
15	67	6	Chordoma		L4-S1	1b	N/A	N/A
16	16	7	Chondrosarcoma	36 M	T2-T5	2b	9-12	A-C
17	65	3	Chondrosarcoma		L4	1b	6-10	A-D
18	50	4	Giant cell tumor		C3	S3	4-11	C-D
19	50	5	Chordoma		C2	1b	1-6	A-D
20	70	4	Chordoma		S2	1b	N/A	N/A
21	18	9	Ewing's sarcoma	18 M	L5	2b	1-6	A-C
22	46	3	Chordoma		S4-S5	1b	N/A	N/A
23	17	7	Osteoblastoma		L1	S2	10-12	A-C
24	31	10	Chondrosarcoma		T7-T10	1b	3-5	A-C
25	26	3	Ewing's sarcoma (recurrent)		T2-T3	2b	1-6	A-C
26	57	20	Chondrosarcoma		T1	2b	3-6	A-B

Note. A summary of patient demographic data and preoperative staging according to both the Enneking and Weinstein Boriani Biagini (WBB) classification (where applicable).

Hasegawa Kazuhiro 13 patients

Table 1. Details of the 13 Cases Who Underwent Margin-Free Spondylectomy

Case No.	Age (yr)	Sex	Diagnosis	Level	F. U Classification	Resected Area
1	45	F	Chondrosarcoma	T2,3	6	T(1),2,3,4,(5)
2	55	F	MET (breast)	T6	2	T(5),6,(7)
3	18	M	Chondrosarcoma	T5	156 M	T(3),4,5,6
4	40	F	MET (thyroid cancer)	T12	5	T(11),12,(L1)
5	61	F	Chondrosarcoma	T6	6	T4,5,6,7,8,(9)
6	22	M	Osteosarcoma	L1	1	(T12),L1,(2)
7	41	M	Chordoma	L2	6	L1,2,3
8	39	M	GCT	T7	6	T(6),7,(8)
9	53	M	MET (RRC)	T10,11	6	T(8),9,10,11
10	45	F	MET (laryngeal cancer)	T7	3	T(6),7,(8)
11	31	F	GCT	T12	4	T11,12,L1
12	54	M	MET (RRC)	T6	3	T(5),6,(7)
13	38	F	GCT	L3	6	L(2),3,(4)

MET (breast) indicates metastatic spine tumor of breast cancer; MET (thyroid cancer), metastatic spine tumor of thyroid cancer; GCT, giant-cell tumor; MET (RC), metastatic spine tumor of renal cell cancer; MET (laryngeal cancer), metastatic spine tumor of laryngeal cancer; Level, vertebral level of tumor origin; Classification, surgical classification by Tomita *et al*⁸; Resected area, extirpated vertebral level. The value in parenthesis indicates the osteotomized normal vertebral level.

P Krepler : 2 Ewing Sarcoma, 1 Chondrosarcoma

F.U. 27 M – 58 M

No evidence of disease

2 Neurological deficit

Case	Gender	Age (yrs)	Histology	Site	Neurology preoperatively	Chemotherapy	Follow-up (mths)	Surgical margins	Oncological state*
1	M	45.8	Leiomyosarcoma	T7	No	No	24	Marginal	DOD
2	M	28.1	Osteogenic sarcoma	T12	No	Yes	67	Wide	NED
3	M	36.9	Spindle-cell sarcoma	T6,7,8	No	Yes	46	Wide	AWD
4	F	16.2	Chondrosarcoma	T2,3	Paraparesis T3	Yes	58	Wide	NED
5	F	6.2	Ewing's sarcoma	L3	Weakness L3	Yes	46	Wide	NED
6	F	34.2	Schwannoma	T10	Paraparesis T10	Yes	12	Marginal	DOD
7	M	18.3	Ewing's sarcoma	L3	No	Yes	27	Wide	NED

* DOD, died of disease; NED, no evidence of disease; AWD, alive with disease

Steven Beer: 2 GCT, 2 Chordomas, 1 Ewing Sarcoma (Long term F.U. 1951-1976)

Diagnosis	Site	Age (yr) Sex	Treatment	Result	Follow-up (yr)
Aneurysmal bone cyst	S1-S3 right sacral ala	15/M	Radical excision and fusion	Normal	20
Aneurysmal bone cyst	L3 body and pedicle right	11/F	Radical excision, no fusion	Normal function, developed scoliosis requiring immobilization	22
Eosinophilic granuloma	C7 body	8/F	Resection and fusion	Normal	20
Osteoid osteoma	S2 pedicle	15/M	Partial excision elsewhere Radical excision/radiation	Recurrence Normal	20
Osteoid osteoma	C4 pedicle	10/M	Radical excision	Normal	23
Osteoid osteoma	L5-S1 pedicle	8/M	Partial excision Excision	Persistent pain, residual tumor Normal	15
Osteoblastoma	C2 anterior arch	9/M	Transoral excision and fusion Immobilization/radiation	Recurred 6 mo Normal	26
Osteoblastoma	L5 and S1 lamina	8/F	Radical excision	Normal	16
Osteoblastoma	L3-L5 posterior arches	6/M	Partial excision Radical excision and radiation	Recurred 1 yr Normal	18
Osteoblastoma	C7-T2 pedicles and transverse processes	13/F	Excision with anterior and posterior fusion Radical excision and radiation	Recurred 6 mo Normal	32
Osteochondroma	T3-T4 pedicle and lamina	16/M	Excision	Normal	11
Osteochondroma	T4-T5 pedicle	10/F	Excision	Normal	25
Osteochondroma	T3 body	15/M	Partial excision	Normal	10
Hemangioma	L2-L3 bodies	14/M	Partial excision and radiation	Normal	30
Hemangioma	T5 lamina and body	14/M	Partial excision	Partial recovery	44
Giant cell tumor	T5-T7 bodies	13/M	Excision with fusion	Normal	19
Giant cell tumor	T2-T3 body and pedicle	14/F	Excision	Partial recovery	30
Chordoma	Sacroiliac region	3/F	Radical resection and radiation	Died 1 yr	
Chordoma	L5-S1 body	2/M	Radical excision	Normal	36
Ewing's sarcoma	T1-T3 body	16/F	Partial excision, radiation, and chemotherapy	No recovery	No recurrence 15 yr

Katsuro Tomita : 1 Osteosarcoma, 1 Chondrosarcoma

F.U. 2 Y and 3.1 Y

Disease Free

Patient No.	Age (yr)/Sex	Histology	Chemotherapy		Radiotherapy		Frankel's Grade		Follow-up (yr)	Physical State at Follow-up
			Preop	Postop	Preop	Postop	Preop	Postop		
1	19/F	Osteosarcoma	No	Yes	No	No	B	E	6.5	CDF
2	7/M	Chondrosarcoma (recurrence)	No	No	No	No	C	D	3.1	NED
3	17/M	Osteosarcoma	Yes	Yes	No	No	E	E	2.0	CDF
4	42/F	Giant cell tumor (recurrence)	No	No	Yes	No	E	E	2.0	CDF
5	60/F	Malignant fibrous histiocytoma	No	No	No	No	C	D	0.6	DOD
6	73/M	Solitary plasmacytoma	No	No	No	No	C	D	3.5	CDF
7	36/M	Giant cell tumor	No	No	No	No	E	F	2.0	CDF

CDF = continuously disease-free; NED = no evidence of disease; DOD = dead of disease.

Total En Bloc Spondylectomy: A New Surgical Technique for Primary Malignant Vertebral Tumors

Tomita, Katsuro MD; Kawahara, Norio MD*; Baba, Hisatoshi MD†; Tsuchiya, Hiroyuki MD*; Fujita, Takuya MD*; Toribatake, Yasumitsu M Spine Volume 22(3), 1 February 1997, pp 324-333*

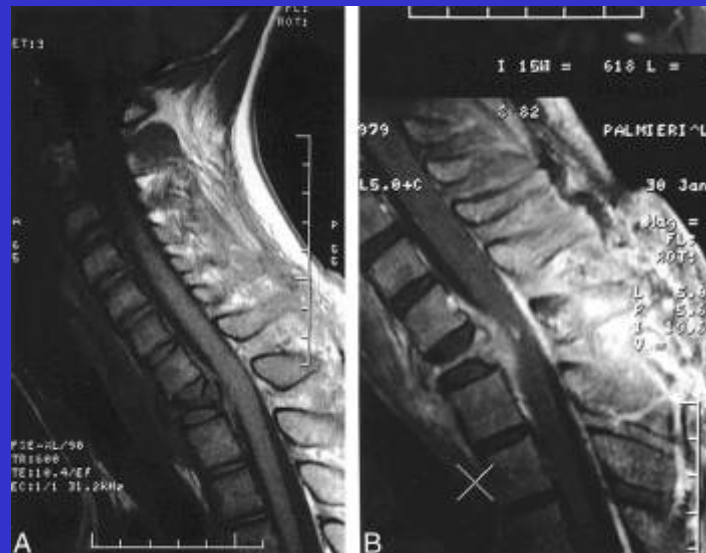Marco Rex : 13 Ewing Sarcoma 19 Y of age (7 – 26)

F.U. 65 M (2 – 218)

Anterior column alone was involved in 4 patients

Posterior column alone was involved in 1 patient

Both columns were involved in the remaining 8 patients



Ewing's Sarcoma of the Mobile Spine

*Marco, Rex A. W. MD**; *Gentry, J Brett MD†*; *Rhines, Laurence D. MD‡*; *Lewis, Valerae O. MD¶*; *Wolinski, J P. MD§*; *Jaffe, Norman MD†*; *Gokaslan, Ziya L. MD§*

Spine Volume 30(7), 1 April 2005, pp 769-773

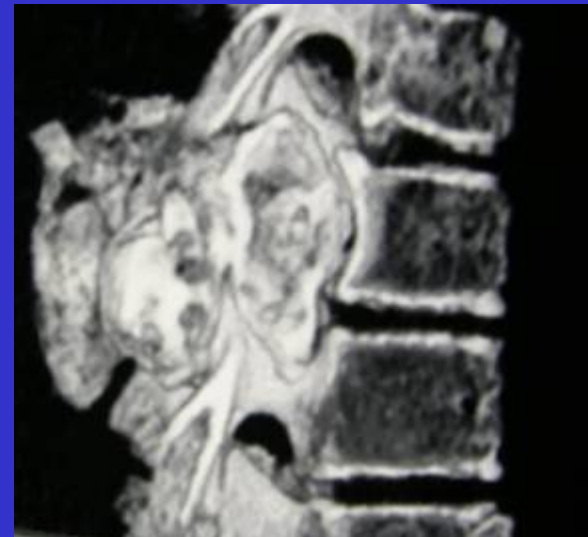
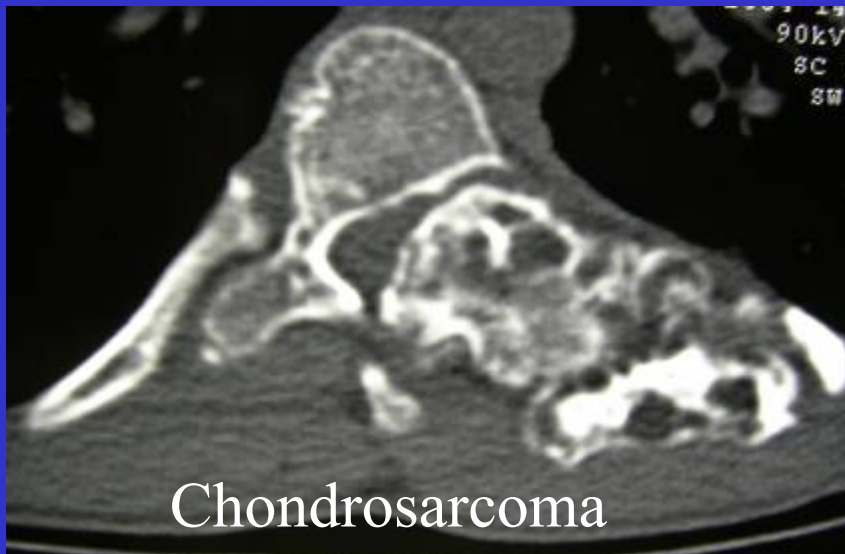
Ewing and PNET tumors

Chondrosarcoma

Osteosarcoma

Chordoma

Rhabdomyosarcoma



CLINICAL ONSET

Pain : backache or radicular

Exacerbated when the patient was supine

Interval between the onset of symptoms and diagnosis ranged from 1 week to more than one year

20 weeks overall


```
graph LR; A[20 weeks overall] --> B[26 weeks for benign tumors]; A --> C[11 weeks for malignant tumors];
```

26 weeks for benign tumors

11 weeks for malignant tumors

CLINICAL ONSET

Neurological deficit such as myelopathy to plexopathy and peripheral neuropathy in



91% of the malignant spine tumors

64% of the benign spine tumors

BIOPSY AND SURGICAL STAGING

Tools for diagnosis
and surgical staging

Computed tomography scanning

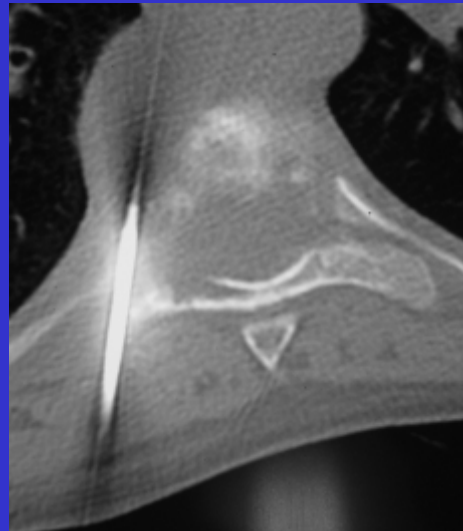
MRI

Bone scintigraphy

Angiography

TEP scan

Biopsy



SURGICAL STAGING

Katsuro Tomita

Classifications of different anatomic sites of the vertebra.

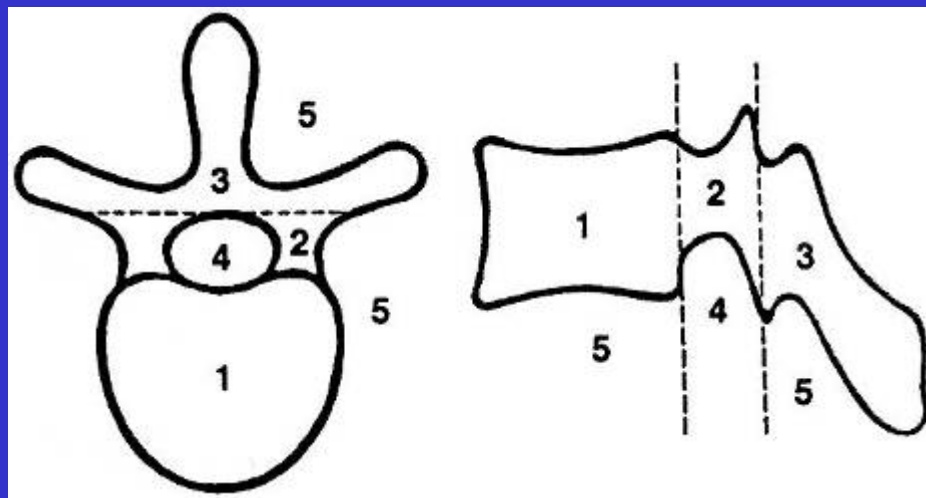
1 = vertebral body.

2 = pedicle.

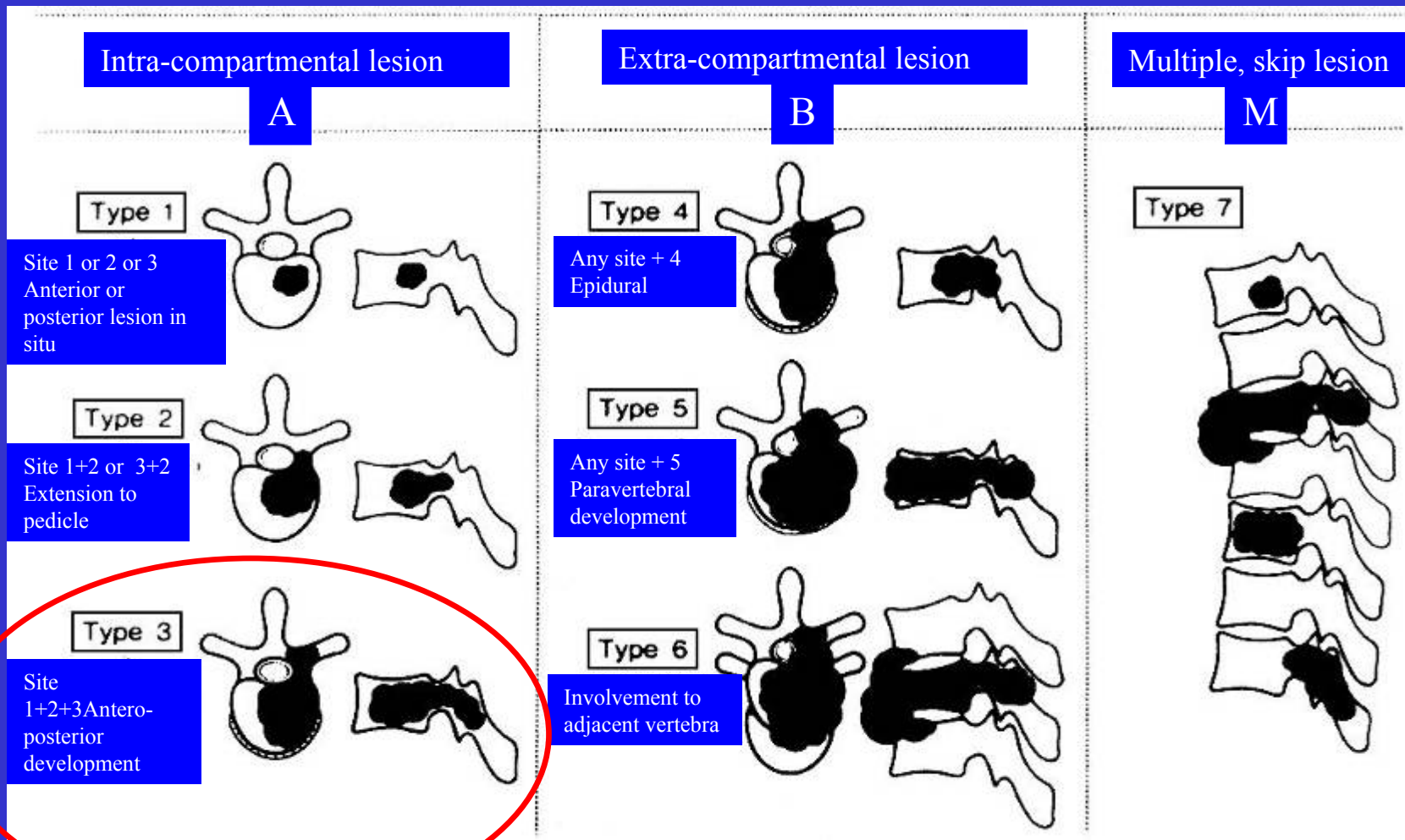
3 = lamina, transverse, and spinous processes.

4 = spinal canal (epidural space).

5 = paravertebral area



SURGICAL STAGING



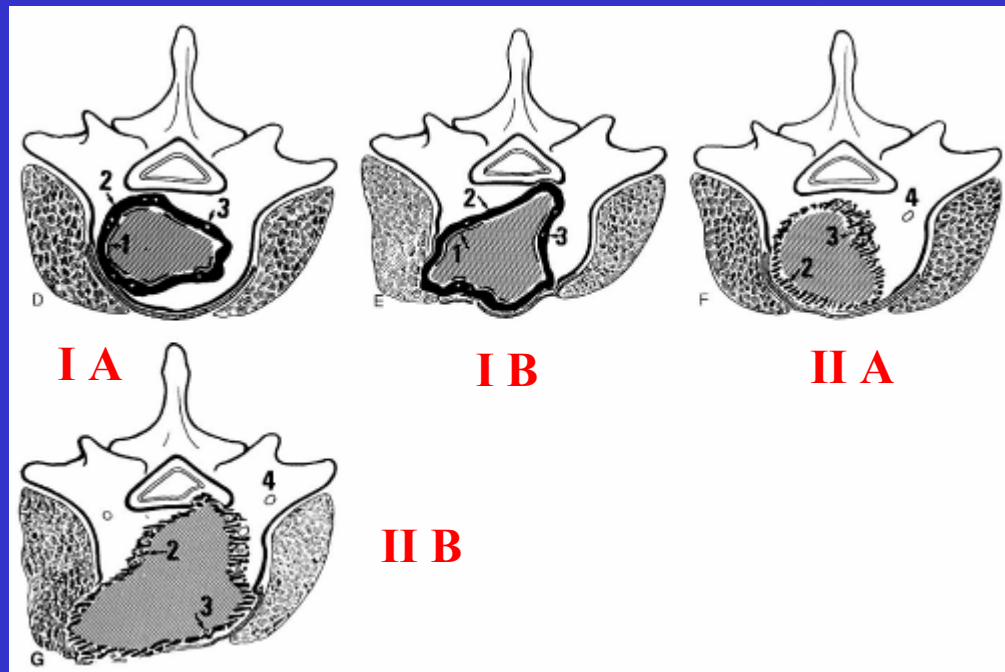
Total En Bloc Spondylectomy: A New Surgical Technique for Primary Malignant Vertebral Tumors

Tomita, Katsuro MD*; Kawahara, Norio MD*; Baba, Hisatoshi MD†; Tsuchiya, Hiroyuki MD*; Fujita, Takuya MD*; Toribatake, Yasumitsu MD*

Spine Volume 22(3), 1 February 1997, pp 324-333

SURGICAL STAGING

Type	Stage	Characteristics
Malignant	I	Low grade without metastases
	IA	Intracompartmental
	IB	Extracompartmental
	II	High grade without metastases
	IIA	Intracompartmental
	IIB	Extracompartmental
Low/high grade with metastases	III	Low/high grade with metastases
	IIIA	Intracompartmental
	IIIB	Extracompartmental



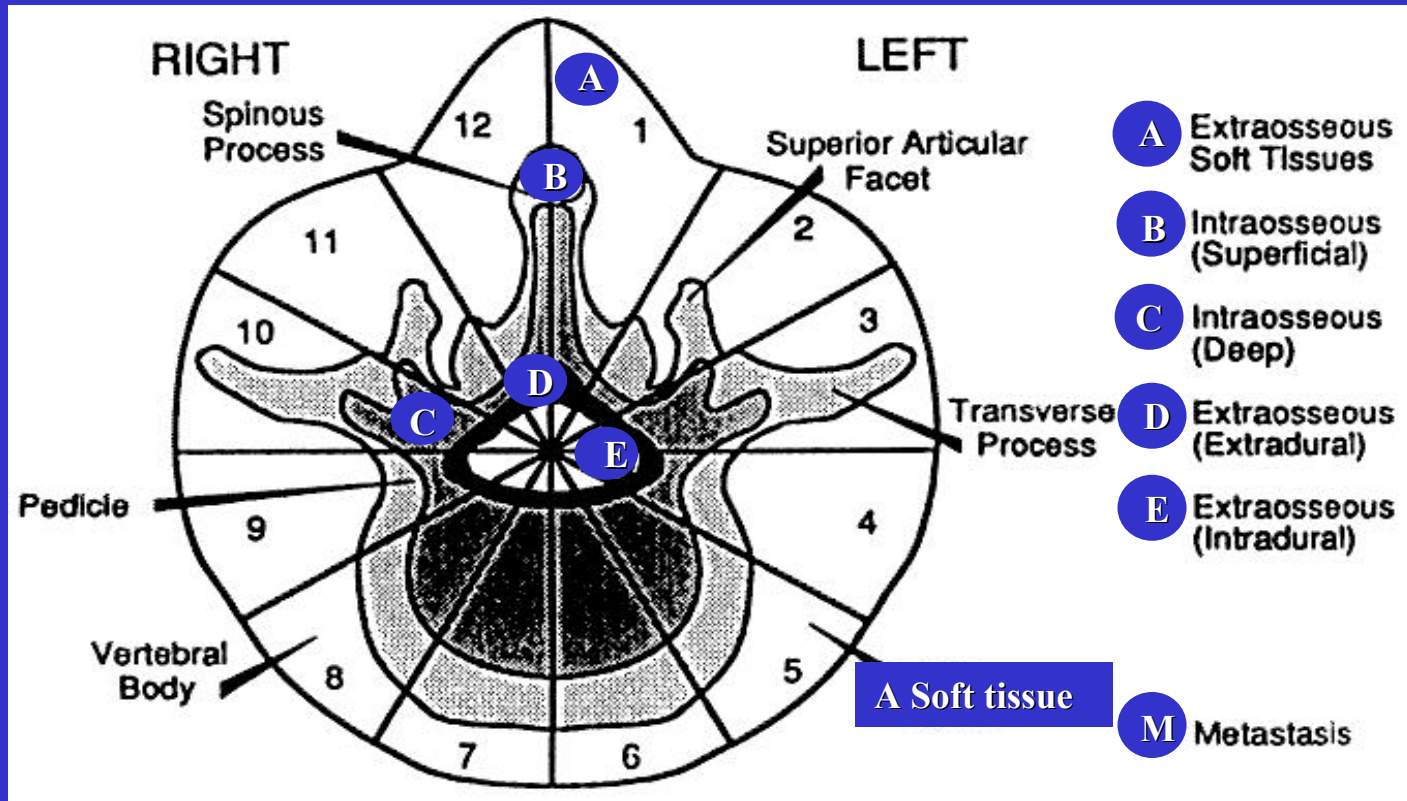
Enneking WF:

A system of staging musculoskeletal neoplasms.

Clin Orthop 1986, 204:9-24

	Stage IA	Stage IB	Stage IIA	Stage IIB
Grade	G1	G1	G2	G2
Site	T1	T2	T1	T2
Metastasis	M0	M0	M0	M0
Clinical course	Symptomatic indolent growth	Symptomatic mass, indolent growth	Symptomatic rapid growth	Symptomatic rapid growth, fixed mass, pathologic fracture
Isotope scan	Increased uptake	Increased uptake	Increased uptake, beyond radiographic limits	Increased uptake, beyond radiographic limits
Radiographic grade	II	II	III	III
Angiogram	Modest neovascular reaction, involvement of neurovascular bundle	Modest neovascular reaction, involvement of neurovascular bundle	Marked neovascular reaction, no involvement of neurovascular bundle	Marked neovascular reaction, involvement of neurovascular bundle
CT scan	Irregular or broached capsule— intracompartmental	Extracompartmental extension or location	Broached (pseudo) capsule— intracompartmental	Broached (pseudo) capsule— extracompartmental

SURGICAL STAGING WBB (Weinstein, Boriani, Biagini)

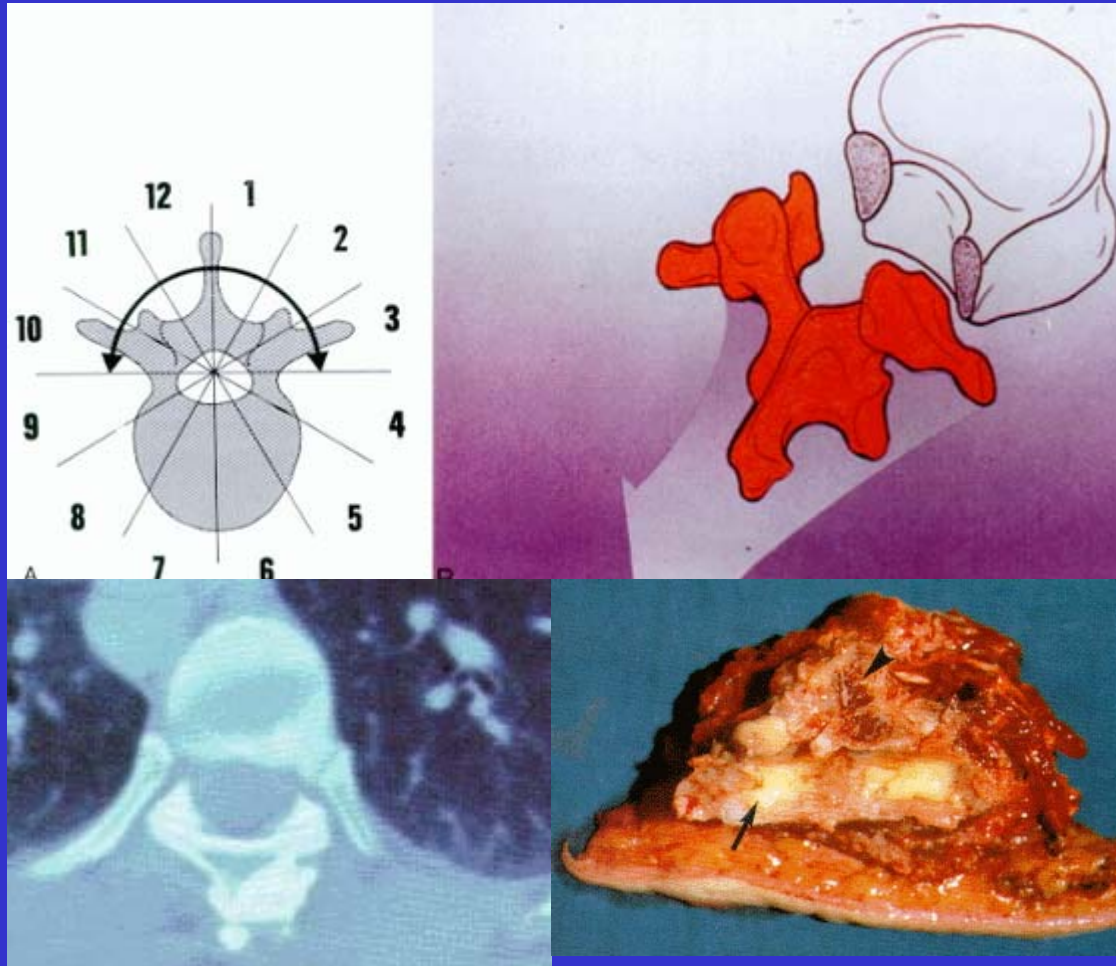


12 radiating zones (numbered 1 to 12 in a clockwise order)

5 concentric layers (A to E, from the paravertebral extraosseous compartments to the dural involvement)

The longitudinal extent of the tumor is recorded according to the levels involved.

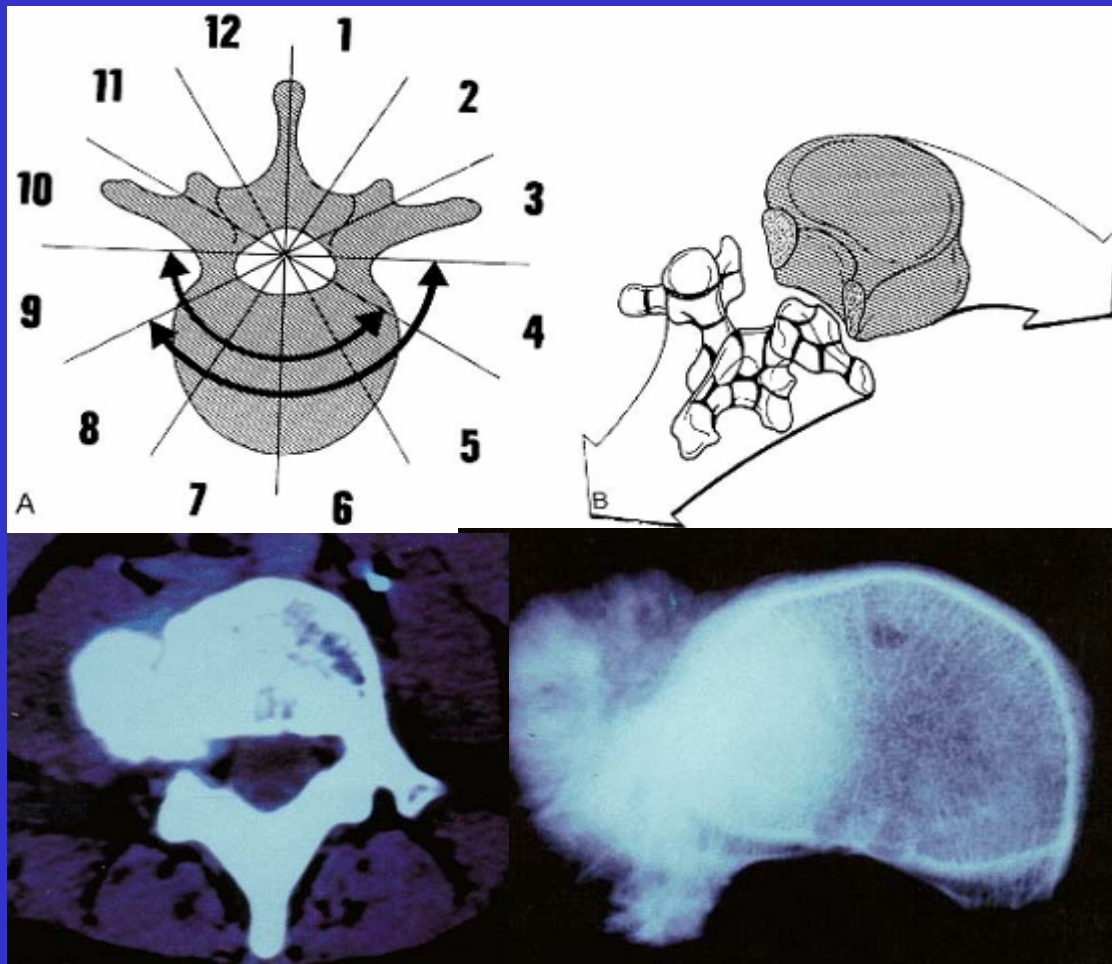
Posterior resection



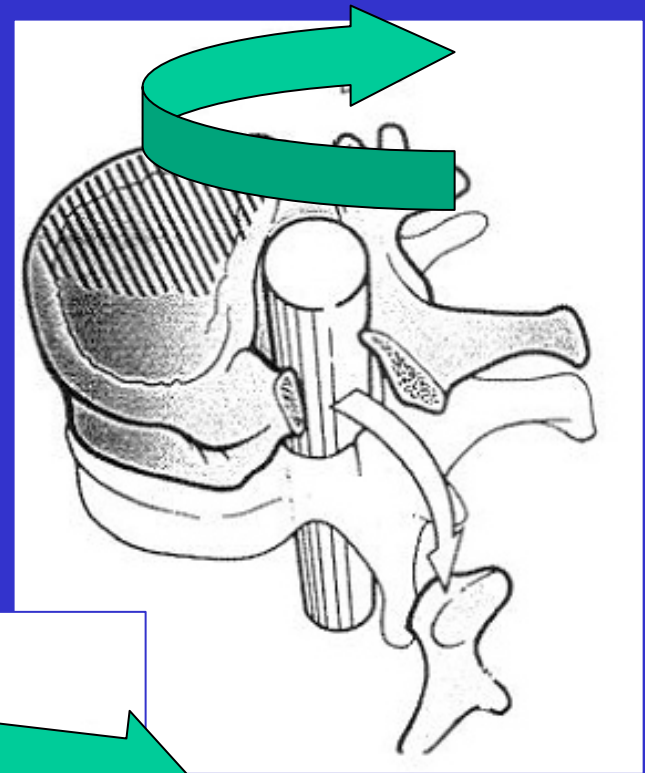
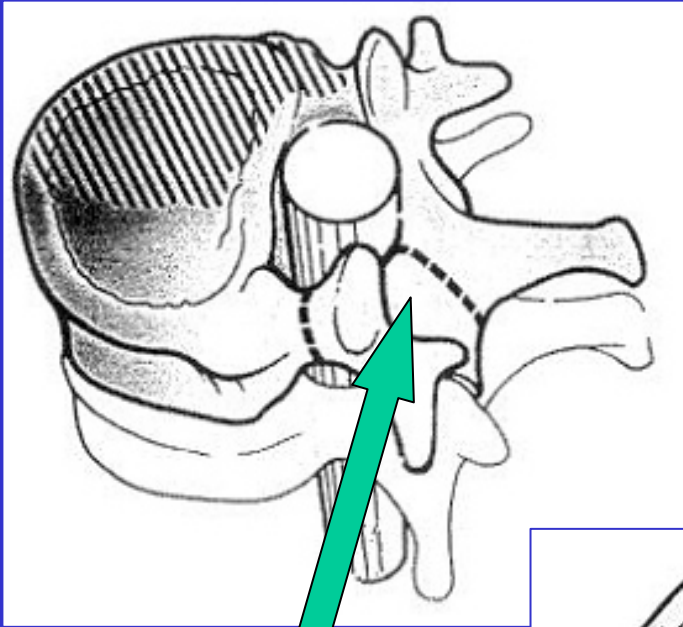
Recurrent chondrosarcoma of T8



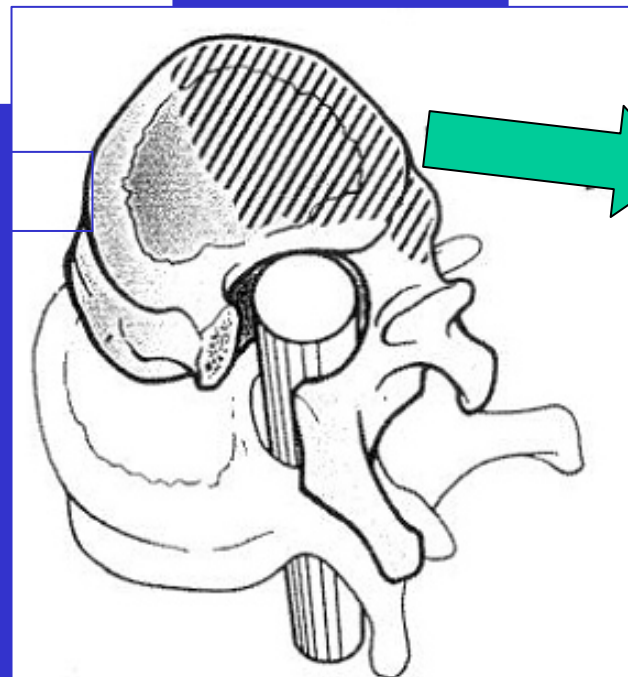
Anterior resection



L 4 metastatic osteosarcoma



Unilateral laminectomy



Total vertebrectomy for primary malignant tumours of the spine

Krepler, P.; Windhager, R.; Bretschneider, W.; Toma, C. D.; Kotz, R.

JBJS Volume 84-B(5), July 2002, pp 712-715

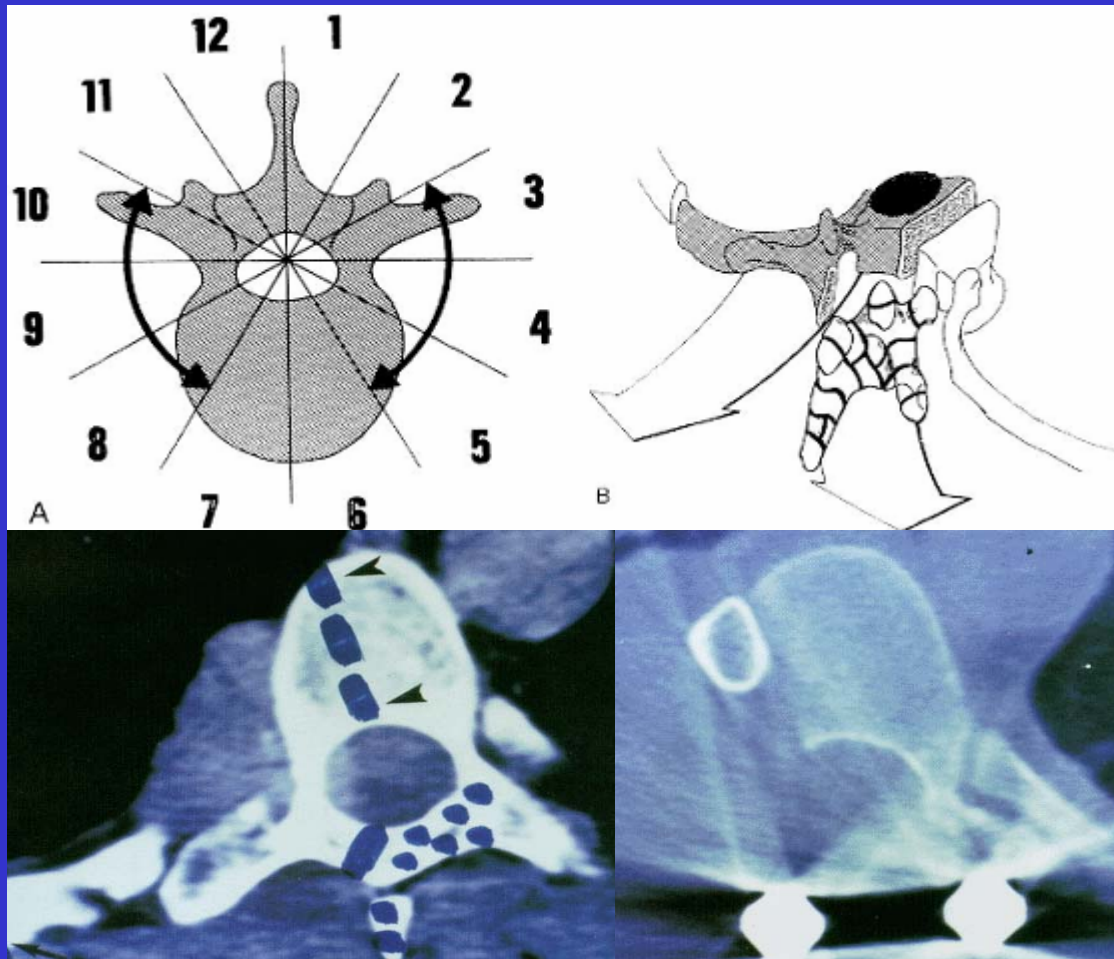
SURGERY 9. 1995

Prone position

Instrumentation L2 L4

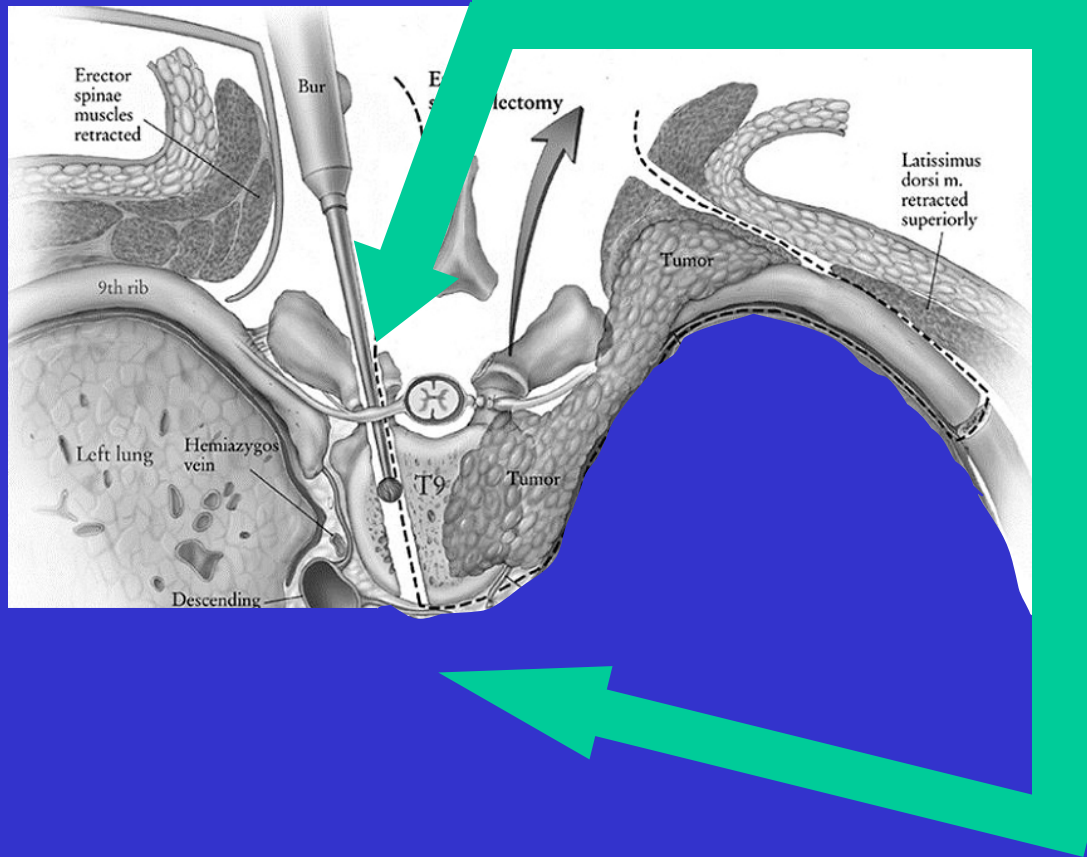
Intralesional resection

Sagittal resection



Liposarcoma arising from the foramen of T7

Sagittal resection



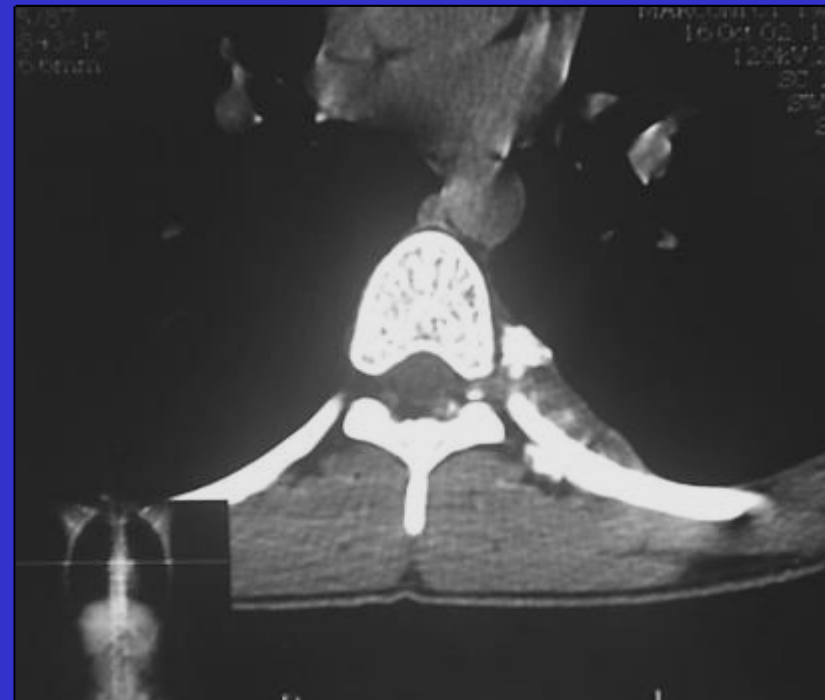
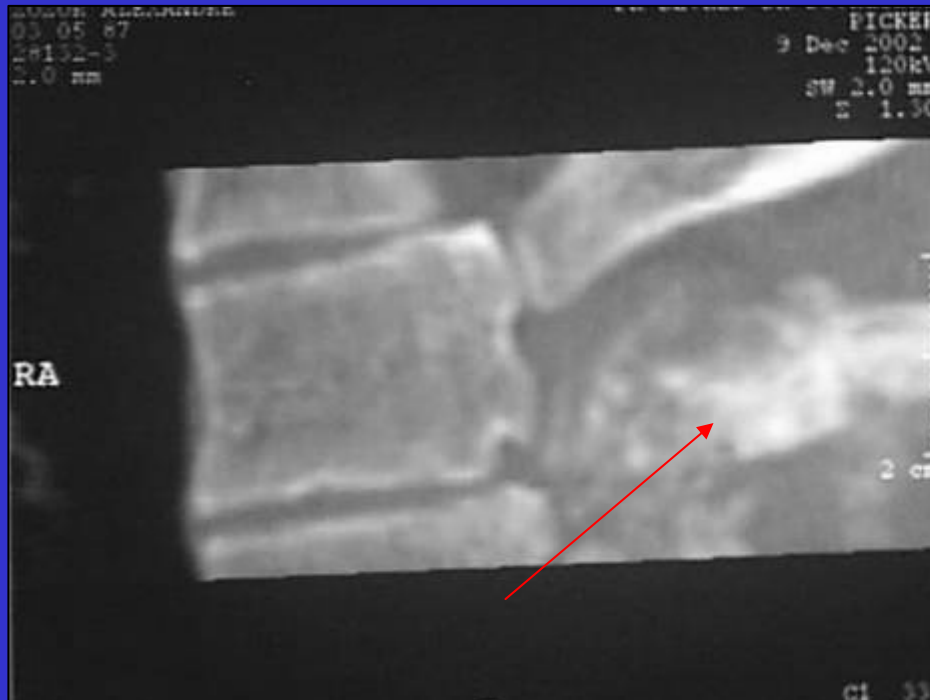The sagittal resection can be performed the patient in a prone position trough a single midline posterior skin incision

Sagittal resection

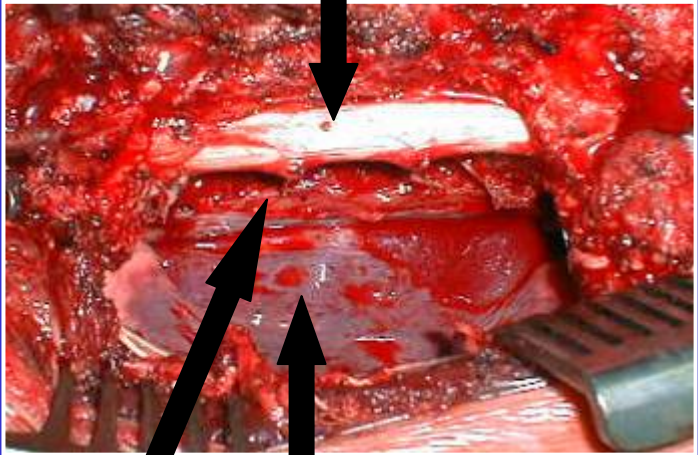
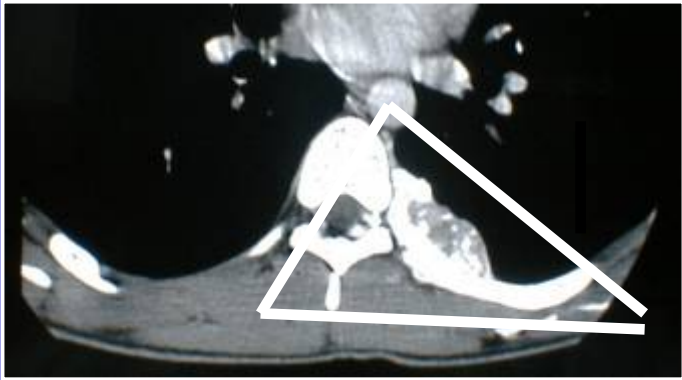
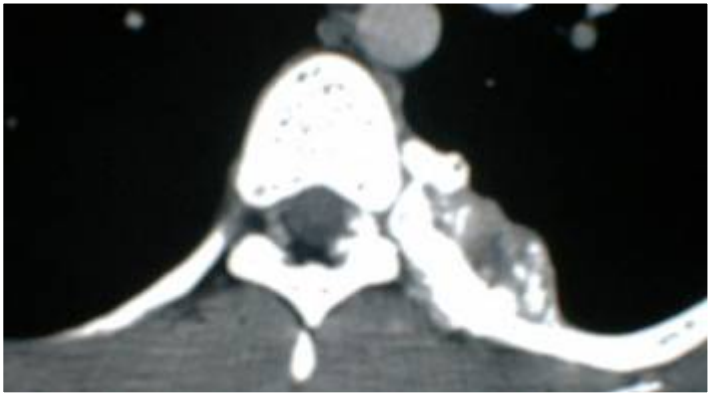
Osteosarcoma (bone metastasis of a femoral osteosarcoma)

Adjuvant chemotherapy

Sagittal resection



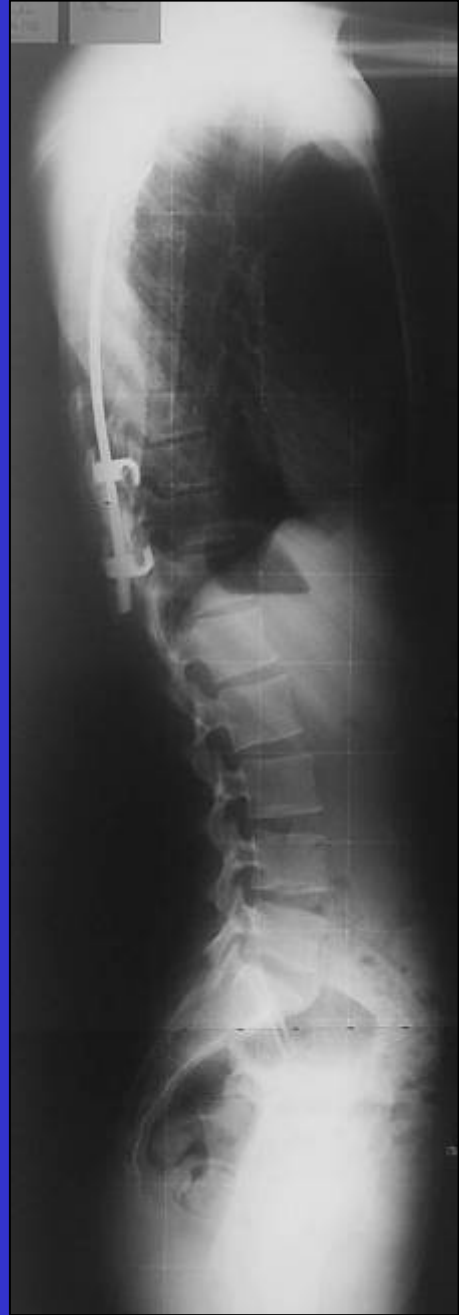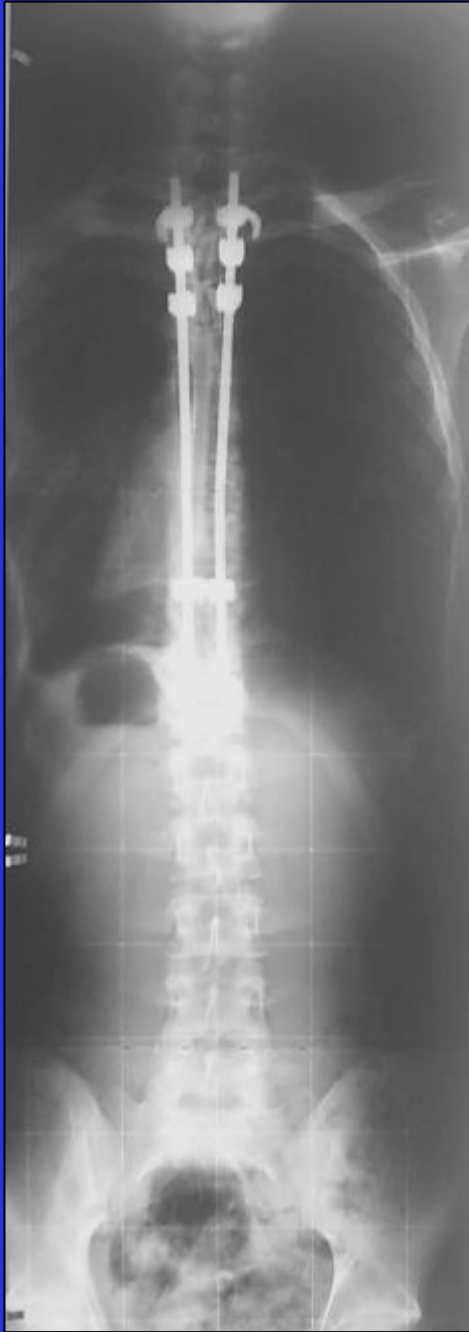Sagittal resection

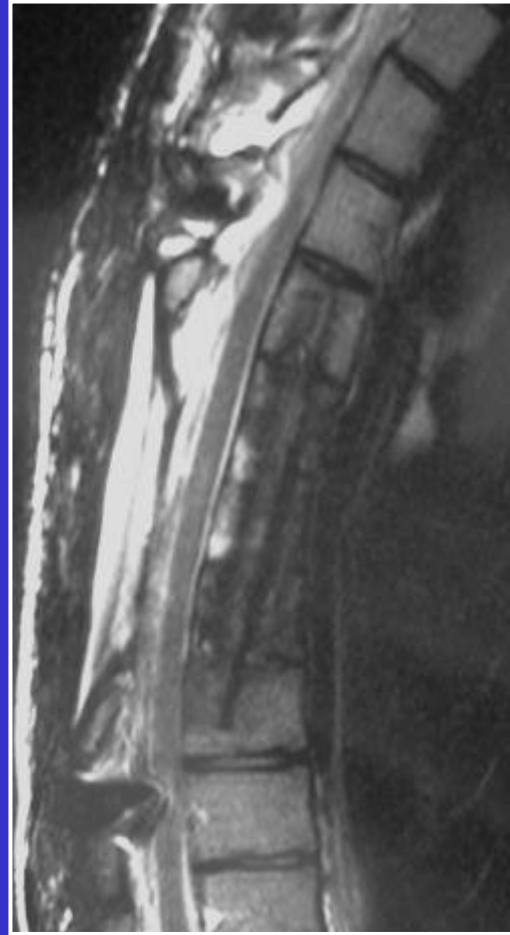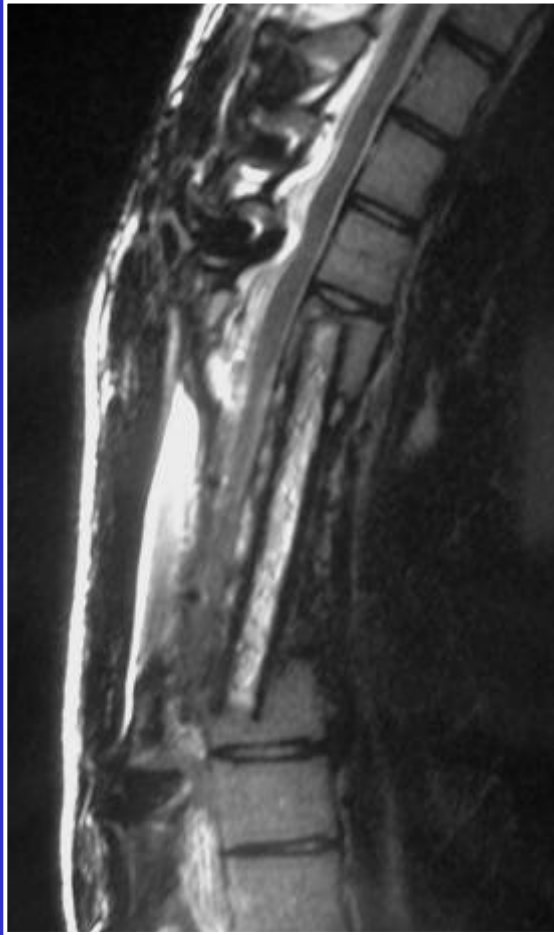


DURA MATTER

SPINE

LUNG





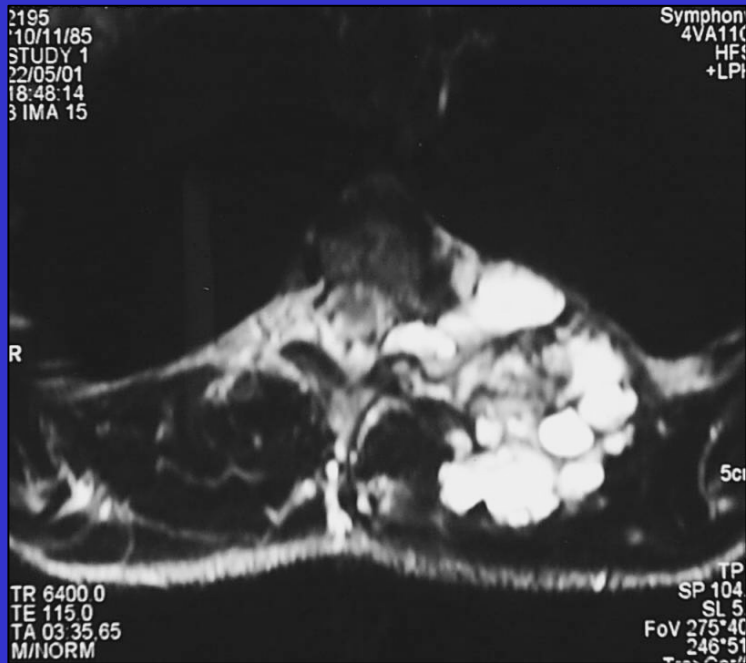

Died at two years F.U. from lung metastasis

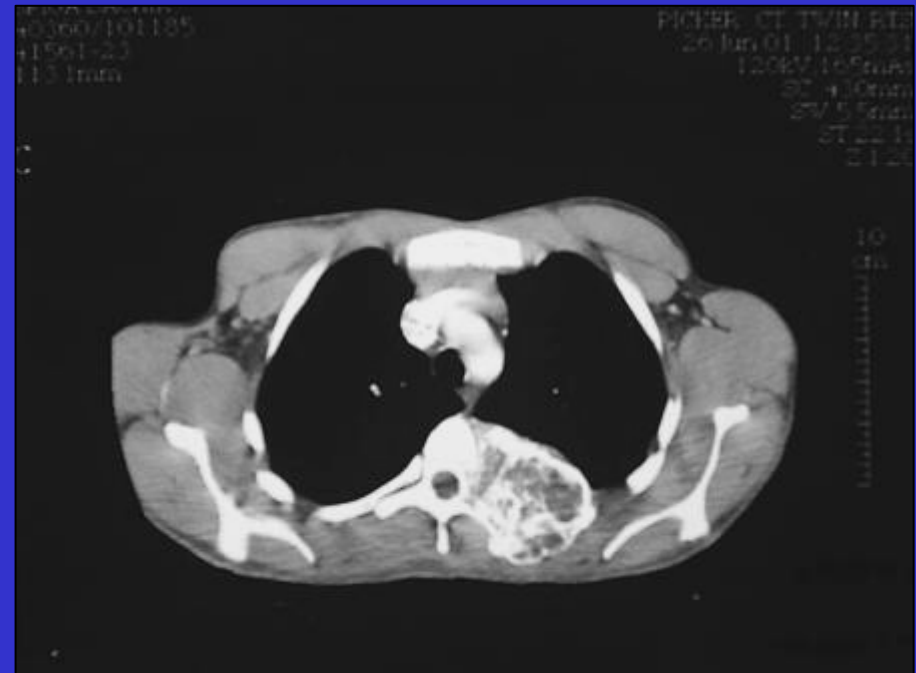No evidence of local recurrence

3/2001

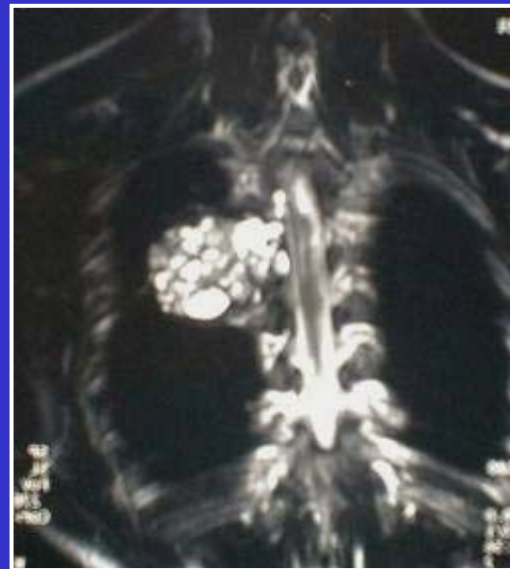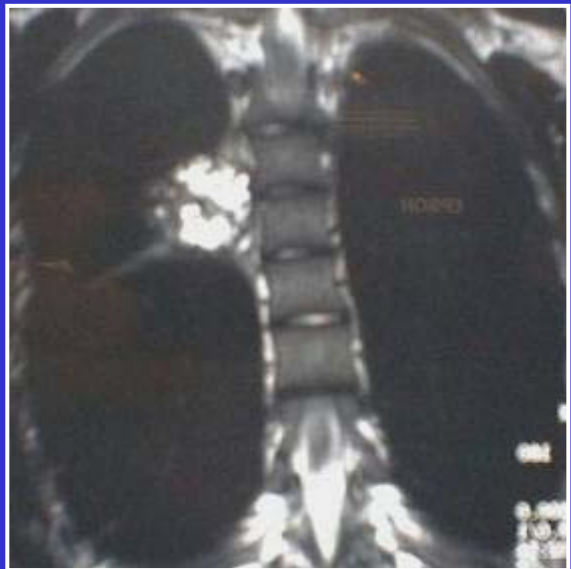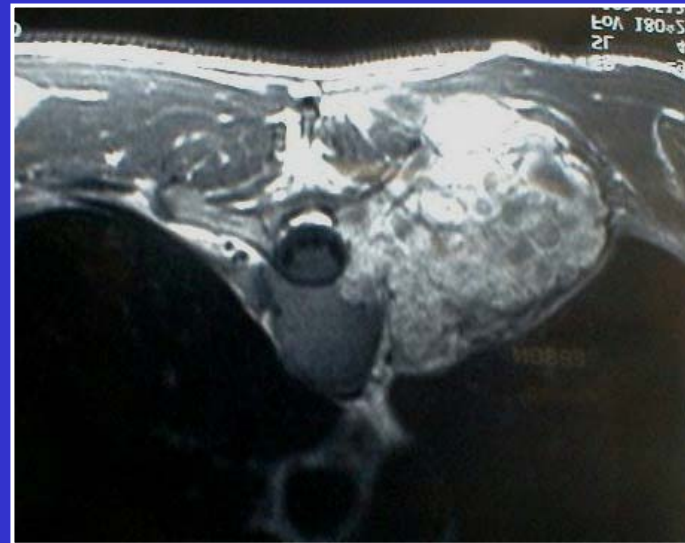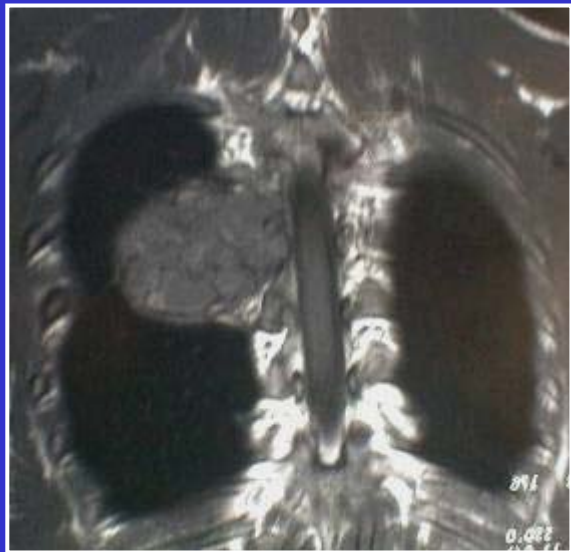
MRI



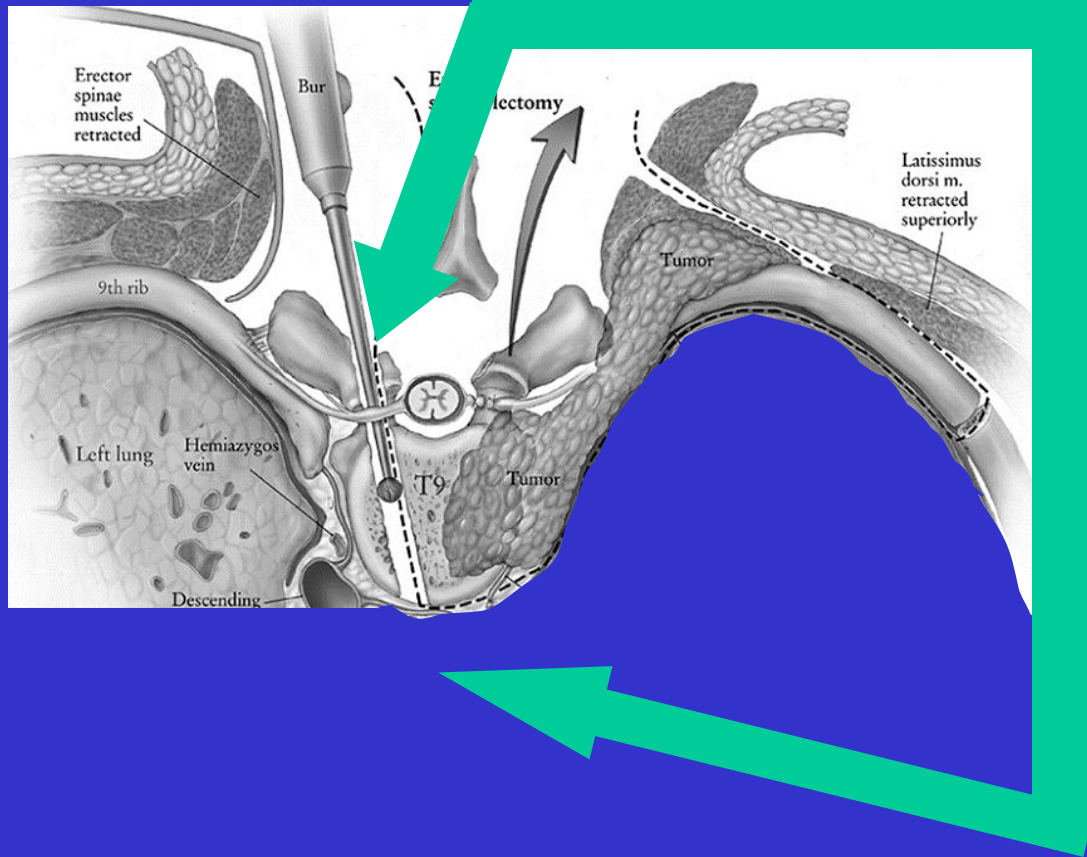
CT SCAN



Telangiectasic osteosarcoma



Sagittal resection



The sagittal resection can be performed the patient in a prone position trough a single midline posterior skin incision

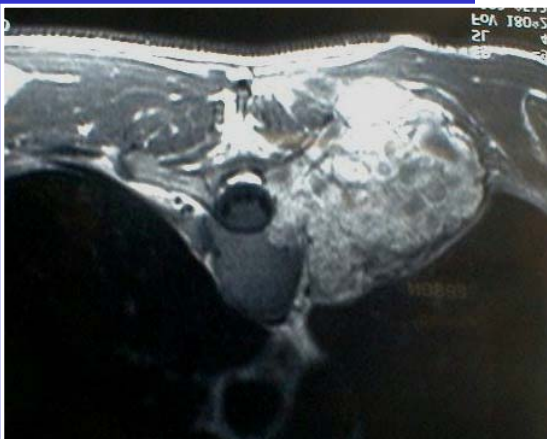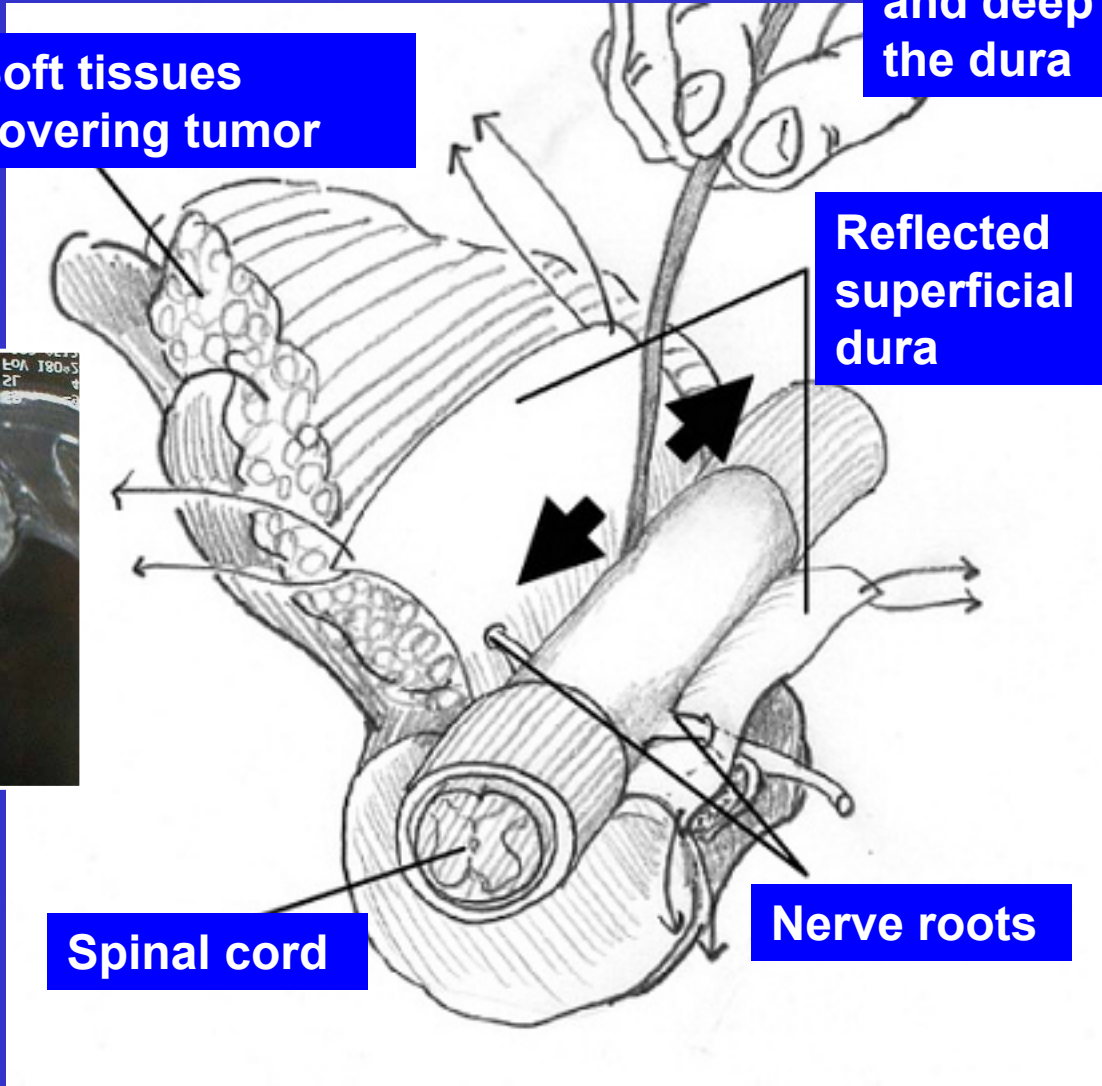
Dissecting the plane between superficial and deep layers of the dura

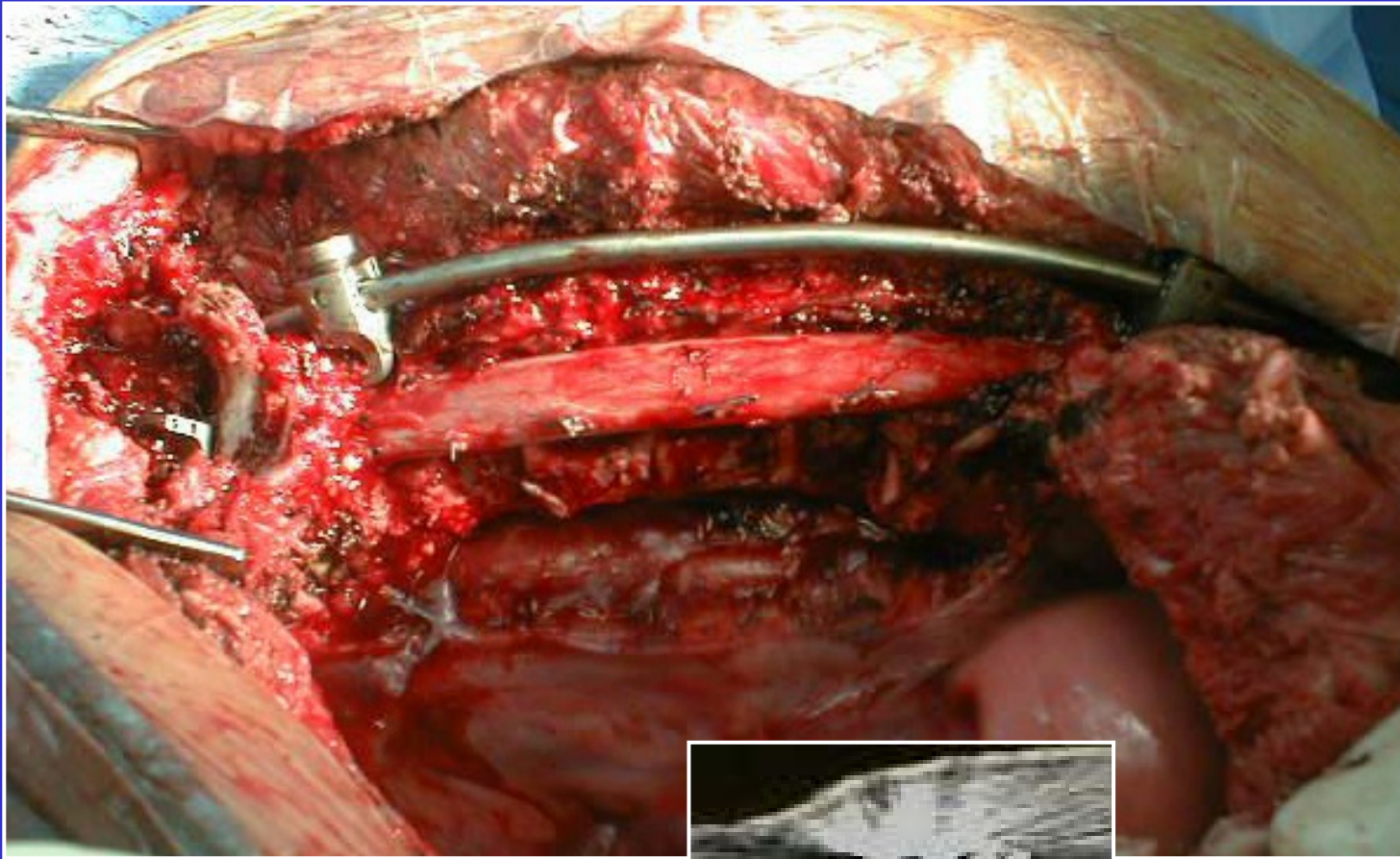
Soft tissues covering tumor

Reflected superficial dura

Spinal cord

Nerve roots






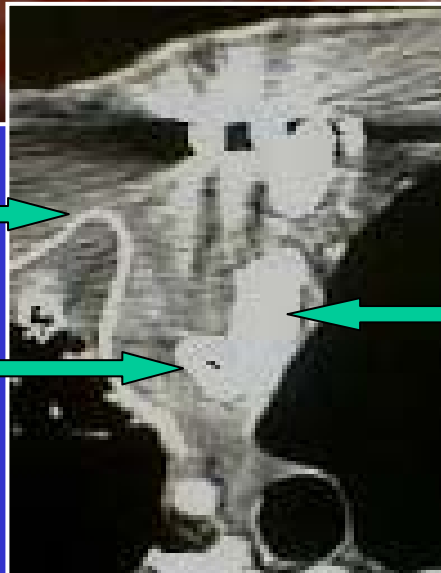
Artificial pad



Fibula



Hemi spine



SURGERY

4 hemi corporectomies

Non vascularized fibula anteriorly

Hardware and fusion posteriorly from T1 to T 9

Post operative complications :

Fibula displacement..... reoperated on

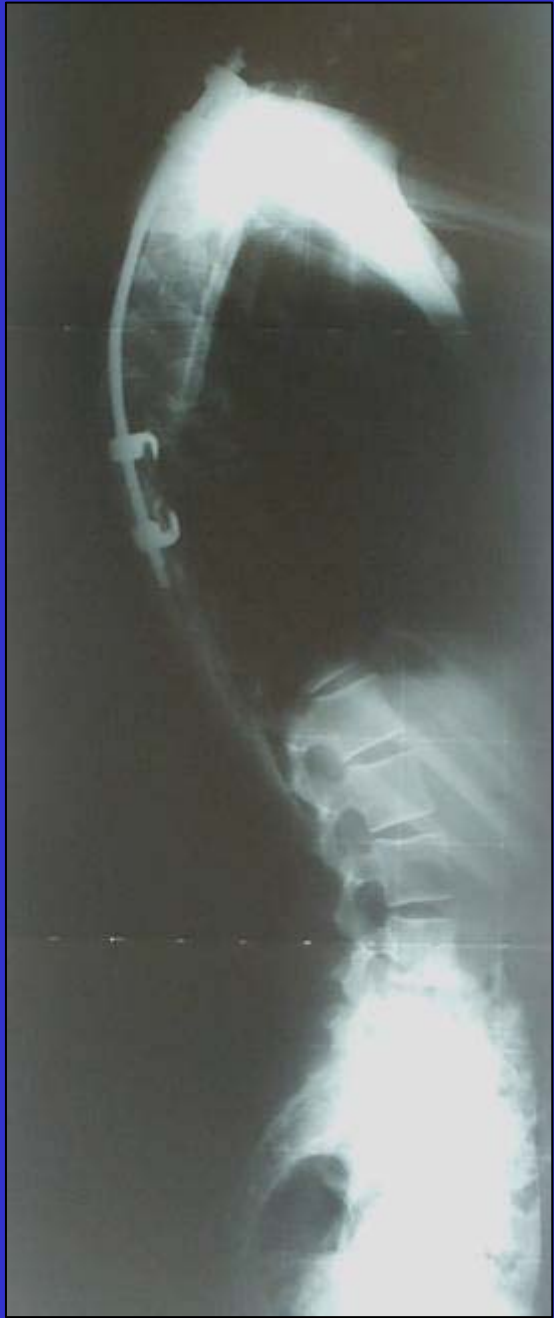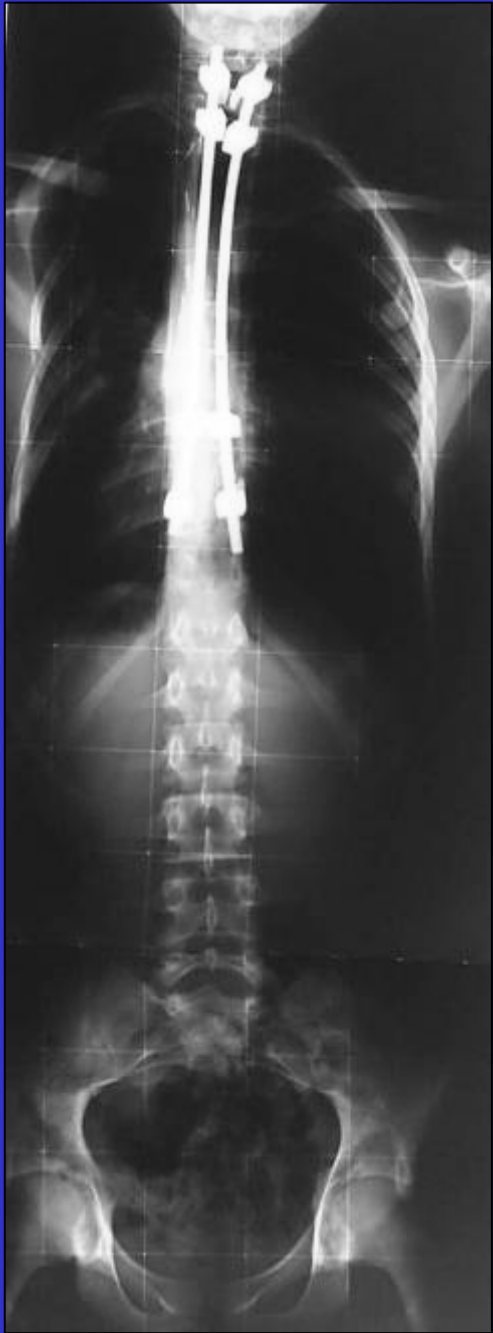Chylothorax

Margins: free of disease

18% of viable cells tumor

Post operative chemotherapy course

F.U. 6 years disease free





Prone position

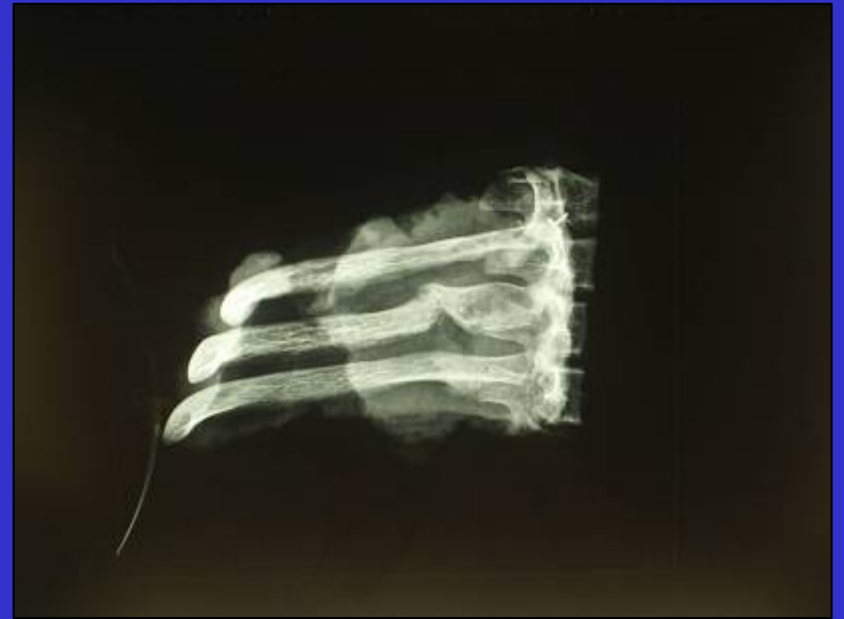Posterior single approach

3 Ribs

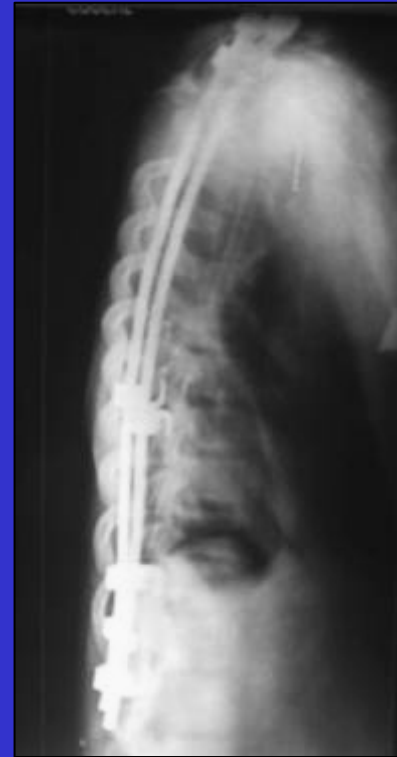
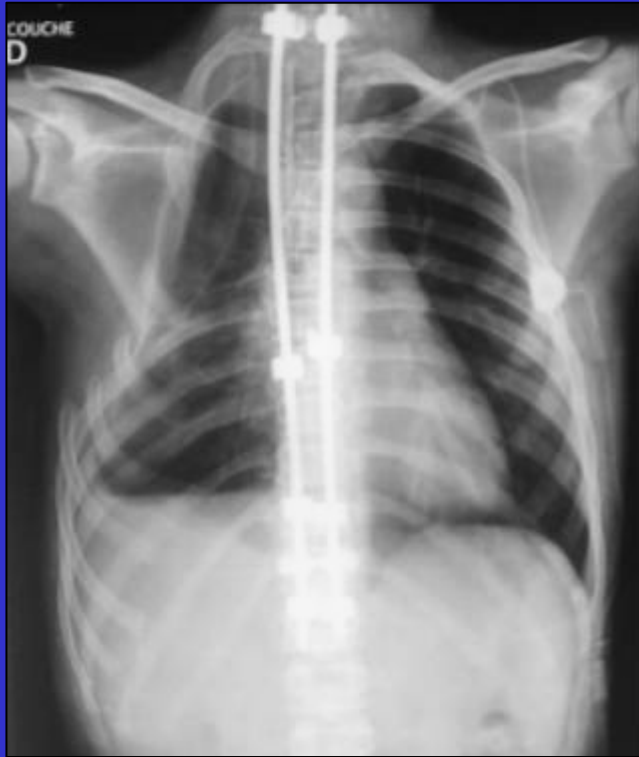4 hemispondylectomies

Fibula anteriorly

Hardware and fusion posteriorly



COMPLICATION



Right lower limb monoparesia post operatively

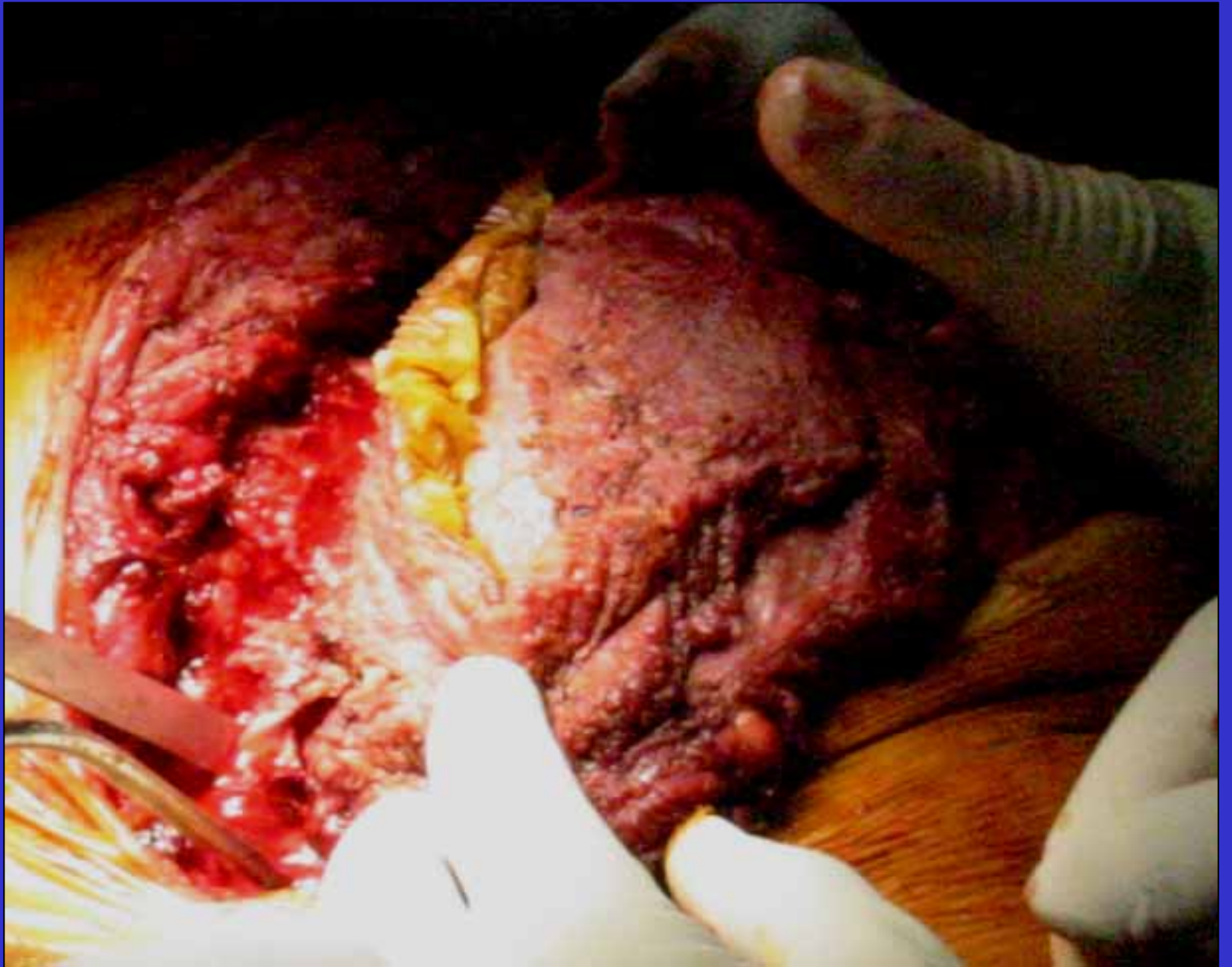Complete recovery at two years F.U.

Surgical decompression

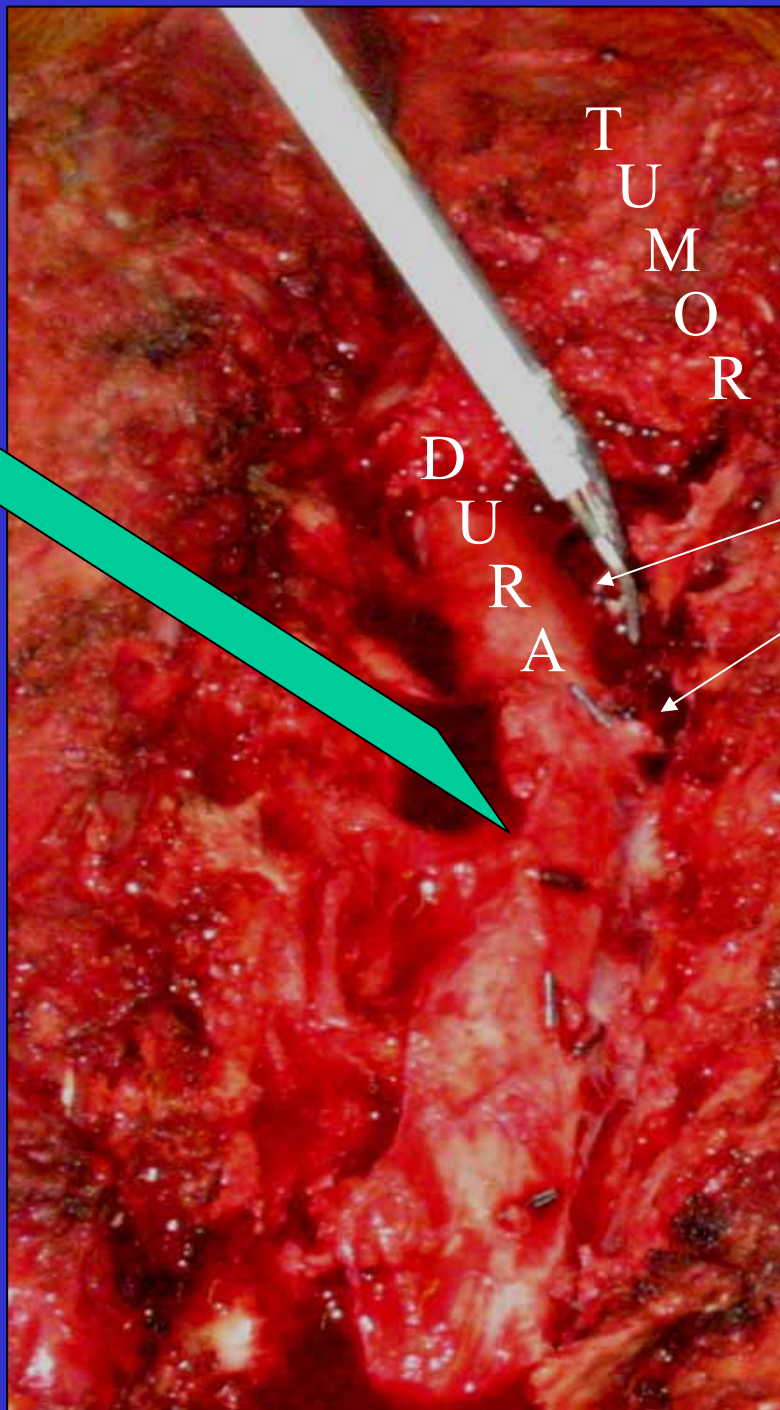
- Laminectomy
- Intratumoral resection

Post-op:

- 1/ regression of the paraplegia
- 2/ histology : PNET (Ewing)



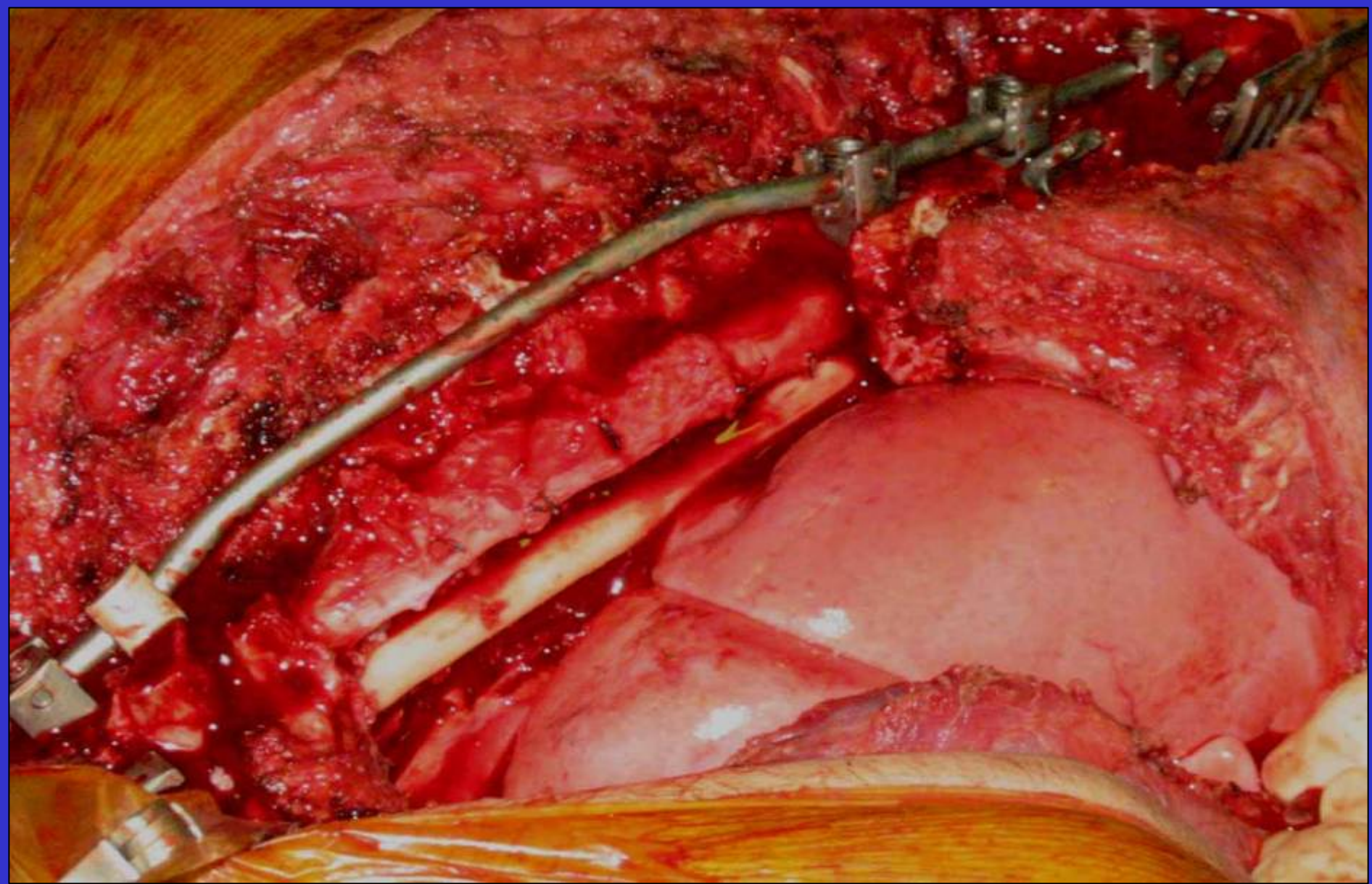
CISEL

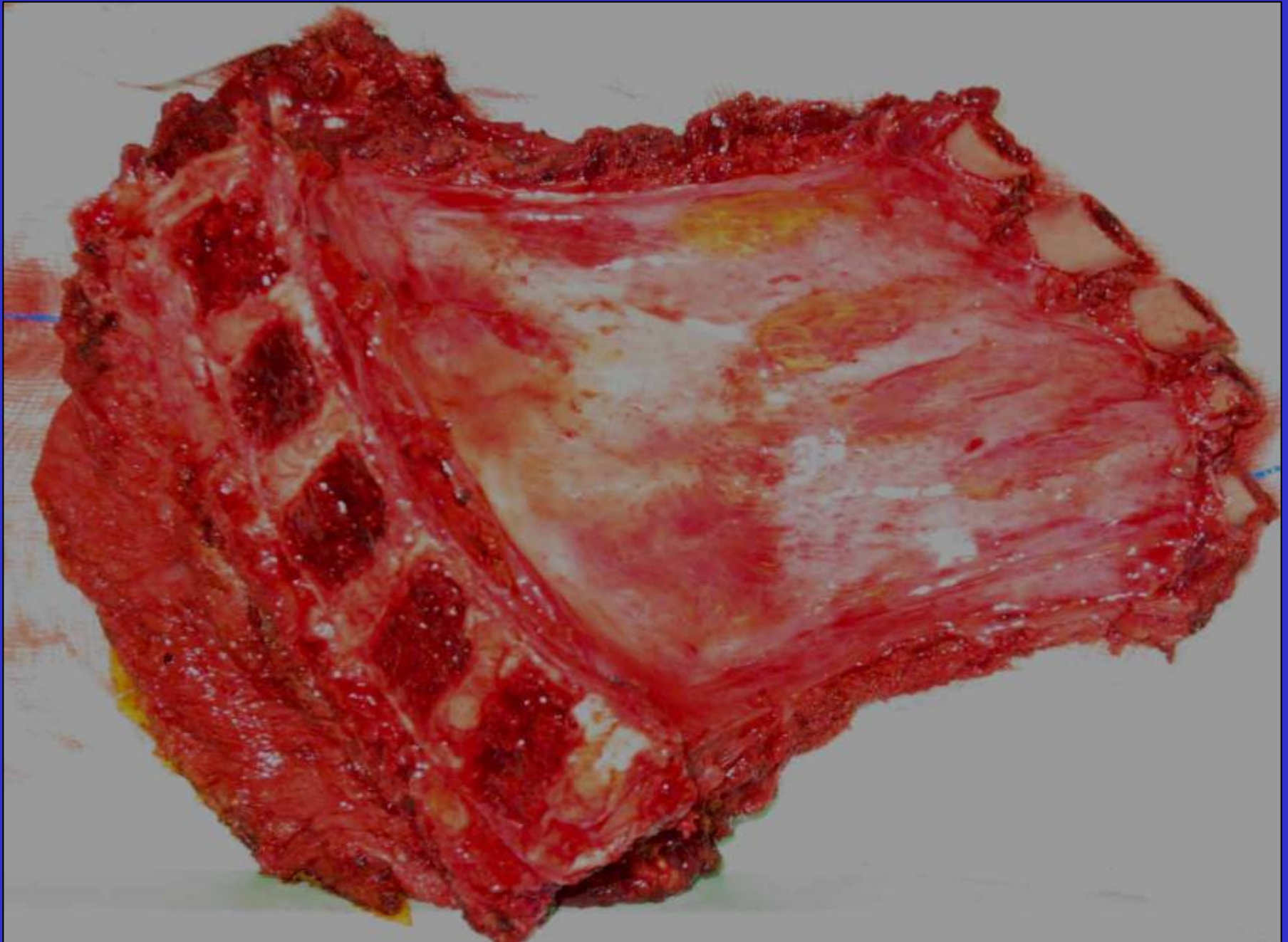


T
U
M
O
R

D
U
R
A

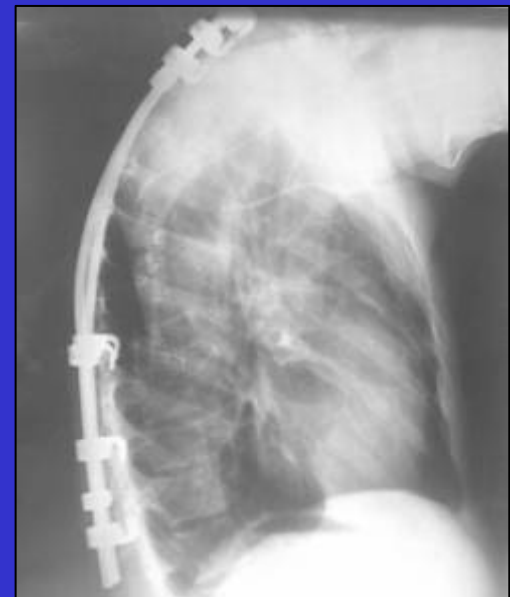
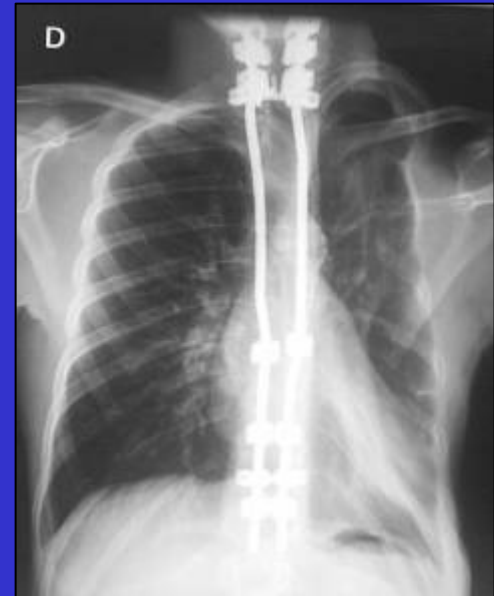Intercostal
nerve
roots on
the tumor
side to be
cut





Complications


- bleeding
- Left chest dysesthesia
- 4 Years F.U. disease free



Surgery is very demanding

Surgery needs surgeons expert in both spinal and tumor surgery

Surgery leads to complications



Is surgery really usefull for such patients ?

Tumor type	Number of Patients	Positive Margins	Local Recurrences
Chondrosarcoma	9	2	3
Osteosarcoma	7	6	5
Ewing's sarcoma	7	5	1
Liposarcoma	1	0	0
Hemangioendothelial sarcoma	1	1	0
Giant cell tumor	1	0	0
Malignant fibrous histiocytoma	2	1	1
Epithelial sarcoma	1	1	1
Myofibroblastic sarcoma	1	0	1

30

16

12

11 Died




Relationship Between Surgical Margins and Local Recurrence in Sarcomas of the Spine

Talac, Robert MD, PhD; Yaszemski, Michael J. MD, PhD; Currier, Bradford L. MD; Fuchs, Bruno MD; Dekutoski, Mark B. MD; Kim, Choll W. MD, PhD; Sim, Franklin H. MD,

Clin Orthop Rel Res Volume 397, April 2002, pp 127-132

PROGNOSIS

82 patients with primary neoplasm of the spine



Radiotherapy alone in Ewing sarcoma

2 of 22 (9%) patients with Ewing Sarcoma involving the trunk survived 5 years after treatment with radiation therapy alone

The curability of Ewing's endothelioma of bone in children

Phillips RF, Higinbotham NL. J Pediatr 1967 ; 70: 391 - 7

5 years survival rate < 19 % in patients with Ewing Sarcoma involving the trunk after treatment with radiation therapy alone

Ewing's sarcoma of bone. Experience with 140 patients

Wilkins RM, Pritchard DJ, Burger EO Jr and al Cancer (Phila) 1986 ; 58: 2551 – 5.

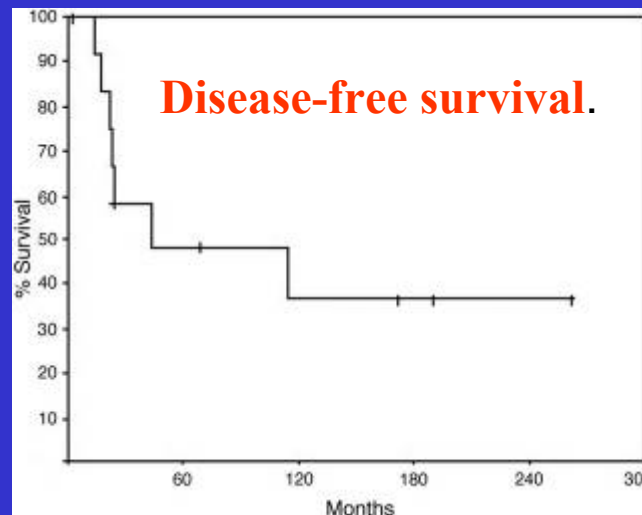
Radiotherapy + Chemotherapy in Ewing sarcoma

3 patients developed a local recurrence

5 / 13 patients disease free at last F.U

Disease-free survival rate 46% at 5 years

34% at 10 years



Ewing's Sarcoma of the Mobile Spine

Marco, Rex A. W. MD*; Gentry, J Brett MD†; Rhines, Laurence D. MD‡; Lewis, Valerae O. MD¶; Wolinski, J P. MD§; Jaffe, Norman MD†; Gokaslan, Ziya L. MD§

Spine Volume 30(7), 1 April 2005, pp 769-773

GOLD STANDARD FOR THE MANAGEMENT OF MALIGNANT SPINAL TUMOR IN CHILDREN

Biopsy ideally per cutaneously CT guided

Neo adjuvant chemotherapy

MRI + CT scan to know exactly the limits of the tumor

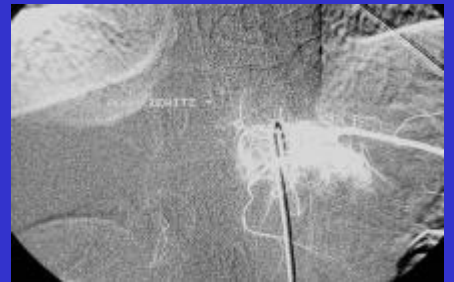Spinal arteriography for Adamkievitch +/- embolization

Surgery if cord compression

En bloc resection as often as possible

Stabilization and fusion (hardware allowing control MRI)

Post operative chemotherapy according to Huvos grading

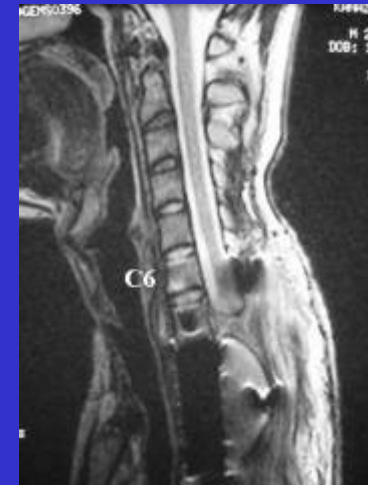
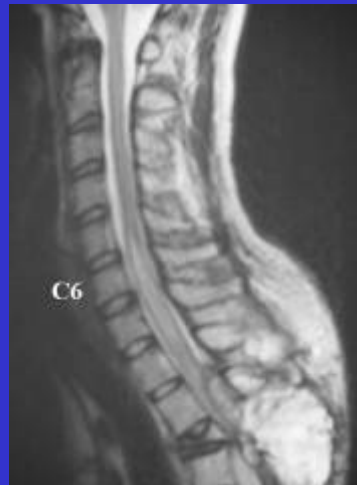
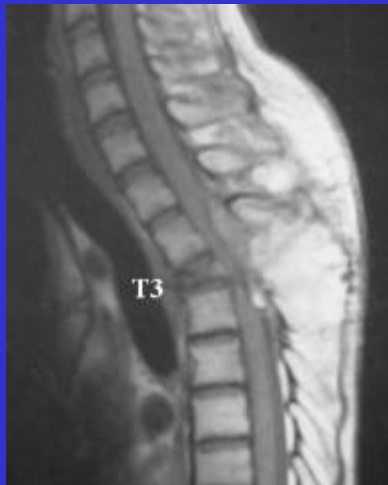
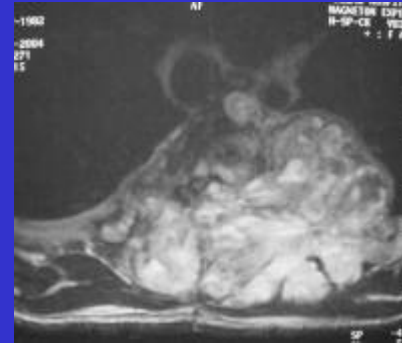
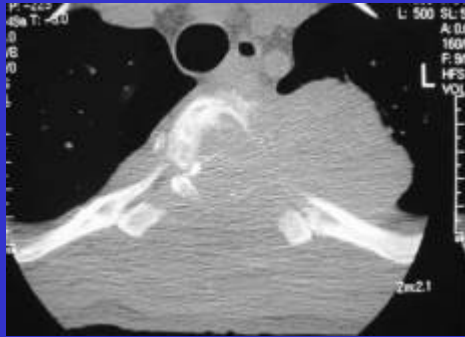


As far as a en bloc resection can be performed the prognosis is now the same that the one of the limbs malignant tumors

2 Telangiectasic Osteosarcomas; 21 and 57 Years old paraplegic patients

Segmental resection of the spine including the spinal cord

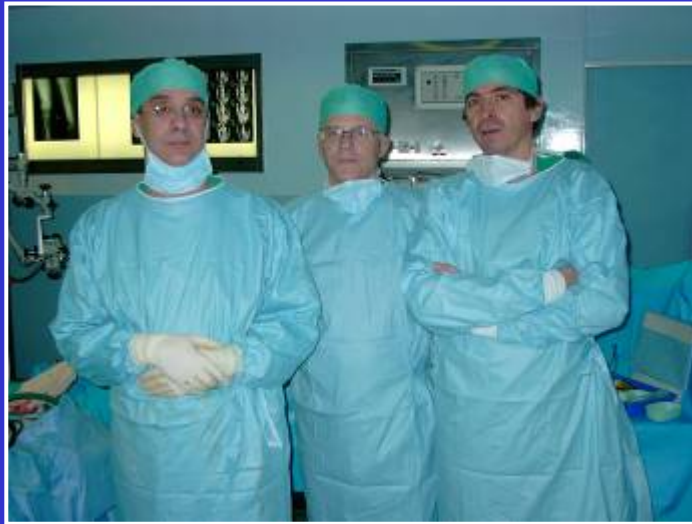Both patients died 6 months after surgery



Complete Segmental Resection of the Spine, Including the Spinal Cord, for Telangiectatic Osteosarcoma: A Report of 2 Cases
Murakami, Hideki MD*; Tomita, Katsuro MD*; Kawahara, Norio MD†; Oda, Makoto MD‡; Yahata, Tetsutaro MD*; Yamaguchi, Takehiko MD‡

Spine Volume 31(4), 15 February 2006, pp E117-E122

J.L.Jouve G.Bollini R.Legré



C. Coze J.C.Gentet



C.Bouvier M.Chrestian



M.Panuel P.Petit

