



Collège Hospitalier et Universitaire
de Chirurgie Pédiatrique

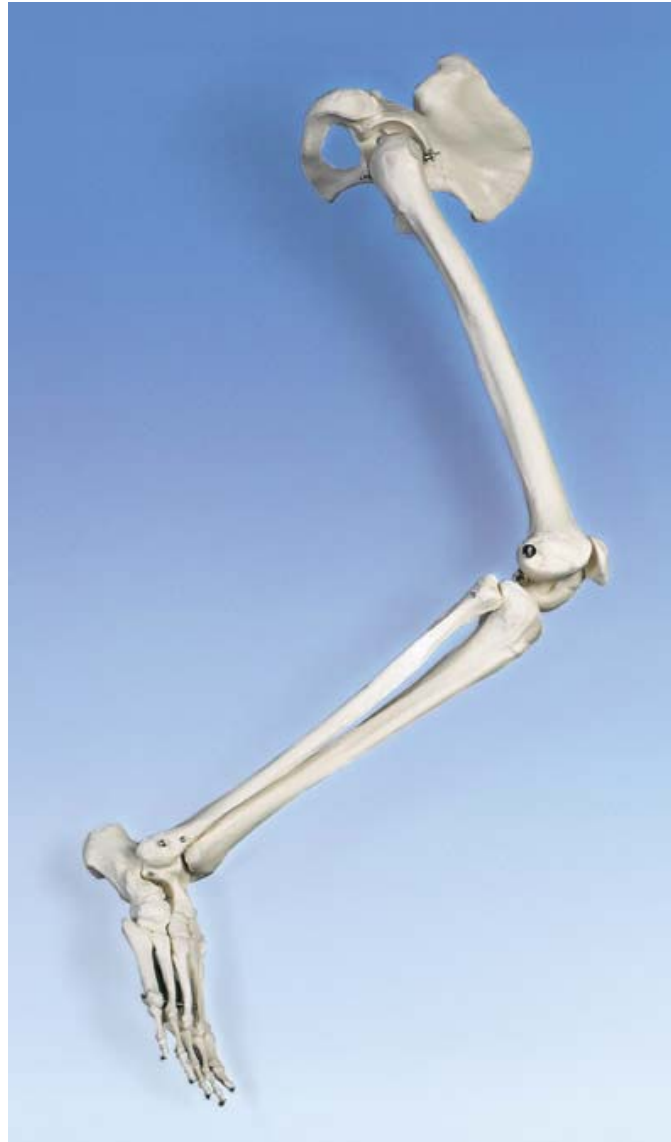DESC de Chirurgie Pédiatrique

Session de Septembre 2010 - PARIS

Fractures des membres inférieurs Fractures du Rachis

R VIALLE

Problématiques pédiatriques



Diaphyse

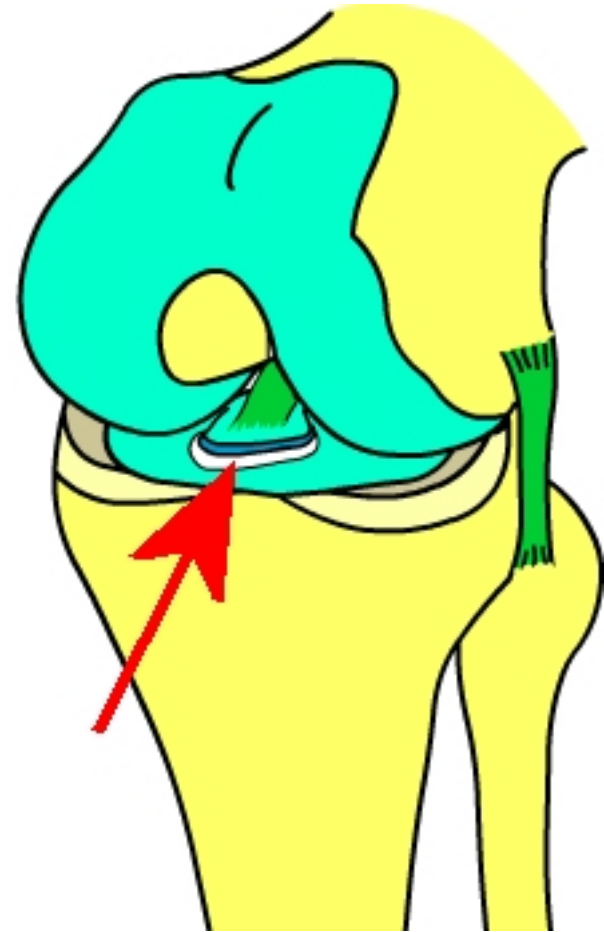

Epiphyse inférieure

Epines tibiales

Patella

TTA

Epines tibiales



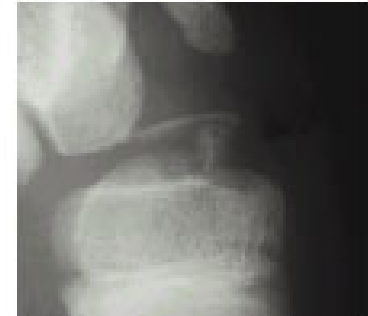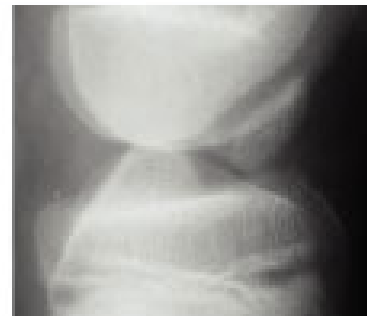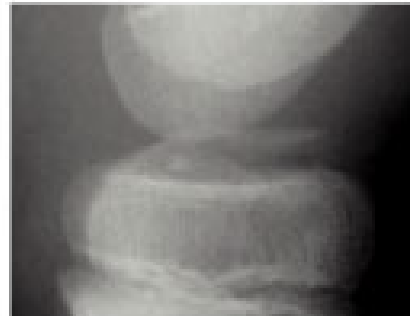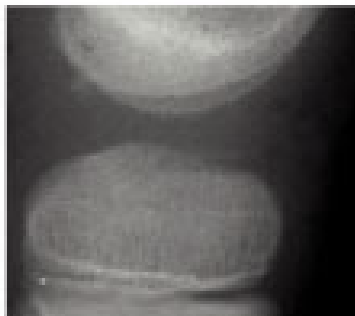
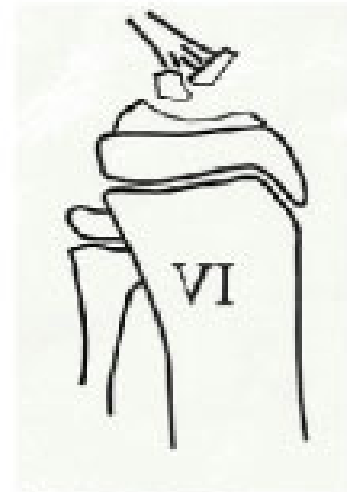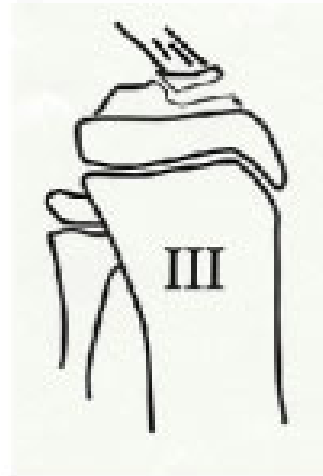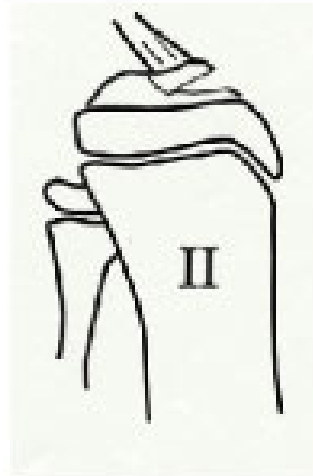
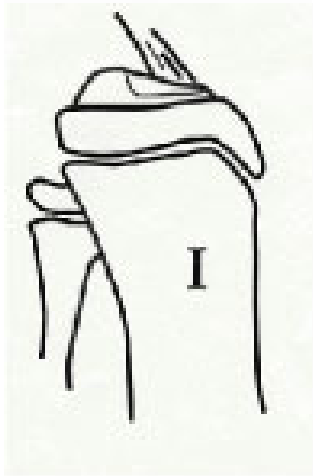Mécanisme = LCA

Epines tibiales

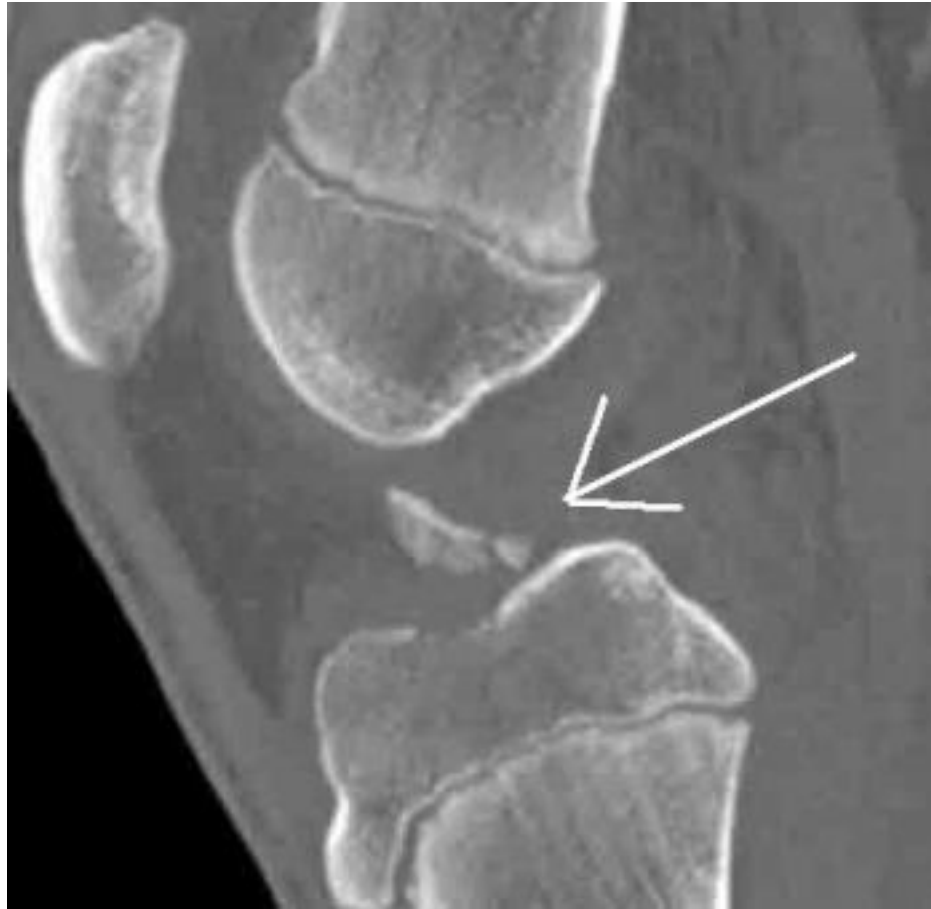

Epines tibiales

Classification de Meyers et Mc Keever

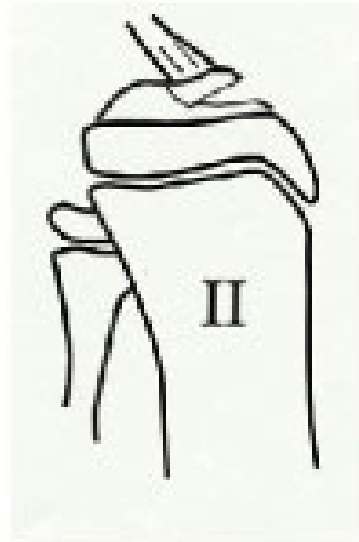
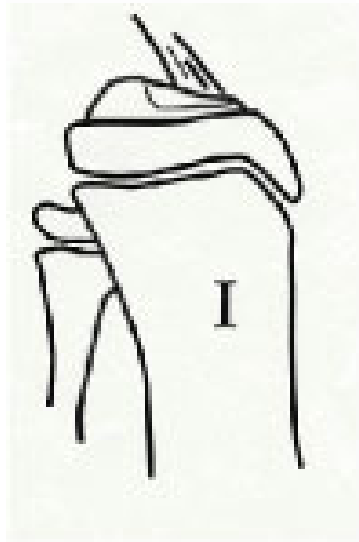

Epines tibiales



Stade 3

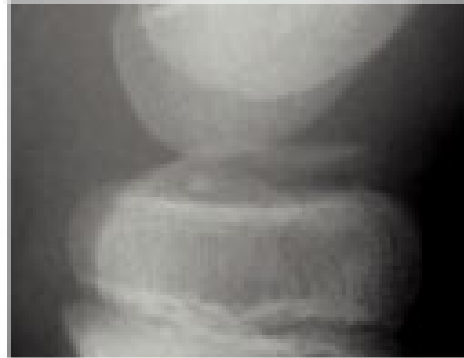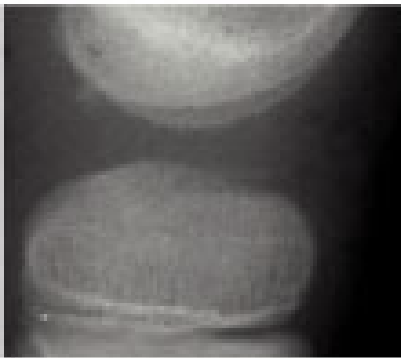
Epines tibiales



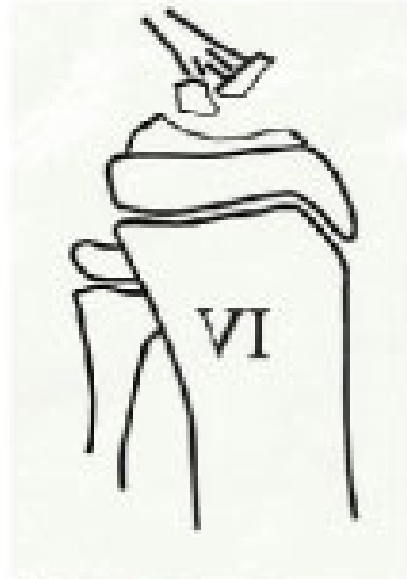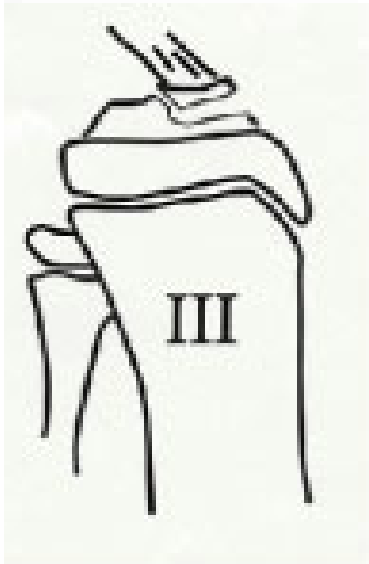Ponction articulaire
(hémarthrose)

Mise en extension du genou

Genouillère en extension
Tolérance



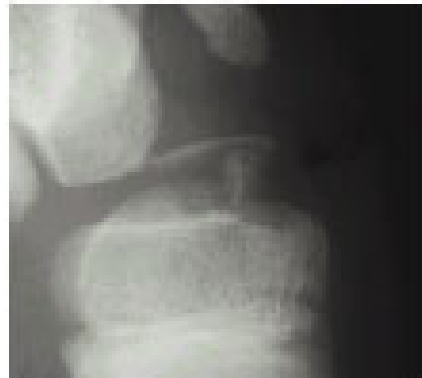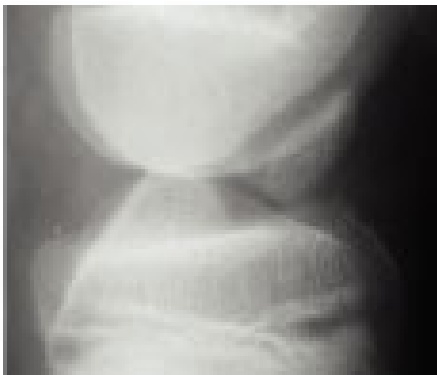Epines tibiales



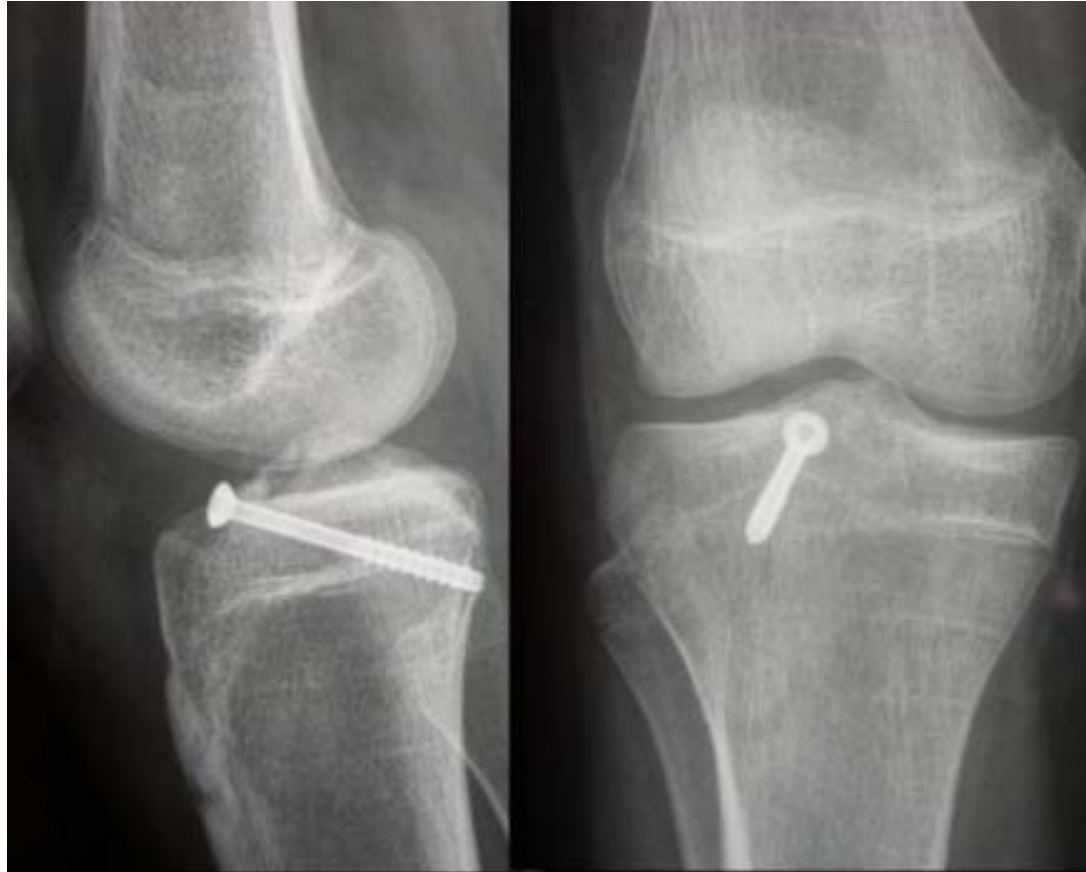Réduction

Fixation chirurgicale

Arthroscopie

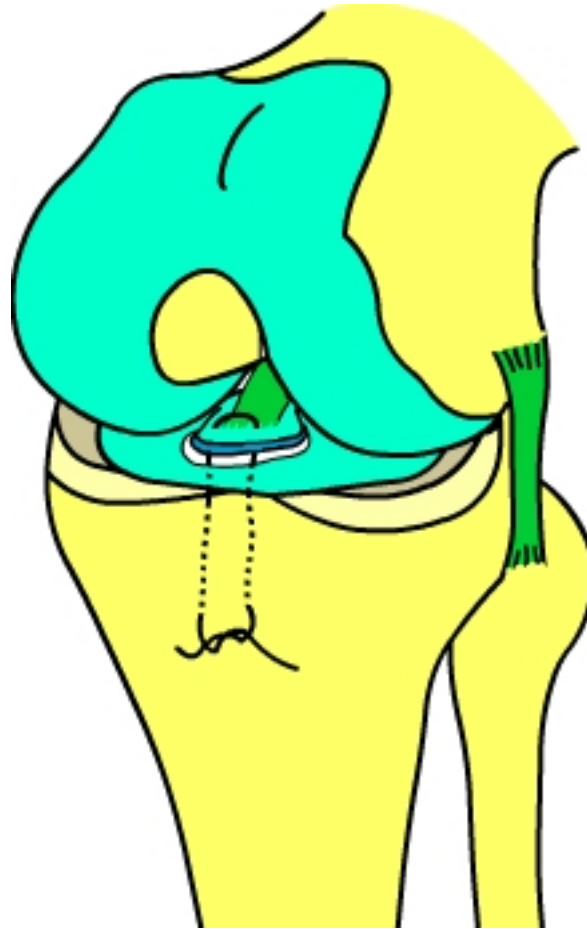


Epines tibiales



Proche de la fin de la croissance

Epines tibiales



Laçage (avant la fin de la croissance)

Problématiques pédiatriques



Diaphyse

Epiphyse inférieure

Epines tibiales

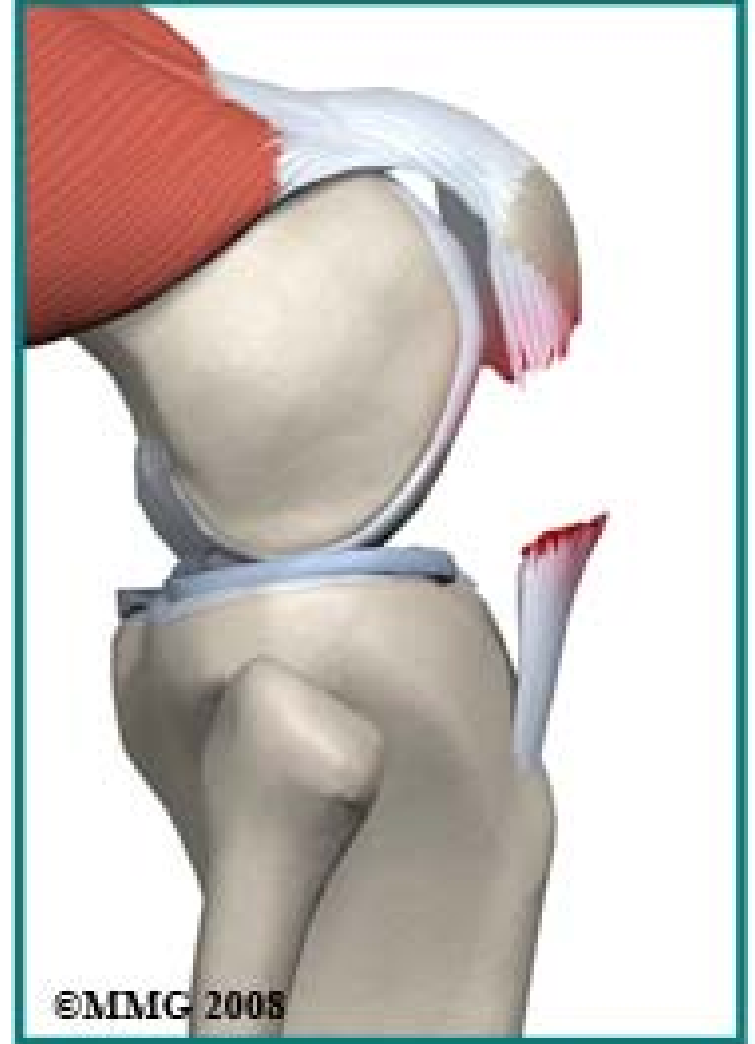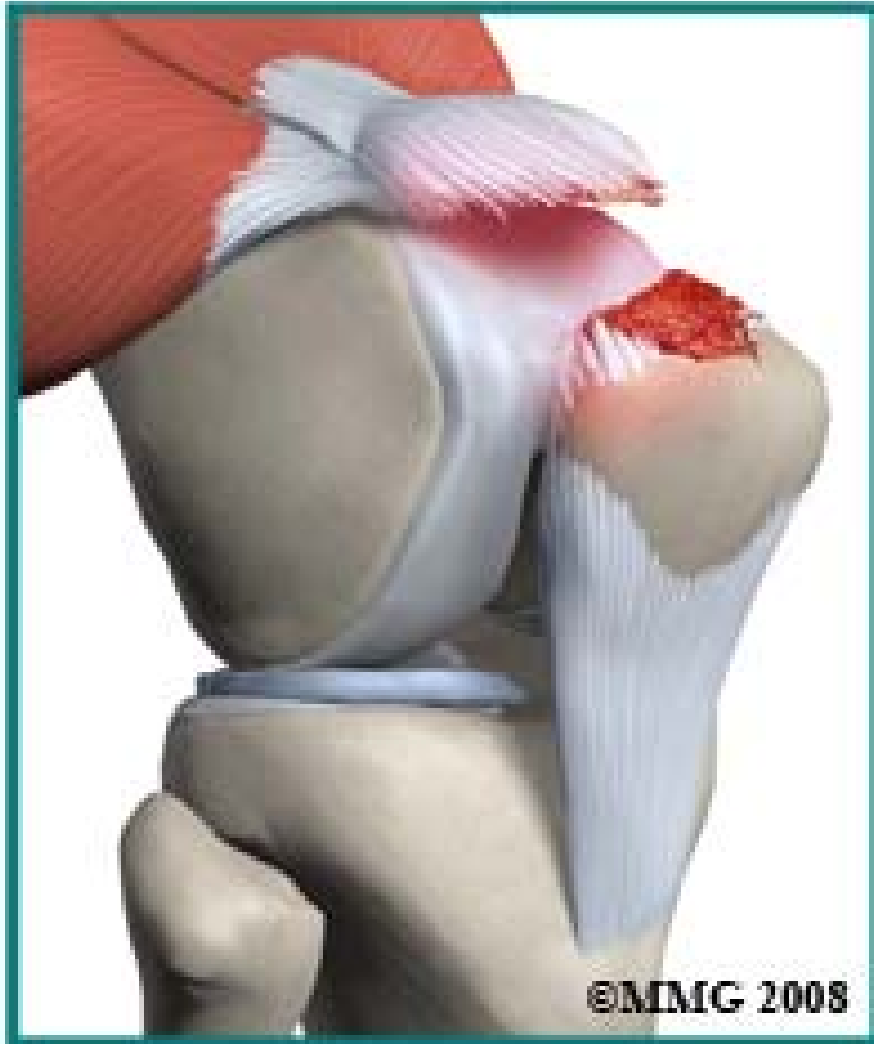Patella

TTA

Ruptures de l'appareil extenseur



Avulsion du tendon patellaire



Avulsion du tendon patellaire

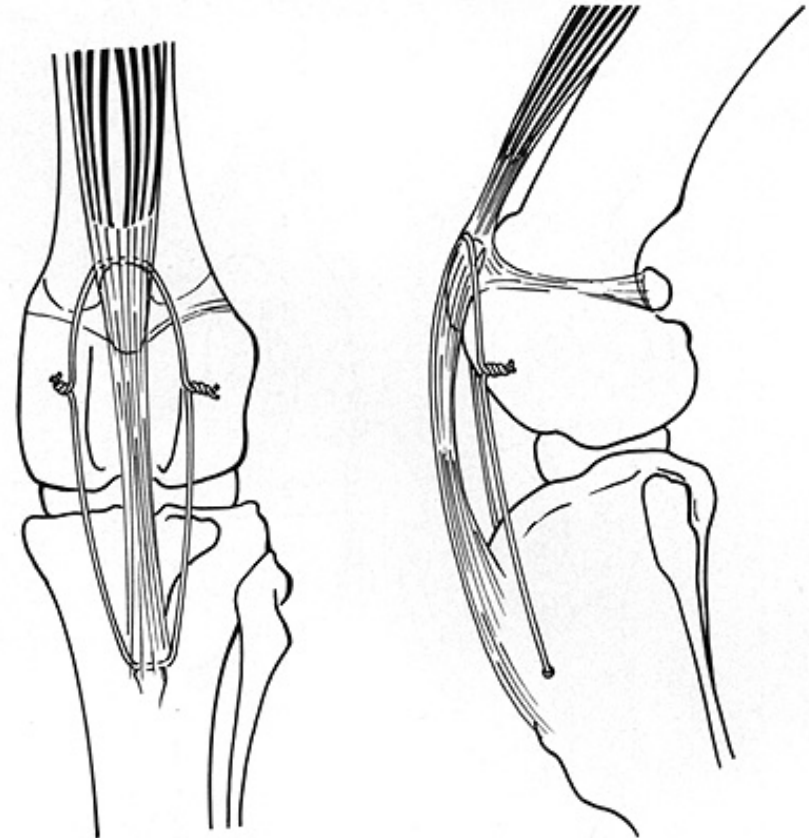
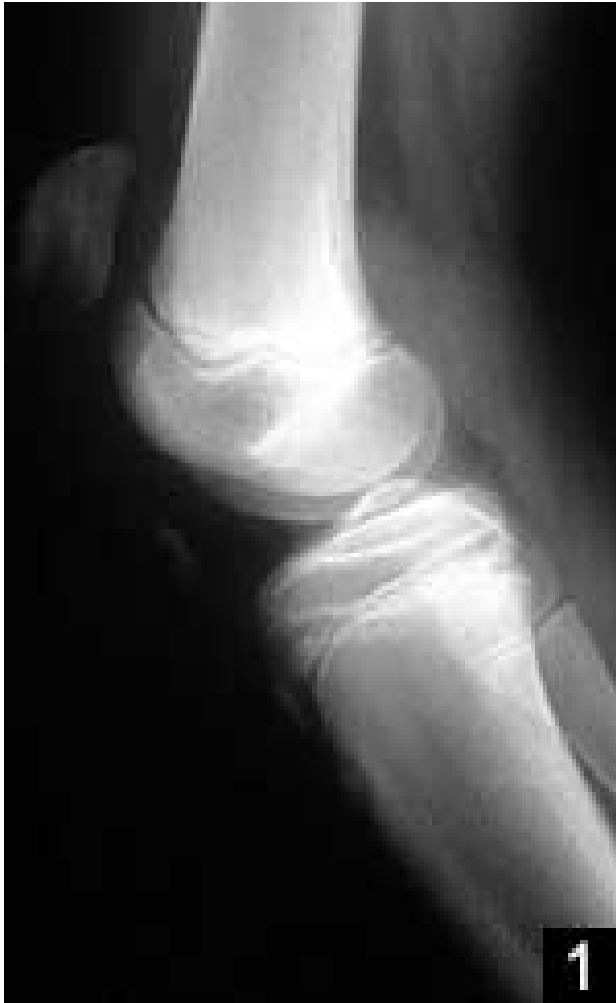
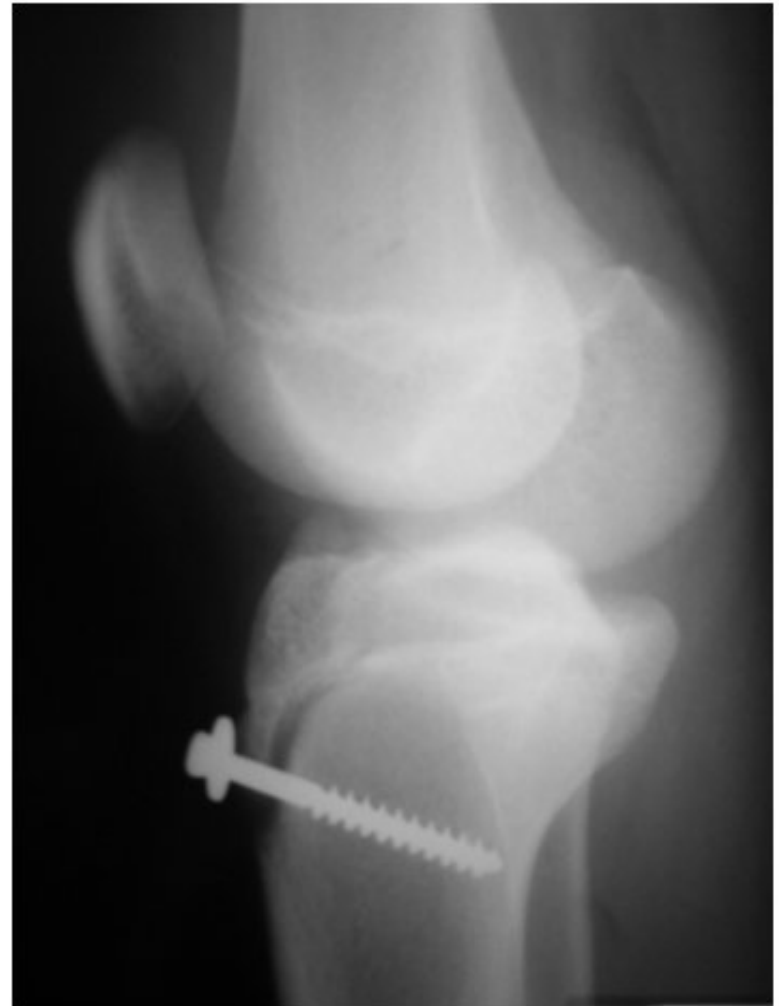
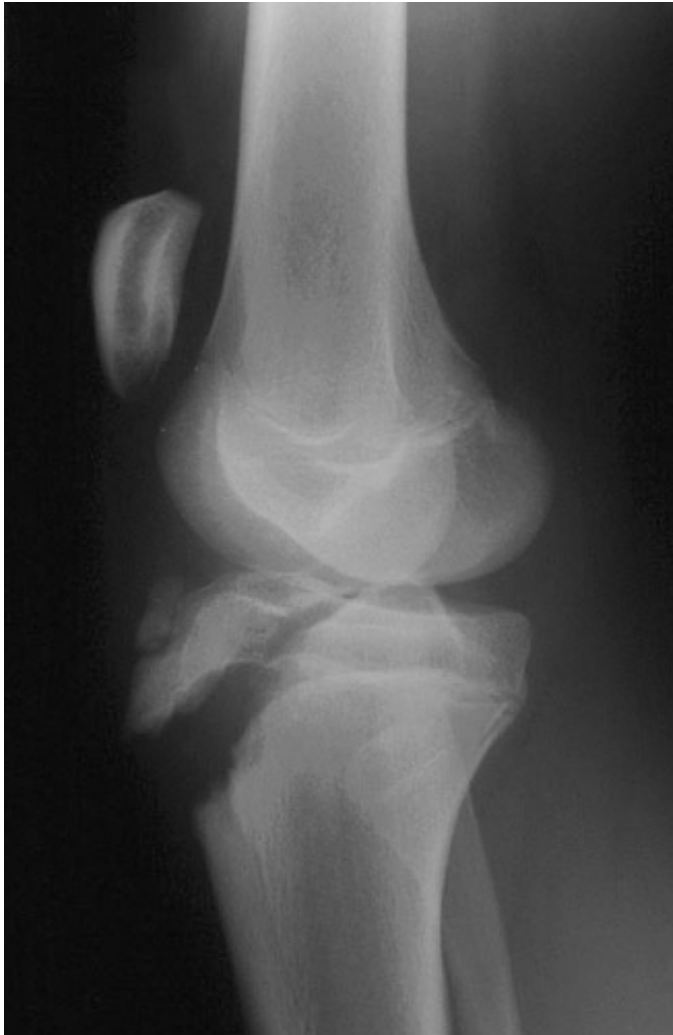FIG. 69-13 Technique to remove tension from a severed patellar ligament to allow suture. The proximal point of purchase of the tension band wire is the proximal pole of the patella. The wire is over the patella and through the quadriceps muscle insertion.

Et ses variantes...



Problématiques pédiatriques



Diaphyse

Epiphyse inférieure

Epines tibiales

Patella

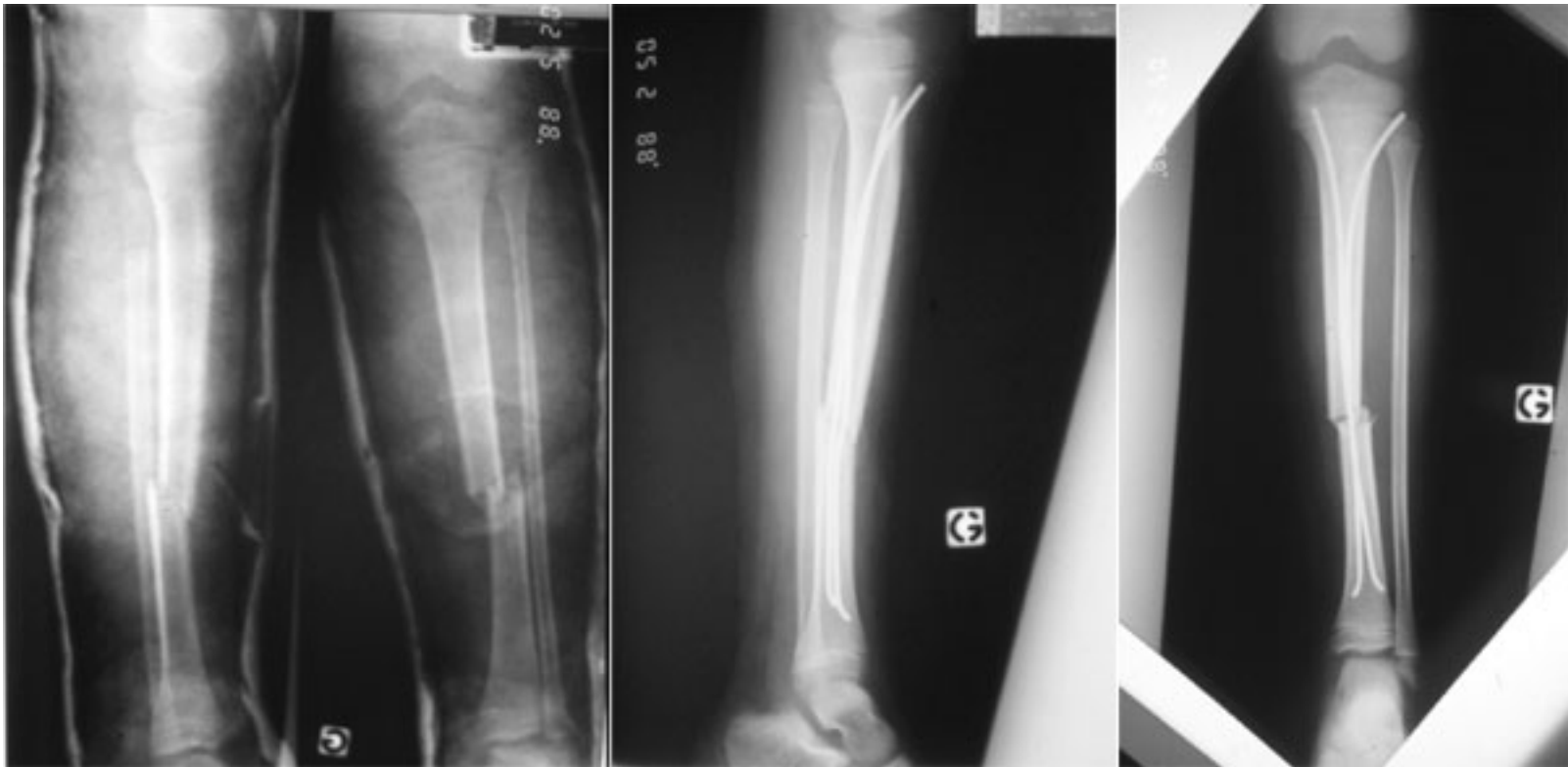
TTA

Fractures diaphysaires du tibia

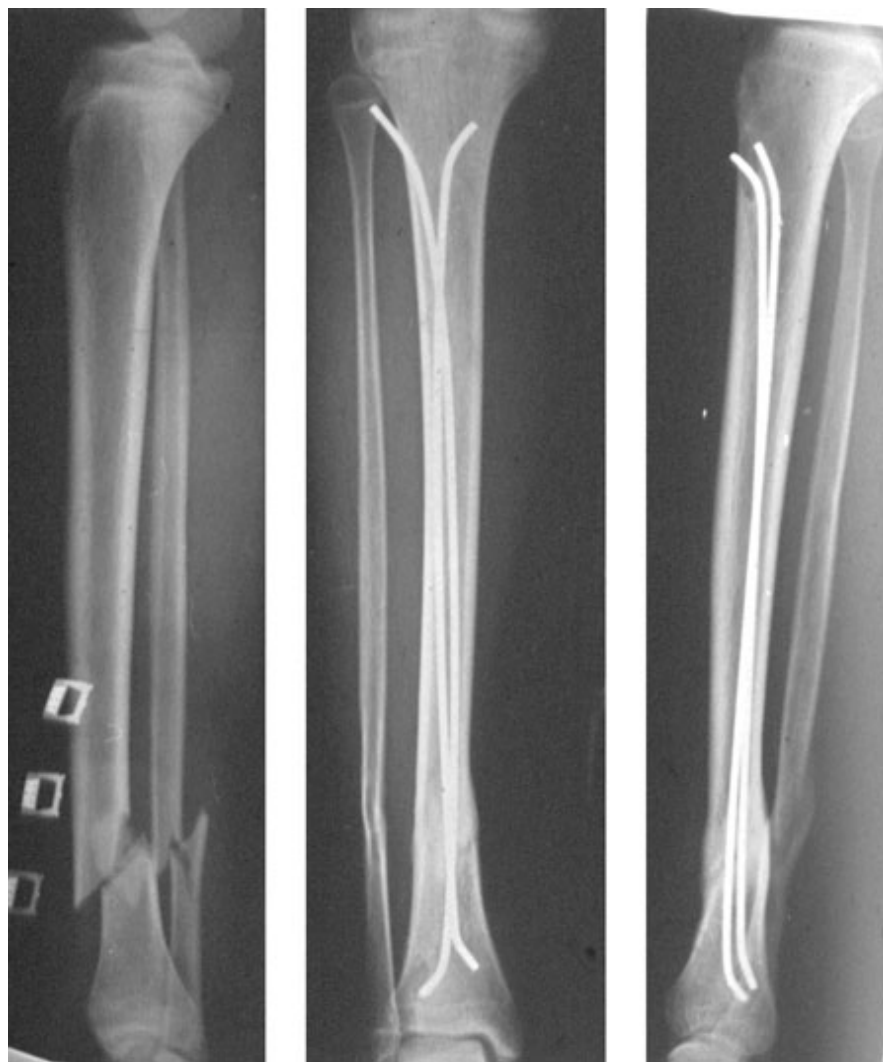


Jean-Paul METAIZEAU
Hôpital Belle-Isle - METZ

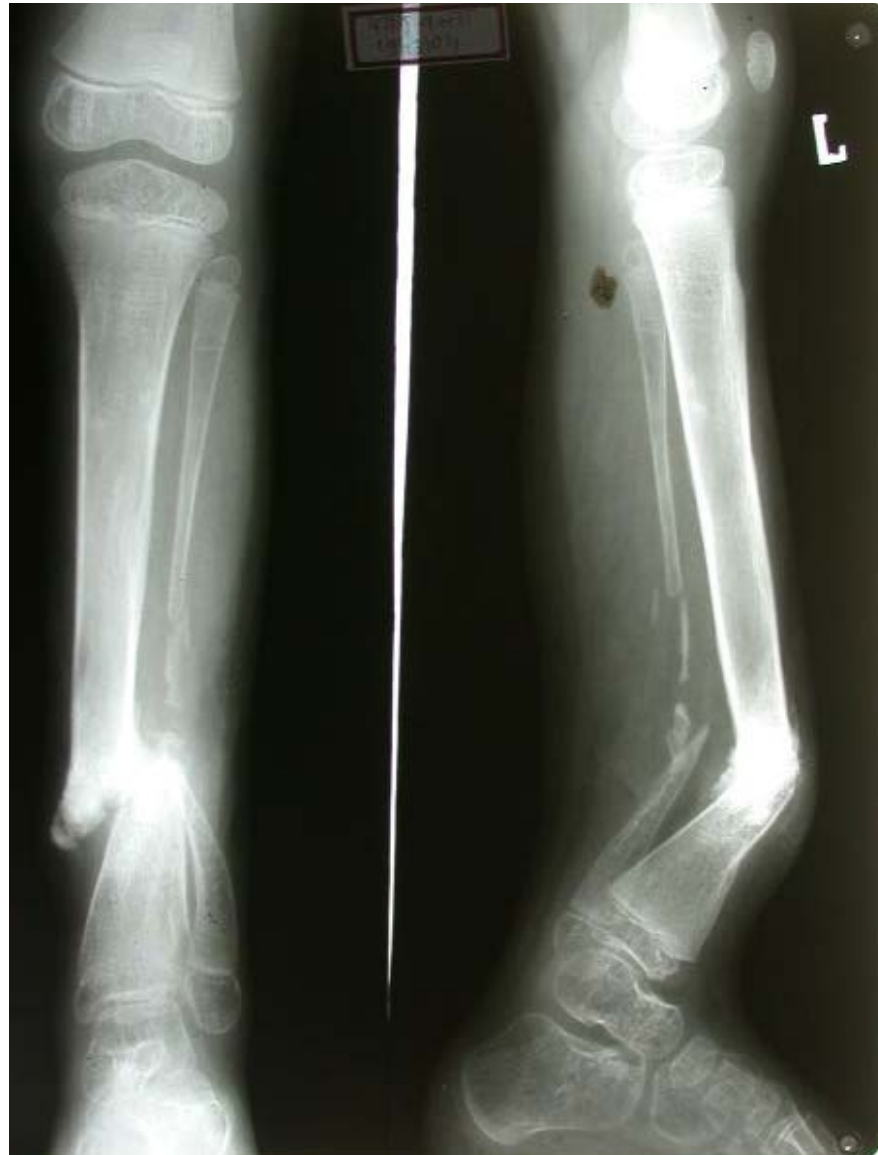Fractures diaphysaires du tibia



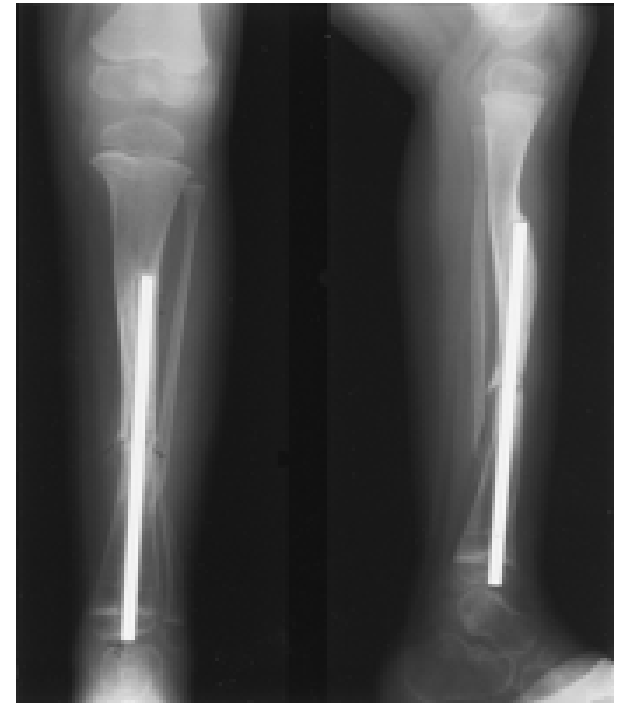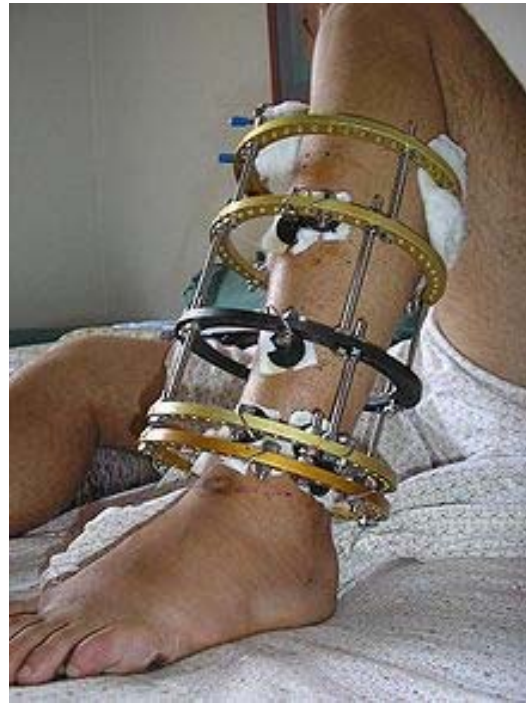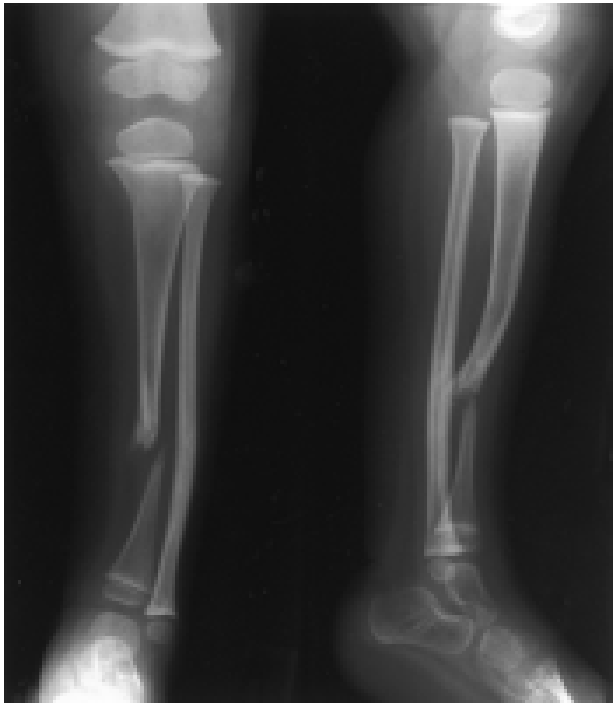Fractures diaphysaires du tibia



“fracture” ???



Fracture ???



Problématiques pédiatriques



Diaphyse

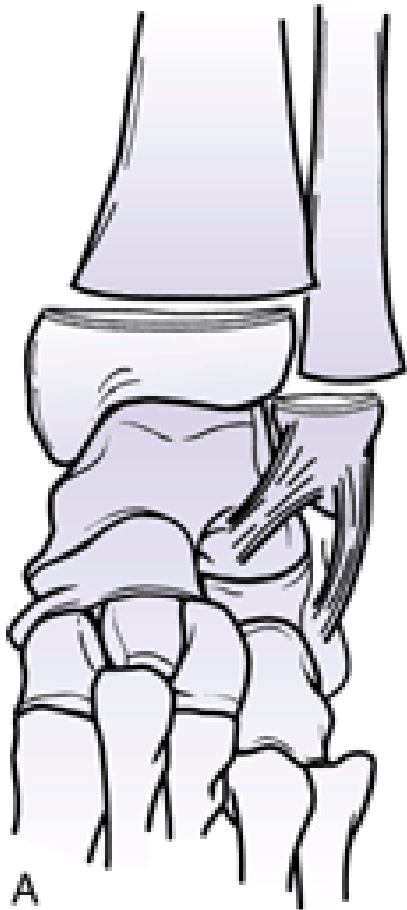Epiphyse inférieure

Epines tibiales

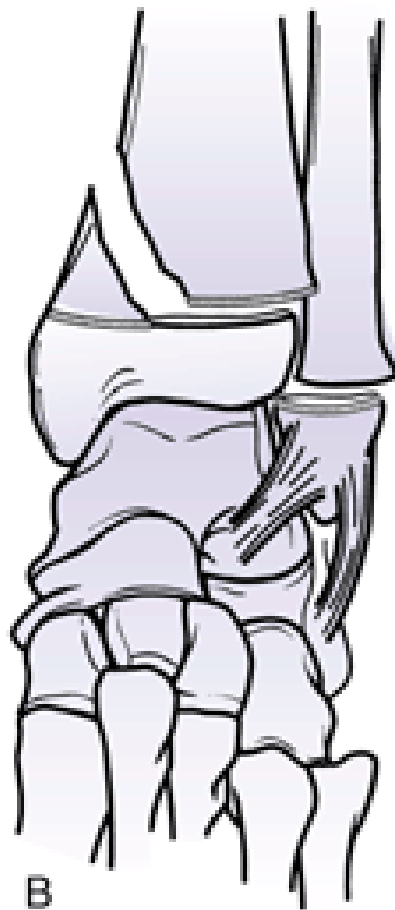Patella

TTA

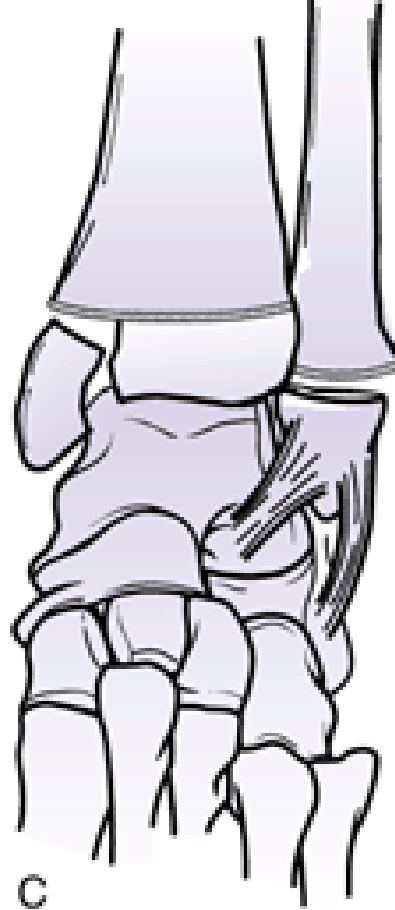Classification de Salter



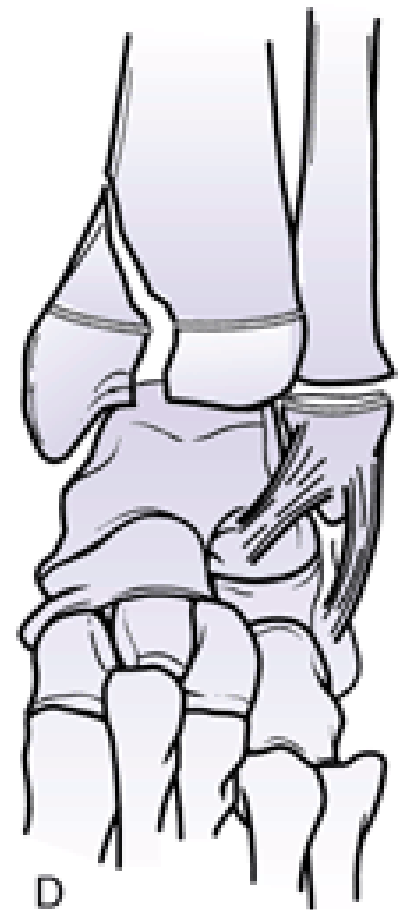1



2



3



4


Robert Bruce Salter, C.C., MD, FRCSC.

Dec 15, 1924 – May 10, 2010



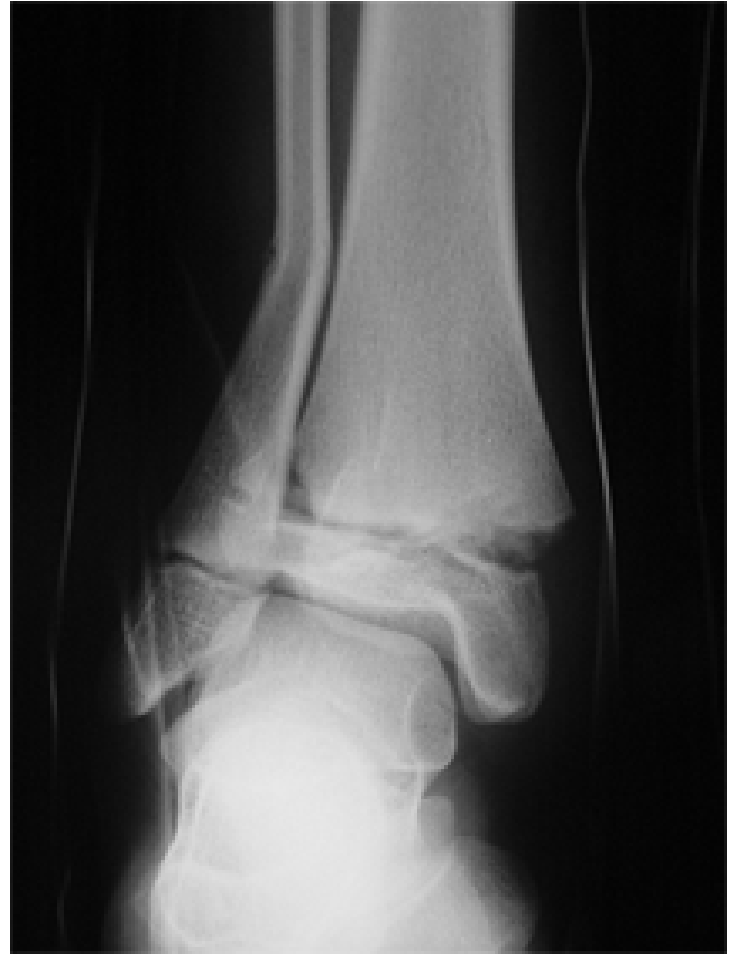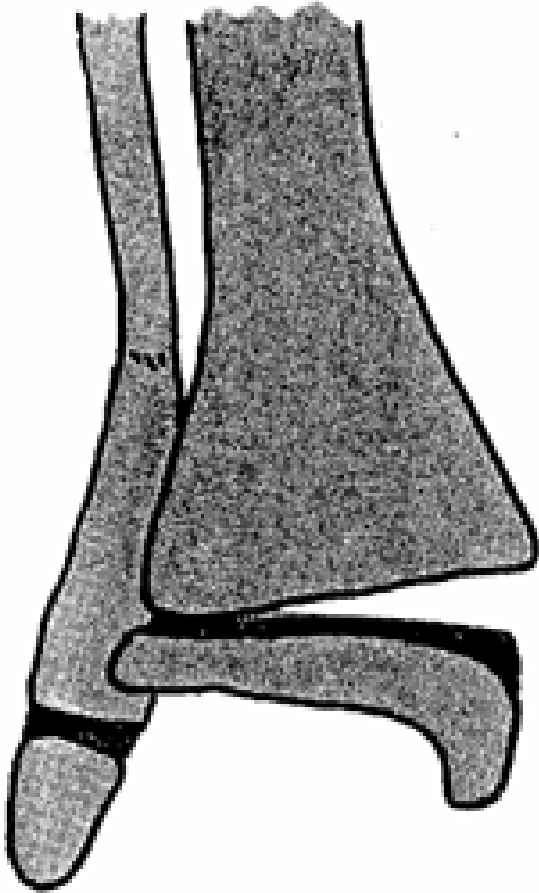
Dr. R. B. Salter (Chief of Surgery, Hospital for Sick Children, Toronto)

Dr. W. Robert Harris
1922 - 2005

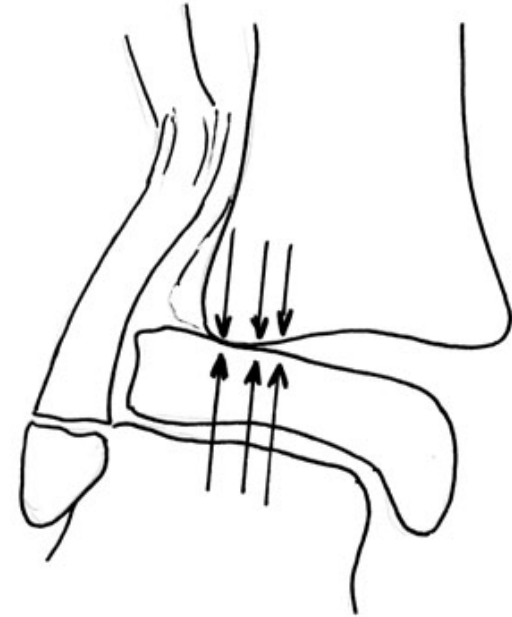
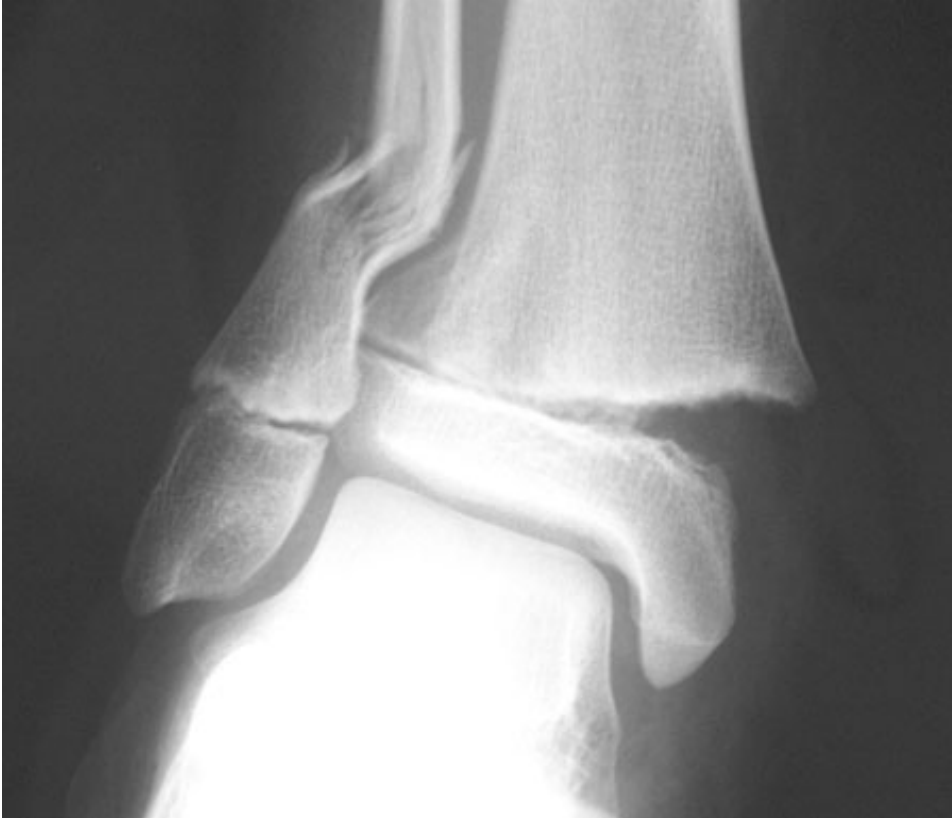

Dr. W. R. Harris (Consultant Orthopaedic Surgeon, Toronto General Hospital)

Salter 1 ou 2

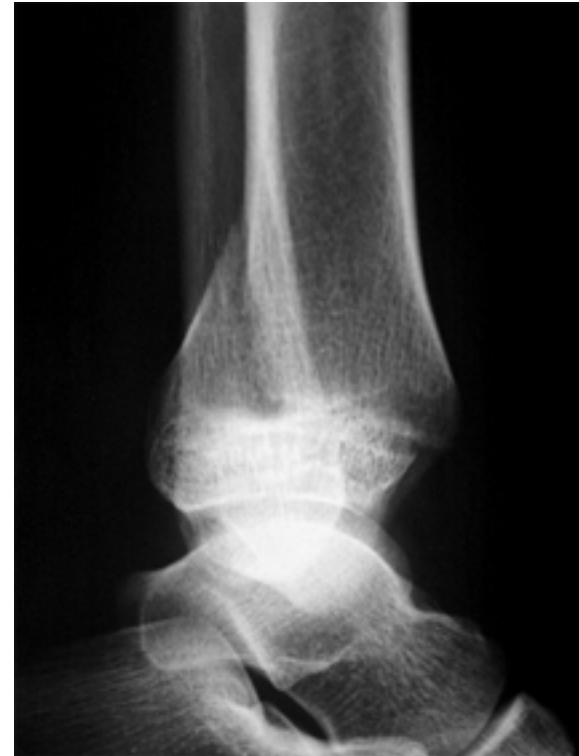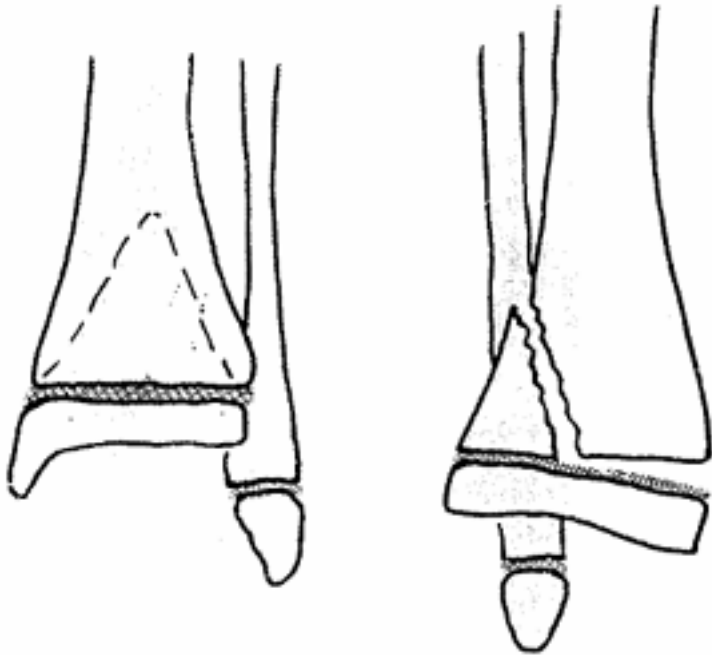


En fait ... Salter 5 ?

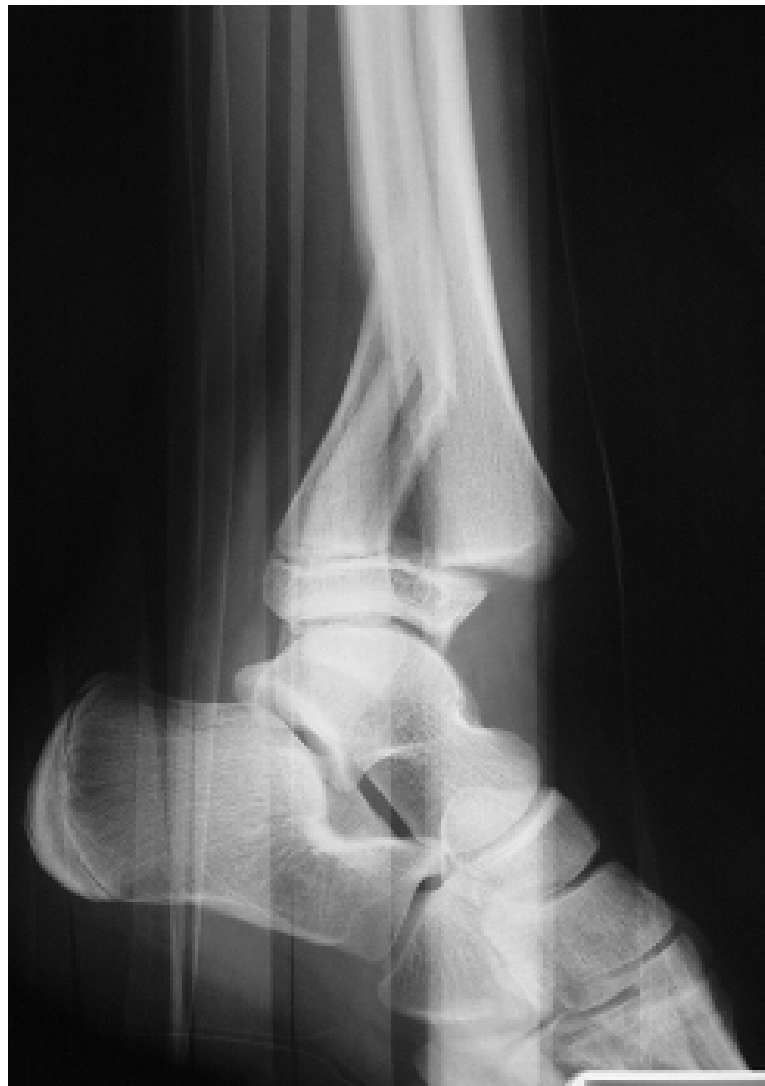

Surveiller +++

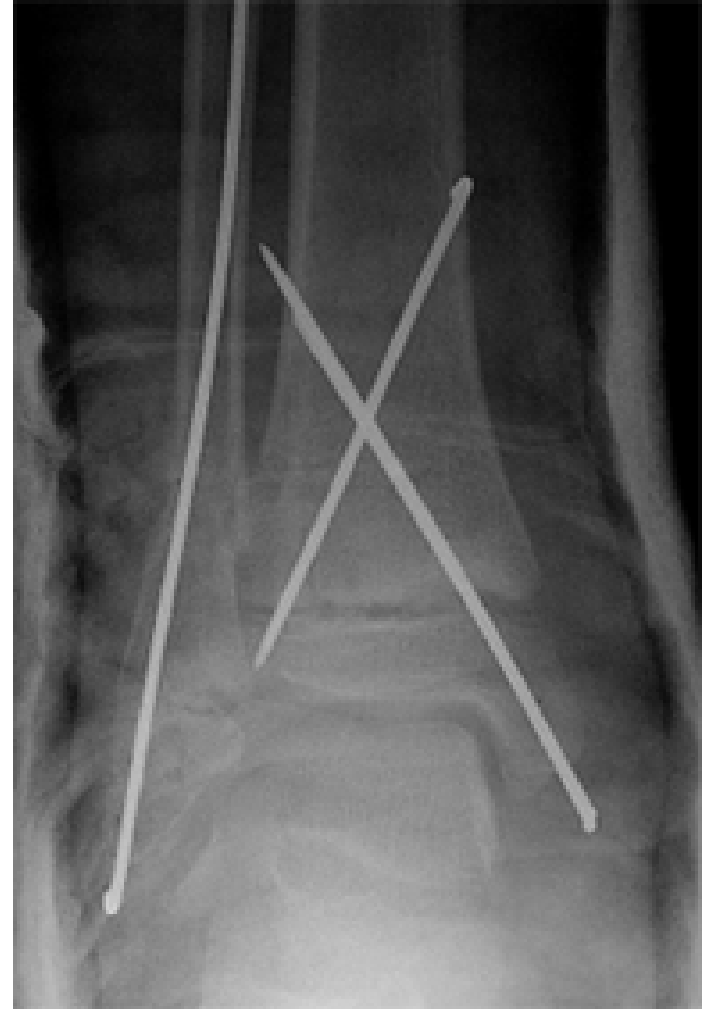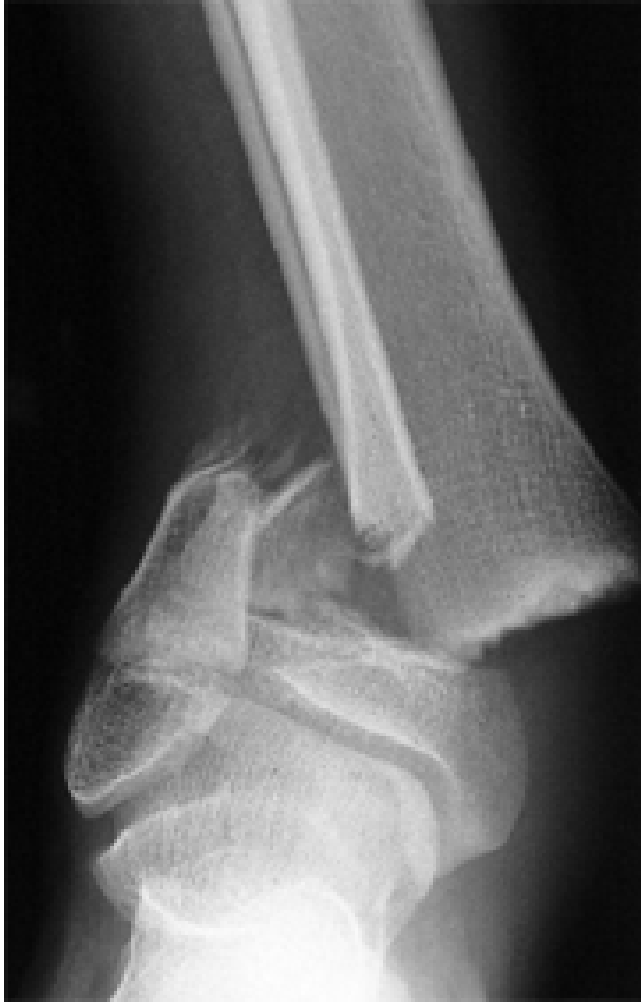Le salter 2 typique



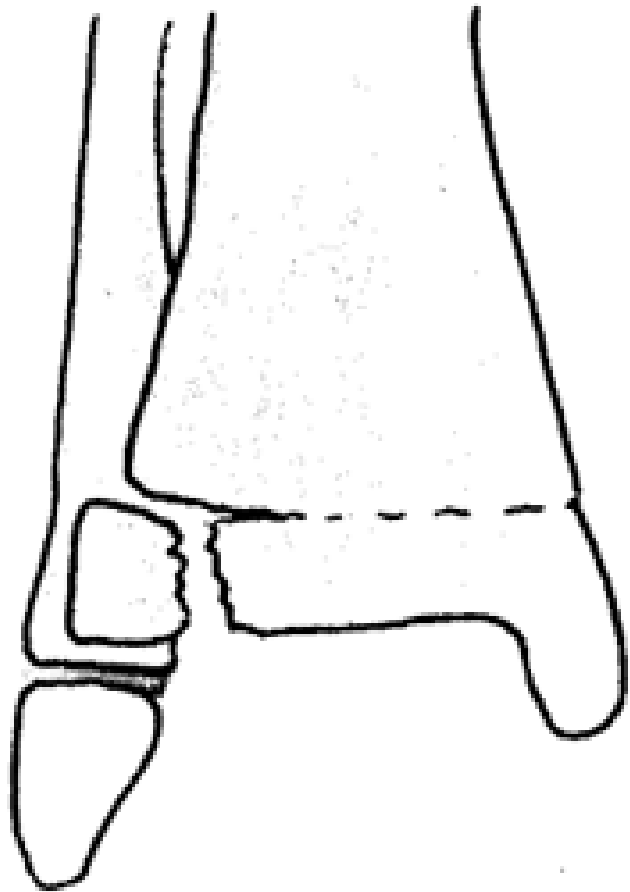
Encore plus typique...



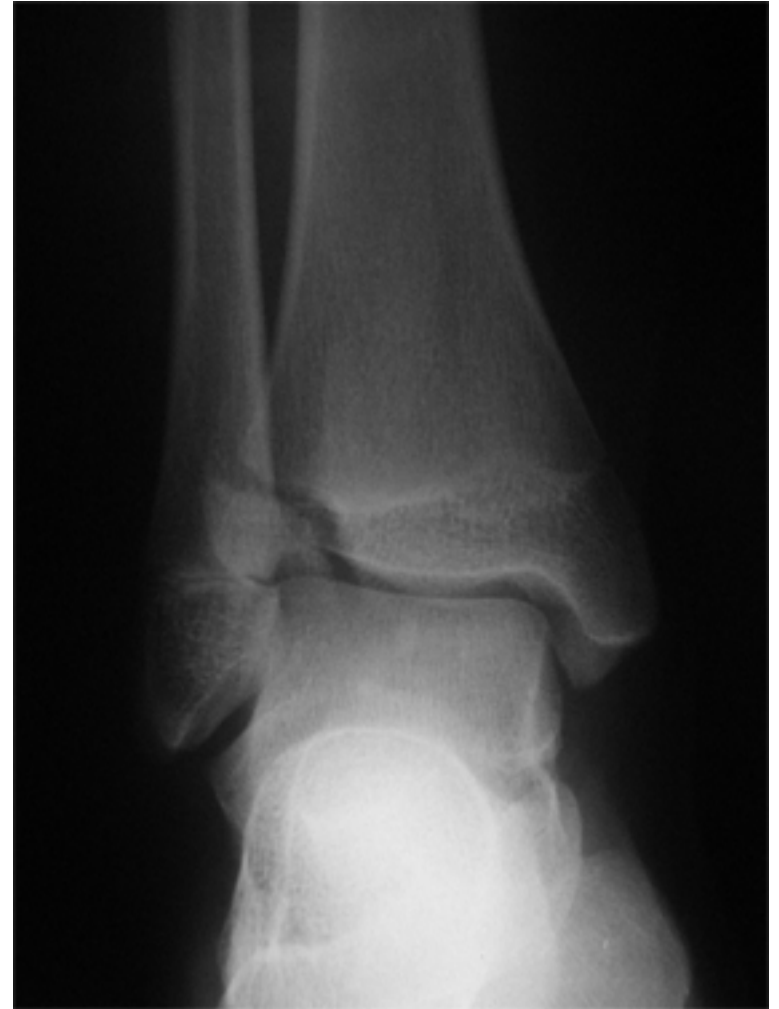Très (trop) déplacé



Le Salter 3



La fracture de Tillaux

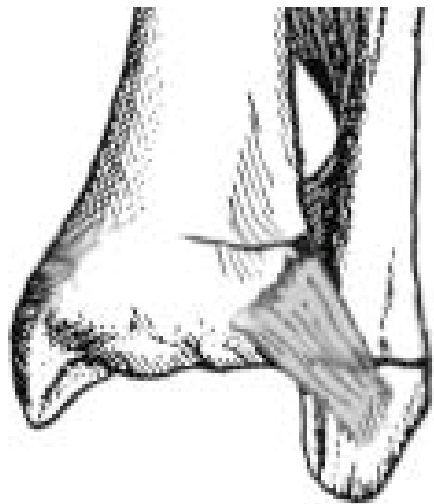


Paul Jules TILLAUX

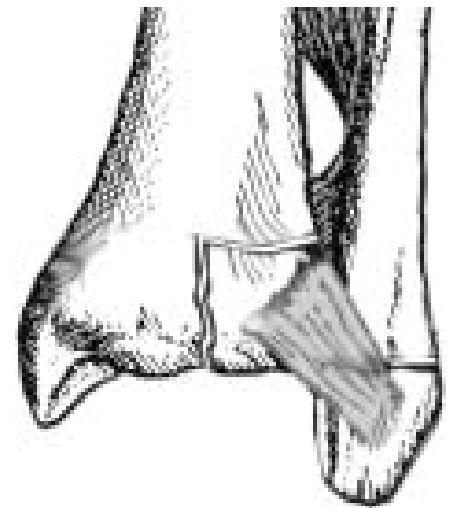

1834 - 1904



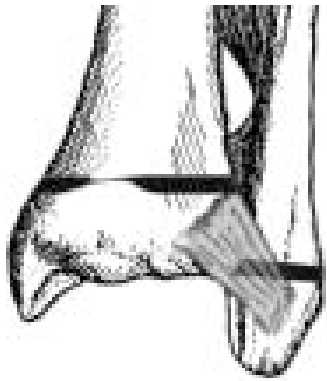
Fracture de Tillaux



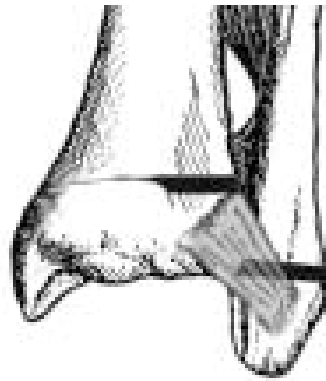
Antérieur



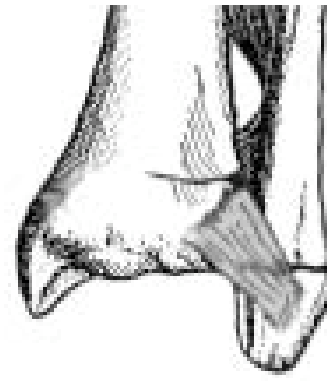
Fracture de Tillaux



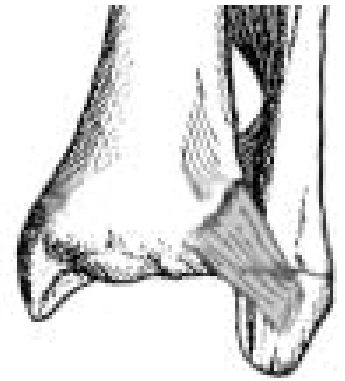
12,5 ans



13 ans



13,5 ans





14 ans

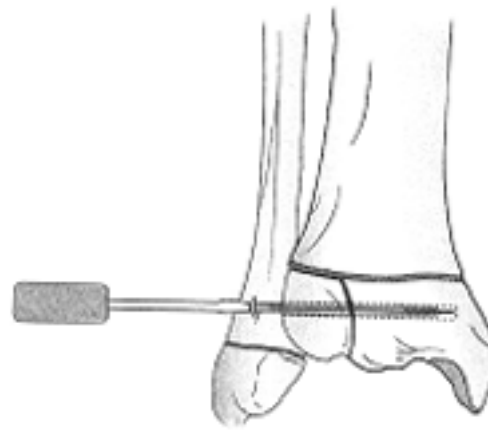
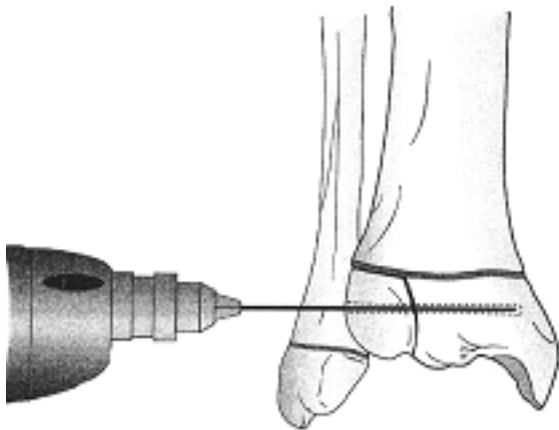
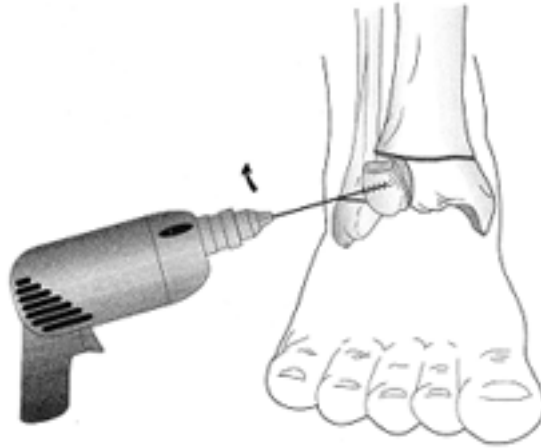


Latéral

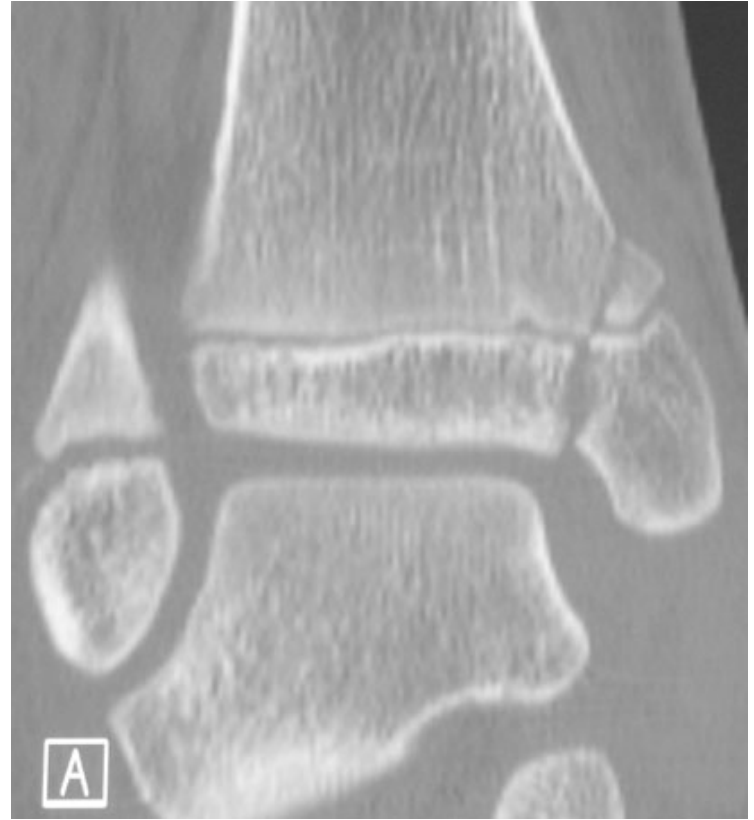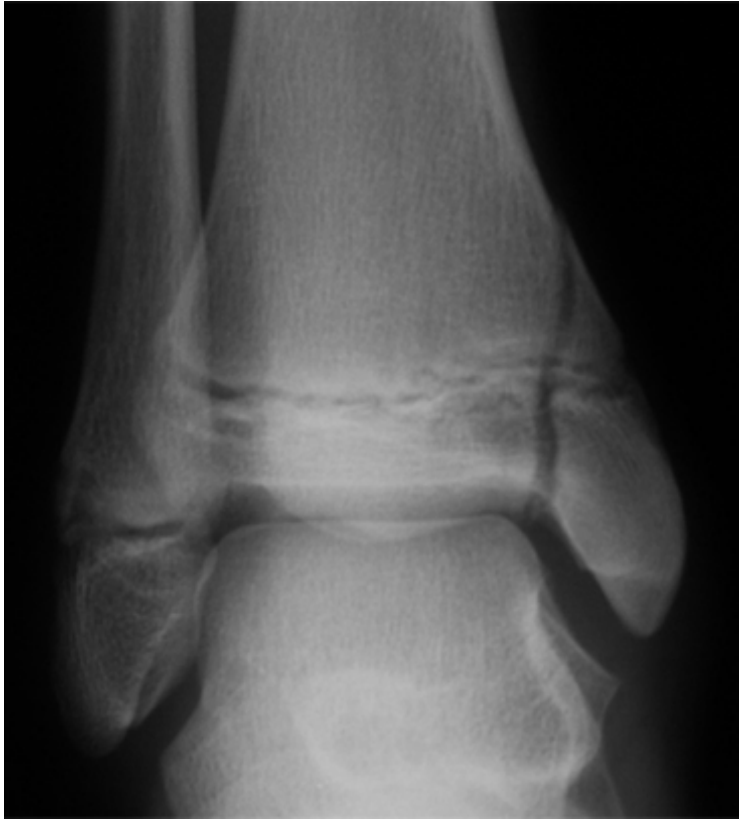Postérieur



Fracture de Tillaux

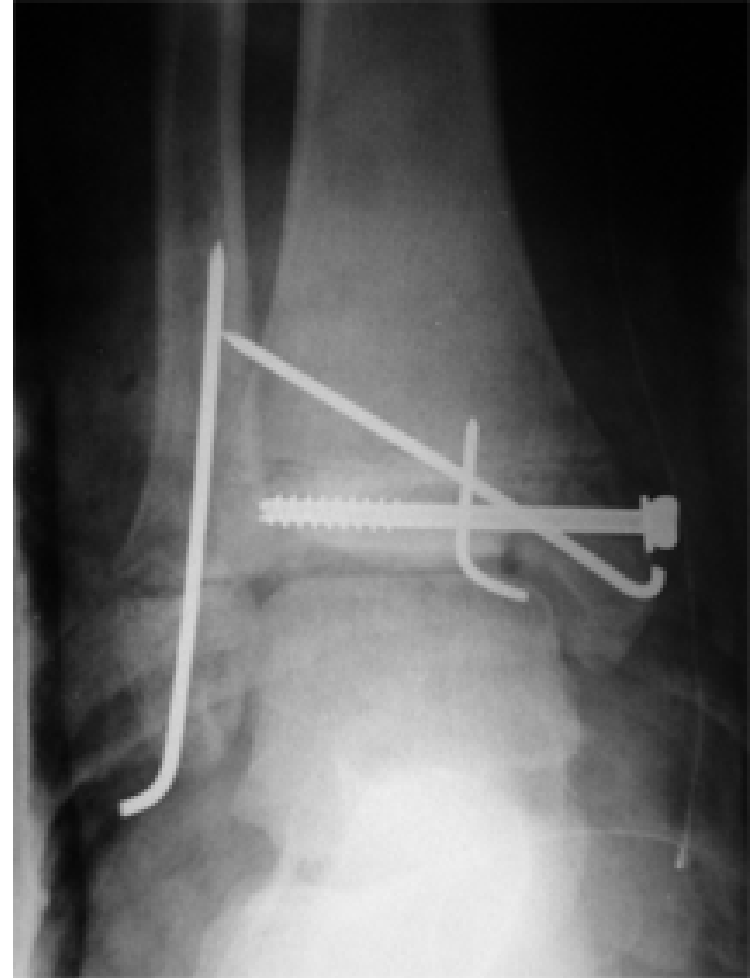
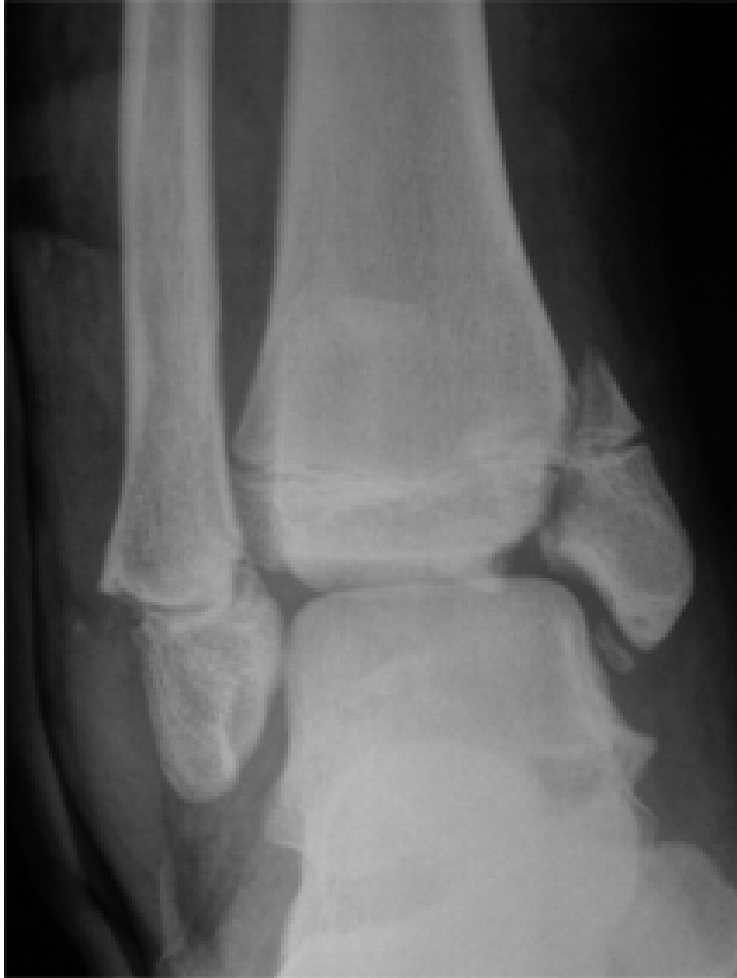

Le Salter 4



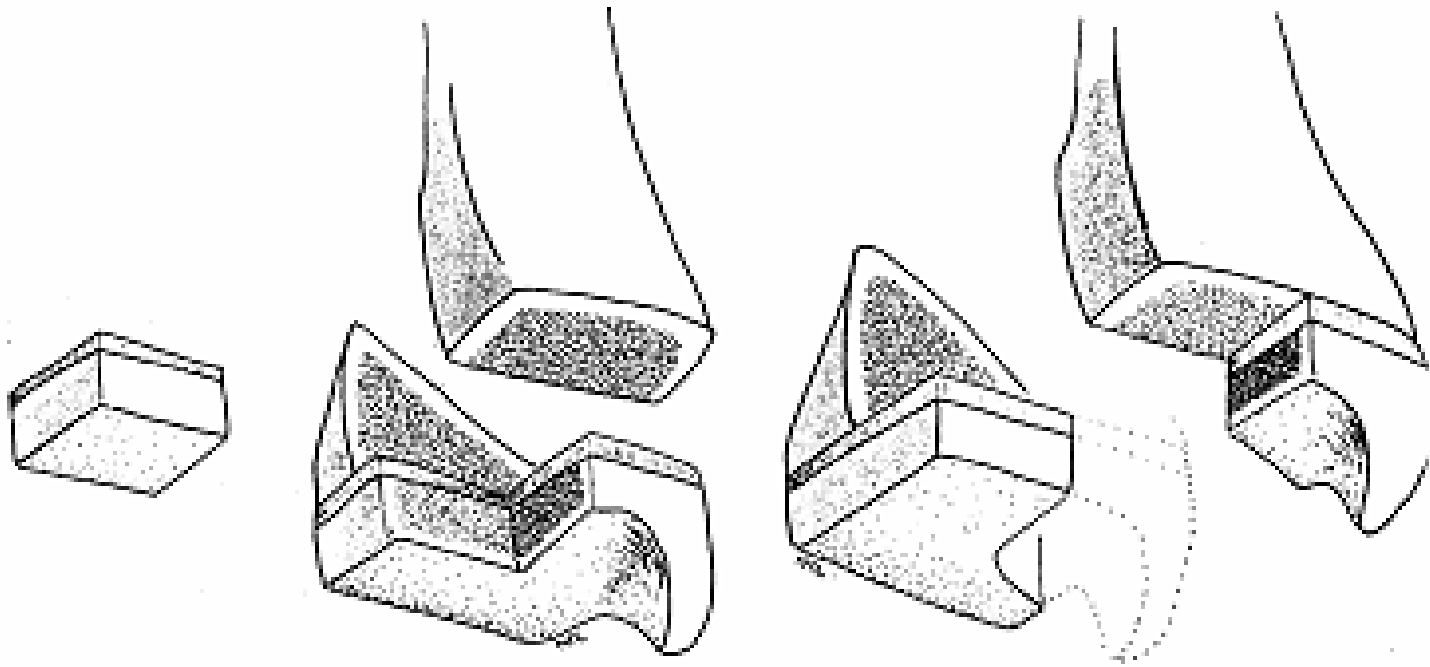
Fracture de Mc Farland

Fracture de Mac Farland



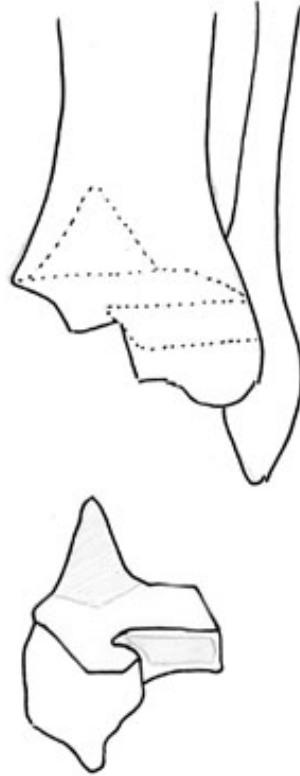
Eviter la physe

Les fractures tri-planes



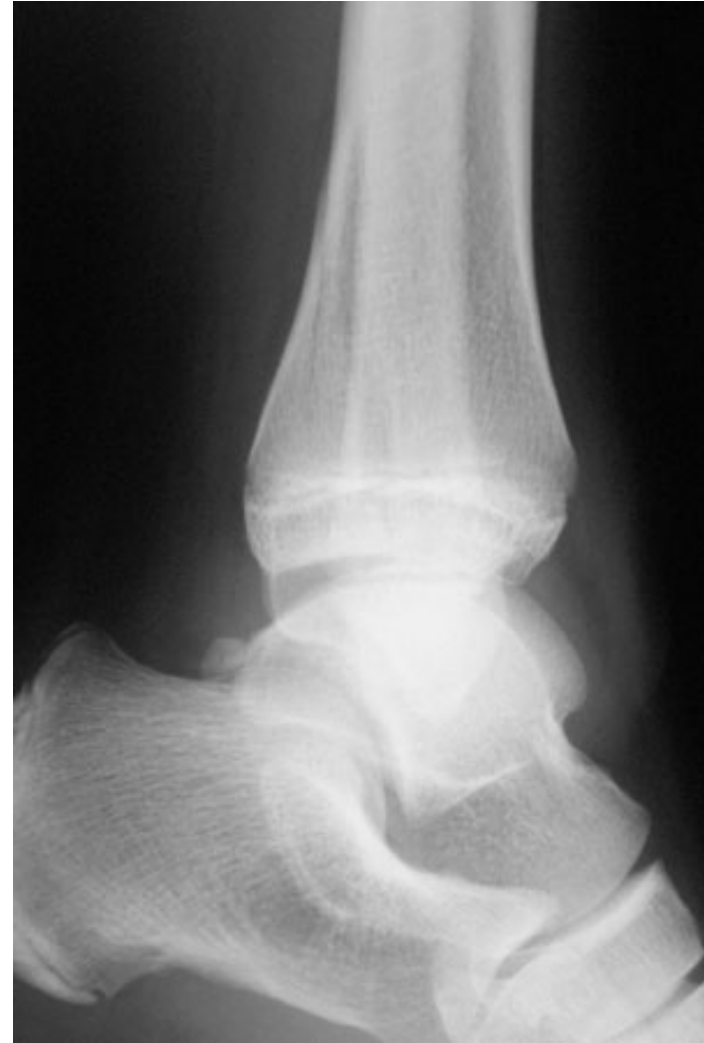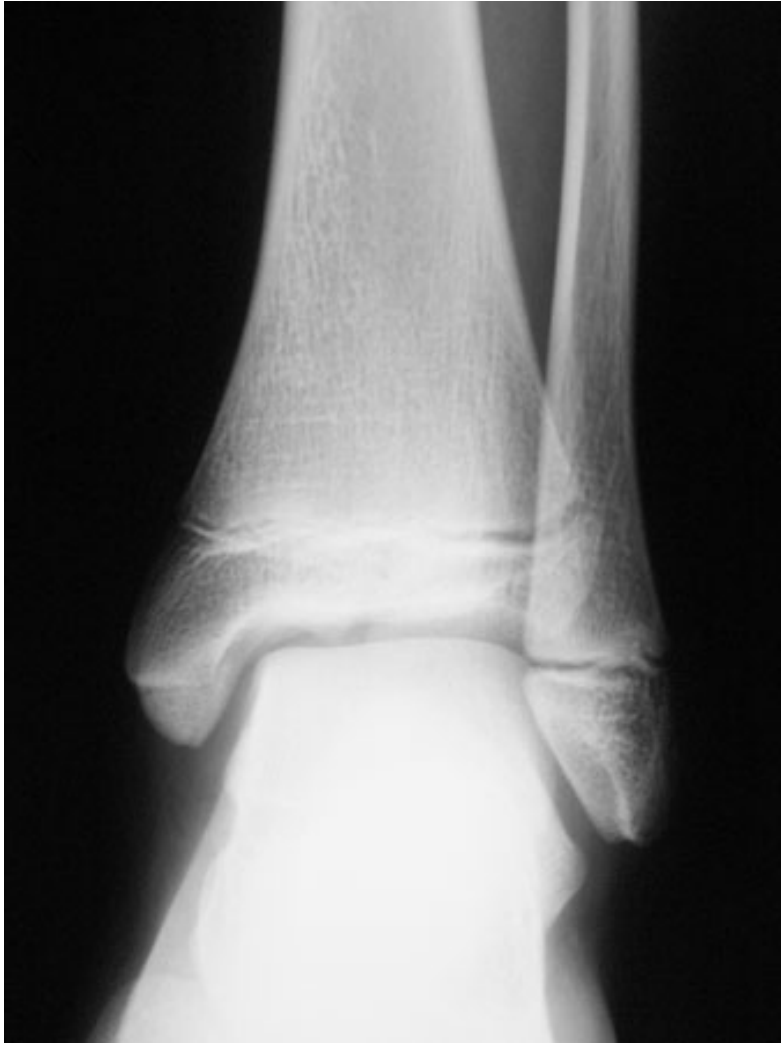Tri-plane latérale à 2 ou 3 fragments
Salter 2 de profil / Salter 3 de face

Les fractures tri-planes

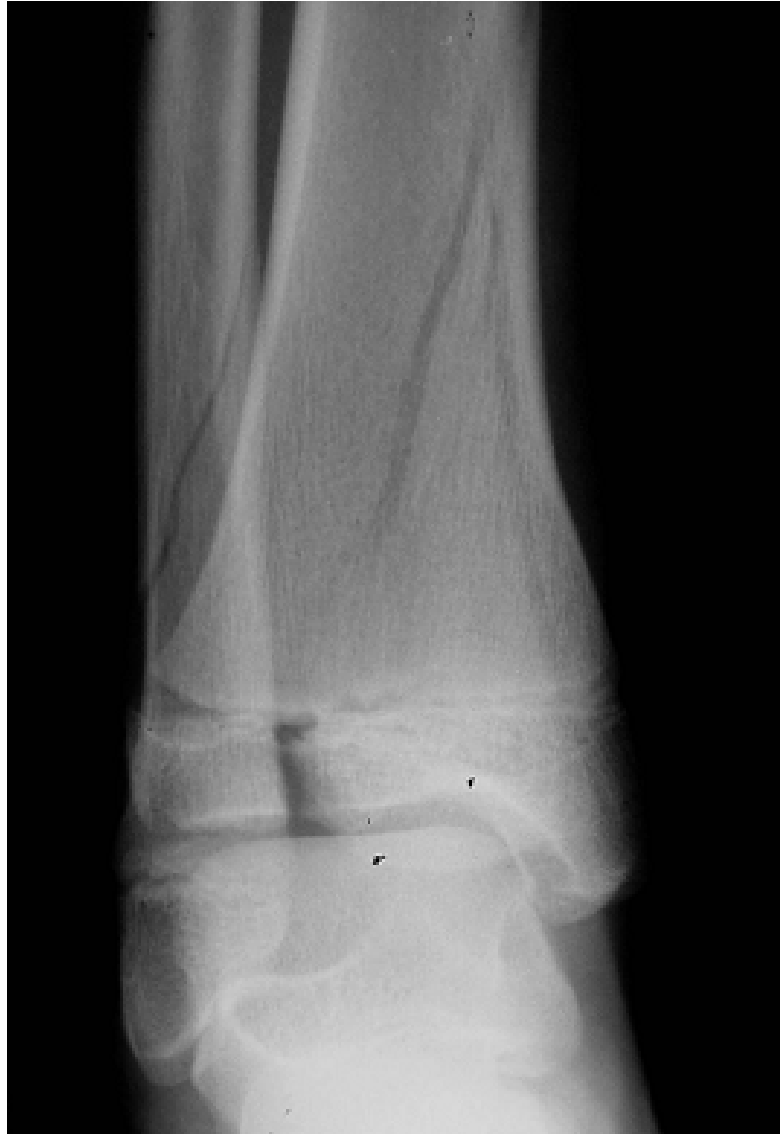

Triplane médiale à 2 fragments

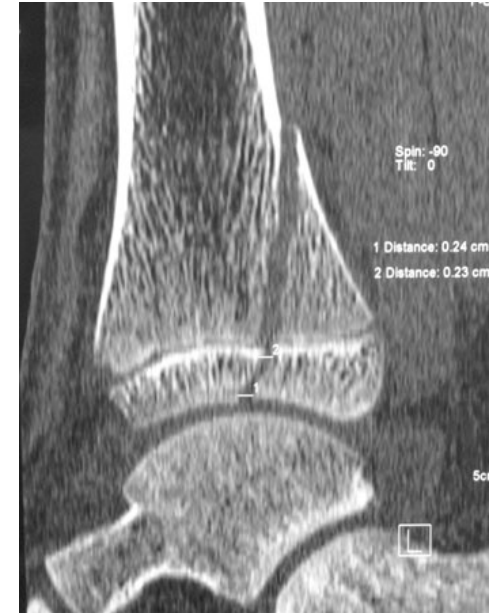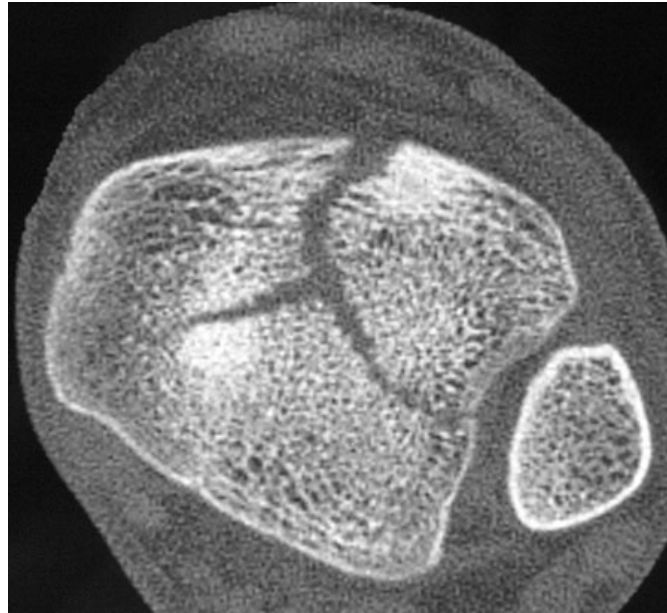
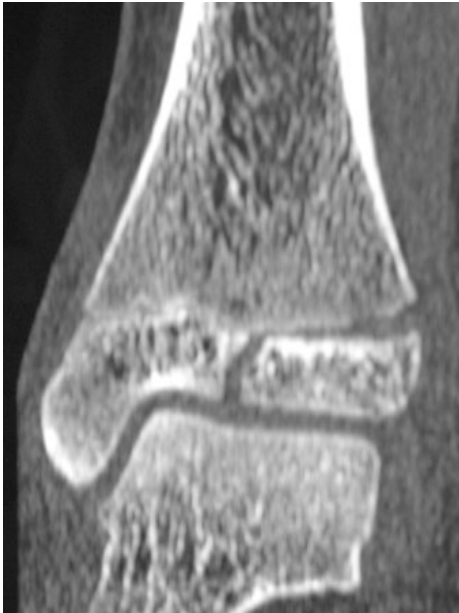A peine visible...



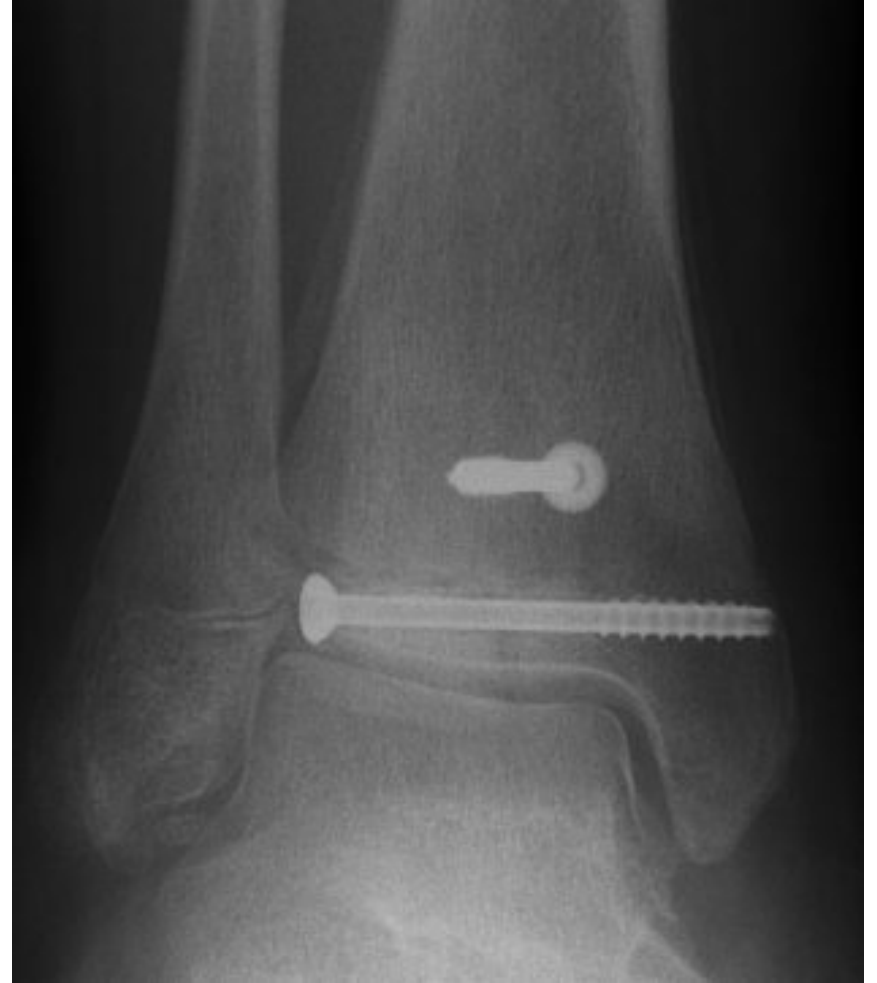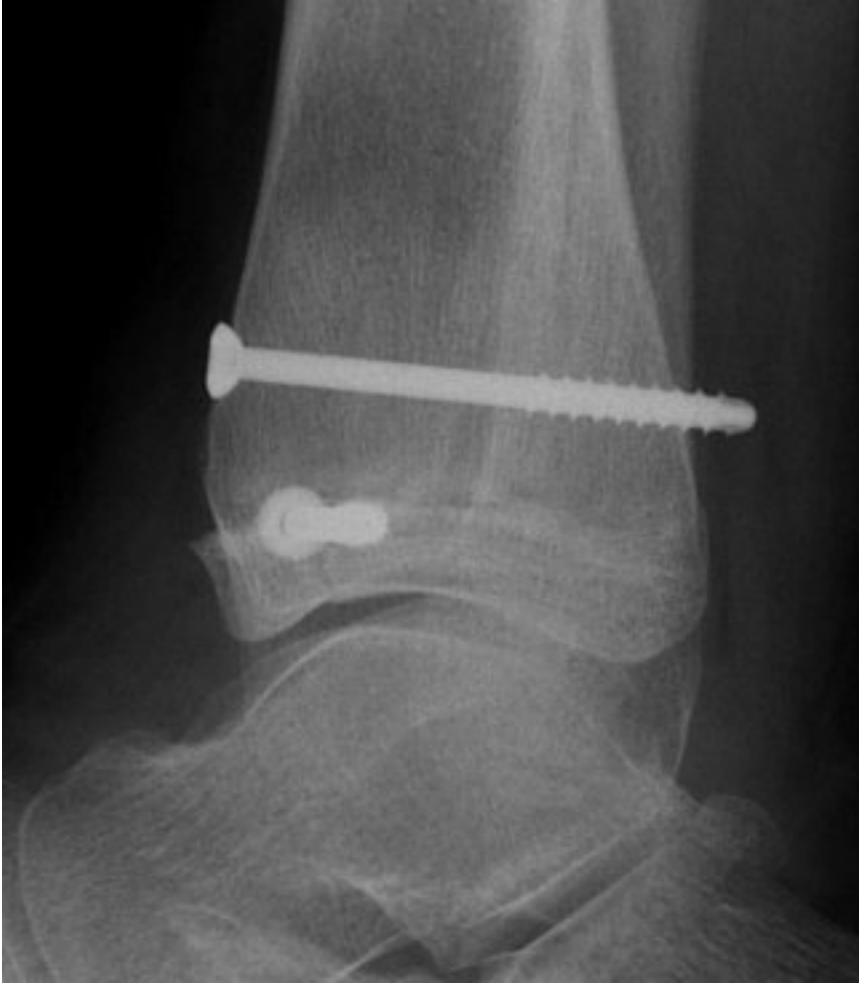Incidence de $\frac{3}{4}$ +++



Ou un scanner +++

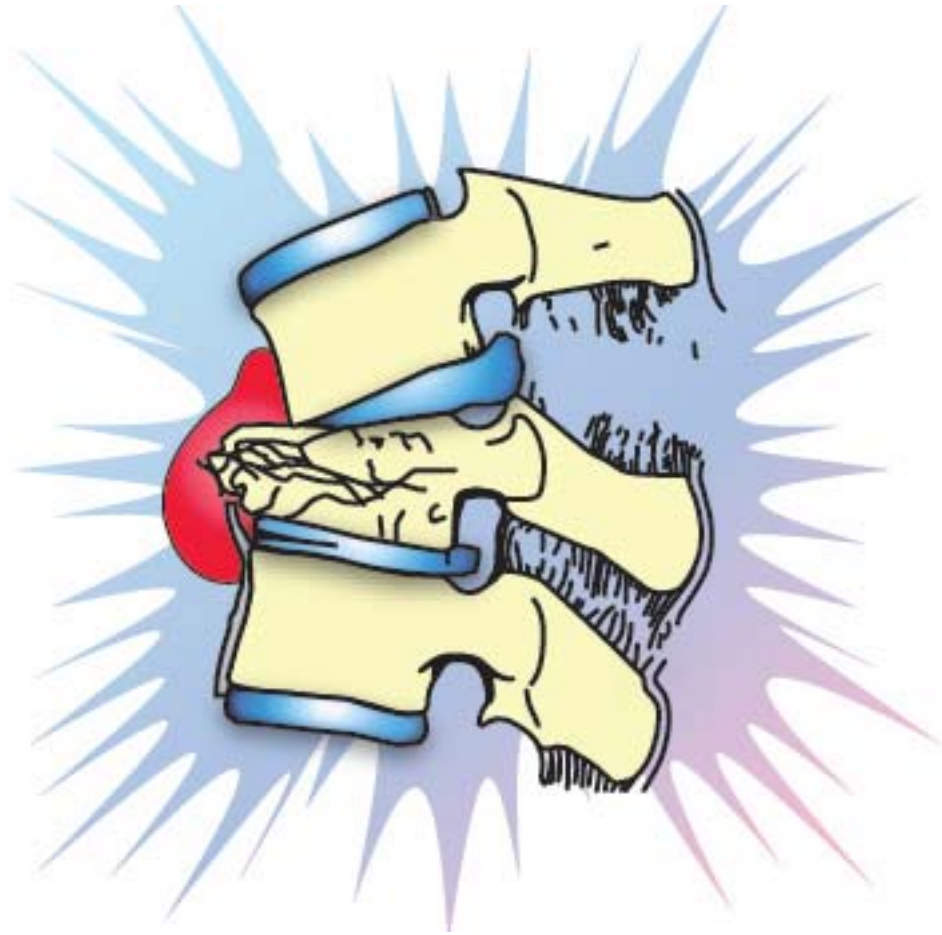


Fracture Tri-plane



Eviter la physe

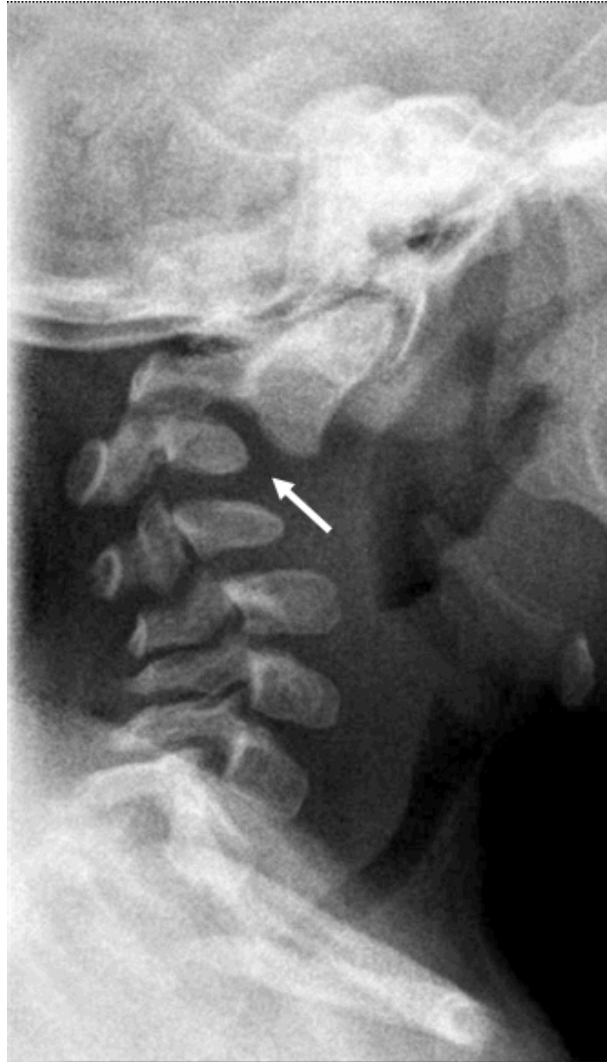Traumatologie Rachidienne



Grandes idées

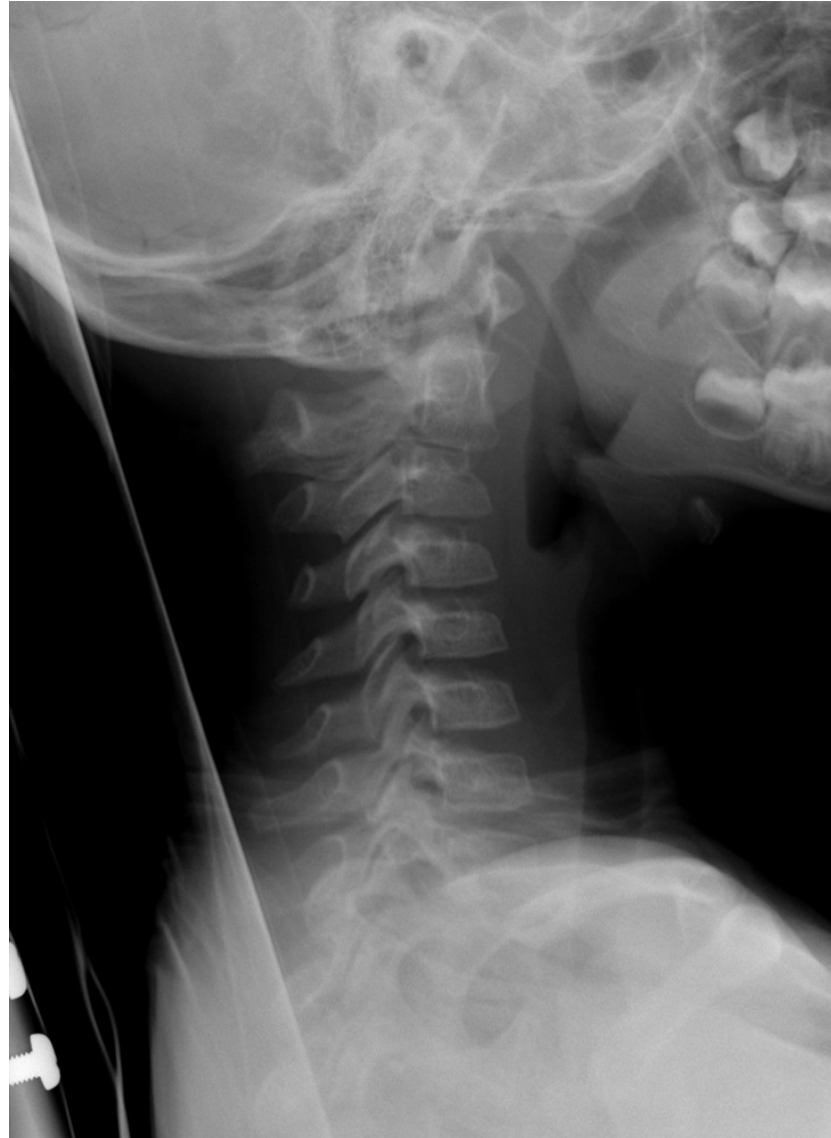- De plus en plus rare...
- Lésions spécifiques (listel, sciwora)
- Traitement orthopédique +++
- Surveillance +++

Piège n° 1



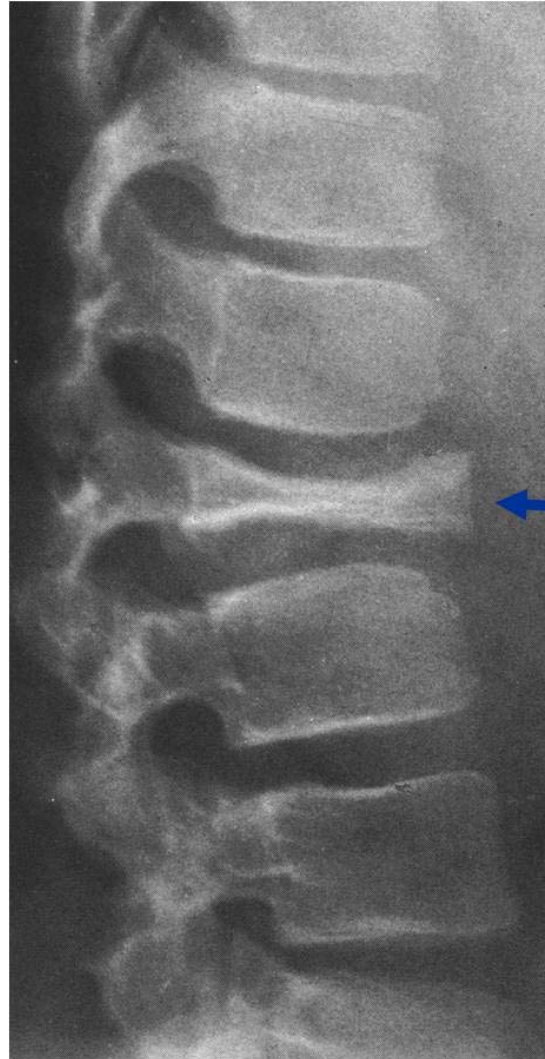
Dysplasie osseuse
ou
Malformation congénitale

Piège n° 2



Pseudo-subluxation C2C3
Physiologique

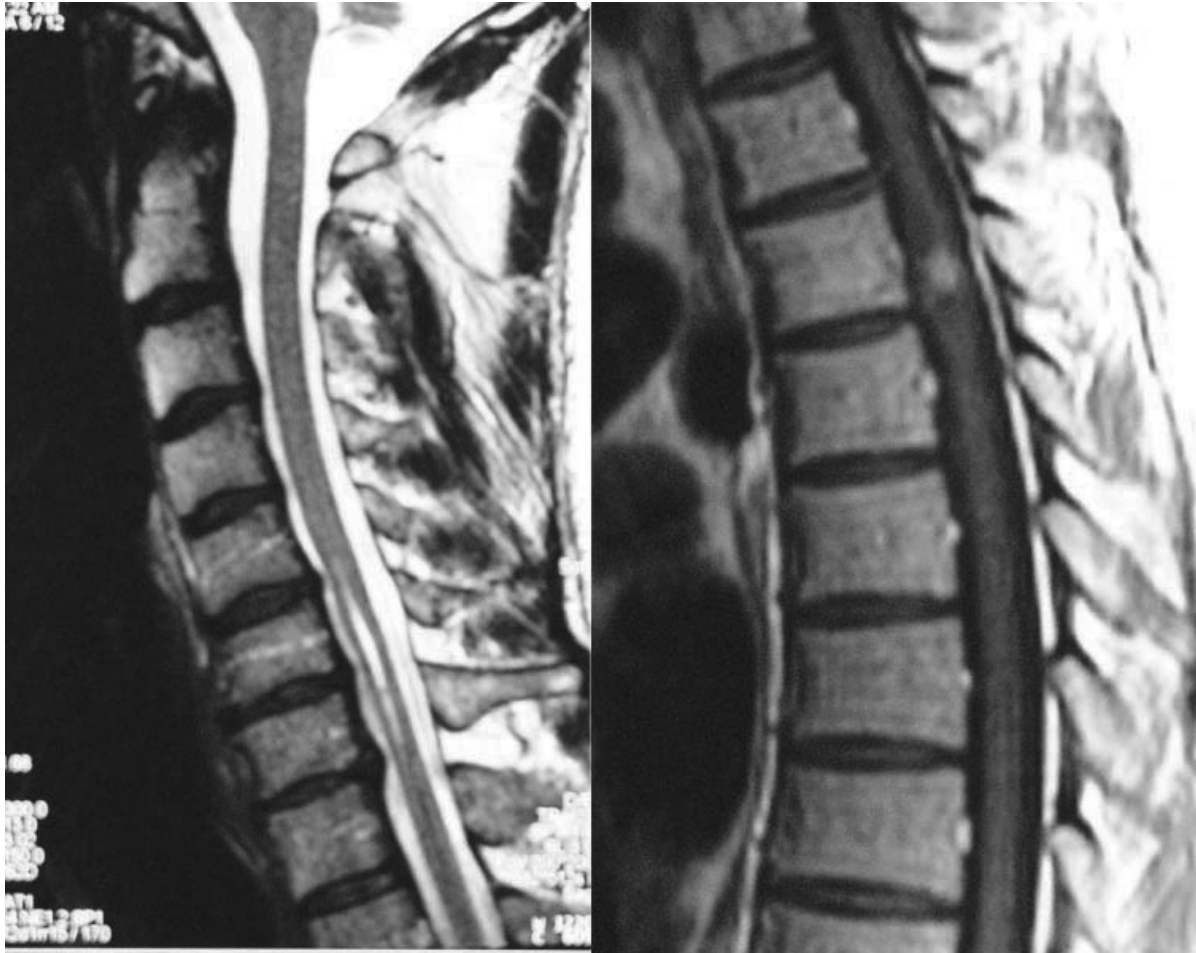Piège n° 3



Vertebra plana
Granulome éosinophile

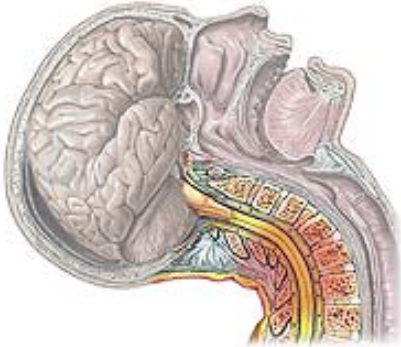SCIWORA

Spinal Cord Injury WithOut Radiological Abnormality



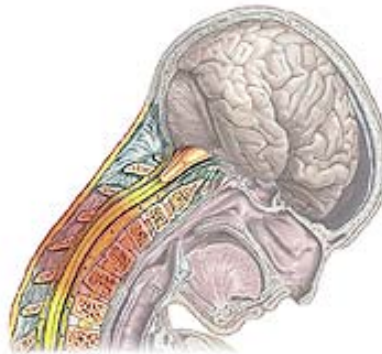SCIWORA

Hyperextension

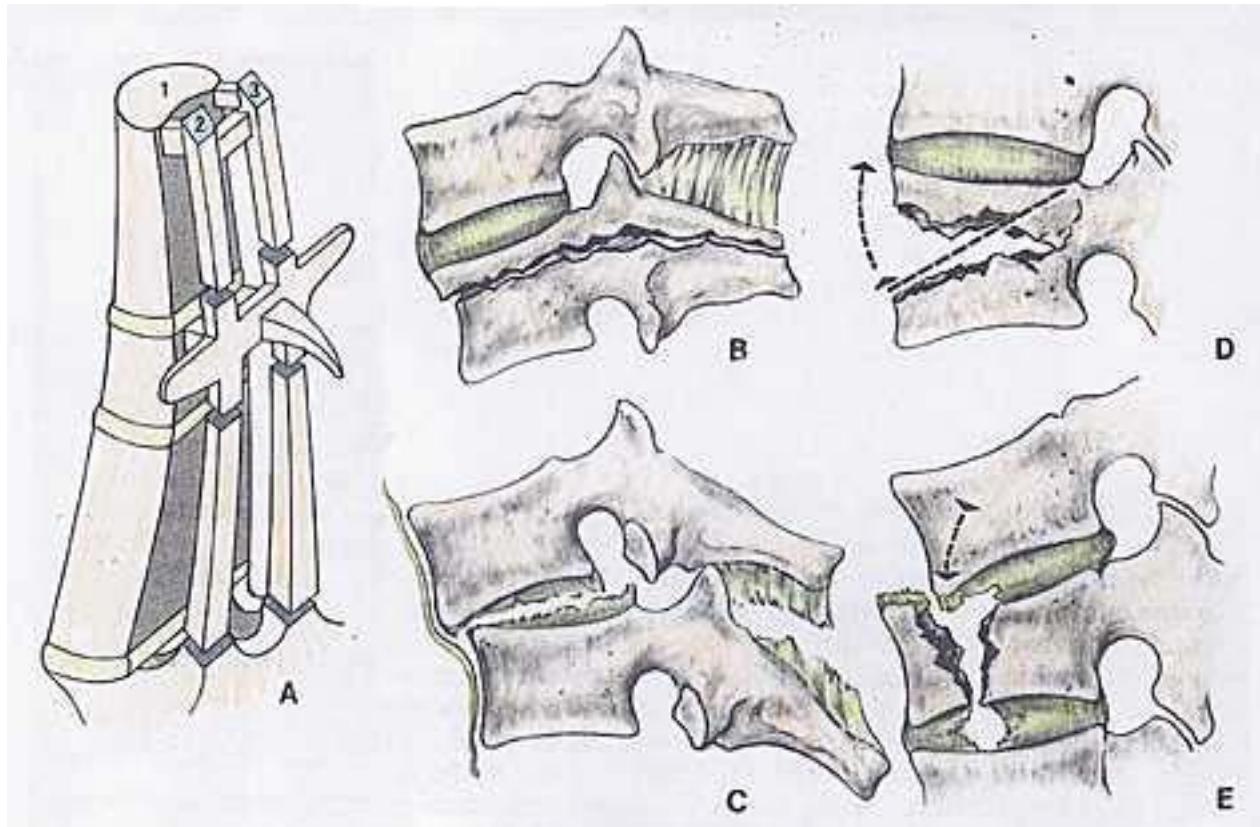


Sprain or strain of cervical tissues

Hyperflexion



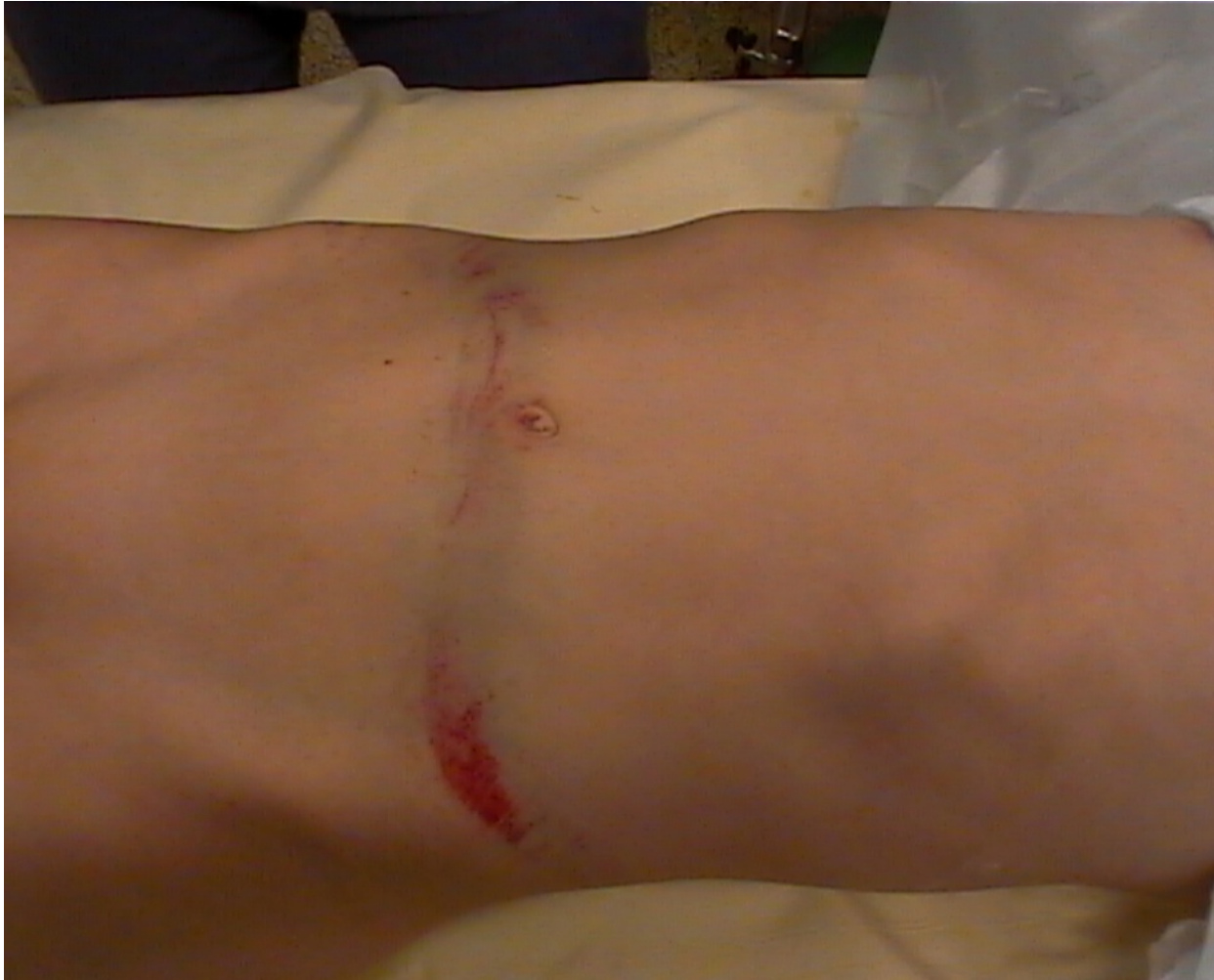Fracture de CHANCE



Fracture de CHANCE

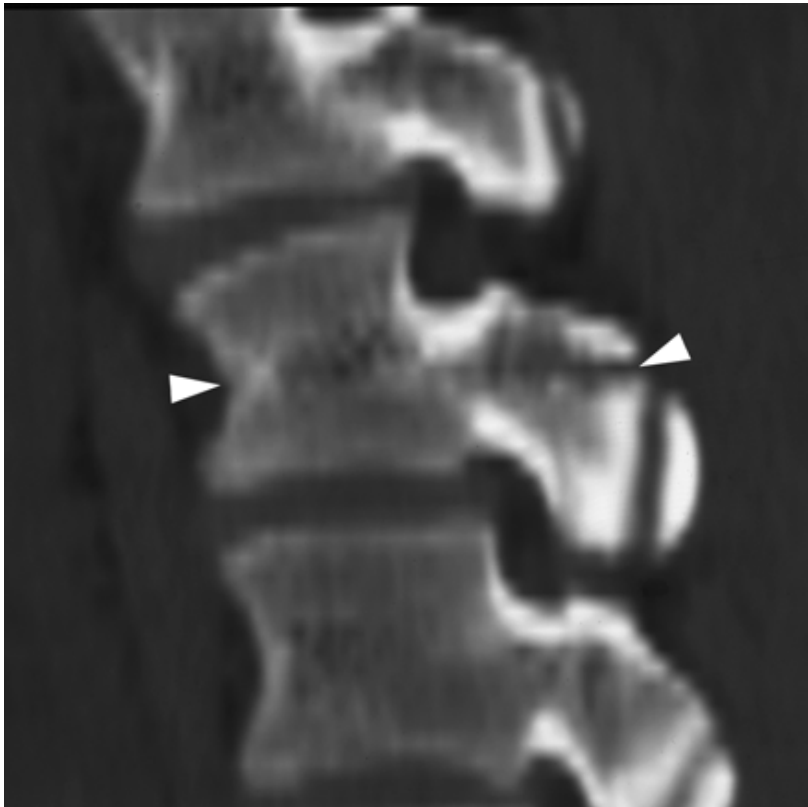

Fracture de CHANCE



Fracture de CHANCE

LESIONS VISCERALES +++

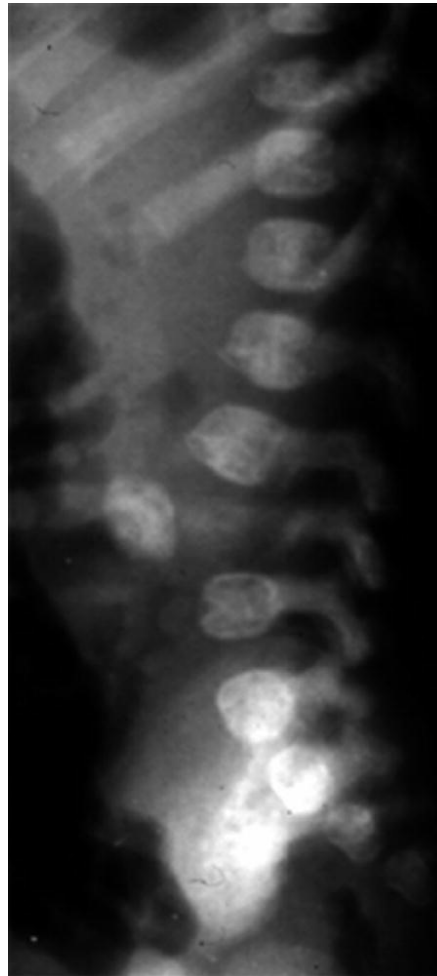


Trait purement osseux
Traitement orthopédique

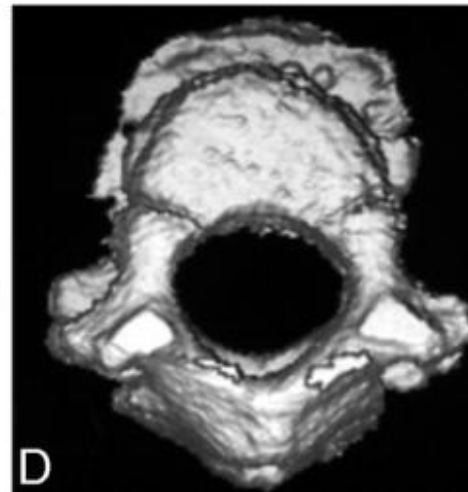
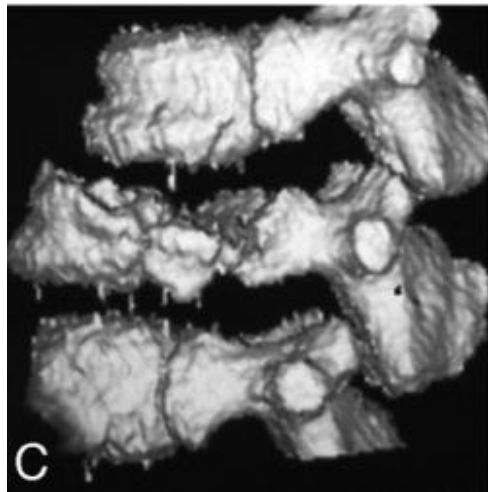
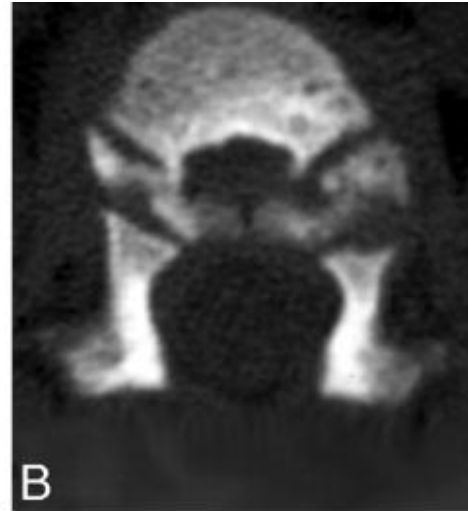
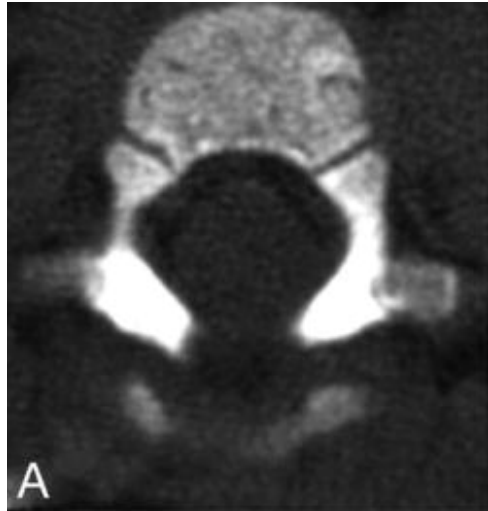
Recherche d'une lésion discale
associée

Chez le tout-petit

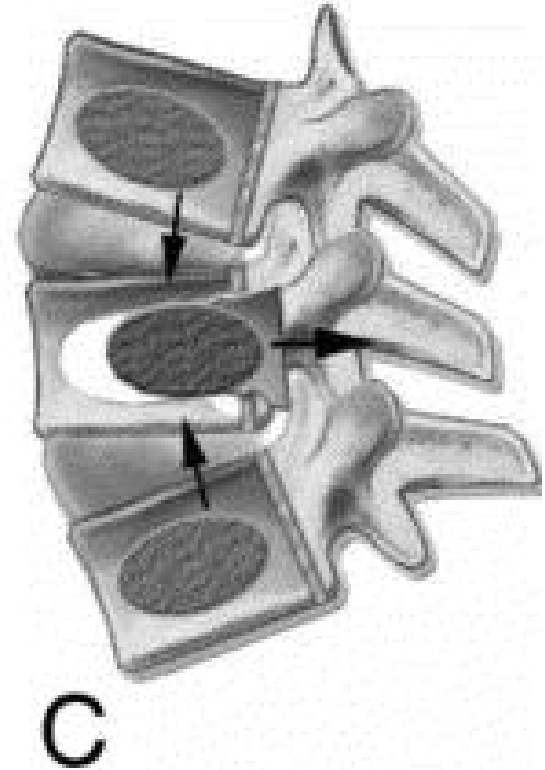
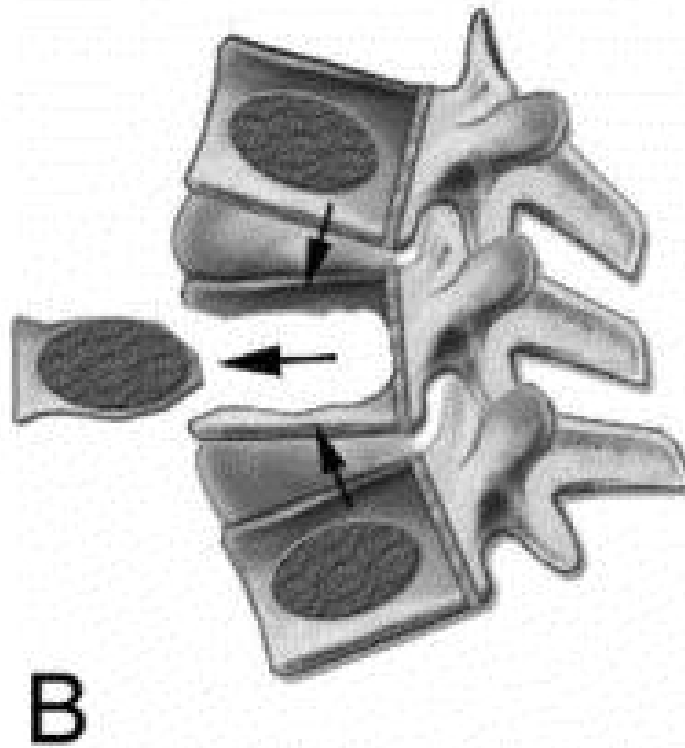
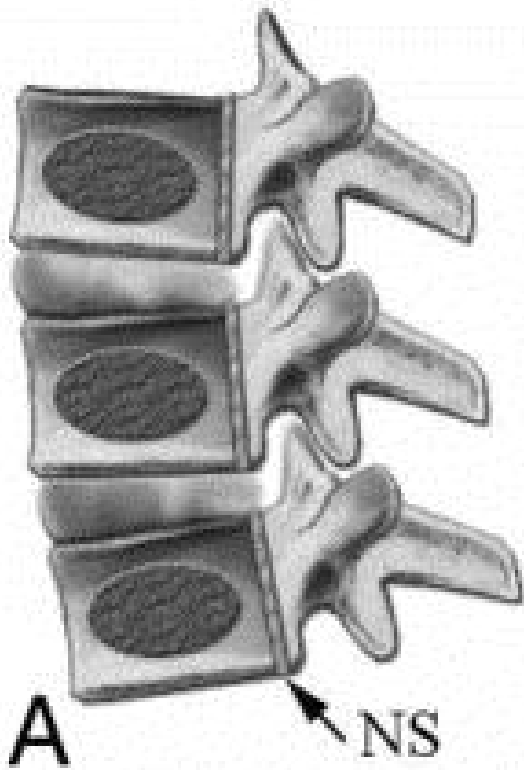Fracture de la synchondrose



Silvermann +++

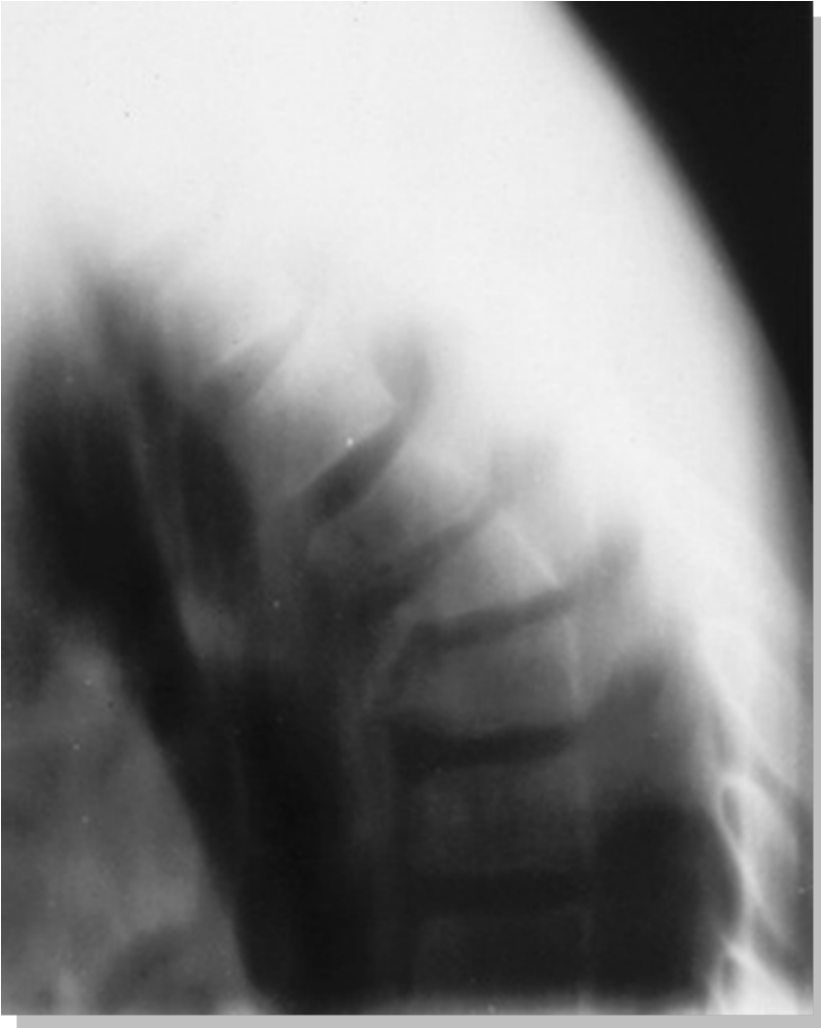

Silvermann +++



Après un traumatisme

Surveillance +++



Cyphoses post-traumatiques

Valeur de l'IRM

D'autant plus que l'enfant est jeune

Questions ?

