

Closed reduction in late-detected developmental dysplasia of the hip: indications, results and complications

P. Wicart¹
R. Seringe²
C. Glorion¹
A. Brassac¹
V. Rampal³

Abstract

Purpose The aim of the study was a review of the literature in order to evaluate the results and complications of closed reduction in late-detected developmental dysplasia of the hip (DDH).

Methods This study consisted of an analysis of the literature relative to late-detected DDH treatment options considering hip congruency, rates of re-dislocation and of avascular necrosis.

Results Gradual closed reduction (Petit-Morel method) appears to be an effective method concerning joint congruency restitution. Dislocation relapse and avascular necrosis are more efficiently prevented with closed *versus* open reduction. The tendency for spontaneous correction of acetabular dysplasia decreases if closed reduction is performed after 18 months of age. Patient age at the beginning of traction should be considered for the prognosis, with a lower rate of satisfactory results showing after the age of 3 years.

Conclusion In our opinion, the Petit-Morel method is a suitable treatment option for children aged between six months and three years with idiopathic DDH.

Cite this article: Wicart P, Seringe R, Glorion C, Brassac A, Rampal V. Closed reduction in late-detected developmental dysplasia of the hip: indications, results and complications *J Child Orthop* 2018;12:317-322. DOI 10.1302/1863-2548.12.180088

¹ Department of Paediatric Orthopaedic Surgery, Paris Descartes University, Necker/Sick Kid University Hospital, APHP, Paris, France

² Department of Orthopaedic Surgery, Paris Descartes University, Cochin University Hospital, APHP, Paris, France

³ Department of Pediatric Orthopaedic Surgery, Lenal University Hospital, Nice, France

Correspondence should be sent to P. Wicart, Department of Paediatric Orthopaedic Surgery, Paris Descartes University, Necker/Sick Kid University Hospital, APHP, 149 rue de Sèvres, 75015 Paris, France.

E-mail: p.wicart@aphp.fr

Keywords: Late-detected developmental dysplasia of the hip; closed reduction; pelvic osteotomy; avascular necrosis

Introduction

Early screening of developmental dysplasia of the hip (DDH) decreased the frequency of late diagnosis and treatment of this disease.¹ However, such cases may still be observed.²

There is no current consensus between the therapeutic benefits of open and closed reduction. Closed reduction methods have improved significantly during the last 15 years. Originally, Somerville and Scott³ applied traction followed with open reduction and femoral derotation osteotomy. In the early 1950s, a French team⁴ used traction with closed reduction and femoral osteotomy. Later, Morel⁵ advocated hip traction with abduction and internal rotation in order to achieve a progressive reduction of the dislocation, followed with a hip spica cast providing a penetration of the femoral head in the acetabulum.⁶ Such treatment was named the Petit-Morel technique.⁷

The aim of the study was a review of the literature in order to evaluate the published results and complications of closed reduction in late-detected DDH.

Methods

This article analyzes the literature relative to late-detected DDH treatment options considering hip congruency, rates of re-dislocation and of avascular necrosis.

Indications and technique of closed reduction

Indication of gradual closed reduction in late-detected DDH at our hospital is unilateral or bilateral idiopathic DDH over the age of six months and below five years. The child's weight should be at least 6 kg.

The aim of the first stage is to achieve the descent of the femoral head. To this end the child is fitted with a Berck harness (Sté FAG Medical SAS, St Georges de Reneins, France) which is fixed to the bed. Bilateral longitudinal skin traction is then applied with the hips in flexion of 45° for children aged below one year and with hip extension after this age. Horizontal traction is adequate because the ilio-*poas* tendon is already stretched by the adoptive stance

and gait demonstrated after walking age (Fig. 1a). The initial weight used for traction, which corresponds to 10% of the body-weight, is gradually increased depending on the child's weight (up to 50% of their body-weight on each limb) and the degree of migration of the femoral head is assessed on weekly radiographs. When the ossific nucleus is at the level of Hilgenreiner's line,⁸ progressive abduction (30° to 50°) and internal rotation equal to the femoral anteversion are applied in order to render the proximal femoral metaphysis horizontal and orientate the epiphysis towards the triradiate cartilage (Fig. 1b). In patients where the ossific nucleus is not radiologically visible, the appropriate time for beginning abduction is when Shenton's line had been restored on the radiographs. The amount of traction is then gradually reduced to allow for reduction of the femoral head into the acetabulum. The average duration of traction in Rampal et al's (2008)⁷ experience was 5.3 weeks. Thanks to recent shortening of the traction period, the duration of the traction is now between 3.5 and four weeks.

The second stage consists of the stabilization of the 'presented' femoral head, in order to allow its progressive 'seating' into the acetabulum and a spontaneous definitive concentric reduction. A hip spica cast is applied under general anaesthesia in the reduced position (20° flexion, 45° abduction and slight internal rotation) obtained at the end of the traction stage. Two successive casts, spaced two months apart, are applied.

The third stage consists of the operative management of residual acetabular dysplasia by a pelvic osteotomy.⁹ A pelvic osteotomy is indicated if acetabular dysplasia did not show sufficient spontaneous correction at the age of five to six years, or if a tendency to early subluxation was noted.

Results

Table 1 displays the results of studies on late-detected DDH applying closed reduction or open reduction considering the hip congruency (Severin score), the rate of re-dislocation and the rate of avascular necrosis.

Discussion

Literature reports good results in term of hip congruency (Severin¹⁰ grade I or II) after preliminary traction and early reduction in between 36% and 82%^{11,12} of hips (Fig. 2). Unsatisfactory evolution was related to residual acetabular dysplasia^{9,11,13} which did not sustain pelvic osteotomy. After gradual closed reduction and pelvic osteotomy, Morel,⁵ Kaneko et al¹⁴ and Rampal et al⁷ reported satisfactory results in, respectively, 85.4% and 82.7% and 93.6% of the hips. Thus, considering hip congruency, the Petit-Morel method seems to be the closed reduction method of choice. Open reduction provides excellent or good outcome rates in between 20%¹¹ and 100%.¹⁵ The best results^{9,16,17} achieved with open reduction do not differ to those obtained with the Petit-Morel method. Thus, considering hip architecture: closed reduction may not be preferred to open reduction.

Progressive closed reduction may fail in 9.7% of cases.⁵ However, a lower rate (4.3%) has been reported.⁷ Reduction failure is more frequent after acute closed reduction, with rates varying between 5.9% and 25%.^{7,17-19} Relapse of dislocation is also reported with open reduction in up to 5.6% of procedures.^{11,16,17,19,20-22} Thus, it appears that the Petit-Morel method may be more efficient than open reduction in preventing recurrent dislocation. Moreover, relapse of dislocation after open reduction




Fig. 1 Treatment of a two-year-old girl with right developmental dysplasia of the hip: (a) first step: horizontal traction in order to achieve the descent of the femur; (b) second step: abduction (A) + internal rotation (B) and trochanter strap (C).

Table 1 Analysis of the literature relative to late-detected developmental dysplasia of the hip treatment options: hip congruency, rates of re-dislocation and of avascular necrosis

Methods	Severin I or II	Re-dislocation	Avascular necrosis
Closed reduction			
<i>Traction and early reduction</i>			
Williamson et al 1989, ²⁸ Zionts and MacEwen 1986, ¹² Malvitz and Weinstein 1994, ¹³ Schoenecker et al 1995, ¹⁸ Daoud and Saighi-Bououina 1996, ¹⁹ Angliss et al 2005 ¹¹	36% to 82%	5.9% to 25%	5% to 72%
<i>Traction and gradual reduction</i>			
Morel 1975 ⁵	93.6%	9.7%	< 2%
Rampal et al 2008 ⁷	82.7%	2.8%	1.4%
Kaneko et al 2013 ¹⁴		1.3%	2.7%
Open reduction			
Salter and Dubos 1974, ⁹ Somerville and Scott 1957, ³ Berkeley et al 1984, ¹⁶ Williamson et al 1989, ²⁸ Galpin et al 1989, ²⁰ Haidar et al 1996, ²¹ Morcuende et al 1997, ²² Huang 1997, ¹⁷ Angliss et al 2005 ¹¹	20% to 96%	< 5.6%	2% to 88% (average: 19.6%)

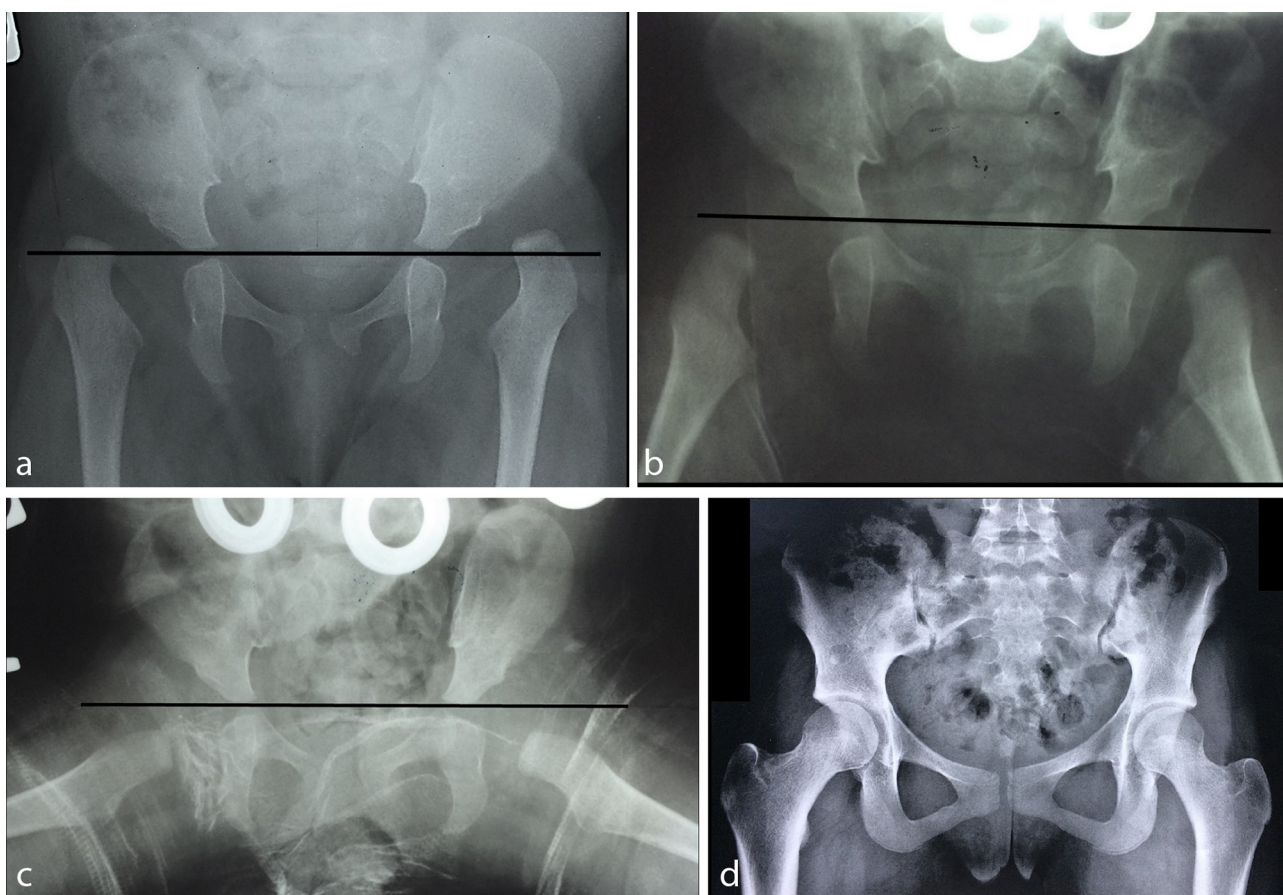


Fig. 2 Bilateral developmental dysplasia of the hip in a six-month-old girl: (a) initial radiography – notice the high position of the proximal femur relatively to the Hilgenreiner's line; (b) step 1: notice the descent of the proximal femur; (c) step 2: abduction and internal rotation; (d) result at 16 years old (Severin I - without surgery).

requires surgical revision which is very demanding and often provides non-satisfactory results with avascular necrosis in more than half of cases, with one-third of the hips rated Severin III or worse.^{20,23} According Angliss et al,¹¹ the frequency of long-term osteoarthritis was 25% and 49% after, respectively, closed and open reduction.

Long-term follow-up displayed a rate of total hip arthroplasty at 45 years after open reduction reaching 46%, revealing significant decreasing of good outcomes after 30 years of age.²⁴

The tendency for spontaneous correction of acetabular dysplasia²⁵ decreases if closed reduction is performed

after 18 months of age.^{7,21,26,27} Before pelvic osteotomies, the task of acetabular dysplasia correction was given to femoral varus derotational osteotomy, which did not succeed in correcting this flaw.^{7,9,13} Pelvic osteotomy, which successfully replaced femoral osteotomy, is an integral part of the Petit-Morel method.

Progressive closed reduction provides the lowest rates of avascular necrosis, reaching 2%.^{5,7,14} Extemporaneous closed reduction after traction induces higher rates of up to 5.8%.^{9,12,18} Overhead traction¹⁹ induced a frequency of avascular necrosis of 10%. Angliss et al¹¹ and Malvitz and Weinstein¹³ published unusually high rates, linked to articles' strict diagnostic criteria. Some articles dealing with closed reduction reported avascular necrosis mostly for relapsed dislocation which required open reduction.^{12,19} Open reduction^{7,15,17,19,21,22,28} resulted in poorer frequencies of avascular necrosis which were superior to 5%. This is three-times the rates observed after the Petit-Morel method, reflecting a major effect of open reduction on proximal femoral epiphysis perfusion. Open reduction combined with femoral shortening osteotomy^{16,20} may explain lower rates of avascular necrosis (< 5%), however,

they remain higher than those observed after closed reduction. The Petit-Morel method decreases the risk of avascular necrosis occurring.

The prognosis influence of the age at the beginning of traction should be considered (Fig. 3). Morel⁵ reported lower rate of satisfactory results after the age of three years. However, the number of patients older than three years treated according to the Petit-Morel method is too small⁷ to draw conclusions from.

Future developments of this method may include closed reduction combined with open psoas and adductor releases in selected cases²⁹ and MRI after cast achievement in order to analyze the perfusion of the femoral epiphysis and the quality of the reduction.³⁰

Finally, mental aspects and inconvenience of traction duration for both children and family should be the focus of a future study.

Conclusions

A study³¹ with a mean follow-up of 50 years, which is the longest follow-up published so far, reported satisfactory clinical

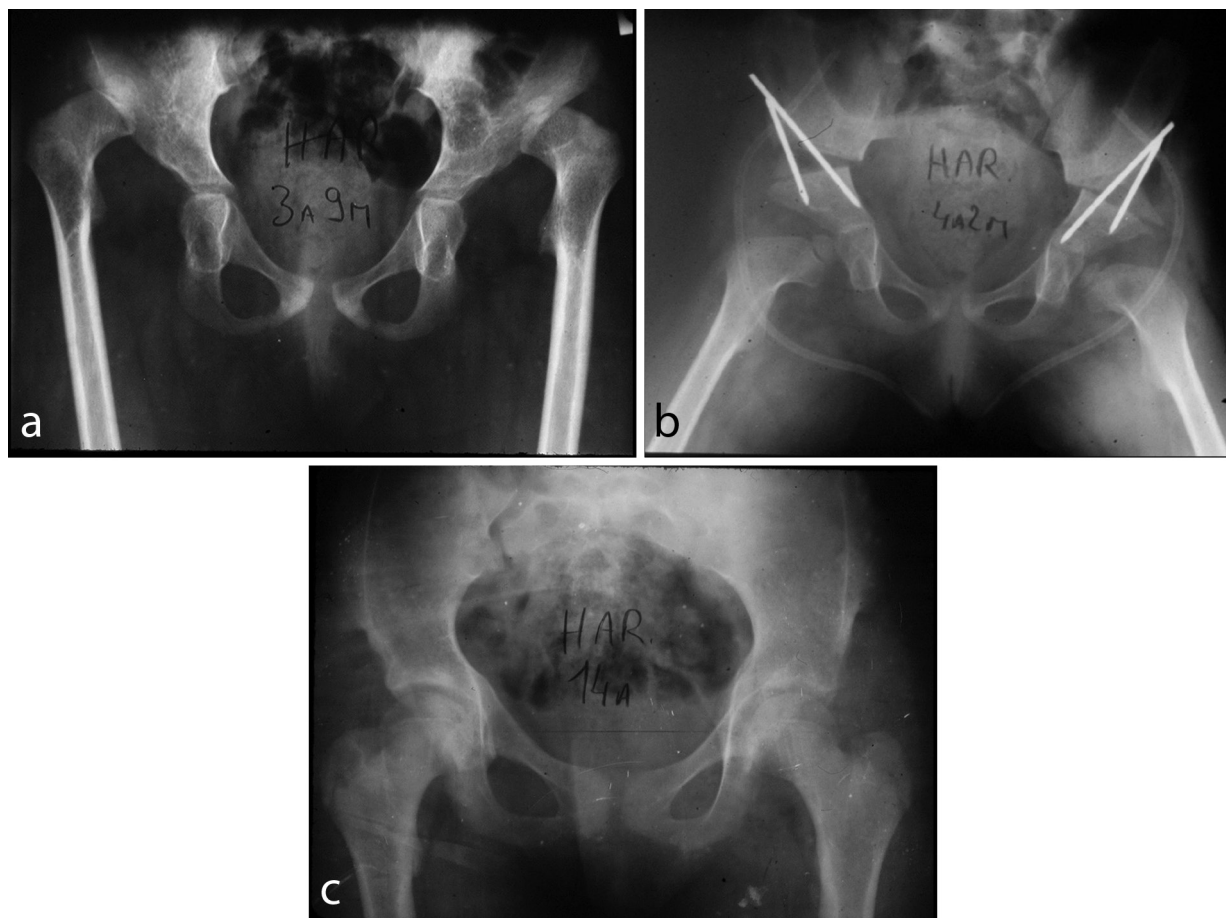


Fig. 3 Bilateral developmental dysplasia of the hip in a three years nine months old girl: (a) initial situation; (b) treatment with bilateral closed reduction and Salter osteotomy; (c) result at 14 years old (Severin I).

and radiographic outcomes after gradual closed reduction by skin traction in approximately two-thirds 83 hips.

Regarding the quality of the long-term follow-up results,³² displaying a hip survival reaching 95% at 40 years follow-up, we consider the Petit-Morel method to be the treatment of choice for children aged between six months and three years with idiopathic DDH.

Received 29 May 2018; accepted 18 June 2018.

COMPLIANCE WITH ETHICAL STANDARDS

FUNDING STATEMENT

No benefits in any form have been received or will be received from a commercial party related directly or indirectly to the subject of this article.

OA LICENCE TEXT

This article is distributed under the terms of the Creative Commons Attribution-Non Commercial 4.0 International (CC BY-NC 4.0) licence (<https://creativecommons.org/licenses/by-nc/4.0/>) which permits non-commercial use, reproduction and distribution of the work without further permission provided the original work is attributed.

ETHICAL STATEMENT

Ethical approval: Ethical approval: All procedures performed in studies involving human participants were in accordance with the ethical standards of the institutional and/or national research committee and with the 1964 Helsinki declaration and its later amendments or comparable ethical standards. Institutional review board approval and informed consent were waived for this work.

Informed consent: Not required.

ICMJE CONFLICT OF INTEREST STATEMENT

None declared.

REFERENCES

1. **Yngve D, Gross R.** Late diagnosis of hip dislocation in infants. *J Pediatr Orthop* 1990;10:777-779.
2. **Vallamshetla VR, Mughal E, O'Hara JN.** Congenital dislocation of the hip. A re-appraisal of the upper age limit for treatment. *J Bone Joint Surg [Br]* 2006;88-B:1076-1081.
3. **Somerville EW, Scott JC.** The direct approach to congenital dislocation of the hip. *J Bone Joint Surg [Br]* 1957;39-B:623-640.
4. **Petit P, Queneau P, Borde J.** Treatment of congenital luxations and subluxations of the hip in early childhood. *Rev Chir Orthop Reparatrice Appar Mot* 1962;48:148-186.
5. **Morel G.** The treatment of congenital dislocation and subluxation of the hip in the older child. *Acta Orthop Scand* 1975;46:364-399.
6. **Severin E.** Congenital dislocation of the hip; development of the joint after closed reduction. *J Bone Joint Surg [Am]* 1950;32-A:507-518.
7. **Rampal V, Sabourin M, Erdeneshoo E, et al.** Closed reduction with traction for developmental dysplasia of the hip in children aged between one and five years. *J Bone Joint Surg [Br]* 2008;90-B:858-863.
8. **Coussement A.** Repères et mesures en radiodiagnostic. *Expansion scientifique* 1974:152-153.
9. **Salter RB, Dubos JP.** The first fifteen year's personal experience with innominate osteotomy in the treatment of congenital dislocation and subluxation of the hip. *Clin Orthop Relat Res* 1974;98:72-103.
10. **Severin E.** Contribution to the knowledge of congenital dislocation of the hip joint: late results of closed reduction and arthrographic studies of recent cases. *Acta Chir Scand* 1941;84:1-142.
11. **Angliss R, Fujii G, Pickvance E, Wainwright AM, Benson MK.** Surgical treatment of late development displacement of the hip. Results after 33 years. *J Bone Joint Surg [Br]* 2005;87-B:384-394.
12. **Zionts LE, MacEwen GD.** Treatment of congenital dislocation of the hip in children between the ages of one and three years. *J Bone Joint Surg [Am]* 1986;68-A:829-846.
13. **Malvitz TA, Weinstein SL.** Closed reduction for congenital dysplasia of the hip. Functional and radiographic results after an average of thirty years. *J Bone Joint Surg [Am]* 1994;76-A:1777-1792.
14. **Kaneko H, Kitoh H, Mishima K, Matsushita M, Ishiguro N.** Long-term outcome of gradual reduction using overhead traction for developmental dysplasia of the hip over 6 months of age. *J Pediatr Orthop* 2013;33:628-634.
15. **Olney B, Latz K, Asher M.** Treatment of hip dysplasia in older children with a combined one-stage procedure. *Clin Orthop Relat Res* 1998;347:215-223.
16. **Berkeley ME, Dickson JH, Cain TE, Donovan MM.** Surgical therapy for congenital dislocation of the hip in patients who are twelve to thirty-six months old. *J Bone Joint Surg [Am]* 1984;66-A:412-420.
17. **Huang SC, Wang JH.** A comparative study of nonoperative versus operative treatment of developmental dysplasia of the hip in patients of walking age. *J Pediatr Orthop* 1997;17:181-188.
18. **Schoenecker PL, Dollard PA, Sheridan JJ, Strecker WB.** Closed reduction of developmental dislocation of the hip in children older than 18 months. *J Pediatr Orthop* 1995;15:763-767.
19. **Daoud A, Saighi-Bououina A.** Congenital dislocation of the hip in the older child. The effectiveness of overhead traction. *J Bone Joint Surg [Am]* 1996;78-A:30-40.
20. **Galpin RD, Roach JW, Wenger DR, Herring JA, Birch JG.** One-stage treatment of congenital dislocation of the hip in older children, including femoral shortening. *J Bone Joint Surg [Am]* 1989;71-A:734-741.
21. **Haidar RK, Jones RS, Vergroesen DA, Evans GA.** Simultaneous open reduction and Salter innominate osteotomy for developmental dysplasia of the hip. *J Bone Joint Surg [Br]* 1996;78-B:471-476.
22. **Morcuende JA, Meyer MD, Dolan LA, Weinstein SL.** Long-term outcome after open reduction through an anteromedial approach for congenital dislocation of the hip. *J Bone Joint Surg [Am]* 1997;79-A:810-817.
23. **Kershaw CJ, Ware HE, Pattinson R, Fixsen JA.** Revision of failed open reduction of congenital dislocation of the hip. *J Bone Joint Surg [Br]* 1993;75-B:744-749.
24. **Thomas SR, Wedge JH, Salter RB.** Outcome at forty-five years after open reduction and innominate osteotomy for late-presenting developmental dislocation of the hip. *J Bone Joint Surg [Am]* 2007;89-A:2341-2350.
25. **Cherney DL, Westin GW.** Acetabular development in the infant's dislocated hips. *Clin Orthop Relat Res* 1989;242:98-103.
26. **Lindstrom JR, Ponseti IV, Wenger DR.** Acetabular development after reduction in congenital dislocation of the hip. *J Bone Joint Surg [Am]* 1979;61-A:112-118.

27. **Wicart P, Ghanem I, Seringe R.** Open reduction after failure of conservative treatment for congenital dislocation of the hip initiated before the age of six months. *Rev Chir Orthop Reparatrice Appar Mot* 2003;89:115-124.
28. **Williamson DM, Glover SD, Benson MKD.** Congenital dislocation of the hip presenting after the age of three years. A long-term review. *J Bone Joint Surg [Br]* 1989;71-B:745-751.
29. **Tennant SJ, Eastwood DM, Calder P, Hashemi-Nejad A, Catterall A.** A protocol for the use of closed reduction in children with developmental dysplasia of the hip incorporating open psoas and adductor releases and a short-leg cast: mid-term outcomes in 113 hips. *Bone Joint J* 2016;98-B:1548-1553.
30. **Jadhav SP, More SR, Shenava V, Zhang W, Kan JH.** Utility of immediate postoperative hip MRI in developmental hip dysplasia: closed vs. open reduction. *Pediatr Radiol* 2018 April 25. (Epub ahead of print)
31. **Terjesen T, Horn J, Gunderson RB.** Fifty-year follow-up of late-detected hip dislocation: clinical and radiographic outcomes for seventy-one patients treated with traction to obtain gradual closed reduction. *J Bone Joint Surg [Am]* 2014;96:e28.
32. **Morin C, Bisogno J, Kulkarni S, Morel G.** Treatment of late-presenting developmental dislocation of the hip by progressive orthopaedic reduction and innominate osteotomy. Our results with more than 30 years of follow up. *J Child Orthop* 2011;5:251-260.